



Contents lists available at ScienceDirect

International Journal of Surgery Case Reports

journal homepage: www.casereports.com

Angioleiomyoma of urethra: A case report

R.A. Amir^{a,*}, S.S. Sheikh^b^a University of Dammam, P.O. Box: 12113, Dhahran 31311, Saudi Arabia^b Chief of Pathology Services Division, Johns Hopkins Aramco Health Care, Dhahran, Saudi Arabia

ARTICLE INFO

Article history:

Received 24 January 2015

Received in revised form 18 March 2015

Accepted 29 March 2015

Available online 1 April 2015

Keywords:

Angioleiomyoma

Leiomyoma

Urethra

Neoplasm

ABSTRACT

INTRODUCTION: Angioleiomyomas are benign smooth muscle tumors that arise from blood vessel walls and commonly involve the deep dermal and subcutaneous tissue. Urethral angioleiomyomas are only rarely seen with only less than 5 cases reported in literature.

PRESENTATION OF CASE: We herein present a case of a 72 year old man who presented with gross hematuria. Cystoscopy showed a polypoid urethral lesion that was resected and on pathologic examination was diagnosed as angioleiomyoma.

DISCUSSION: Differential diagnoses of a urethral polypoid lesion, including inflammatory and neoplastic conditions are discussed. The main emphasis is on recognition and review of angioleiomyoma features when presenting in commonly encountered locations and other sites that are only rarely involved.

CONCLUSION: This rare case reports an elderly patient with angioleiomyoma in an extremely unusually encountered location and presenting with unusual symptoms of gross hematuria that did not recur after resection of the lesion.

© 2015 The Authors. Published by Elsevier Ltd. on behalf of Surgical Associates Ltd. This is an open access article under the CC BY-NC-ND license (<http://creativecommons.org/licenses/by-nc-nd/4.0/>).

1. Introduction

Urethral neoplasms, in particular benign mesenchymal tumors are exceedingly rare. To our knowledge only less than 5 cases of primary urethral angioleiomyomas are reported in literature mostly in females. Angioleiomyomas are benign smooth muscle tumors that are commonly seen in subcutaneous location of the extremities. Herein, we present a rare case of primary angioleiomyoma of urethra in a 72 years old male who presented with hematuria.

2. Presentation of case

A 72 year old male who is a known case of diabetes mellitus presented with gross hematuria of two day duration. There was no history of obstructive symptoms. His physical examination was unremarkable apart from markedly enlarged prostate that was identified on rectal examination. Repeated urine cytology showed few atypical cells. His laboratory data showed normal hemogram and electrolytes. Ultrasound showed normal kidneys and urinary bladder. Retrograde pyelogram was normal.

Due to the persistent gross hematuria and passage of blood clots and presence of atypical cells in urine, clinical decision was made to do cystoscopy and at the same time do transurethral resection of prostate (TURP) since the patient had a markedly enlarged prostate. Cystoscopy showed an incidental urethral polypoid lesion that was

excised in addition to random biopsies that were taken from the urinary bladder.

Pathological examination showed no significant histopathologic findings in the bladder biopsies. The prostatic tissue exhibited benign prostatic hyperplasia. The prostatic urethral polyp showed a well circumscribed nodule exhibiting scattered thick walled blood vessels that were surrounded by spindle cell proliferation (Fig. 1). The cells were elongated, had eosinophilic cytoplasm, bland appearing nuclei, and lacked any cytologic atypia or increased mitotic activity (Fig. 2A). In addition, there was underlying mild chronic inflammation. The spindle cell proliferation and the smooth muscle walls of the blood vessels were strongly positive for Actin (Fig. 2B). The histologic features were consistent with an angioleiomyoma.

The patient had an uneventful postoperative course and 12 years later he had no recurrence of hematuria, atypical cells in urine, or evidence of recurrent urethral lesion.

3. Discussion

Urethral polypoid lesions most commonly represent reactive inflammatory conditions. Primary urethral neoplasms are extremely rare. Most urethral lesions encompass urethral caruncle, diverticulum, mucosal prolapse, skene duct cyst/abscess, cowper gland duct cyst, fibroepithelial polyp, and prostatic-type poly. Rarely malakoplakia, endometriosis, and amyloidosis can be seen involving the urethral location. Urethral neoplasms, in particular benign mesenchymal tumors, are exceedingly rarely reported [1]. Marshall et al. reported a study of 394 lesions of female urethra revealing 372 benign lesions and only 22 malignant tumors.

* Corresponding author. Tel.: +966 533032011; fax: +966 138776783.

E-mail addresses: chinga93@gmail.com (R.A. Amir), sheikhss28@gmail.com (S.S. Sheikh).

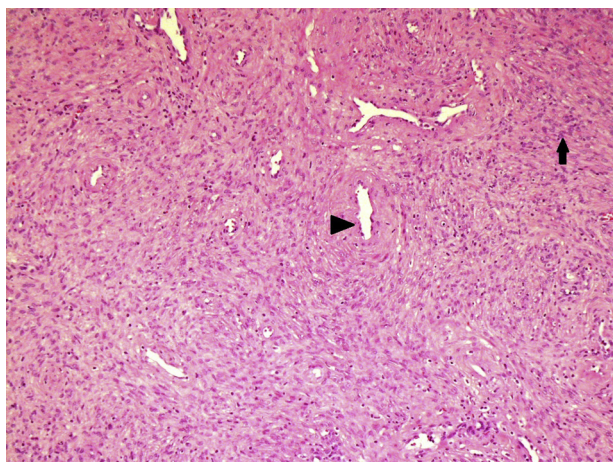


Fig. 1. Low power view exhibiting spindle cell proliferation (arrow) and scattered in between thick-walled blood vessels (arrowhead).

Caruncle was found to be the most commonly encountered lesion accounting for 96% and no leiomyoma or angioleiomyoma was reported in that study. Grabstaldt reported 96 urethral tumors again with not a single case of angioleiomyoma [2]. Subsequently, few leiomyomas were reported in literature with only rare cases of angioleiomyomas that arose from urethra [3–7]. Most of these angioleiomyomas were associated with obstructive symptoms as

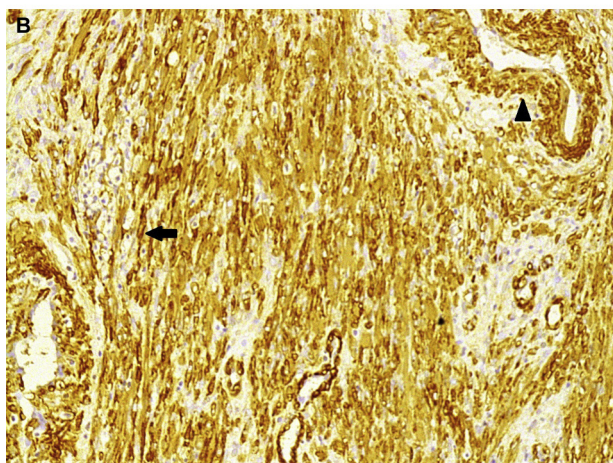
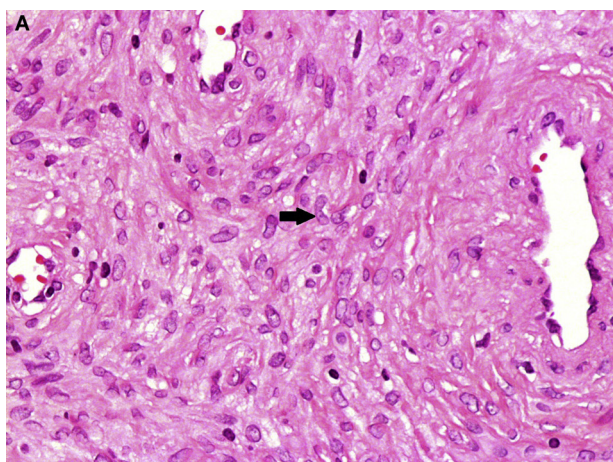


Fig. 2. (A) High power showing neoplastic spindle cells (arrow) with elongated bland nuclei and abundant eosinophilic cytoplasm. (B) Actin strongly positive in the spindle cell proliferation (arrow) and walls of blood vessels (arrowhead).

is the case with many other urethral lesions, however our patient presented only with gross hematuria and no symptoms of obstruction.

Angioleiomyomas are common deep dermal, or subcutaneous benign, well-circumscribed smooth muscle tumors that originate from the walls of blood vessels in particular veins. Although the neoplasm can affect any age, it is commonly seen in adults between the age of 30 and 60 years of age. There is mild overall male predominance, however, larger studies show that there is female predominance when angioleiomyomas are seen involving lower extremities and male predominance in the head and neck region and upper extremities. 60% of the lesions occur in lower extremities below the thighs. Typically, the lesion presents as a solitary, small (less than 2 cm), slow growing, nodule affecting the extremities, and is often painful or tender on compression [8,9]. Only rare cases have been reported in literature that arise in urethral location. To our knowledge, less than five cases have been reported thus far that are mostly reported in females.

Grossly these lesions are sharply circumscribed white rubbery nodules that are mostly 1–2 cm in size. Histologically, these are mostly round encapsulated lesions that are composed of many blood vessels of variably thickened walls that are surrounded by interlacing fascicles and bundles of uniform spindled cell. There may be areas of myxoid change, thrombosis, lipomatous metaplasia, or dystrophic calcifications. Rarely prominent nuclear palisading mimicking Verocay bodies is seen. Occasional cases may exhibit epithelioid changes of the cells and few cells with enlarged hyperchromatic nuclei, however, no increase in mitotic activity is seen in these cases. Such atypia without mitotic activity is considered secondary to degenerative or reactive changes and does not indicate malignancy. Lipomatous angioleiomyomas are sometimes erroneously called “angiomyolipomas”. True angiomyolipomas belong to the family of Perivascular epithelioid cell tumor (PEComas), however, angioleiomyomas are not related to PEComas and do not show the characteristic HMB-45 positive staining of PEComas.

Three histologic variants have been recognized; the most common one being “capillary or solid” type representing approximately 67% of cases. Other variants include “venous” and “cavernous” types. Identification of these histologic variants is important for pathologists to be able to identify them and recognize them as variants of the same benign entity, however, has no clinical significance [10].

Immunohistochemistry shows cells to be positive for smooth muscle actin, calponin, and h-caldesmin. In addition, there is variable positive staining with desmin.

Cytogenetic studies show chromosomal imbalances, with most consistent finding being recurrent losses in chromosome 22q11 [11].

Surgical excision is the recommended treatment for any urethral lesion mainly to identify the lesion histologically, and to distinguish reactive from neoplastic, and benign from malignant tumors. Examples include smooth muscle tumors to differentiate benign leiomyoma from leiomyosarcoma based on the number of mitotic figures and benign versus malignant urothelial neoplasms based on architectural and cytologic features.

Recurrence of angioleiomyoma after simple excision is extremely rare and malignant transformation has not been convincingly documented or reported in literature.

4. Conclusion

In conclusion, we herein, report a case of a primary angioleiomyoma arising from a rarely encountered location, urethra, in a male patient who presented with only gross hematuria.

Angioleiomyomas are benign smooth muscle neoplasms of vessel walls that are commonly seen in subcutaneous and deep dermal tissue of extremities. Only rare cases are reported to arise from other sites with only less than 5 cases reported in literature involving urethra.

Consent

Not applicable.

Author contribution

Rawan Amir: writing the manuscript.
Salwa Sheikh: reviewer.

Acknowledgment

There is no conflict of interest or financial acknowledgments for this case report.

References

- [1] M. Amin, D. Grignon, J. Srigley, J. Eble, Pathology of male and female urethra, in: *Urological Pathology*, Wolters Kluwer, 2014, pp. 469–481.
- [2] H. Grabstald, Tumors of the urethra in men and women, *Cancer* 32 (1973) 1236–1255.
- [3] T. Kato, T. Kobayashi, R. Ikeda, T. Nakamura, K. Akakura, T. Hikage, et al., Urethral leiomyoma expressing estrogen receptors, *Int. J. Urol.* 11 (2015) 573–575.
- [4] C. Cheng, F. Mac-moune Lai, P.S.F. Chan, Leiomyoma of the female urethra: a case report and review, *J. Urol.* 148 (1992) 1526–1527.
- [5] D. Pacik, J. Dolezel, R. Skoumal, J. Bucek, J. Kladsensky, Very rare angioleiomyoma of the male urthra, *Int. Urol. Nephrol.* 25 (2015) 480–484.
- [6] J. Monzon, G. Rodriguez, S. Trilla, Obstructive urethral angioleiomyoma, *Arch. Esp. Urol.* 57 (2015) 1128–1130.
- [7] G. Krivoborodov, A. Raksha, V. Malenko, Angioleiomyoma of the ureter, *Urologia* 3 (2015) 43–45.
- [8] M. Miettinen, Ch:16. Smooth muscle tumors, tumors and non-neoplastic conditions, in: *Modern Soft Tissue Pathology*, 1st ed., Cambridge, 2010, pp. 463–466.
- [9] P. Mckee, E. Calonje, S. Granker, Ch: 31. Connective tissue tumors, in: *Pathology of the Skin with Clinical Correlations*, 3rd ed., Elsevier Mosby, 2005, pp. 1799–1800.
- [10] T. Hachisuga, H. Hashimoto, M. Enjoji, Angioleiomyoma. A clinicopathologic reappraisal of 562 cases, *Cancer* 54 (1) (1984) 126–130.
- [11] J. Nishio, H. Iwasaki, Y. Ohijimi, et al., Chromosomal imbalances in angioleiomyomas by comparative genomic hybridization, *Int. J. Mol. Med.* 13 (2004) 13–16.

Open Access

This article is published Open Access at sciedirect.com. It is distributed under the [IJSCR Supplemental terms and conditions](#), which permits unrestricted non commercial use, distribution, and reproduction in any medium, provided the original authors and source are credited.