

Comparing the Ability of Different Materials and Techniques in Filling Artificial Internal Resorption Cavities

 Kazem Ashofteh YAZDI,  Mohsen AMINSOBHANI,  Parvin ALEMI

ABSTRACT

Objective: This ex vivo study aims to investigate the root filling quality of warm vertical technique, single-cone technique with GuttaFlow2, Endoseal MTA and EndoSequence BC sealer as a sealer in artificial internal resorption cavity.

Methods: For this study, 40 human single-root teeth were selected. After root preparation, the roots were horizontally sectioned 7 mm from the apex. The hemisphere cavities were created on both sides, and then they were re-approximated. According to filling methods and materials, the samples were randomly assigned to four experimental groups: I: warm vertical compaction technique (WVC), II: single-cone technique with GuttaFlow2 (GF), III: single-cone technique with Endoseal MTA sealer (EM), IV: single-cone technique with EndoSequence BC sealer (ES). Filled roots were radiographed in buccolingual and mesiodistal views to check the obturation, and stored in humid environment at the room temperature for 7 days. Each tooth was sectioned 7 mm from the root apex at the level of the previous cut, and it was then photographed under stereomicroscope. The photographs and radiographs of all samples were imported to an image-analysis software to calculate the percentage of sealer, gutta-percha, and voids. The results were statistically analyzed using one-way ANOVA and Kruskal–Wallis Dunn's tests.

Results: In buccolingual view of radiographs, the WVC and EM groups showed significantly lower percentage of voids (P value <0.05) compared to that in the GF group. In mesiodistal view, the WVC and EM groups showed significantly lower percentage of voids (P value <0.05) compared to that in the GF and ES groups. In stereomicroscope evaluation, the WVC and EM groups showed significantly lower percentage of voids (P value <0.05) compared to that in the GF and ES groups. The differences observed between the WVC and EM groups (P value >0.05) or between the GF and ES groups (P value >0.05) were not significant.

Conclusion: WVC technique and single-cone technique with EM sealer are the optimum methods to fill artificial resorption cavities.

Keywords: Calcium silicate, filling quality, GuttaFlow2, gutta-percha, internal resorption, root filling techniques

HIGHLIGHTS

- Endoseal MTA and EndoSequence BC sealer are new premixed and pre-loaded MTA sealer in a syringe.
- The filling quality of different materials and techniques in artificial internal resorption cavities were assessed using two different methods: radiography and observation of sectioned samples with a stereomicroscope.
- The WVC technique and single-cone technique with Endoseal MTA are optimal for filling artificial resorption cavities.

INTRODUCTION

A successful root canal therapy aims to obtain complete filling of the root canal system with no voids using a three-dimensionally stable and biocompatible filling material. The normal root-canal anatomy may be changed by pathological processes such as internal root resorption (IRR) that makes complete filling of the root canal space rather challenging (1). Loss of dental hard tissues caused by the clastic activities produces root resorption (2). Root resorp-

tion is classified into external and internal based on the location of the resorption in relevance to the root surface (3). The importance of achieving total filling of the root canal system has been emphasized in case of IRR (4). Thus, the filling materials should be flowable to obturate the resorption defect adequately (5).

A number of ex vivo studies have been conducted to evaluate many techniques and materials to examine their ability to fill IRR. Collins et al (6) proposed the use of warm lateral and warm vertical

Please cite this article as: Yazdi KA, Aminsobhani M, Alemi P. Comparing the Ability of Different Materials and Techniques in Filling Artificial Internal Resorption Cavities. *Eur Endod J* 2019; 4: 21-7

From the Department of Endodontic (P.A. ✉ Parvin.alemi@gmail.com, K.A.Y., M.A.) School of Dentistry, Tehran University of Medical Sciences, Tehran, Iran; Department of Endodontic (M.A.) School of Dentistry, AJA University of Medical Sciences, Tehran, Iran

Received 21 April 2018, last revision received 05 September 2018, accepted 05 November 2018

Published online: 13 December 2018 DOI 10.14744/eej.2018.13008

compaction (WVC) techniques for such cases. Gencoglu et al (5) found that thermoplasticized gutta-percha injection techniques using Obtura II system were significantly better in obturating artificial internal resorption cavities (AIRC) than Thermafil and cold lateral compaction techniques.

GuttaFlow2 (Coltene, Altstätten, Switzerland) is a cold, flowable, and self-curing root filling material containing polydimethylsiloxane and gutta-percha powder with a particle size of less than 30 µm. According to the manufacturer, this material has great flow properties and it expands a little on setting that raises adaptation to root canal system (7).

MTA is a suitable repair material in endodontic treatments because of its useful properties like good sealing capability, excellent biocompatibility and acceptable antibacterial activity (8, 9). However, it cannot be recommended as a routine sealer or root canal filling material because of its disadvantages such as difficulty in filling of complicated root canal system, long setting time, unknown solvent for set MTA (8), inadequate water to powder ratio and insufficient compaction which prevent adaptation of MTA to the root canal walls (10, 11). To overcome potential shortcomings of MTA as a root canal filling material, calcium-silicate-based sealer was used during the root canal filling procedures (12). Endoseal MTA (Maruchi, Wonju, Korea) has been recently introduced as a premixed and pre-loaded calcium-silicate-based sealer in a syringe. Unlike some other products, it permits direct application of the sealer into the root canals without requiring powder/liquid mixing. Some desirable mechanical and biological characteristics of calcium-silicate-based sealers include initial fast setting time, higher washout resistance, biocompatibility and bioactivity (10).

Bioceramic materials with faster setting time, homogeneous mass during placement and better handling characteristics are better alternatives to MTA (13). EndoSequence BC sealer (Brasseler, Savannah, USA) has been recently developed to improve the seal of root canal filling. According to the manufacturer, it is a premixed ready-to-use injectable bioceramic cement paste that requires the presence of moisture in the dentinal tubules to set (14).

Today, several root filling techniques are used for three-dimensional and homogenous filling of root canal system. Among them, the single-cone technique with matched-taper gutta-percha cones is one convenient option. It provides better adaptation in three-dimensional preparation (15) and it takes lesser time compared to that taken by other techniques (16). New injectable sealers are designed to use in single-cone technique (17, 18). To facilitate root filling, this technique relies on a sealer with good physicochemical properties. It allows the sealer to flow and to fill any space between the cone and dentine that provides a tight seal (19).

The objective of this ex vivo study is to investigate the quality of root filling by measuring the sealer/gutta-percha/voids ratios of AIRC filled with the WVC technique and single-cone technique with GuttaFlow2, Endoseal MTA, and EndoSequence BC sealer as a sealer.

MATERIALS AND METHODS

40 single-root teeth (recently extracted due to periodontal disease) were selected. These teeth were adjusted to a length of 20 mm through the coronal portion reduction using a diamond fissure bur (Jota AG, Rüthi, Switzerland). A conventional endodontic access cavity was prepared in each tooth. Then, a size 10 K-file (Micro-Mega, Besancon, France) was inserted into the canal until only the tip was visible at the apical foramen. The length of the file was measured, and 1 mm was subtracted from it to determine the working length. After that, ProTaper Universal files (#S1-F3, Dentsply Maillefer, OK, USA) were used. The manufacturer instructions were followed in cleaning and shaping of the root canal system up to F3 file combined with 1 ml of 2.5% sodium hypochlorite (Cerkamed, Stalowa Wola, Poland) irrigation with 30 gauge side-vented needle (Henry Schein, NY, USA) between each step. Subsequently, all teeth canals were rinsed to remove any remaining smear layer using 1 ml 17% EDTA (Morvabon, Tehran, Iran) for 1 min, followed by 5 ml 2.5% sodium hypochlorite irrigation.

To create AIRC, the roots were horizontally sectioned (Kerr Rotary, Biberach, Germany) 7 mm from the root apex by a fine diamond disc. Hemisphere cavities were created using a low speed no. 6 round carbide bur around the periphery of the opening of the root canal of each section. The sections were joined together by cyanoacrylate glue (Rower glue, Tabriz, Iran) on the dentine surface around the cavities. The teeth were radiographed in buccolingual and mesiodistal views to visualize the AIRC. The prepared teeth were randomly divided into four groups, each with ten samples.

Group I: Warm vertical compaction technique (WVC)

The master cone (F3, ProTaper gutta-percha, Dentsply Maillefer, Ballaigues, Switzerland) was removed after adaptation with 0.5–2 mm shorter than the prepared working length. Then, Ad-seal root canal sealer (Meta Biomed, Cheongju-si, Korea) was applied to the cone and walls of the prepared canal. The cone was then placed in the canal, and the coronal portion was removed with a heated instrument. A heated plugger (Kerr, Orange CA, USA) removed the coronal portion of gutta-percha in successive increments as well as softened the remaining material in the canal. A Schilder plugger #10 (Dentsply Maillefer, Ballaigues, Switzerland) was inserted into the canal to compact the gutta-percha, forcing the plasticized material apically. The process was repeated until reaching the apical third segment. The coronal canal space was gradually back-filled with thermoplasticized gutta-percha injection techniques using E&Q master root filling gun (Meta Biomed, Chungcheongbuk-do, Korea) until gutta-percha became visible in the canal orifice. Schilder hand pluggers #10, #11, #12 (Dentsply Maillefer, Ballaigues, Switzerland) were used every 3–4 mm to vertically compact the filling material.

Group II: Single-cone technique with GuttaFlow2 (GF)

F3 ProTaper gutta-percha was used as a master cone. Following the manufacturer instructions, the mixed material came out from the auto-mix needle tip with low pressure to a GuttaFlow2 syringe. Then, the canal was impregnated using GuttaFlow2 by master cone. A master point was then coated with

sufficient GuttaFlow2 and fitted to the proper working length. Finally, the master point was cut off at the orifice and vertically compacted with a hand plugger.

Group III: Single-cone technique with Endoseal MTA sealer (EM)

Endoseal MTA was gradually injected into the canal until sealer was seen at the canal orifice. Then, the master point was coated with adequate sealer, and was fitted to the proper working length. Next, an ultrasonic tip (NSK, Kanuma, Japan) connected to an ultrasonic device (NSK, Kanuma, Japan) was used to gutta-percha for better distribution of the sealer. The ultrasonic device power was set on "7" to apply an indirect vibration to the pincette that held the master cone. The master gutta-percha cone was cut at the orifice level. Coronal compaction was done with hand pluggers.

Group IV: Single-cone technique with EndoSequence BC sealer (ES)

Following the manufacturer instructions, the tip of the syringe was inserted into the coronal third of root canal. A small amount of EndoSequence BC sealer was gently dispensed into the root canal by compressing the plunger of the syringe. No

15 hand file was used to lightly coat the root canal wall with sealer. Then, the master gutta-percha cone (F3 ProTaper gutta-percha) was coated with a thin layer of sealer, and inserted very slowly into the canal. Eventually, the master point was cut off at the orifice, and a hand plugger was used to compact the filling vertically.

To check the filling, filled roots were radiographed in buccolingual and mesiodistal views using the CMOS sensor (Kodak, Marne-la-Vallee, France) and Xgenus dental X-ray unit (de Götzen, Via Roma, Italy). Then, they were stored in humid environment at the room temperature for 7 days to ensure that the materials had been set. One postgraduate student performed all root canal preparations and fillings.

Radiographic evaluation

The radiographs (in buccolingual and mesiodistal views) of all samples were imported to a computer-based image-analysis software (AutoCAD, Autodesk Inc, USA). This software was used to calculate the percentage of filling areas and voids in radiographs (Fig. 1). Then, the specimens were grouped as follows:

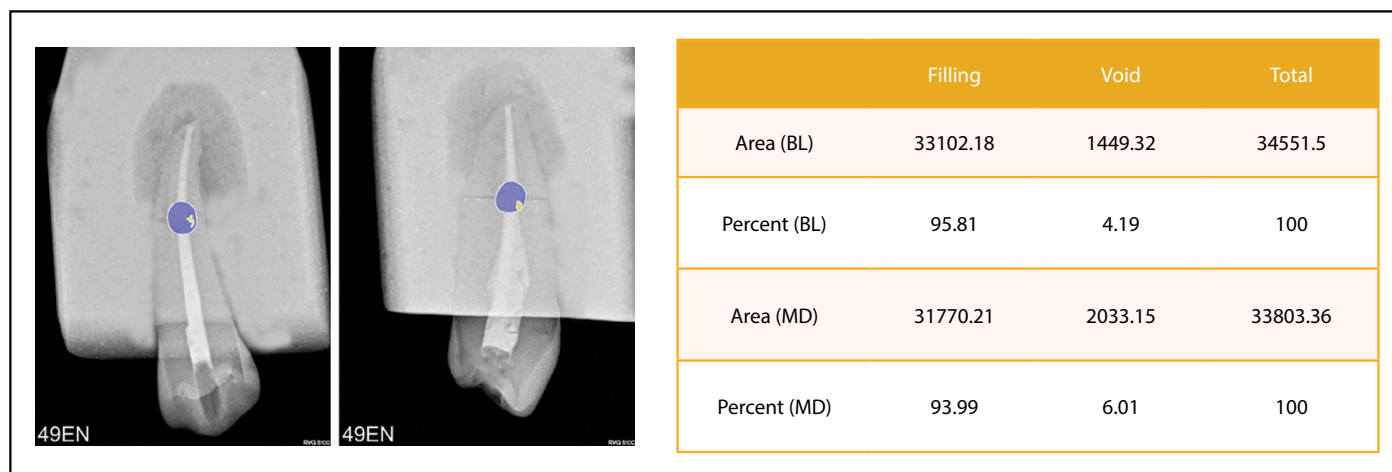


Figure 1. Distribution of filling (purple area) and void (yellow area) areas in buccolingual and mesiodistal radiographs of a sample




Figure 2. Distribution of gutta-percha (pink area), sealer (purple area), and void (yellow area) are as in stereo microscope cross-section of a sample

Total filling: The AIRC was completely obturated in the buccolingual as well as in the mesiodistal radiographs. No voids were seen.

Filling with void: The obturated AIRC indicated voids in the bulk of the filling material or between the filling material and the dentine walls in buccolingual and/or mesiodistal radiographs.

Stereomicroscopic evaluation

Each tooth was sectioned with a scalpel (IndiaMART, Kolkata, India) 7 mm from the apex at the level of the previous cut. The root sections were evaluated under stereomicroscope model LA-SZM45-B1 (Nanjing Sunny Optical Instrument, Nanjing, China) with 30× magnification. The images were saved in the JPEG format by the Dinocapture 2.0 software using AM423X Dino-Eye digital eyepiece (Dino-Lite Edge, New Taipei, Taiwan) and RL-L64 LED light source LED model. The photographs of all samples were imported to a computer-based image-analysis software. The AutoCAD calculation results determined the percentage of sealer, the gutta-percha, and the voids in surfaces (Fig. 2).

Statistical analysis

Statistical package for the social sciences (IBM SPSS, Version 23, USA) was used for data analysis. One-way analysis of variance (ANOVA) and Kruskal–Wallis Dunn’s tests were used to identify significant differences between the compared groups. P value less than 0.05 was considered significant.

RESULTS

The obtained stereomicroscopic and radiographic results have been summarized in Tables 1 and 2, respectively. In buccolingual view of radiographs, the WVC and EM groups showed significantly lower percentage of voids (P value<0.05) compared with that in the GF group. No significant differences were observed among other groups (P value>0.05). In mesiodistal view, the WVC and EM groups showed significantly lower per-

centage of voids (P value<0.05) compared to that in the GF and ES groups. In stereomicroscopic evaluation (Fig. 3), the WVC group displayed significantly higher percentage of gutta-percha than that in the other groups (P value<0.05). The amount of sealer in the WVC group was significantly less than that in the other groups (P value<0.05). The void among the groups did not show normal distribution. Therefore, Kruskal–Wallis Dunn’s tests were used to compare the void among the studied groups. The WVC and EM groups demonstrated significantly lower percentage of voids (P value<0.05) as compared to that in the GF and ES groups. No significant differences were observed between the WVC and EM groups (P value>0.05) or between the GF and ES groups (P value>0.05).

DISCUSSION

The anatomy of root canal system has diversity and some pathologic processes, such as IRR, makes it more complicated. Filling of IRR is a complex procedure that needs high degree of precision. Further research to identify suitable filling materials and obturating systems to completely fill the resorbed area is essential (20). This study shows that the WVC technique and single-cone technique with Endoseal MTA sealer have better quality with minimal void volume of AIRC. The middle third of the roots has been reported as the most prevalent area related to internal resorption lesion (21). In this study, simulated internal resorption cavities were located in this area. The radiographic method and stereomicroscope analysis were used to evaluate the filling quality through the percentage calculation of gutta-percha, sealer, and voids in artificial resorption cavity. Goldberg et al (22) reported limitations of the buccolingual radiographic views to detect the voids, and concluded that adding a mesiodistally directed radiographic view is more appropriate for this purpose. The comparative analysis in this study between the buccolingual and mesiodistal radiographs showed differences in 3 of the 40 samples. While the buccolingual view in each instance indicated the total filling of the IRR, the mesiodistal view displayed some voids in the same tooth

TABLE 1. Mean percentage values±SD of the filling materials and voids in the artificial internal resorption cavity

Variable Groups	Gutta-percha (Mean(%)±SD)	Sealer (Mean(%)±SD)	Void (Mean(%)±SD)
Warm vertical compaction	84.26±14.35	15.48±14.49	0.26±0.81
Guttaflow2	11.38±1.35	78.30±16.36	10.32±16.84
Endoseal MTA	9.98±2.01	89.09±4.15	0.93±2.94
EndoSequence BC	11.23±1.39	78.72±13.42	10.05±12.78

TABLE 2. Radiographic evaluation of root filling quality in the artificial internal resorption cavity

Groups	Sample	Total filling (BL)	Filling with void (BL)	Mean percentage of voids (BL)	Total filling (MD)	Filling with void (MD)	Mean percentage of voids (MD)
Warm vertical compaction	10	10	0	0%	10	0	0%
GuttaFlow2	10	6	4	6%	6	4	6.61%
Endoseal MTA	10	10	0	0%	9	1	0.36%
EndoSequence BC	10	7	3	2.78%	5	5	4.26%

BL: buccolingual view of radiographs, MD: mesiodistal view of radiographs

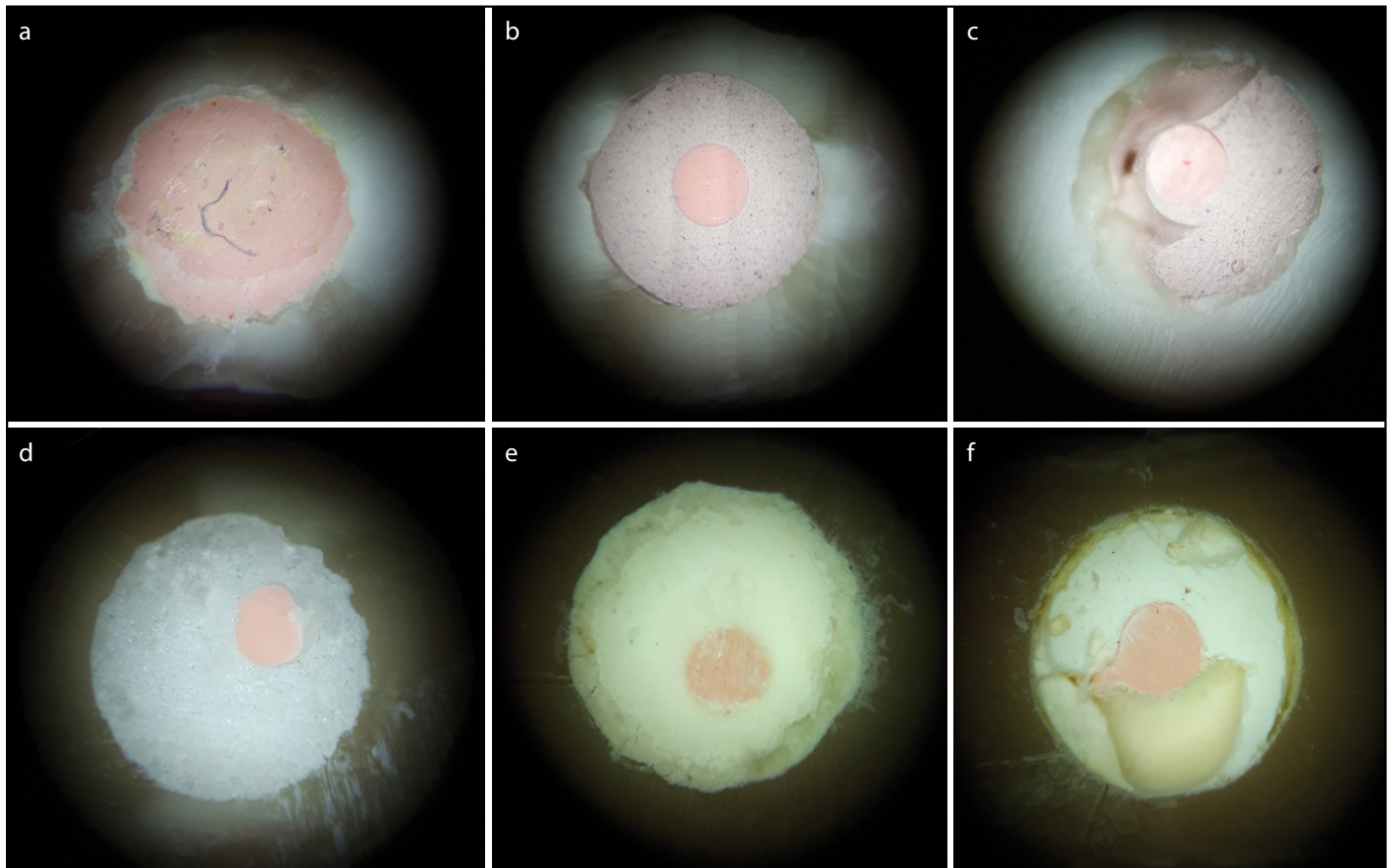


Figure 3. Stereo microscopic view of the internal resorption cavity obturated with (a) warm vertical compaction, (b) single-cone technique with Gutta Flow 2 (total filling), (c) single-cone technique with Gutta Flow 2 (filling with void), (d) single-cone technique with Endoseal MTA, (e) single cone technique with Endo Sequence BC sealer (total filling), (f) single-cone technique with Endo Sequence BC sealer (filling with void)

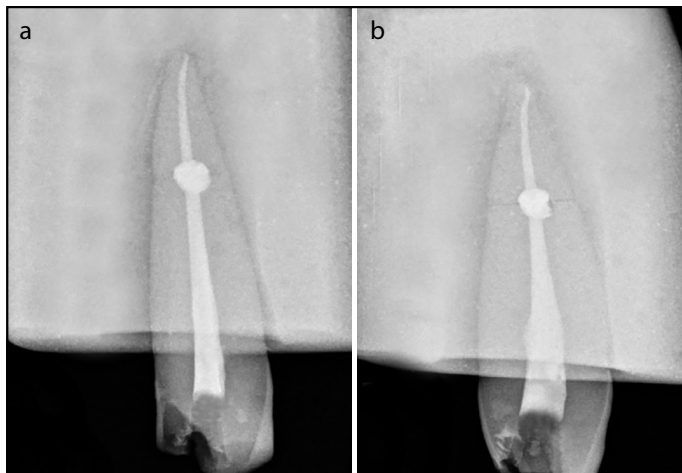


Figure 4. Single-cone technique with Endo seal MTA sealer: (a) buccolingual view of radiography showing complete filling, (b) mesiodistal view of same tooth showed filling with void

(Fig. 4). Our results corroborated the findings of the Goldberg study (22). As it is hard to evaluate voids and practically impossible to radiographically differentiate gutta-percha and sealer, the radiographic analysis is inadequate to estimate the root filling quality for internal resorption cavities (5). Since a radiograph is a two-dimensional image of a three-dimensional object, the exact extension of the root filling cannot be measured (23).

Most studies have confirmed the advantage of thermoplasticized gutta-percha injection techniques to achieve proper filling of IRR (5, 22). It is commonly accepted that root fillings should contain more gutta-percha and less sealer (1). Because root canal sealers have shrinkage during setting (24), they wash out and degrade to different degrees in the presence of moisture (25). The clinician must detect IRR, its extension, and presence of any perforation in the affected root canal walls, and then select the appropriate root filling materials and techniques. Therefore, the flowing and bioactivity of material have a great importance.

In this study, WVC was used as a gold standard technique. GuttaFlow2 was selected because of excellent flow, good adaptation to root canal walls (26) and its ability to expand on setting (27). EndoSequence BC sealer and Endoseal MTA are newly developed calcium-silicate-based sealers. The bioactivity of these materials makes them an attractive sealer type (8). The results of this study illustrated that single-cone technique with Endoseal MTA and WVC technique were comparable.

In the stereomicroscopic and radiographic analysis, the average percentage of existing voids was lower in the EM group compared with that in the GF and ES groups. This can be explained by different instructions, which manufacturers recommended. In GuttaFlow2, the canal is impregnated with sealer by master cone, master apical file or lentulo spiral without injection. EndoSequence BC sealer is injected into the coronal third of root

canal following the manufacturer instructions, while Endoseal MTA sealer is gradually injected into the canal from the apex toward the canal orifice. Furthermore, Endoseal MTA sealer application has a specific concept of ultrasonic vibration. The ultrasonic vibration creates higher sealer distribution degrees as well as lining efficacy (28), which improved canal filling in this study.

Many researchers have investigated different techniques and materials to introduce the best technique with excellent resorption defects filling capability. Keles et al (29) proposed vertical compaction technique as an optimum method for the AIRC filling that was significantly superior to lateral compaction and core carrier techniques such as Thermafil. Basavana et al (1) found that the thermoplasticized gutta-percha injection techniques by using Obtura II provided the best result for filling of simulated internal resorption lesions compared to system B, Thermafil, and lateral compaction techniques. Agarwal et al (23) reported that Thermafil and lateral compaction fillings were inferior compared to thermoplasticized gutta-percha injection fillings using Obtura II and ultrasonic compaction for filling of internal resorption cavities. Results of this study support findings of another investigation (30) which reported that single-cone technique with Endoseal MTA and ultrasonic activation performs well in filling root canal system. In a microCT study, Celikten et al (17) found that EndoSequence BC sealer generated similar void in comparison with AH Plus in filling oval root canal. The single-cone technique used in this study is known to be less operator-dependent, less harmful to the root canal dentin (19), potentially more conservative and faster than other root filling techniques (16).

As per discussion above, it appears that, single-cone technique with Endoseal MTA sealer is a promising filling material, which provides results similar to those of the WVC technique. For future development, it is proposed to conduct research about use of GuttaFlow2 and EndoSequence BC sealer in AIRC similar to the recommended instruction of Endoseal MTA manufacturer. Filling of IRR can be evaluated by other calcium-silicate-based sealer like Endoseal MTA.

CONCLUSION

Within the limitations of this ex vivo study, it can be concluded that WVC technique and single-cone technique with Endoseal MTA are the optimum methods to fill artificial resorption cavities. These techniques are significantly superior to single-cone technique with EndoSequence and GuttaFlow2.

Disclosures

Conflict of interest: The authors deny any conflicts of interest related to this study.

Ethics Committee Approval: We took Ethics Committee approval letter from Tehran University of medical science.

Financial Disclosure: The research costs is funded by Tehran University of medical science.

Authorship contributions: Concept – K.A.Y., M.A., P.A.; Design – M.A., P.A.; Supervision – K.A.Y., P.A.; Fundings - M.A., P.A.; Materials - K.A.Y., P.A.; Data collection &/or processing – K.A.Y., M.A., P.A.; Analysis and/or interpretation – P.A.; Literature search – P.A.; Writing – M.A., P.A.; Critical Review – P.A.

REFERENCES

- Basavanna R, Pendharkar K, Kumer D. Effectiveness of four different gutta percha techniques in filling experimental internal resorptive lesions-Anin vitro study. *Endodontology* 2014;26(1): 128–36.
- Patel S, Ford TP. Is the resorption external or internal? *Dent Update* 2007; 34(4):218–20, 222, 224–6, 229.
- Andreasen J. Review of root resorption systems and models, etiology of root resorption and the homeostatic mechanisms of the periodontalligament. In: Davidovitch D, editor. *The biological mechanisms of tooth resorption and root resorption*. Birmingham: EBSCO Media 1988:9–21.
- Frank AL, Weine FS. Nonsurgical therapy for the perforative defect of internal resorption. *J Am Dent Assoc* 1973; 87(4):863–8.
- Gencoglu N, Yildirim T, Garip Y, Karagenc B, Yilmaz H. Effectiveness of different gutta-percha techniques when filling experimental internal resorptive cavities. *Int Endod J* 2008; 41(10):836–42.
- Collins J, Walker MP, Kulild J, Lee C. A comparison of three gutta-percha obturation techniques to replicate canal irregularities. *J Endod* 2006;32(8):762–5.
- Mohammad Y, Alafif H, Hajeer MY, Yassin O. An Evaluation of GuttaFlow2 in Filling Artificial Internal Resorption Cavities: An in vitro Study. *J Contemp Dent Pract* 2016; 17(6):445–50.
- Parirokh M, Torabinejad M. Mineral trioxide aggregate: a comprehensive literature review-Part III: Clinical applications, drawbacks, and mechanism of action. *J Endod* 2010; 36(3):400–13.
- Parirokh M, Torabinejad M. Mineral trioxide aggregate: a comprehensive literature review-Part I: chemical, physical, and antibacterial properties. *J Endod* 2010; 36(1):16–27.
- Yoo YJ, Baek SH, Kum KY, Shon WJ, Woo KM, Lee W. Dynamic intratubular biomineralization following root canal obturation with pozzolan-based mineral trioxide aggregate sealer cement. *Scanning* 2016; 38(1):50–6.
- Saghiri MA, Asgar K, Lotfi M, Karamifar K, Neelakantan P, Ricci JL. Application of mercury intrusion porosimetry for studying the porosity of mineral trioxide aggregate at two different pH. *Acta Odontol Scand* 2012; 70(1):78–82.
- Camilleri J, Gandolfi MG, Siboni F, Prati C. Dynamic sealing ability of MTA root canal sealer. *Int Endod J* 2011; 44(1):9–20.
- Lovato KF, Sedgley CM. Antibacterial activity of endosequence root repair material and proroct MTA against clinical isolates of *Enterococcus faecalis*. *J Endod* 2011; 37(11):1542–6.
- BrasselerUSA. EndoSequence BC sealer instructions for use. Available at: www.BrasselerUSA.com. Accessed Nov 12, 2008.
- Cavenago BC, Duarte MA, Ordinola-Zapata R, Marciano MA, Carpio-Perochena AE, Bramante CM. Interfacial adaptation of an epoxy-resin sealer and a self-etch sealer to root canal dentin using the System B or the single cone technique. *Braz Dent J* 2012; 23(3):205–11.
- Tasdemir T, Yesilyurt C, Ceyhanli KT, Celik D, Er K. Evaluation of apical filling after root canal filling by 2 different techniques. *J Can Dent Assoc* 2009; 75(3):201a–201d.
- Celikten B, Uzuntas CF, Orhan AI, Orhan K, Tufenkci P, Kursun S, et al. Evaluation of root canal sealer filling quality using a single-cone technique in oval shaped canals: An In vitro Micro-CT study. *Scanning* 2016; 38(2):133–40.
- Topçuoğlu HS, Tuncay Ö, Karataş E, Arslan H, Yeter K. In vitro fracture resistance of roots obturated with epoxy resin-based, mineral trioxide aggregate-based, and bioceramic root canal sealers. *J Endod* 2013;39(12):1630–3.
- Deniz Sungur D, Moinszadeh AT, Wesselink PR, Çalt Tarhan S, Özok AR. Sealing efficacy of a single-cone root filling after post space preparation. *Clin Oral Investig* 2016; 20(5):1071–7.
- Calışkan MK, Türkün M. Prognosis of permanent teeth with internal resorption: a clinical review. *Endod Dent Traumatol* 1997; 13(2):75–81.
- Trope M, Chivian N. Root resorption. In: *Pathways of the pulp*. 6th ed. St. Louis: Mosby; 1994. p. 493–503.
- Goldberg F, Massone EJ, Esmoris M, Alfie D. Comparison of different techniques for obturating experimental internal resorptive cavities. *Endod Dent Traumatol* 2000; 16(3):116–21.
- Agarwal M, Rajkumar K, Lakshminarayanan L. Obturation of internal resorption cavities with 4 different techniques: An in-vitro comparative study. *Endodontology* 2002; 14:3–8.
- Kazemi RB, Safavi KE, Spångberg LS. Dimensional changes of endodontic sealers. *Oral Surg Oral Med Oral Pathol* 1993; 76(6):766–71.

25. McMichen FR, Pearson G, Rahbaran S, Gulabivala K. A comparative study of selected physical properties of five root-canal sealers. *Int Endod J* 2003; 36(9):629–35.
26. Zielinski TM, Baumgartner JC, Marshall JG. An evaluation of Guttaflow and gutta-percha in the filling of lateral grooves and depressions. *J Endod* 2008; 34(3):295–8.
27. Ørstavik D, Nordahl I, Tibballs JE Dimensional change following setting of root canal sealer materials. *Dent Mater* 2001; 17(6):512–9.
28. Hwang JH, Chung J, Na HS, Park E, Kwak S, Kim HC. Comparison of bacterial leakage resistance of various root canal filling materials and methods: Confocal laser-scanning microscope study. *Scanning* 2015; 37(6):422–8.
29. Keles A, Ahmetoglu F, Uzun I. Quality of different gutta-percha techniques when filling experimental internal resorptive cavities: a micro-computed tomography study. *Aust Endod J* 2014; 40(3):131–5.
30. Kim JA, Hwang YC, Rosa V, Yu MK, Lee KW, Min KS. Root Canal Filling Quality of a Premixed Calcium Silicate Endodontic Sealer Applied Using Gutta-percha Cone-mediated Ultrasonic Activation. *J Endod* 2018; 44(1):133–8.