



# Peripartum Abdominal Compartment Syndrome Following Extracorporeal Hemodynamic Support

Violetta Lozovyy, MD<sup>1</sup> Fawzi Saoud, MD<sup>1</sup> Luis D. Pacheco, MD<sup>1,2</sup>

<sup>1</sup>Division of Maternal-Fetal Medicine, Department of Obstetrics and Gynecology, The University of Texas Medical Branch, Galveston, Texas

<sup>2</sup>Division of Surgical Critical Care, Department of Anesthesiology, The University of Texas Medical Branch, Galveston, Texas

**Address for correspondence** Luis D. Pacheco, MD, Division of Maternal-Fetal Medicine, Department of Obstetrics and Gynecology, The University of Texas Medical Branch, 301 University Boulevard, Galveston, TX 77555-0587 (e-mail: ldpachec@utmb.edu).

AJP Rep 2024;14:e19–e21.

## Abstract

In massive pulmonary embolism (PE), anticoagulation and thrombolytics may increase the risk of retroperitoneal bleeding following vascular cannulation for extracorporeal hemodynamic support resulting in abdominal compartment syndrome (ACS). A 27-year-old women at 33 weeks of gestation presented with acute chest pain and shortness of breath. Massive PE was diagnosed. Intravenous unfractionated heparin was started together with catheter-directed tissue plasminogen activator (tPA) infusion and mechanical thrombectomy. During the procedure, cardiac arrest developed. Cardiopulmonary resuscitation, intravenous tPA, and urgent perimortem cesarean delivery were performed. After return of spontaneous circulation, profound right ventricular failure required venoarterial membrane oxygenation. Six hours afterward, ACS secondary to retroperitoneal bleeding developed, requiring surgical intervention. ACS may result from retroperitoneal bleeding following cannulation for extracorporeal hemodynamic support.

## Keywords

- ▶ C-section
- ▶ complications
- ▶ pulmonary embolism
- ▶ ECMO

The risk of venous thromboembolism (VTE) during pregnancy is increased fivefold compared with nonpregnant individuals<sup>1</sup> The overall incidence of VTE is approximately 0.5 to 2.0 per 1,000 pregnancies, and it is responsible for 9.2% of pregnancy-related deaths in the United States.<sup>2</sup>

Most pulmonary embolisms (PEs) originate from clots in the pelvic veins. The term “massive” PE refers to cases complicated by systemic hypotension (commonly defined as a systolic blood pressure below 90 mm Hg).<sup>3</sup> Hemodynamic instability develops due to acute onset of right ventricular failure/dilation

with subsequent left-sided displacement of the interventricular septum resulting in left ventricular compression and decreased cardiac output. Massive PE mandates immediate administration of thrombolytic agents, such as tissue plasminogen activator (tPA).<sup>3</sup>

Severe refractory right ventricular failure following PE may require transient hemodynamic support with venoarterial extracorporeal membrane oxygenation (VA-ECMO). Vascular cannulation in the setting of anticoagulation and recent use of thrombolytic agents may result in severe bleeding complications.

received  
December 9, 2020  
accepted  
October 22, 2023

DOI <https://doi.org/10.1055/s-0043-1777997>.  
ISSN 2157-6998.

© 2024. The Author(s).

This is an open access article published by Thieme under the terms of the Creative Commons Attribution-NonDerivative-NonCommercial-License, permitting copying and reproduction so long as the original work is given appropriate credit. Contents may not be used for commercial purposes, or adapted, remixed, transformed or built upon. (<https://creativecommons.org/licenses/by-nc-nd/4.0/>)

Thieme Medical Publishers, Inc., 333 Seventh Avenue, 18th Floor, New York, NY 10001, USA

## Case

A 26-year-old woman was transferred to our center with a 33-week pregnancy complicated by intrauterine fetal demise and a massive PE diagnosed with computed tomography angiography at the referral center.

Upon arrival, the patient was hemodynamically unstable with an arterial blood pressure of 80/40 mm Hg, heart rate 130 beats per minute, respiratory rate 30 per minute, and an arterial hemoglobin saturation of 90% while breathing oxygen at 10 L/minute via non-rebreather face mask. Initial laboratory examinations were remarkable for a hemoglobin 12.8 g/dL, arterial pH 7.23, partial pressure of carbon dioxide 19 mm Hg, and a partial pressure of arterial oxygen of 154 mm Hg. Serum troponin I was elevated at 2.650 ng/mL. A point-of-care transthoracic echocardiography (TTE) revealed signs of a massively dilated right ventricle, with left-sided displacement of the interventricular septum resulting in a D-shaped collapsed left ventricle (►Fig. 1).

Intravenous unfractionated heparin (UFH) was started, and the interventional radiology team was consulted for immediate percutaneous catheter-directed tPA administration and mechanical thrombectomy. During the procedure, left uterine displacement was maintained, and a norepinephrine infusion was started to maintain a mean arterial blood pressure above 60 mm Hg. After central vascular access was obtained, an initial tPA bolus of 4 mg was infused directly into the main pulmonary artery followed by thrombectomy of a right-sided proximal pulmonary artery clot. The patient was given a second 50-mg tPA dose into her main pulmonary artery. Shortly after, the patient developed pulseless electrical activity requiring immediate cardiopulmonary resuscitation (CPR) followed by a perimortem cesarean delivery. Return of spontaneous circulation was achieved after 20 minutes of CPR and administration of 100 mg of systemic tPA. Repeat bedside TTE revealed global hypokinesis of the right ventricle despite administration of vasopressors and inotropes. A decision was made to start peripheral VA-ECMO utilizing the femoral approach. After hemodynamic stabilization, the patient was transferred to the surgical intensive

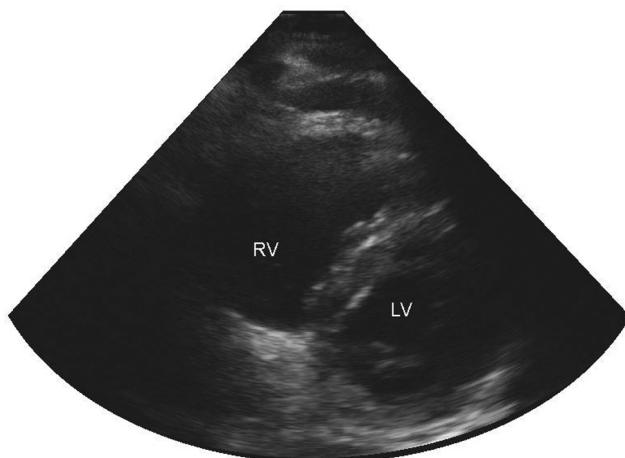
care unit (SICU). Anticoagulation with UFH was continued. A few hours after admission, abdominal distention was noted with new-onset oliguria and elevated airway peak pressures on the ventilator, all concerning for abdominal compartment syndrome (ACS). The intravesical pressure measurement was elevated at 27 mm Hg. The hemoglobin level had decreased to 7.5 g/dL. A bedside laparotomy was performed in the SICU. Uterine tone was normal, and some mild oozing was noted in the hysterotomy. The spleen and liver were unremarkable. The retroperitoneum was noted to be full of blood, displacing the abdominal organs anteriorly. Expectant management was decided, the fascia was left open, and the abdominal wall was closed with the use of a vacuum device. Medical management included transfusion of packed red cells, platelets, fresh frozen plasma, and cryoprecipitate as indicated. VA-ECMO was continued without anticoagulation for 24 hours. UFH was then restarted without any complications. The fascia was closed 48 hours later after weaning of VA-ECMO. The retroperitoneal hematoma was noted to have decreased significantly in size, allowing closure of the fascia. The patient was successfully extubated and discharged with no neurologic sequelae.

## Comment

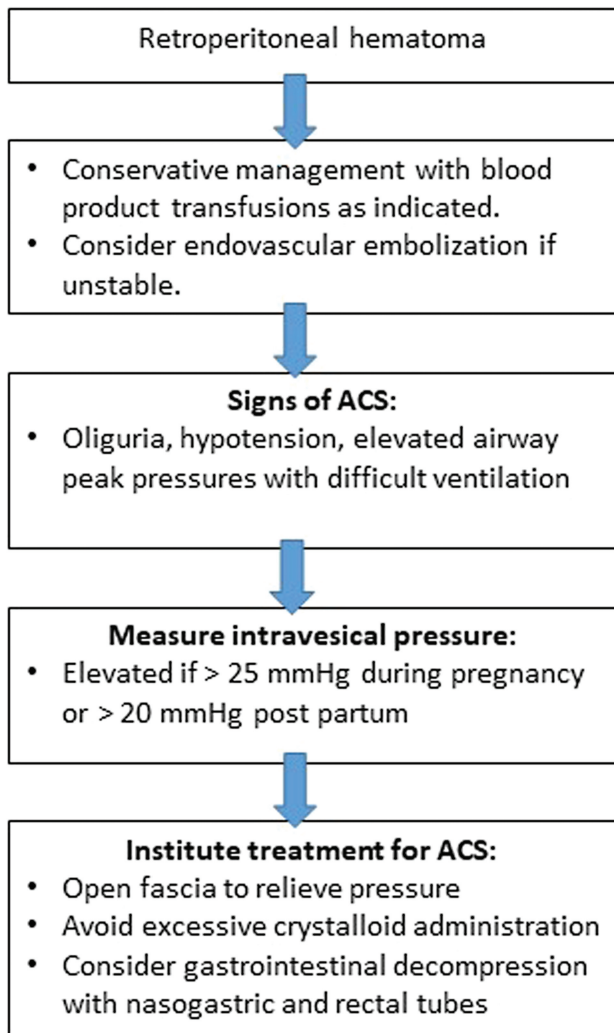
Massive PE requires immediate administration of thrombolytic therapy (usually tPA) to allow for fast clot lysis with a subsequent decrease in right ventricular afterload. Current guidelines recommend the use of systemic tPA given through a peripheral intravenous line at a dose of 100 mg over 2 hours.<sup>3</sup> By the time tPA is administered, most patients will be receiving concomitant therapeutic intravenous UFH. Importantly, administration of tPA should not be delayed waiting for availability of percutaneous catheter-directed thrombolysis/thrombus removal, as this may result in significant delays leading to irreversible right ventricular failure. In the present case, due to the immediate availability of this intervention in our center, it was decided to proceed with percutaneous clot removal. In selected cases, where there is an absolute contraindication for systemic tPA (e.g., recent central nervous system bleeding) or if no improvement is evident after systemic administration, thrombus removal (with either a percutaneous approach or, rarely, an open surgical technique) may be considered as an adjuvant intervention.<sup>3</sup>

If PE-induced right ventricular failure is severe and persists despite the use of thrombolytic therapy, hemodynamic support with VA-ECMO may be required.<sup>4</sup> As the vast majority of these patients will be receiving both anticoagulation and thrombolytics at the time of femoral cannulation for ECMO access, the risk of retroperitoneal bleeding is significant.<sup>3</sup>

Retroperitoneal hematomas may be secondary to cannulation/laceration of femoral vessels and blunt or penetrating trauma. Similarly, bleeding into the retroperitoneal area may be a complication of surgical procedures (including cesarean sections and perineal lacerations) or may occur spontaneously among anticoagulated individuals.<sup>5</sup> In most cases, conservative



**Fig. 1** Transthoracic echocardiogram showing short axis view with a massively dilated right ventricle.



**Fig. 2** Management of abdominal compartment syndrome (ACS) secondary to retroperitoneal hematoma.

management is preferred with transfusion of blood products as indicated to correct any underlying coagulopathy. In unstable patients, percutaneous vascular embolization may be required to control bleeding.<sup>6</sup> Expectant management will invariably result in accumulation of blood in the retroperitoneal space, with a potential risk of developing ACS. In our case, anterior displacement of the posterior peritoneum resulted in increased intra-abdominal pressures. In nonpregnant individuals, ACS is defined as an intravesical pressure (surrogate of intra-abdominal pressure) more than 20 mm Hg with evidence of organ dysfunction.<sup>7</sup> The latter may include acute kidney injury from renal hypoperfusion due to renal vein compression, respiratory failure due to decreased functional residual capacity secondary to cephalad displacement of the diaphragm, and systemic

hypotension as a consequence of decreased preload and cardiac output (from inferior vena cava compression). During pregnancy and the immediate postpartum period, ACS may be suspected if the measured intra-abdominal pressures are above 25 and 20 mm Hg, respectively.<sup>8</sup>

In the present case, at the time of bedside laparotomy for suspected ACS, the intra-abdominal findings did not explain the elevated intra-abdominal pressures recorded; the retroperitoneal findings did. Regardless of the etiology, definite management of ACS consists of surgical opening of the fascia to relieve intra-abdominal pressure, allowing for improved preload and cardiac output. Similarly, the decrease in abdominal pressure will allow the diaphragm to descend during inspiration, improving the respiratory status. Clinicians should be aware that concealed retroperitoneal bleeding may result in increased intra-abdominal pressure and ACS. ►**Fig. 2** summarizes the management of ACS in the setting of a retroperitoneal hematoma.

#### Funding

None.

#### Conflict of Interest

None declared.

#### References

- Bennett A, Chunilal S. Diagnosis and management of deep vein thrombosis and pulmonary embolism in pregnancy. *Semin Thromb Hemost* 2016;42(07):760–773
- ACOG Practice Bulletin No. 196: thromboembolism in pregnancy. *Obstet Gynecol* 2018;132(01):e1–e17
- Kucher N, Rossi E, De Rosa M, Goldhaber SZ. Massive pulmonary embolism. *Circulation* 2006;113(04):577–582
- Pacheco LD, Saade GR, Hankins GDV. Extracorporeal membrane oxygenation (ECMO) during pregnancy and postpartum. *Semin Perinatol* 2018;42(01):21–25
- Daliakopoulos SI, Bairaktaris A, Papadimitriou D, Pappas P. Giant retroperitoneal hematoma as a complication of anticoagulation therapy with heparin in therapeutic doses: a case report. *J Med Case Rep* 2008;2:162
- Chan YC, Morales JP, Reidy JF, Taylor PR. Management of spontaneous and iatrogenic retroperitoneal haemorrhage: conservative management, endovascular intervention or open surgery? *Int J Clin Pract* 2008;62(10):1604–1613
- Kirkpatrick AW, Roberts DJ, De Waele J, et al; Pediatric Guidelines Sub-Committee for the World Society of the Abdominal Compartment Syndrome. Intra-abdominal hypertension and the abdominal compartment syndrome: updated consensus definitions and clinical practice guidelines from the World Society of the Abdominal Compartment Syndrome. *Intensive Care Med* 2013;39(07):1190–1206
- Lozada MJ, Goyal V, Levin D, et al. Management of peripartum intra-abdominal hypertension and abdominal compartment syndrome. *Acta Obstet Gynecol Scand* 2019;98(11):1386–1397