

## Feasibility of patency capsule and colon capsule endoscopy in patients with suspected gastrointestinal stenosis: a prospective study

Hiroyuki Otsuka<sup>1</sup>, Masanao Nakamura<sup>1</sup>, Takeshi Yamamura<sup>1</sup>, Keiko Maeda<sup>2</sup>, Tsunaki Sawada<sup>2</sup>,  
Yasuyuki Mizutani<sup>1</sup>, Eri Ishikawa<sup>1</sup>, Takuya Ishikawa<sup>1</sup>, Naomi Kakushima<sup>1</sup>, Kazuhiro Furukawa<sup>1</sup>,  
Eizaburo Ohno<sup>1</sup>, Hiroki Kawashima<sup>2</sup>, Takashi Honda<sup>1</sup>, Masatoshi Ishigami<sup>1</sup>  
and Mitsuhiro Fujishiro<sup>1</sup>

<sup>1</sup>*Department of Gastroenterology and Hepatology, Nagoya University Graduate School of Medicine,  
Nagoya, Japan*

<sup>2</sup>*Department of Endoscopy, Nagoya University Hospital, Nagoya, Japan*

### ABSTRACT

Patency capsule (PC) can evaluate the patency of gastrointestinal (GI) tract. We hypothesized preceding patient selection using PC would improve the successful rate of colon capsule endoscopy (CCE). Therefore, a prospective single-arm study using PC followed by CCE was conducted with a control group of CCE alone. Patients with suspected or known GI stenosis scheduled for CCE were enrolled. CCE was performed only when the PC was excreted out of the body within 33 hours of ingestion. Primary endpoint was the rate of observation of the entire GI tract within the duration of examination. The secondary endpoints were complications and CCE findings. Twenty-three patients (17 men) were enrolled. The mean age was 50.5±19.8 years. Suspected stenotic sites were 8, 5, and 10 in the small, large, and small and large bowel, respectively. Sixteen, 12, and 10 patients had abdominal pain, active inflammatory bowel disease, and history of surgery for suspected stenosis, respectively. Patency of GI tract was confirmed in 96% (22/23) of the patients by administered PC. Of the 22 patients who underwent CCE, the entire GI tract was observed in 86% (19/22). No complications were observed. The median transit times in the small bowel and colon were 99 (21–682) and 160 (5–328) minutes, respectively. CCE findings revealed ulcers, erosions, and diverticula in 5, 9, and 4 patients, respectively. In conclusion, CCE with PC might be a safer and useful modality to observe the large colon for patients with suspected GI stenosis.

Keywords: colon capsule endoscopy, stenosis, retention, Crohn's disease

#### Abbreviations:

SBCE: small bowel capsule endoscopy

CCE: colon capsule endoscopy

GI: gastrointestinal

PC: patency capsule

CD: Crohn's disease

AFR: adaptive frame rate function

PEG: polyethylene glycol

NSAIDs: non-steroidal anti-inflammatory drugs

Received: September 3, 2020; accepted: November 19, 2020

Corresponding Author: Masanao Nakamura, MD, PhD

Department of Gastroenterology and Hepatology, Nagoya University Graduate School of Medicine, 65

Tsurumai-cho, Showa-ku, Nagoya 466-8550, Japan

Tel: +81-52-744-2172, Fax: +81-52-744-2180, E-mail: makamura@med.nagoya-u.ac.jp

This is an Open Access article distributed under the Creative Commons Attribution-NonCommercial-NoDerivatives 4.0 International License. To view the details of this license, please visit (<http://creativecommons.org/licenses/by-nc-nd/4.0/>).

## INTRODUCTION

With the advent of small bowel capsule endoscopy (SBCE) in 2000, there has been a dramatic change and advancement in the management of the small bowel diseases. Currently, colon capsule endoscopy (CCE) is also available in Japan.<sup>1</sup> The most common complication of SBCE and CCE is the retention of the capsule in strictures at the oral end of the gastrointestinal (GI) tract for up to 2 weeks. To avoid the retention of the SBCE capsule, a patency capsule (PC), which is of the same size as the capsule endoscope and collapses in the GI tract within 100 to 200 hours, was introduced in Japan in July 2012. In cases where the patency of the entire GI tract is confirmed by ingestion of the PC, subsequent SBCE can be safely performed. With the introduction of PC, SBCE can be performed in patients with GI stenosis such as patients with Crohn's disease (CD) and those who have undergone abdominal radiotherapy.<sup>2-4</sup> Previously, these conditions were contraindications for SBCE.

CCE is one of the most valuable tools for investigating the entire colon, although colonoscopy is still the gold standard. The rate of observation of the entire colorectum on CCE has been reported to be 70–100%, which is comparable with that of colonoscopy. CCE is expected to become increasingly popular and further develop in the future.<sup>5</sup> In CCE, it is possible to observe the entire GI tract, including the small bowel, using the adaptive frame rate function (AFR), by which the capture image rate changes from 4 to 35 frames per second when the system determines that the capsule is moving more quickly.<sup>6</sup> However, CCE also has the potential risk of capsule retention in any part of the GI tract, and there is no other device to check the patency of the GI tract. In this prospective study, we examined the feasibility of PC to predict the possible retention of CCE in patients with suspected or known GI stenosis.

## METHODS

### *Patients*

Patients were recruited from February 2016 to April 2018. The inclusion criteria were: patients who were aged 18 years and above, and wished to undergo CCE despite suspected GI stenosis. The exclusion criteria were as follows: history of hypersensitivity to any medicines used for bowel preparation, swallowing disorder, implantation of cardiac pacemaker or an electro-medical device, suspected acute abdomen, and severe constipation. The study protocol was approved by the local ethics committee (Nagoya University Hospital ethic committee ID 2015-372), registered at UMIN-CTR (UMIN000019632) and written informed consent was obtained from all patients who met the inclusion criteria and agreed to participate in the study.

### *Methods*

Details of the PC plus CCE regimen are shown in Table 1. Patients were administered 24 mg of sennoside and PC before bedtime, two days before the examination. Bowel preparation was initiated from breakfast on the day before the examination. Patients had low residue meals at breakfast, lunch, and dinner and took 50 g of magnesium citrate, 180 ml of water, and 24 mg of sennoside before going to bed. Patients drank 500 ml of MOVIPREP™, which is a polyethylene glycol (PEG) solution plus ascorbic acid, and 250 ml of water at 8:30 am on the day of the CCE examination. All patients swallowed the capsule after 1 hour at 9:30 am in the AFR mode. The

patients drank 30 ml of castor oil with 100 ml of water as the 1<sup>st</sup> boost, 1500 ml of PEG with 1500 ml of water as the 2<sup>nd</sup> boost, 30 ml of castor oil with 100 ml of water as the 3<sup>rd</sup> boost, and 50 g magnesium citrate with 900 ml of water as the 4<sup>th</sup> boost.<sup>7,8</sup> This regimen is currently one of the standard regimens in Japan because sodium phosphate is not available in Japan and MOVIPREPTM is used as the main booster.<sup>9-11</sup>

**Table 1** Regimen of patency capsule and colon capsule endoscopy

Day 0	Bedtime	24 mg Sennosides, <b>PC ingestion</b>
Day 1	(Each meal)	Low fiber diets
	PM 7–10	50 g magnesium citrate, 180 ml water and 24 mg Sennoside
Day 2	AM 8:00	(checking the PC excretion)
	AM 8:30	500 ml MOVIPREP * and 250 ml water
	AM 9:30	<b>CCE ingestion</b> , adapted framed rate started at the same time
	1 <sup>st</sup> booster	30 ml castor oil and 100 ml water
	2 <sup>nd</sup> booster	1500 ml MOVIPREP * and 1500 ml water
	3 <sup>rd</sup> booster	30 ml castor oil and 100 ml water
	4 <sup>th</sup> booster	50 g magnesium citrate, 900 ml water

PC: PillCam patency capsule

CCE: colon capsule endoscopy

\* PEG solution plus ascorbic acid (MOVIPREP®, EA Pharma Co., Ltd, Tokyo, Japan)

The CCE, PillCam COLON 2 capsule (GIVEN Imaging, Ltd., Yokneam, Israel), is a minimally invasive technology that does not require sedation or intubation.<sup>12,13</sup> The capsule measures 31.5 × 11.6 mm and has a camera at each end. Each camera can obtain two images per second. Similar to the SBCE, the PillCam COLON 2 capsule transmits captured images to an external data recorder that later downloads the data to the RAPID 8 (GIVEN Imaging, Ltd., Yokneam, Israel) workstation.

PC, PillCam patency capsule (GIVEN Imaging, Ltd., Yokneam, Israel), is a self-dissolving dummy capsule with exactly the same size as that of SBCE and of the similar size as that of CCE. The capsule is primarily composed of barium sulphate and lactose anhydrous. When a patient swallows the PC, it advances through the GI tract by peristaltic movement. When there is no severe stenosis to trap the PC in the GI tract, it is naturally excreted in the feces. Thirty hours after ingestion of the PC, a built-in timer opens two small holes on the capsule's surface. The digestive juice enters the capsule and starts dissolving it, which is useful to test the possibility of retention of the real capsule endoscope without complications. The longest diameter of the PC (26.0 mm) is shorter than that of the CCE (31.5 mm); however, the shortest diameter of PC (11.0 mm) is nearly equal to that of the CCE (11.6 mm).

In accordance with a previous study, we used “excellent/good/fair/poor” to categorize the colon cleansing level. “Excellent/good” levels were considered as adequate, and “fair/poor” as inadequate. We evaluated the colon cleansing level in four segments: right colon (cecum, ascending colon), transverse colon, left colon (descending colon, sigmoid colon), and rectum.<sup>13,14</sup>

### *Evaluation*

Results of the PC and CCE procedures, including the duration of each procedure, were

recorded. Regular CCEs in clinical practice conducted during the same period as that of this study were reviewed. Examination results between the regular CCE and PC plus CCE were retrospectively compared. The primary endpoint was the total GI tract observation rate within the duration of examination in cases with confirmed patency of the GI tract. The secondary endpoints were the complications of the procedures and CCE findings.

#### Statistical analysis

All data were analyzed using the SPSS version 24.0 statistical software (IBM, Tokyo, Japan). Mann-Whitney *U* test and Pearson's Chi-square test were used for comparisons of the patients' background between the regular CCE and PC plus CCE groups. Mann-Whitney *U* test, Pearson's Chi-square test and Fisher's exact test were used for comparisons of the results between the regular CCE and PC plus CCE groups. Differences with values of  $p < 0.05$  were considered statistically significant.

## RESULTS

#### PC plus CCE results

The flowchart of the study design is shown in Fig. 1. In all, 23 patients were registered in the study (Tables 2, 3), and the confirmation rate of the patency of GI tract was 96% (22/23) by PC examination. One patient with CD did not excrete the PC within 33 hours from ingestion because of stenosis in the ascending colon (Fig. 2). The rate of complete examination with the CCE was 86% (19/22). Three patients did not expel the capsule within the duration of the battery life. CCE findings revealed ulcers, erosions, and diverticula in 5, 9, and 4 patients, respectively (Fig. 3, 4, Table 4).




Fig. 1 Flowchart of the study



**Table 2** Patient characteristics

PC plus CCE performed	n=23
Age, mean $\pm$ SD (years)	50.5 $\pm$ 19.8
Male/female	17/6
BMI (%)	20.6 $\pm$ 3.4
Constipation (%)	2 (8.6)
Use of laxative (%)	2 (8.6)
Previous abdominal surgery (%)	10 (43.4)
Abdominal symptoms (%)	16 (69.5)
Diabetes (%)	5 (21.7)

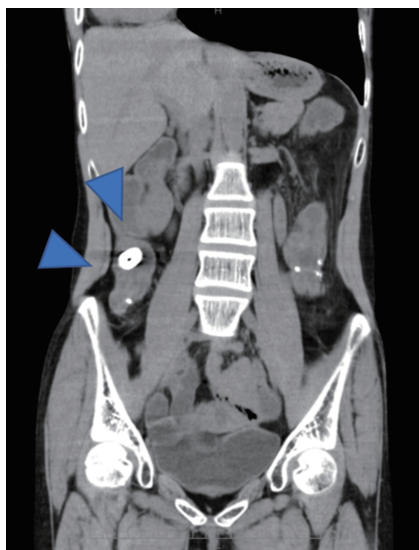
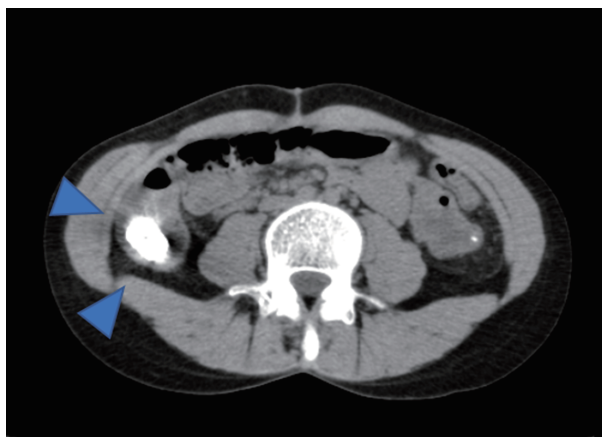
BMI: body mass index

**Table 3** Reason for using PC in the patients

Suspected stenotic part	n=23	Details
Small bowel	8	2 with stenotic symptoms, 1 amyloidosis, 1 radiation enteritis, 1 intestinal tuberculosis, 1 long-term user of NSAIDs, 1 lupus enteritis, 1 previous small bowel obstruction
Colon	5	2 sigmoid diverticulum, 2 ulcerative colitis, 1 severe constipation
Small bowel and colon	10	10 Crohn's disease

PC: patency capsule

NSAIDs: non-steroidal anti-inflammatory drugs

**Fig. 2a****Fig. 2b**

**Fig. 2** Patency capsule was retained at the oral side of the stenosis in the ascending colon due to Crohn's disease

**Fig. 2a:** Coronal image on plain CT.

**Fig. 2b:** Axial image on plain CT.

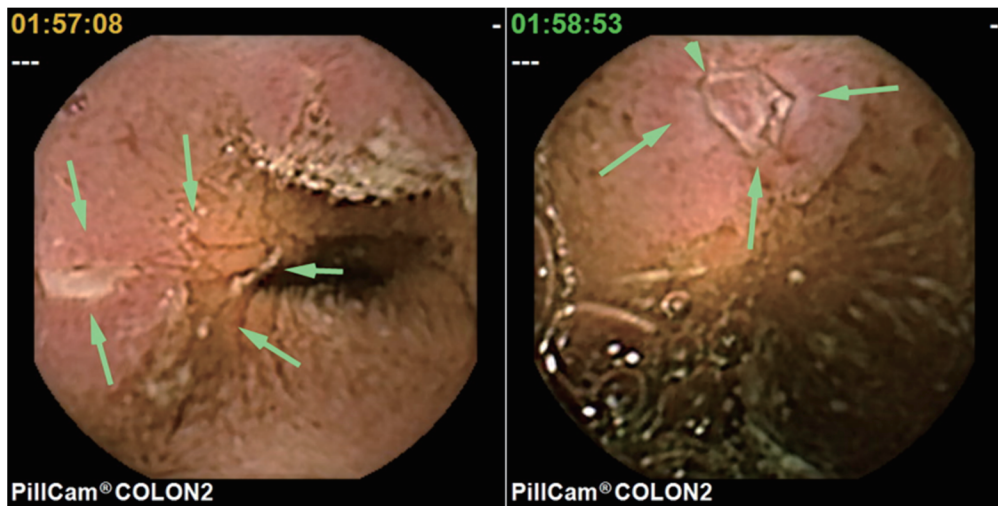


Fig. 3a

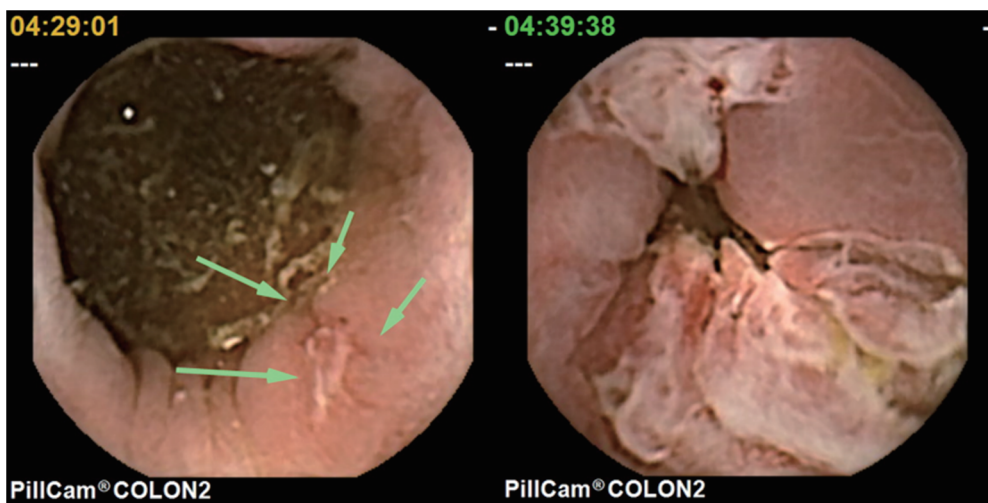


Fig. 3b

**Fig. 3** A patient of Crohn's disease with anal pain and suspected anal stenosis (patency capsule was excreted out of the body)

**Fig. 3a:** Colon capsule endoscopy revealed ulcers in the small bowel and large bowel.

**Fig. 3b:** A couple of longitudinal ulcers were detected from the rectum to the anal canal.

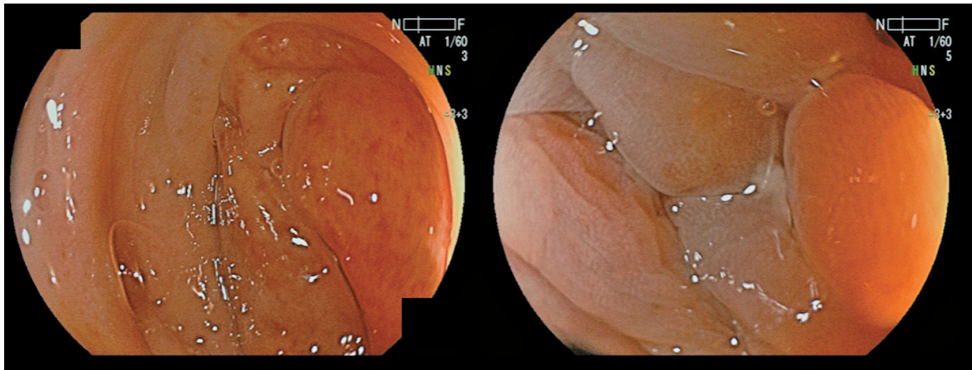


Fig. 4a

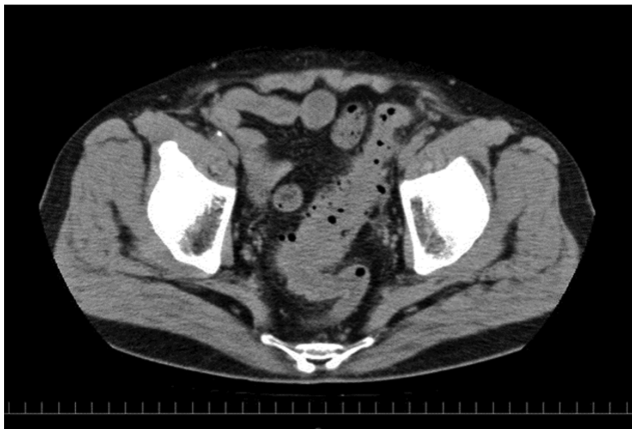


Fig. 4b

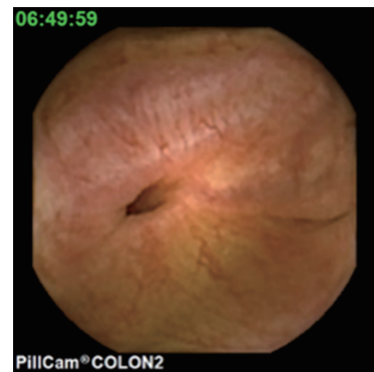

Fig. 4c

**Fig. 4** A patient with wall thickness in the sigmoid colon

**Fig. 4a:** Since a sigmoid colon tumor was suspected, colonoscopy was attempted. However, it could not be inserted into the target area due to the narrow lumen.

**Fig. 4b:** Plain CT scan revealed the wall thickness and multiple diverticula in the sigmoid colon.

**Fig. 4c:** Patency capsule was excreted out of the body. Colon capsule endoscopy revealed the diverticula and absence of tumor.

**Table 4** CCE results

	PC and CCE <i>n</i> =22
<b>Procedure</b>	
Number of excreted CCE (%)	19 (86.3)
Gastric transit time, median (min)	18 (4–186)
Small bowel transit time, median (min)	99 (21–682)
Colorectal transit time, median (min)	160 (5–328)
right-side colon transit time, median (min)	17 (1–341)
transverse colon transit time, median (min)	4 (1–85)
left-side colon transit time, median (min)	57.5 (1–313)
Total transit time, median (min)	345 (158–1037)
<b>Findings (no. of patients)</b>	
Diverticulum	4
Erosion	9
Ulcer	5
<b>Adverse events</b>	
CCE retention	0
Swallow disorder	0

CCE: colon capsule endoscopy

PC: patency capsule

#### *Comparison between the outcomes with Regular CCE and PC plus CCE*

Regular CCE was performed in 52 patients during the same period (Table 5). Comparisons of the procedures between the regular CCE and PC plus CCE groups revealed no significant differences in the capsule discharge rate and duration until discharge. The median colorectal transit time in the regular CCE and PC plus CCE groups was 87 and 160 minutes, respectively; however, the difference was not statistically significant (Table 6). The median transit time in the small intestine showed a significant difference between the regular CCE and PC plus CCE groups (58 vs. 99 minutes,  $p=0.004$ ). Bowel cleansing was adequate (excellent/good) in 82% of the patients in the PC and CCE group (Fig. 5). Adequate patients showed decrease in the left side of colon and rectum in both groups.

**Table 5** Comparison of patients' backgrounds between regular CCE and PC plus CCE groups

N	CCE 52	PC plus CCE 23	p-value
Age, mean $\pm$ SD (years)	54.1 $\pm$ 16.8	50.5 $\pm$ 19.8	*0.331
Male/female	32 / 20	17 / 6	**0.436
BMI (%)	23.5 $\pm$ 3.5	20.6 $\pm$ 3.4	*0.004
Constipation (%)	7 (13.4)	2 (8.6)	**0.713
Use of laxative (%)	5 (9.6)	2 (8.6)	**0.999
Previous abdominal surgery (%)	17 (32.6)	10 (43.4)	**0.522
Abdominal symptoms (%)	15 (28.8)	16 (69.5)	**0.002
Diabetes (%)	2 (3.8)	5 (21.7)	**0.025
Indications			
activity of IBD	21	12	
hematochezia	3	3	
abdominal pain	5	3	
bowel movement disorder	4	3	
follow-up post polypectomy	9	0	
fecal immunological test	7	0	
others	3	2	

\* Mann-Whitney *U* test

\*\* Pearson's Chi-square test

CCE: colon capsule endoscopy

PC: patency capsule

IBD: inflammatory bowel disease

**Table 6** Comparison of results between the regular CCE and PC plus CCE groups

	Regular CCE <i>n</i> =52	PC plus CCE <i>n</i> =22	p-Value
Number of excreted CCE (%)	39 (75.0)	19 (86.3)	**0.364
Number of adverse events (%)	0 (0%)	0 (0%)	***1.000
Gastric transit time, median (min)	35 (1–262)	18 (4–186)	*0.653
Small bowel transit time, median (min)	58 (18–428)	99 (21–682)	*0.004
Colorectal transit time, median (min)	87 (16–420)	160 (5–328)	*0.422
right-side colon transit time, median (min)	22 (1–226)	17 (1–341)	*0.528
transverse colon transit time, median (min)	3.5 (1–286)	4 (1–85)	*0.700
left-side colon transit time, median (min)	34 (1–415)	57.5 (1–313)	*0.398
Total transit time, median (min)	276 (68–997)	345 (158–1037)	*0.132

\* Mann-Whitney *U* test

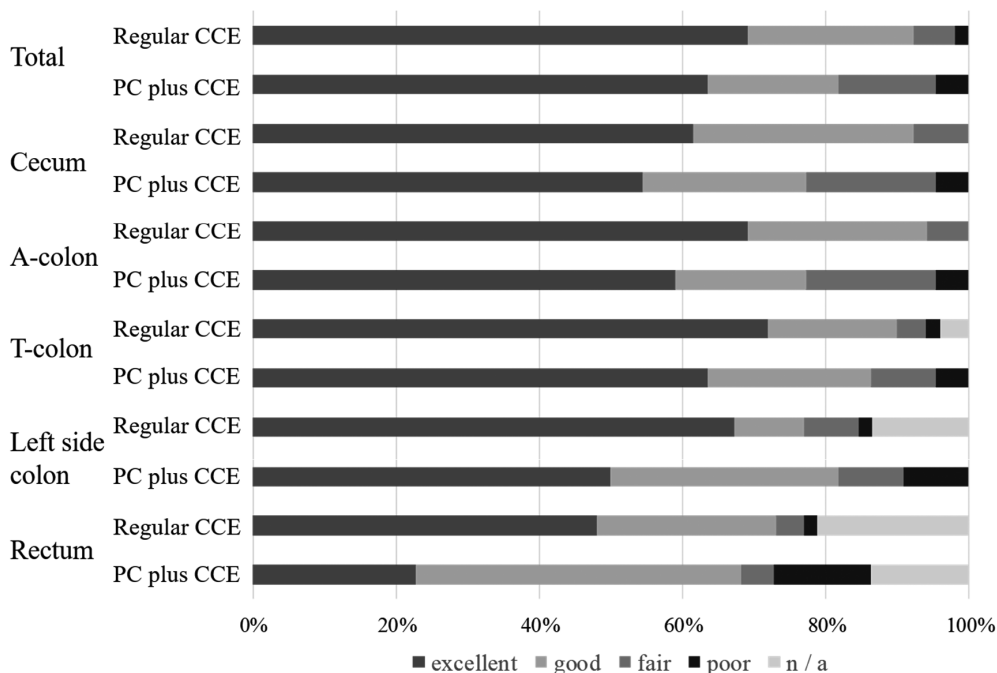
\*\* Pearson's Chi-square test

\*\*\* Fisher's exact test

CCE: colon capsule endoscopy

PC: patency capsule

IBD: inflammatory bowel disease



**Fig. 5** Colon cleansing level in the regular CCE and PC plus CCE groups

PC: patency capsule

CCE: colon capsule endoscopy

## DISCUSSION

Currently, there is no PC which has the same size as that of the CCE. CCE has a wider diameter and usually goes through the entire small bowel, just like the SBCE. However, the CCE might be retained by a stenotic lesion.<sup>15,16</sup> The aim of this study was to highlight the feasibility of checking the presence of lesions that cause intestinal stenosis, such as advanced colorectal cancer and Crohn's disease, by evaluating the patency of the GI tract using PC prior to CCE. Else, the indication for CCE would have a limited scope. In the clinical setting, CCE is usually performed for the detection of colorectal polyps<sup>7</sup> and evaluation of the endoscopic activity in ulcerative colitis<sup>17</sup>; however, there is a potential risk of retention of the CCE at the stenotic site in the small and large bowels. This is because even advanced colorectal cancer might not exhibit any symptoms, and active ulcerative colitis can cause deep ulcerations, resulting in large bowel stenosis. Therefore, we evaluated the patency of the GI tract before the CCE to avoid CCE retention, with a focus on safety and feasibility. SBCE and CCE are similar in shape and diameter, and their lateral diameter is almost the same, which is an important factor for evaluating the patency. Hence, we assumed that CCE can be evacuated from the same passage as the PC. According to our preliminary results, PC and CCE appeared to be safe.

To compare the results between regular CCE and PC plus CCE, we evaluated the CCE transit time. This is essential for the diagnosis and complete examination using CCE. Rapid passage of the CCE in the colon has the advantage of complete examination; however, it has a risk of missing the lesions.<sup>7</sup> Small bowel transit time was significantly longer in the PC plus CCE group, and obstruction to the transit of the CCE might depend on small bowel lesions. We found that

CCE was able to detect all findings, once the bowel preparation was adequate. CCE is not the primary examination tool to evaluate lesions in the large colon; rather, it is a complementary tool. In the Japanese population, multiple diverticular lesions are seen in the sigmoid colon, rather than in the ascending colon. It might be challenging to diagnose advanced cancer of the sigmoid colon complicated by multiple diverticula at the same site. As seen in Fig. 4, CCE detected the diverticular lesion in a patient with GI stenosis, which developed from multiple diverticula while the colonoscopy data were not available. In some cases of stenosis in the large colon, an antegrade approach might be better than a retrograde approach.

CD involves ulcers in the colon and rectum, as well as in the small bowel. Although the usefulness of CCE for CD was reported in the previous studies,<sup>18-20</sup> they did not use PC. Since patients with CD have a potential risk of unexpected CCE retention, PC should be recommended, especially, in patients with obstructive symptoms, history of intestinal obstruction or surgery, or according to the treating physician's request.<sup>21-23</sup>

Prior to the CCE examination, it is necessary to evaluate the patency of GI tract by any method, including an interview, which can prevent the retention of the CCE that can occur due to NSAIDs-induced stricture, intestinal tuberculosis, or stenosis at an anastomotic site. Our study demonstrated the usefulness of PC as another evaluation tool before CCE. In the future, we suggest that evaluation of the patency of the GI tract will be more frequently required for CCE, as the number of patients with suspected GI stenosis increase. For an accurate evaluation of the patency, the development of a PC with a size corresponding to that of the CCE is awaited.

This study has several limitations. This was a preliminary prospective study, conducted in a single-center, and had a small sample size. The size of the PC used was similar to that of CCE but not exactly the same. This study included only 22 patients and further study with a large sample size is necessary to evaluate the differences between PC and CCE.

In conclusion, this study indicates that colorectal lesions can be evaluated by CCE in patients with suspected GI stenosis, by using a PC. This will significantly benefit patients with CD, which is otherwise a contraindication for CCE.

## CONFLICT OF INTEREST

None of the authors have a conflict of interest regarding the work in the manuscript.

## REFERENCES

- 1 Eliakim R. The impact of panenteric capsule endoscopy on the management of Crohn's disease. *Therap Adv Gastroenterol.* 2017;10(9):737-744. doi:10.1177/1756283X17720860
- 2 Postgate AJ, Burling D, Gupta A, Fitzpatrick A, Fraser C. Safety, reliability, and limitations of the given patency capsule in patients at risk of capsule retention: a 3-year technical review. *Dig Dis Sci.* 2008;53(10):2732-2738. doi:10.1007/s10620-008-0210-5
- 3 Spada C, Shah SK, Riccioni ME, et al. Video capsule endoscopy in patients with known or suspected small bowel stricture previously tested with the dissolving patency capsule. *J Clin Gastroenterol.* 2007;41(6):576-582. doi:10.1097/01.mcg.0000225633.14663.64
- 4 Triester SL, Leighton JA, Leontiadis GI, et al. A meta-analysis of the yield of capsule endoscopy compared to other diagnostic modalities in patients with non-stricturing small bowel Crohn's disease. *Am J Gastroenterol.* 2006;101(5):954-964. doi:10.1111/j.1572-0241.2006.00506.x
- 5 Mccoy E, Gerson LB. Is colon capsule endoscopy ready for prime time? *Gastroenterology.* 2014;147(3):709-711. doi:10.1053/j.gastro.2014.07.011
- 6 Hall B, Holleran G, McNamara D. PillCam COLON 2© as a pan-enteroscopic test in Crohn's disease. *World J Gastrointest Endosc.* 2015;7(16):1230-1232. doi:10.4253/wjge.v7.i16.1230



- 7 Yamada K, Nakamura M, Yamamura T, et al. Clinical factors associated with missing colorectal polyp on colon capsule endoscopy. *Digestion*. 2020;101(3):316–322. doi:10.1159/000498942
- 8 Ohmiya N, Hotta N, Mitsufuji S, et al. Multicenter feasibility study of bowel preparation with castor oil for colon capsule endoscopy. *Dig Endosc*. 2019;31(2):164–172. doi:10.1111/den.13259
- 9 Kashyap PK, Peled R. Polyethylene glycol plus an oral sulfate solution as a bowel cleansing regimen for colon capsule endoscopy: a prospective, single-arm study in healthy volunteers. *Therap Adv Gastroenterol*. 2015;8(5):248–254. doi:10.1177/1756283X15586355
- 10 Togashi K, Fujita T, Utano K, et al. Gastrografin as an alternative booster to sodium phosphate in colon capsule endoscopy: safety and efficacy pilot study. *Endosc Int Open*. 2015;3(6):E659–E661. doi:10.1055/s-0034-1393075
- 11 Sato J, Nakamura M, Watanabe O, et al. Prospective study of factors important to achieve observation of the entire colon on colon capsule endoscopy. *Therap Adv Gastroenterol*. 2017;10(1):20–31. doi:10.1177/1756283X16673556
- 12 Romero-Vázquez J, Caunedo-Álvarez Á, Belda-Cuesta A, Jiménez-García VA, Pellicer-Bautista F, Herréras-Gutiérrez JM. Extracolonic findings with the PillCam Colon: is panendoscopy with capsule endoscopy closer? *Endosc Int Open*. 2016;4(10):E1045–E1051. doi:10.1055/s-0042-115406
- 13 Akyüz Ü, Yılmaz Y, İnce AT, Kaya B, Pata C. Diagnostic role of colon capsule endoscopy in patients with optimal colon cleaning. *Gastroenterol Res Pract*. 2016;2016:2738208. doi:10.1155/2016/2738208
- 14 Leighton JK, Rex DK. A grading scale to evaluate colon cleansing for the PillCam COLON capsule: a reliability study. *Endoscopy*. 2011;43(2):123–127. doi:10.1055/s-0030-1255916
- 15 Araujo IK, Pages M, Romero C, Castells A, González-Suárez B. Twelve-year asymptomatic retention of a colon capsule endoscope. *Gastrointest Endosc*. 2017;85(3):682–683. doi:10.1016/j.gie.2016.04.045
- 16 Toth E, Marthinsen L, Bergström M, et al. Colonic obstruction caused by video capsule entrapment in a metal stent. *Ann Transl Med*. 2019;5(9):199. doi:10.21037/atm.2017.03.79
- 17 Hosoe N, Hayashi Y, Ogata H. Colon Capsule Endoscopy for Inflammatory Bowel Disease. *Clin Endosc*. 2020;53(5):550–554. doi:10.5946/ce.2019.156
- 18 Boal Carvalho P, Rosa B, Dias de Castro F, Moreira MJ, Cotter J. PillCam COLON 2 in Crohn's disease: a new concept of pan-enteric mucosal healing assessment. *World J Gastroenterol*. 2015;21(23):7233–7241. doi:10.3748/wjg.v21.i23.7233
- 19 D'Haens G, Löwenberg M, Samaan MA, et al. Safety and feasibility of using the second-generation Pillcam colon capsule to assess active colonic Crohn's disease. *Clin Gastroenterol Hepatol*. 2015;13(8):1480–1486. doi:10.1016/j.cgh.2015.01.031
- 20 Eliakim R, Spada C, Lapidus A, et al. Evaluation of a new pan-enteric video capsule endoscopy system in patients with suspected or established inflammatory bowel disease - feasibility study. *Endosc Int Open*. 2018;6(10):E1235–E1246. doi:10.1055/a-0677-170
- 21 Nemeth A, Kopylov U, Koulaouzidis A, et al. Use of patency capsule in patients with established Crohn's disease. *Endoscopy*. 2016;48(4):373–379. doi:10.1055/s-0034-1393560
- 22 Nakamura M, Watanabe K, Ohmiya N, et al. Tag-less patency capsule for suspected small bowel stenosis: a nationwide multicenter prospective study in Japan. *Dig Endosc*. 2021;33(1):151–161. doi:10.1111/den.13673
- 23 Yoshimura T, Hirooka Y, Nakamura M, et al. Clinical significance of gastrointestinal patency evaluation by using patency capsule in Crohn's disease. *Nagoya J Med Sci*. 2018;80(1):121–128. doi:10.18999/nagjms.80.1.121