

Review

Open Access

Rate of complications in scoliosis surgery – a systematic review of the Pub Med literature

Hans-Rudolf Weiss*¹ and Deborah Goodall²

Address: ¹Asklepios Katharina Schroth Spinal Deformities Rehabilitation Centre, Korczakstr. 2, D-55566, Bad Sobernheim, Germany and ²163 Sandringham Road, WD24 7bh Watford, London, UK

Email: Hans-Rudolf Weiss* - hr.weiss@asklepios.com; Deborah Goodall - Deborahgoodall@nhs.net

* Corresponding author

Published: 5 August 2008

Received: 1 July 2008

Scoliosis 2008, **3**:9 doi:10.1186/1748-7161-3-9

Accepted: 5 August 2008

This article is available from: <http://www.scoliosisjournal.com/content/3/1/9>

© 2008 Weiss and Goodall; licensee BioMed Central Ltd.

This is an Open Access article distributed under the terms of the Creative Commons Attribution License (<http://creativecommons.org/licenses/by/2.0>), which permits unrestricted use, distribution, and reproduction in any medium, provided the original work is properly cited.

Abstract

Background: Spinal fusion surgery is currently recommended when curve magnitude exceeds 40–45 degrees. Early attempts at spinal fusion surgery which were aimed to leave the patients with a mild residual deformity, failed to meet such expectations. These aims have since been revised to the more modest goals of preventing progression, restoring 'acceptability' of the clinical deformity and reducing curvature.

In view of the fact that there is no evidence that health related signs and symptoms of scoliosis can be altered by spinal fusion in the long-term, a clear medical indication for this treatment cannot be derived. Knowledge concerning the rate of complications of scoliosis surgery may enable us to establish a cost/benefit relation of this intervention and to improve the standard of the information and advice given to patients. It is also hoped that this study will help to answer questions in relation to the limiting choice between the risks of surgery and the "wait and see – observation only until surgery might be recommended", strategy widely used. The purpose of this review is to present the actual data available on the rate of complications in scoliosis surgery.

Materials and methods: Search strategy for identification of studies; Pub Med and the SOSORT scoliosis library, limited to English language and bibliographies of all reviewed articles. The search strategy included the terms; 'scoliosis'; 'rate of complications'; 'spine surgery'; 'scoliosis surgery'; 'spondylodesis'; 'spinal instrumentation' and 'spine fusion'.

Results: The electronic search carried out on the 1st February 2008 with the key words "scoliosis", "surgery", "complications" revealed 2590 titles, which not necessarily attributed to our quest for the term "rate of complications". 287 titles were found when the term "rate of complications" was used as a key word. Rates of complication varied between 0 and 89% depending on the aetiology of the entity investigated. Long-term rates of complications have not yet been reported upon.

Conclusion: Scoliosis surgery has a varying but high rate of complications. A medical indication for this treatment cannot be established in view of the lack of evidence. The rate of complications may even be higher than reported. Long-term risks of scoliosis surgery have not yet been reported upon in research. Mandatory reporting for all spinal implants in a standardized way using a spreadsheet list of all recognised complications to reveal a 2-year, 5-year, 10-year and 20-year rate of complications should be established. Trials with untreated control groups in the field of scoliosis raise ethical issues, as the control group could be exposed to the risks of undergoing such surgery.

Background

Scoliosis, as a general medical term is better known as a lateral curvature of the spine [1], and is conventionally measured using the Cobb angle technique of X-rays taken of the coronal plane view [2]. But as it presents clinically, the condition is actually a much more complex deformity and to correctly measure and define the different effects it has upon the human spine it is necessary to use 3D terminology along with observations taken on the three anatomical planes [1].

The underlying cause of scoliosis may on some occasions be clearly determined, such as congenital changes, or neuropathic or myopathic conditions, or a form of degenerative spondylosis. In the majority of cases, the causes are unfortunately unknown and have come to be known as having 'idiopathic' scoliosis [3]. Adolescent Idiopathic Scoliosis (AIS), the most common form of scoliosis, is a

three-dimensional structural deformity of the spine and of the trunk, occurring in otherwise healthy children during puberty, while early onset idiopathic scoliosis occurs before puberty [4]. AIS has been classified according to specific curve patterns and these patterns clinically may appear more or less pronounced (Figure 1).

Historically, in central Europe the treatment for AIS – and for some other forms of scoliosis as well – includes; Physiotherapy (PT) on an outpatient basis; Scoliosis In-patient Rehabilitation (SIR); corrective bracing and surgery, with or without spinal fusion [5-7]. Conservative Scoliosis Management is usually regarded as effective when curvature progression has been stopped below specific limits, although parameters other than curve progression may play an important role in terms of outcome [4-6].

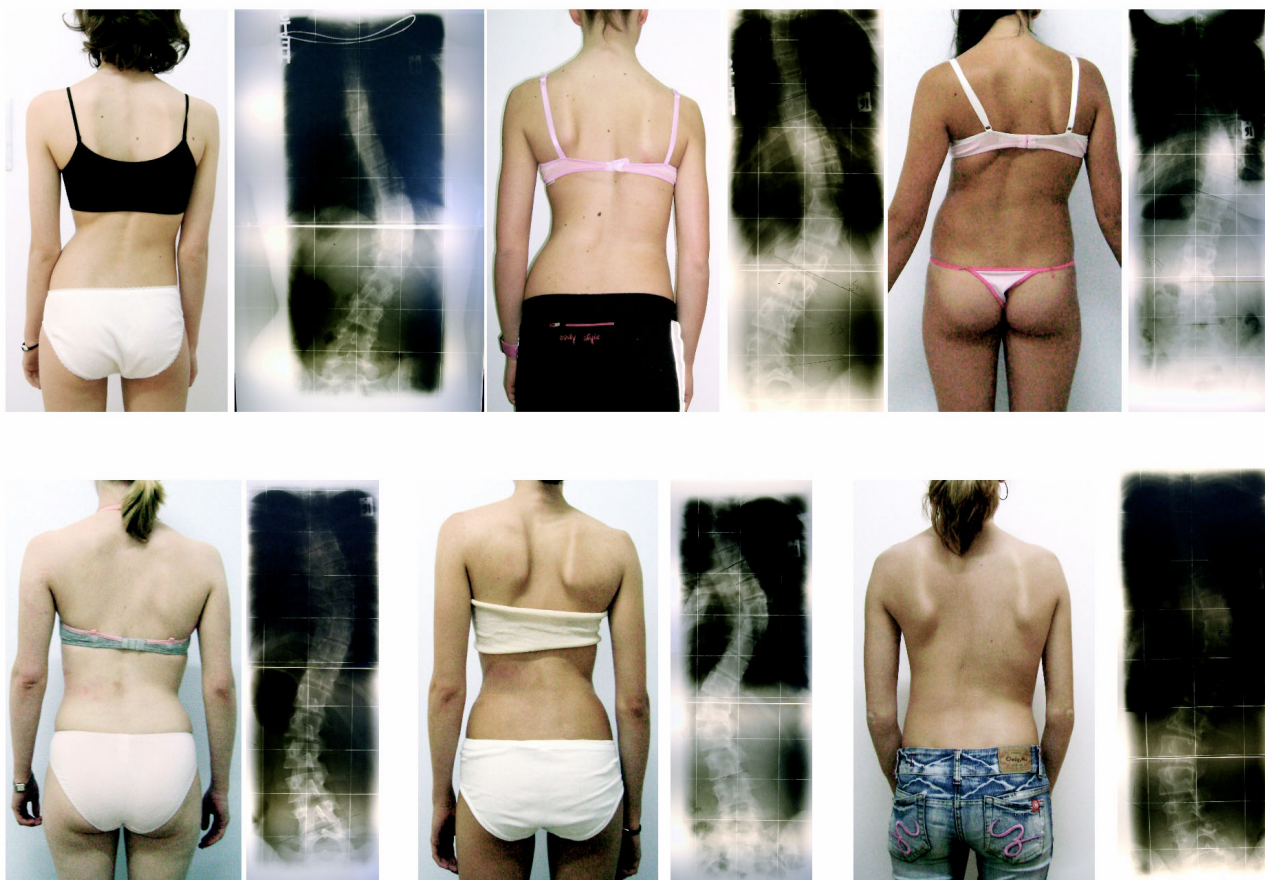


Figure 1
Similar Cobb angles clinically may look different depending on curve pattern. All patients on this figure have a Cobb angle of 40 degrees. As can be seen, the more decompensated a curve, the more visible the deformation. Double major curvatures are compensated; the most stable curves present after the end of growth [4] and therefore rarely requiring surgical treatment.

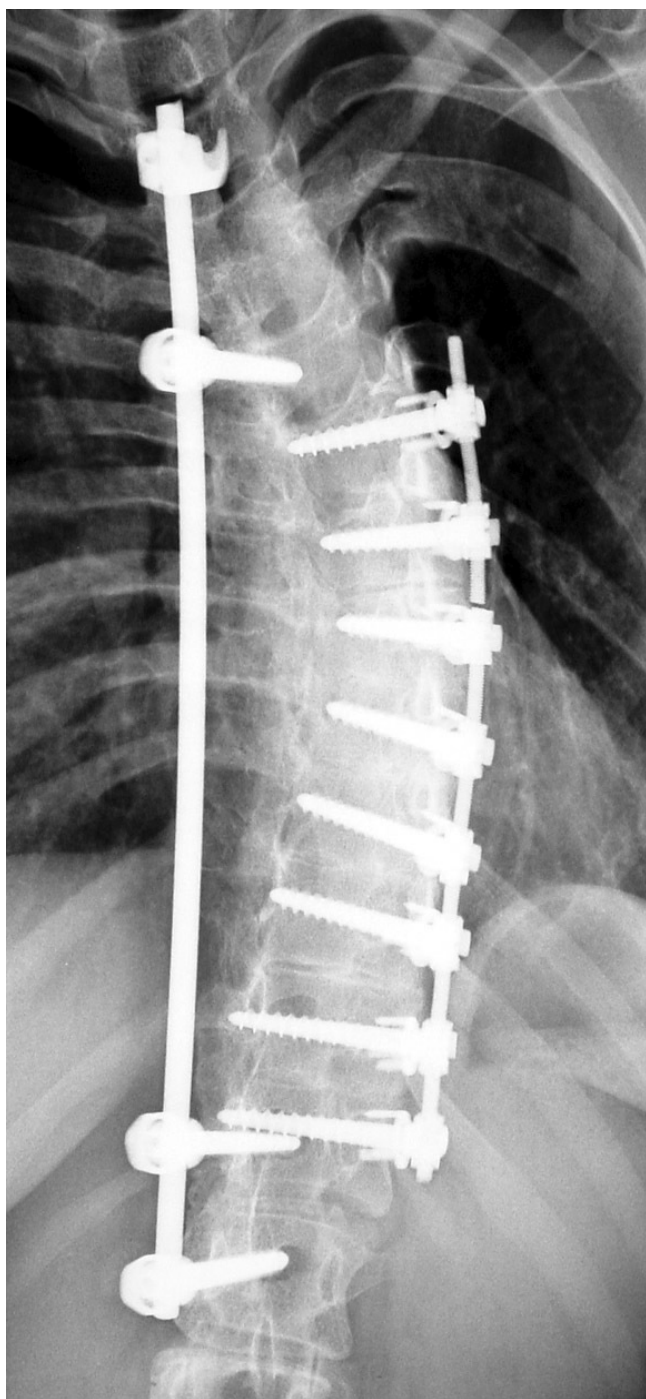

Figure 2
Failure of spinal fusion often requires salvage surgery.
 Failure of the ventral instrumentation (VDS): An additional dorsal rod was implanted to stabilize the spine.

Spinal fusion surgery, which is recommended when magnitude of curvature exceeds 40–45 degrees, has been used as a treatment for nearly a century [8-10]. The aims and goals of surgery have varied widely. Early hopes that spi-

nal fusion could be used to leave the patient with a mild residual deformity were not successful as a third of patients lost all postoperative correction within 1–10 years post surgery [11]. Expectations have been revised to the more modest goals of preventing progression, restoring 'acceptability,' and reducing curvature. In spinal fusion the vertebrae are accessed by posterior, anterior, or thoracoscopic incision. The main principle these surgical techniques have in common, is the use of the spine as a structural scaffold, cementing the parts onto this via a bone paste, giving it an overall straighter shape. [10,12-14]. These surgical methods are based on the expectation that this operation will heal well and remain sturdy for the lifespan of the patient. Steel rods, screws, wires etc. have been used to reinforce the stability of the spinal fusion [13-18] and the choice of the instrumentation used is based upon the preferences of the surgeon [19-23]. The specific choice of these has been reviewed recently [21-23]. Failure of spinal fusion requires re-operation to restore curvature correction [19] (Figure 2). In a recent review [24], the different kinds of complications which may arise during or after scoliosis surgery have been listed:

Complications of Spine Surgery independent of aetiology

In principle, all kinds of complications may occur in all scoliosis aetiologies [24]. However, in the otherwise healthy subjects with AIS the incidence of major complications may not be as high as in neuromuscular disorders [24]. Before outlining the incidence and prevalence of complications (Tables 1, 2 and 3) it is of primary importance to describe the possible complications independent of the aetiology.

Risks of spinal fusion include those occurring in any major surgery, such as severe blood loss; urinary infections due to catheterization; pancreatitis; and obstructive bowel dysfunction due to immobilisation during and after surgery [25-31]. The frequency of specific complications, including death is unknown. This is due to problems in reporting such as; mandatory reporting, definitions, interpretation of complications and compli-

Table 1: Pooled rate [122] of complications for the different aetiologies

	Studies	Average rate	Range
Neuromuscular Scoliosis	22	35% (SD 21)	0 – 89%
Adult Scoliosis	11	44% (SD 24)	10 – 78%
Idiopathic Scoliosis	11	20% (SD 22)	0 – 73%*
Early onset Scoliosis	1	48%	
Congenital Scoliosis	4	14% (SD 23)	0 – 48%
Congenital Heart Disease	1	27%	

This table shows the wide range of variability of the overall complication rate in the different entities. * In the IS group one study on fusion down to the pelvis [69] showed the highest rate of 73%.

Table 2: Pooled rate [122] of major complications for the different aetiologies

	Studies	Average rate	Range
Neuromuscular Scoliosis	17	17,4%	0 – 39%
Adult Scoliosis	6	30%	10 – 62%
Idiopathic Scoliosis	7	8,6%	0 – 37%*
Congenital Scoliosis	3	3%	0 – 9%

The pooled data [122] seems incomplete in comparison to the total rate of complications, because in the various papers major complications were not always shown. Therefore, a statistical analysis does not make sense. However, this table shows the wide range of variability of major complications in the different entities. * In the IS group one study on fusion down to the pelvis [69] showed the highest rate of major complications (37%), whilst the range in the IS group, excluding this paper was 0 – 9,5%.

ance varies [32]. Information is based on voluntary reporting by clinicians. Other risks of scoliosis surgery are summarised below.

Death and neurological damage

The incidence of death as a complication of spinal surgery, for otherwise healthy patients is reported to be less than 1% [33]. In one survey, only one child out of 352 patients died of peritonitis [34] and in a group of 447 patients, two deaths occurred due to pulmonary complications [35]. The life expectancy of patients with a complex neuromuscular condition was significantly reduced by spinal surgery [36]. Another study involving adults with a less than 60% vital capacity measure, 20% had died within 1 year post surgery [37]. In a survey further highlighting these complications [38], 21% were contributed to be secondary to spinal fusion surgery.

Symptoms of neurological damage post-surgery include; partial or total paraplegia, quadriplegia, or peripheral nerve deficit [25,39]. Neurological deficits can result from vascular, metabolic, or mechanical complications of spine surgery [40-51]. Published cases include migration of bone graft into the spinal canal [48]; breakage of implants

[52]; penetration of instrumentation into the spinal canal [49] and compression of the nerve roots by components of implants [39].

Loss of normal spinal function

In each spinal surgery case there is an irreversible loss of the normal active range of movement in the spinal column [53-55], including the non-fused segments [56-58]. When compared with control subjects, the ability of surgical patients to side flex was reduced by 20–60% [59]. This loss of spinal mobility has gained little significance in the literature, especially in relation to the detrimental effects upon patient health, function, and quality of life. Winter et al. [59] argued that 'it has long been a clinical observation by surgeons who manage scoliosis that patients seem to function well and be relatively unaware of spinal stiffness, even after many motion segments have been fused.' No data in support of this observation is provided. In actual fact, it has been shown that in non-surgical cases, pain increases as flexibility is reduced [60].

Strain on un-fused vertebrae

The post surgical rigid spine causes strain on the un-fused parts of the skeletal framework [54-59] and in a severe case, a woman sustained stress fractures to the pelvis [61]. More commonly reported are post surgical degenerative changes, which occur in young adults [62] and in adults, sometimes within 2 years post-surgery [52]. A higher degree of correction results in a higher rate of degenerative osteoarthritis and the high stress on the rigid spine means that even low impact can cause serious injuries [63]. Surgeons now recommend that in surgically treated scoliosis patients, 'trauma physicians should have a high index of suspicion for potential spinal injuries above a previous multi-level fusion' [63].

Post-surgery pain

Pain is the primary indication for re-operation [64-66]. The mechanism for increased neck and back pain after surgery is not well understood [67]. Bridwell [10] suggests

Table 3: List of individual complications occurring in the different scoliosis aetiologies as found in the reviewed literature

Complication	NM	AS	IS	CS	Mixed
Death	6,5%	(3S) 2,5%	0,03%		
Pseudarthrosis	(7S) 13,1%	(7S) 17,5%	(5S) 5%		(4S) 23%
Deep wound infection	(3S) 13,2%		(S2) 3,1%		4,7%
Neurologic Complications		(2S) 7,5%	(3S) 1,5%	9%	(4S) 2,7%
Delayed Infection			(2S) 2,9%		
Pedicle screw mispl.			(2S) 15,8%		10,5%
Delayed Paraparesis			X		

Individual complications as have been found in the literature reviewed for the rates of complications [13,68,69,71,77,88,135,138-215] as a descriptive analysis for neuromuscular scoliosis (NM), adult scoliosis (AS), idiopathic scoliosis (IS), congenital scoliosis (CS) and scoliosis of mixed aetiology (Mixed). Whenever there was more than one study found describing a certain complication rate, the number of studies (S) has been given and the rates have been averaged. X = described once.

that late-developing pain could be a complication of surgery, or an effect of aging, or '*perhaps a focus on the disability associated with spinal deformity and surgical treatment.*' But the answer for surgeons seems to be to re-operate [68]. Among 190 patients, 19% required re-operation within 2 to 8 years after surgery [67]. For 27 patients who sought treatment 59% felt their pain had been reduced, but 41% did not feel a reduction in their pain levels, and a further 26% were very unhappy with the outcome [68]. Among 34 patients with significant post surgical pain, 56% reported reduced pain after additional surgery, while 44% did not; in the same study, 2 patients who did not have pain before surgery reported pain in the follow up [69].

Pain at the iliac graft site, first noted in 1979, has now been formally published [70,71]; of 87 patients, 24% complained of pain at the graft site, with 15% reporting severity sufficient to interfere with daily activities. As reported by the authors such problems with iliac crest grafting have been severely neglected in literature, especially problems associated with rib-resection.

Infection and inflammatory processes

Infections from surgery may manifest months or years later [72-81] and has been detected more than 8 years after surgery, with 5 to 10% of patients developing deep infections at 11-45 months after surgery [77,78] and in some cases, leaving the spinal cord exposed to injury [78]. Infections reportedly are becoming more common, perhaps due to larger instrumentation used [77] or perhaps due to the increasing prevalence of multi-drug resistant bacteria in hospital settings. Inflammatory responses to metallic instrumentation can occur independently or in conjunction with infections [79]. Particulate debris from implants can stimulate an autoimmune response that can result in bone deterioration [80]. In most cases, additional surgery to remove instrumentation and to treat the wound is required [81].

Infection may also be transmitted through blood transfusions needed to replace the large amounts of blood lost during invasive procedures [82] and a similar risk occurs with the use of allograft [83]. Some have reported to be infected with HIV following this type of surgery [84]. In a survey of spine surgeons, 41% of those using allograft reported having concerns about the risk of disease transmission and 88% of those make it a policy to inform patients or parents [85].

Curvature progression

Some curvatures continue to progress after spinal fusion due to broken rods or other failure of instrumentation. Renshaw [13] has said that, "*One would expect that if the patient lives long enough, rod breakage will be a virtual cer-*

tainty." Furthermore, discomfort may occur when any pressure is placed against the back; this is especially problematical with newer bulky instrumentation implanted in thin patients [10].

'Pseudarthrosis' ('false fusion') or failure of the bone graft, which constitutes the spinal fusion, can occur years after surgery and can be difficult to diagnose [86,87]. Among 74 patients treated surgically between 1961 and 1976, pseudarthrosis occurred in 27% of patients within a few years of surgery [88]. For adult patients, 15% had failure of fusion and/or instrumentation requiring additional surgery [89]. Curvatures may continue to progress in young children despite a rigid fusion, due to a '*crankshaft phenomenon*' in which spinal growth causes rotation around the fusion [90,91].

Decompensation and increased sagittal deformity

Beginning with Harrington rods, surgeons have experimented with instrumentation of increasing complexity and bulk to hold spinal fusions in place [24]. Each new variety of instrumentation has brought with it new problems [24]. One of the ongoing problems has been decompensation or the development of new deformities involving changes in sagittal contours and coronal balance of the body as a result of surgery [92-97] (Figure 3 and 4). Reducing the lateral curvature in thoracic scoliosis can exacerbate the sagittal deformity and cause flattening of the cervical, thoracic and/or lumbar spine beyond that which caused the deformity itself [94-97]. Development of '*flatback*' is a painful condition with potentially devastating complications such as disability [98]. In response to such discoveries, focus is shifting towards the sagittal contours and coronal balance of the spine [10].

Increased torso deformity

Despite the application of force to straighten and derotate the spine during surgery, the rib hump can worsen after surgery [99-102]. Even when rib hump magnitude improves postoperatively, much of the correction can be lost and in many patients the situation is eventually worse than before surgery. In response, surgeons increasingly use costoplasty to assure an improved appearance, by excising the ribs that comprise the prominence [103]. This procedure can in actual fact cause a progressive scoliosis [9] and the destabilising effects of rib removal can also result in a disabling condition called '*flail chest*' in which the normal function of the rib cage is permanently compromised [104]. Rib resection excises a substantial part of the functional components of the chest but the effects on chest expansion has not been documented [24]. However, this procedure has been shown to reduce the volume of the chest cage and to substantially impair pulmonary function [24].

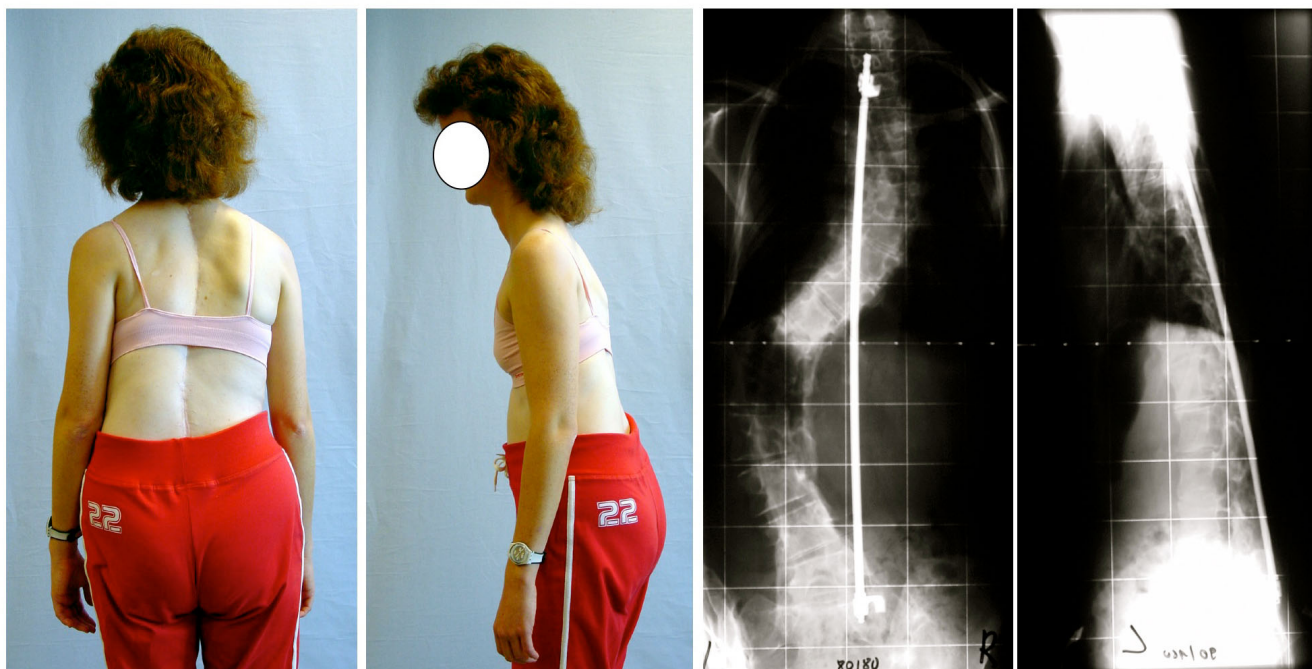


Figure 3
Ventral decompensation after spinal fusion. After operation this patient was unable to walk upright. The implant fixed the patient in forward bent position.

Other long-term complications

The complexity of spinal surgery is reflected in the diversity of complications that may occur months or years later. Given the time delay and difficulty in diagnosis, it is likely that only a minority of such events are recognised as surgical complications and when investigated are then recognised as being related to the surgery [88,105-114] (Table 4.).

Salvage surgery

Due to such complications outlined above more re-operation is necessary, sometimes referred to as 'reconstructive,' 're-corrective,' 'revision,' or 'salvage' surgery [115]. Even stable fusions may fail in response to sudden force, for example, in the event of automobile accidents [116,117]. Some authors suggest that patients and their parents should be advised that it may take more than one operation [24]. Documented cases of patients having had 5 or more salvage surgeries [69], as in one study, 22% of patients needed a total of 28 additional operations and of 110 adolescent patients 21% required implant removal [118]. Complication rates vary; failure of fusion has been found in more than 50% of treated patients [24] and among 25 adult patients, 40% required salvage surgery [119]. Even when a solid fusion has been obtained by the time of re-operation, removal of instrumentation 'may lead to spinal collapse and further surgery' [120].

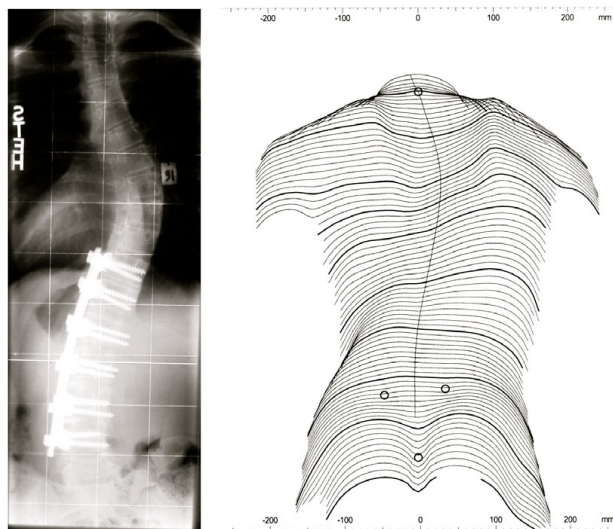


Figure 4
Lateral decompensation after fusion of the lumbar curve. The lumbar curve has been fused; the thoracic curve progressed leading to a decompensation to the thoracic convex side. Because of the imbalanced appearance the patient was dissatisfied. There was no cosmetic/psychological benefit in this case and therefore this surgery should perhaps not have been performed.

Table 4: List of other long-term complications as found in literature [24]

Complication
Curvature progression after surgery [10,13,86-91]
Decompensation [92-97]
Increased sagittal deformity [98]
Increased torso deformity [99-104]
Emotional breakdown [88]
Gastrointestinal bleeding (late complication 6 years post surgery) [105]
Subarachnoid-pleural fistula [106]
Blindness due to central retinal artery occlusion [107]
Kidney failure due to compression of a ureter [108]
Nerve root injury and degeneration due to compression [109]
Recurrent meningitis [110]
Chronic intermittent vomiting [111,112]
Cast syndrome [113,114]

From the patient's perspective, the preferred plan of action would likely to be based upon avoiding unnecessary risk i.e. avoiding surgery, or to keep it as the final option, once all conservative measures have failed. Under this premise, every effort should be undertaken to improve non-operative treatments for at least adolescent idiopathic scoliosis (AIS), the most common form of scoliosis which is regarded to be relatively benign [121]. Other forms of scoliosis may have worse prognoses [4], however real long-term natural history studies do not exist for every single possible form of scoliosis.

Recently claims have been made for a randomised controlled trial (RCT) on brace treatment [122-124], although there is some evidence, that conservative treatment approaches can influence natural history of the disease and decrease the rate of progression [7].

Prospective controlled studies on in-patient rehabilitation and bracing [125-127] and consistent results in retrospective studies [7] justify the recommendation of at least grade B research [128]. Therefore, to perform a RCT on bracing and withhold treatment on half of the patient population with significant curves until surgery may be recommended would be unethical [129]. In view of the fact that there is no evidence that health related signs and symptoms of a scoliosis can be changed by spinal fusion in the long-term [24,130-134], a clear medical indication cannot be derived from most scoliosis conditions [129,131-134]. In the light of an actual publication on adolescent idiopathic scoliosis with a prospective design [135], showing the short-term risks of scoliosis surgery to be more than 3 times higher than previously expected from retrospective reviews, the matter of surgical indications at present should be investigated more closely in order to improve the patient's safety.

The paper by Martha Hawes [24] contains very comprehensive accounts of the reported complications of scoliosis surgery until early 2006. Just recently, new papers on this topic appeared [130,135] and in the light of recent discussions about the specific indications for scoliosis surgery [130-132], a review on this topic seems desirable. The knowledge of the rate of complications of scoliosis surgery may enable us to establish a cost/benefit relationship for this intervention and to improve the quality of the advice given to prospective patients. This study will also address the question as to whether the risks of surgery are small enough to justify the 'wait and see – observation only' strategy, which is widely accepted [5].

The purpose of this review therefore, is to present the research available on the rate of complications in scoliosis surgery.

Methods

Exclusion and inclusion criteria for the selection of studies in this review

Types of studies included

all types of studies, retrospective and prospective ones, reporting on the rate of complications related to scoliosis surgery have been included.

Types of participants included

patients with any type of scoliosis

Types of participants excluded

with complications not due to scoliosis surgery.

Type of intervention

surgery.

Search strategy for identification of the studies

Pub Med and the SOSORT scoliosis library [136,137], limited to English language and bibliographies of all reviewed articles.

The search strategy included the terms; 'scoliosis'; 'rate of complications'; 'spine surgery'; 'scoliosis surgery'; 'spondylodesis'; 'spinal instrumentation' and 'spinal fusion'.

Study selection

An electronic search was performed and the studies were selected based on title, abstract and key words. When appropriate, full copy of the articles were printed in order to determine whether or not they met with the inclusion criteria. Additionally, the references of all included articles were checked for further papers that might meet the inclusion criteria. If two papers were found analysing the same group of patients, the most recent paper or the one with the largest sample of patients was selected for inclusion.

Results

The search carried out on 1st of February 2008, with the key words "scoliosis", "surgery", "complications" revealed 2590 titles, which not necessarily attributed to our quest for the term "rate of complications". 287 titles have been found when the term "rate of complications" was used as a key word.

Of these, 23 papers were found to report on the rate of complication in patients with neuromuscular scoliosis [138-160], 11 papers were found to report on the rate of complication in patients with adult scoliosis [68,161-170], 13 papers were found to report on the rate of complication in patients with idiopathic scoliosis (11 with a general rate of complications) [13,69,135,171-181] and 4 papers were found to report on the rate of complication in patients with congenital scoliosis [182-185]. One paper included patients with early onset scoliosis [186] and one included patients with congenital heart disease [187]. 11 papers reported on the rate of complication in patients with scoliosis of mixed aetiologies [88,188-197] and one in patients after re-operation [198].

Three papers were found to report on problems associated with pedicle screw fixation [199-201], 5 reported on problems associated with thoracoscopic procedures [202-206] and one on problems associated with vertebral body stapling [207].

There were also papers reporting on the rate of certain complications, like pseudarthrosis [208-213], retrolisthesis [214], delayed paraparesis [215], delayed infection [77] and problems with posterior iliac crest bone crafting [71].

In 17 studies, the main focus was on complications, whilst in the others complications have been reported additionally to results, unfortunately most of these utilised different definitions, some of them focussing specifically upon certain complications. Within some of these studies, differences have been made between minor and major complications, however, in most of the articles, the borderline between major and minor have been drawn more or less at random. In one paper a clear definition is given [167], but this definition unfortunately, is not used as a valid general standard.

Major complications were considered to be deep wound infection, pseudarthrosis, transition syndrome, neurologic deficit, and death. Minor complications considered were asymptomatic instrumentation failure (without loss of correction), instrumentation prominence requiring removal, and proximal or distal '*junctional segmental kyphosis*' (5–10 degrees) or subsequent disc space narrowing of 2–5 mm without clinical symptoms.

The pooled overall rate of complications for the different aetiologies can be seen on table 1. The pooled rate of major complications is listed on table 2 and the list of complications found within the reviewed papers can be seen on table 3 and 4.

Discussion

The prevalence of complications in scoliosis surgery seems quite high. The variation of the rates surely is dependent on the surgical procedure performed, on the specification of the subset of patients investigated in the various studies and on the distribution of Cobb angles in the different samples of patients. For instance, there are many subsets of conditions, which have to be regarded as neuromuscular (Duchenne muscular dystrophy, myelomeningocele patients, cerebral palsy, neuropathic scoliosis, spinal muscular atrophy and poliomyelitic scoliosis). The adult population may consist of adult patients with idiopathic scoliosis or of patients with degenerative deformity. Even the subset of patients with idiopathic scoliosis may contain more or less patients with early onset scoliosis, patients with different Cobb degrees and different maturity. Congenital scoliosis is no uniform condition as well. Therefore, a standardization of patient subsets does not seem possible.

The definition of major and minor complications also varies in these studies. Some authors report the major complications and some report the whole rate of general complications (Table 1 and 2.).

In one study, a re-operation due to instrumentation prominence [167] has been defined as a minor complication as were '*junctional kyphosis*' and disc space narrowing.

However, these complications may lead to a re-operation decades after surgery and then might cause major problems. Also, the high rate of pedicle screw misplacements [199-201], thought to be asymptomatic after operation might in fact cause problems in future years after surgery, as has been found in other complications [24].

The follow-up time is also different in the different studies. Long-term follow-up studies have not been found.

As highlighted by Hawes [24], the complexity of spinal surgery is reflected in the diversity of complications that may result months or years later. Given the time delay and difficulty in diagnosis, it is likely that only a minority of such events are recognized as surgical complications.

The data on the rate of complications seems rather inhomogenous and incomplete. Unfortunately there is no mandatory reporting of complications, neither is there a standardized way.

However, the high variability of complication rates could be clarified should a mandatory reporting system exist, reporting on all types of spinal implants in a standardized way. With a spreadsheet list of all recognized complications [24] a 2-year, 5-year, 10-year and 20-year rate of complications could be established for all implants available including the complications 'progression after operation', 'Increased torso deformity' and 'coronal and/or sagittal decompensation after surgery' which are often not really registered by the surgeon [24,86-104,130].

There is a relatively high rate of complications in patients with neuromuscular scoliosis and the benefit for the patient remains questionable as outlined below:

"Cardio-respiratory function and life expectancy are not improved, but most patients and families are very satisfied by the comfort brought about by the surgical operation" [159].

"Surgery should be considered as soon as frontal or sagittal collapse of the spine is observed. However surgery does not result in respiratory improvement, or extending life expectancy" [160].

The signs and symptoms of AIS obviously are not significantly influenced by surgery [24]. Patients with rare diseases associated with scoliosis like Prader Willi syndrome do not clearly benefit from spinal fusion [133] and surgery of patients with congenital scoliosis has also specifically been under criticism recently [134]. So called long-term studies reporting on congenital scoliosis patients reveal follow-up periods of 3-6 years with most of the patients being still before the pubertal growth spurt at final follow-up [216-219].

To conclude from single case reports that; *"the early fusion prevented the customary severe progression of this condition and early death due to cor pulmonale"* [220,221], seems biased when there could be the possibility that even without surgery cor pulmonale would not necessarily be the consequence of an untreated congenital scoliosis. The question raised by this research is; where is the research and long-term case reports where patients actually did experience severe problems due to surgery? Without such research one can only assume that the rates of complication may be even higher than those reported [222].

What specific evidence is there to support scoliosis surgery? The signs and symptoms of any kind of scoliosis obviously cannot be changed by scoliosis surgery and long-term beneficial effects have not been reported yet as there are no studies presenting long-term risks [24].

No report of the long-term surgical outcome (balance, rate of fusion, rib hump correction, cosmetic correction, pain, and patient satisfaction) is available for any series. Further prospective studies including these parameters will be required to determine the real benefit of such procedures to the patient [24].

As early as 1973, Paul Harrington envisioned in the future a common database or registry of all SRS members' patient's treatment results [8]. Unfortunately the SRS failed to follow this vision until recently. Instead of achieving long-term evidence for surgical treatment on a higher level and addressing the problems after surgery to attempt to improve patient's safety, the surgical community is presenting large numbers of papers describing HRQL after surgery and related research [223-241]. The problem with such studies however, is that they lack validity as they do not investigate the actual signs of scoliosis or the symptoms of the patient post surgery [242].

Those studies containing psychological questionnaires may be compromised by the dissonance effect [242-246], which applies to all situations that include important decisions to be made. Cognitive dissonance occurs most often in situations where an individual must choose between two incompatible beliefs or actions and there is a tendency for individuals to seek consistency among their cognitions. Unable to face an inconsistency, such as being dissatisfied with a surgical procedure, a person will often change his attitude or action.

Surgery is impossible to reverse, but subjective beliefs and public attitude can be altered more easily. The clinical significance of this is that a patient not satisfied with a surgical treatment may not necessarily publicly admit this, as Moses et al. have described in their paper [242]:

"Slim objective favourable outcomes correlate with high post-surgical patient satisfaction, while a considerable share of patients with whom a highly favourable outcome has been attained express relatively low post-surgical patient satisfaction. This paradoxical trend may be well understood when applying Cognitive Dissonance Theory. The whole pattern of results point again at highly complex and powerful psychological processes, some of them seemingly irrational".

The dissonance effect is reflected in the scoliosis literature as well:

"Patient satisfaction is subjective. It does not reflect the benefits of surgery with respect to the future preservation of pulmonary function in thoracic curves nor the prevention of osteoarthritis in lumbar curves" [247]. (Figure 5)

"Radiographic and physical measures of deformity do not correlate well with patients' and parents' perceptions of appearance. Patients and parents do not strongly agree on the cosmetic outcome of AIS surgery" [248]. (Figure 6, 7 and 8)

From searching all of the studies based on questionnaires within this review, no evidence can be derived that supports the assumption that patients have experienced benefits from undergoing surgery, as none were able to rule

out the cognitive effect of dissonance. Without being able to rule out such effects on the post-operative experience these outcomes do not appear to be reliable [4,249,250].

Today, from the patient's perspective, healthcare professionals have more open questions than answers when approaching the subject of spinal surgery in patients with scoliosis. For example; What are the long-term effects in the elderly; how long does the cosmetic effect of an operation last; is there a prospective controlled study clearly showing that scoliosis surgery really prevents progression in the long term; does the untreated patient really feel more impaired when progressing 10 degrees more in 20 years?

In view of the questions raised by research [129,130], the lack of measurable medical benefit [24] and the high amount of short and long-term risks of the surgical procedures applied, the decision to have surgery does not seem to rely on any valid evidence to support it. The informed patient should perhaps make the final decision after being provided with all the objective facts available. As there is also no clear benefit for the operation in patients with neuromuscular scoliosis [159,160], the indication in these cases deserves to be debated and approved by ethical committees.

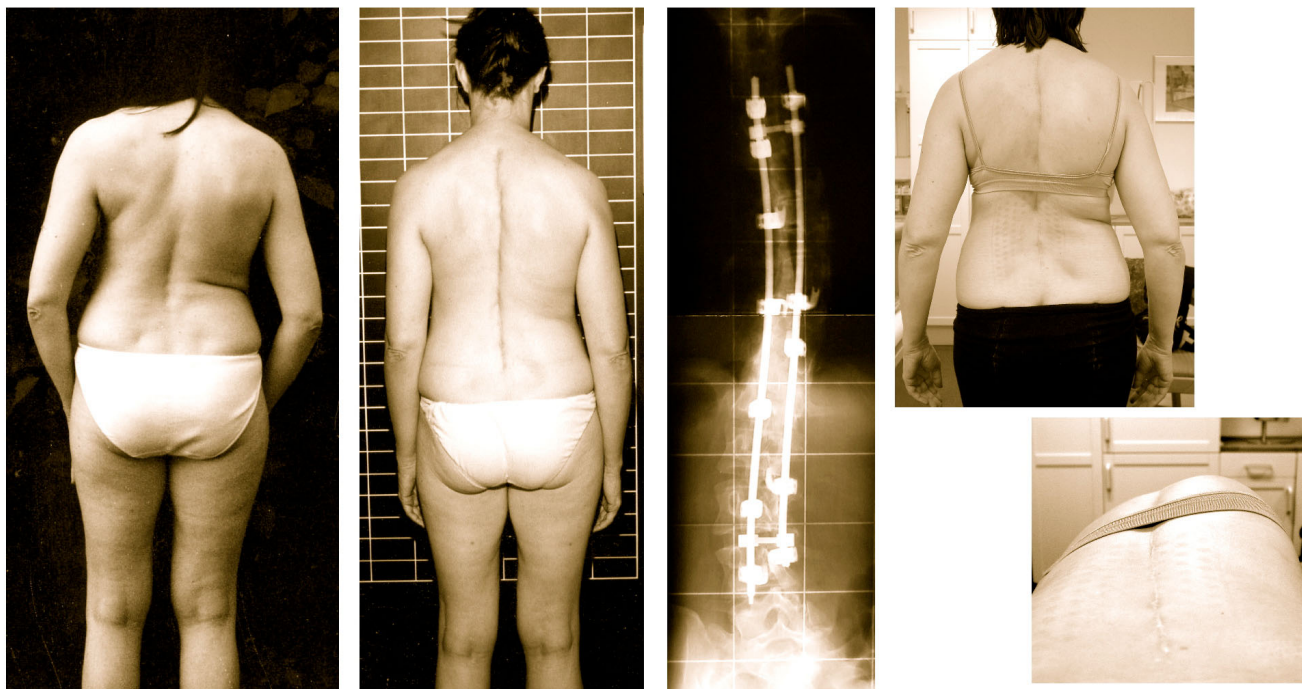


Figure 5
Balanced appearance with marked rib-hump after surgery. Although a marked rib-hump is clearly visible after surgery the patient is satisfied with the operation. The rib-hump reappeared after 5 years, however compensation has been maintained. The best cosmetic result was achieved directly after surgery.

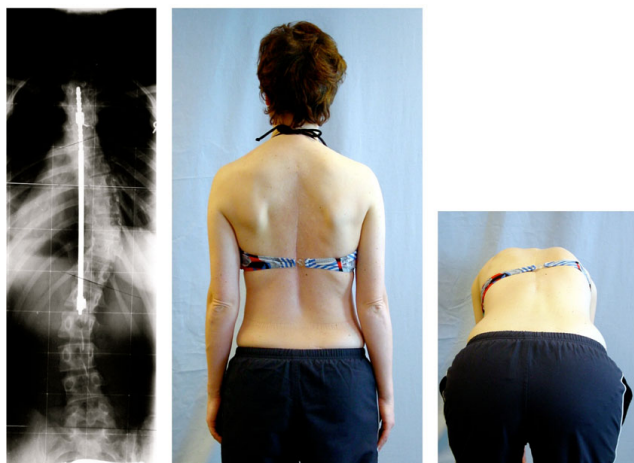


Figure 6
Excellent clinical result without patient satisfaction.
 Excellent clinical result 20 years after Harrington instrumentation. The patient is without pain, however suffers from lack of spinal function although the lumbar spine remained unfused. Additionally, the patient, operated on at the age of 13 years, complained that her parents made the decision. After operation the patient experienced significant functional problems she feels unable to cope with.

Claims for a randomized controlled trial on bracing also seem unethical [129]. To allow growing patients to continue without conservative treatment (a control group) until surgical intervention may be recommended, is completely unethical, especially when one considers the problems with surgery, such as; primary risks; a re-surgery rate, which might be higher than 44% in the long-term [4,24,250] and still undetected future complications which might comprise the elderly patients [4].

It is recognised that this review is limited to the Pub Med/ Medline and SOSORT databases and that further database searches would deepen the topic further. To find more variations in a bigger number of papers would not lead to other conclusions as to those that have already been drawn. The lack of standardization of the reports on complications does not allow final conclusions on the numbers per se. The procedure of averaging rates (pooling) as performed in another paper [122] will not permit the estimation of the risk for the individual case. Like the quality of bracing [122] the quality of treatment in surgery is hardly defined in the literature available. It is possible that clinics with smaller rates of complications exist, but in the same way it is possible that clinics with higher rates also exist, which simply may not report their rates of complication publicly [32,222].

A first step into the right direction has been made by the Scoliosis Research Society: In the Scoliosis Research Soci-

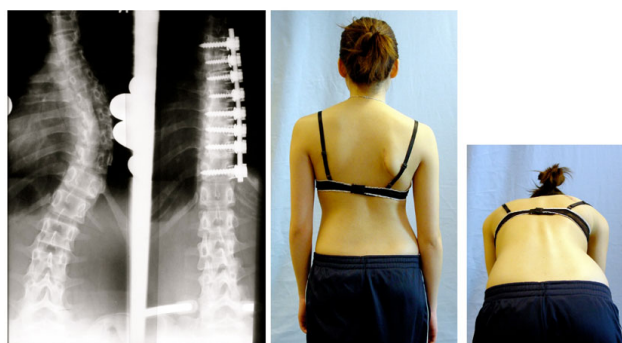


Figure 7
Excellent radiological result without patient satisfaction.
 An 'excellent radiological result' one year after ventral fusion. But the patient complained about the decompensation (clinical overcorrection) and the visual prominence of the shoulder blade.

ety Morbidity and Mortality Reports (2002 – 2005) [251] 57 of all patients with spinal fusion (0,2%) died mainly due to cardiac causes, 59 of the scoliosis patients (0,8%) had neurological deficits (in patients with dwarfism mainly), infections between 0,9% (Idiopathic Scoliosis) and 3,4% (neuromuscular scoliosis) and an overall complication rate of 8,6% when all scoliosis aetiologies are concerned (SRS 2002 M & M data abstract [251]). Unfortunately in the years 1994 to 2005, there is a varying percentage of SRS members submitting data, ranging from 35 to 70% (SRS 2005 M & M data abstract [251]). Additionally to that not all types of complications are registered

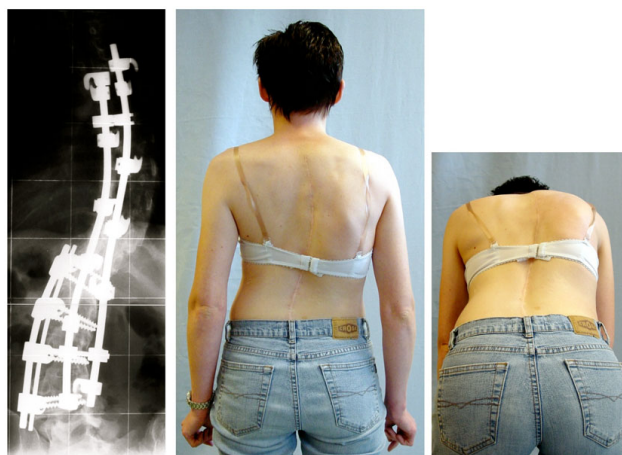

Figure 8
Not the best clinical result with patient satisfaction.
 This patient was satisfied although two operations have been necessary and the rib-hump and decompensation are still visible. This satisfaction may be the result of the dissonance effect [242].

like many of those described in the introduction of this paper. The long-term complications, that may develop years after surgery [24] are not listed in the M & M summaries [251], which are not easily accessible to the public.

In the light of the conflict of interest many spine surgeons have because of their affiliation to industry [251-253], the indication for surgery in the case of scoliosis may well be more appropriately assigned to a more specialized role. For example, a conservative scoliosis specialist that can utilise standardized psychological questionnaires [254] after having discussed all possible benefits and complications of surgery with the patient.

Conclusion

Scoliosis surgery has a varying but high rate of complications. A medical indication for scoliosis surgery cannot be established in view of the lack of evidence found within this review. Long-term risks of scoliosis surgery have not yet been reported. Mandatory reporting for all spinal implants in a standardized way using a spreadsheet list of all recognized complications to reveal a 2-year, 5-year, 10-year and 20-year rate of complications should be established which may help develop a more clear indication for surgery and a more accurate account of the complications of surgery. Trials with untreated control groups in the field of scoliosis are unethical, when the control group is exposed to the risks of undergoing surgery.

Competing interests

The authors declare that they have no competing interests.

Authors' contributions

HRW manuscript writing, research of databases and Figures, DG manuscript writing, copyediting and research of databases. All authors read and approved the final manuscript.

Acknowledgements

Written informed consent was obtained from the patients for publication of their cases.

The authors wish to thank Dr. TB Grivas for providing the summaries of the Scoliosis Research Society Morbidity and Mortality Reports (2002 – 2005).

We also would like to thank Prof. Martha Hawes for providing the first extensive review on complications of scoliosis surgery [24] and the SOSORT scoliosis libraries, which have been extremely helpful for our work on this paper.

Many thanks to Lesley Schneider for proof reading and correcting the final manuscript.

References

1. Stokes IAF: **Three dimensional terminology of spinal deformity: A report presented to the Scoliosis research Society by**

- the Scoliosis Research Society Working Group on 3-D Terminology of Spinal Deformities. *Spine* 1994, **19**:236-248.
2. Cobb JR: **Outline for the study of scoliosis.** In *AAOS, Instructional Course Lectures Volume 5*. Edited by: Edwards JW. Ann Arbor: The American Academy of Orthopaedic Surgeons; 1948:261-75.
3. Kleinberg S: **The operative treatment of scoliosis.** *Arch Surg* 1922, **5**:631-645.
4. Asher MA, Burton DC: **Adolescent idiopathic scoliosis: natural history and long term treatment effects.** *Scoliosis* 1(1):2. 2006 Mar 31;
5. Hawes MC: **The use of exercises in the treatment of scoliosis: an evidence-based critical review of the literature.** *Pediatr Rehabil* 2003, **6(3-4)**:171-82.
6. Weiss HR, Negrini S, Hawes MC, Rigo M, Kotwicki T, Grivas TB, Maruyama T, members of the SOSORT: **Physical exercises in the treatment of idiopathic scoliosis at risk of brace treatment – SOSORT consensus paper 2005.** *Scoliosis* 1:6. 2006 May 11;
7. Weiss HR: **Rehabilitation of adolescent patients with scoliosis – what do we know? A review of the literature.** *Pediatr Rehabil* 2003, **6(3-4)**:183-94.
8. Moen KY, Nachemson AL: **Treatment of scoliosis: an historical perspective.** *Spine* 1999, **24**:2570-2575.
9. Hall JE: **Spinal surgery before and after Paul Harrington.** *Spine* 1998, **23**:1356-1361.
10. Bridwell KH: **Surgical treatment of AIS.** *Spine* 1999, **24**:2607-2616.
11. Shands AR, Barr JS, Colonna PC, Noall L: **End-result study of the treatment of idiopathic scoliosis.** *Report of the Research Committee of the American Orthopedic Association. Journal of Bone and Joint Surgery* 1941, **23-A**:963-99741.
12. Phipps HE: **The diagnosis of incipient IS.** *Journal of Bone and Joint Surgery* 1962, **44-1**:1489.
13. Renshaw TS: **Role of Harrington instrumentation and posterior spine fusion in the management of AIS.** *Orthopedic Clinics of North America* 1988, **19**:257-269.
14. Leatherman K, Dickson RA: **The management of spinal deformities.** London, Boston Singapore, Sydney, Toronto, Wellington: Wright Press; 1998.
15. Otani K, Saito M, Sibasaki K: **Anterior instrumentation in IS: a minimum followup of ten years.** *International Orthopedics* 1997, **21**:4-8.
16. Padua R, Padua S, Aulisa L, Ceccarelli E, Padua L, Romanini E, Zanoli G, Campi A: **Patient outcomes after Harrington instrumentation for IS; a 15–28 year evaluation.** *Spine* 2001, **26**:1268-1273.
17. Albers H, Hresko T, Carlson J, Hall JE: **Comparison of single and dual rod techniques for posterior spinal instrumentation in the treatment of AIS.** *Spine* 2000, **25**:1944-1949.
18. Perez-Grueso FS, Fernandez-Baillo N, de Robles SA, Fernandez AG: **The low lumbar spine below Cotrel-Dubouset instrumentation for IS; a 15–28 year evaluation.** *Spine* 2001, **25**:2333-2341.
19. Wenger DR, Mubarak SJ, Leach J: **Managing complications of posterior spinal instrumentation and fusion.** *Clin Orthop Relat Res* 1992, **284**:24-33.
20. Lonstein JE: **AIS.** *Lancet* 1994, **344**:1407-1412.
21. Stasikelis PF, Pugh LI, Allen BL: **Surgical correction in scoliosis: a meta-analysis.** *J Pediatr Orthop B.* 1998, **7-B(2)**:111-116.
22. Mohaideen A, Nagarkatti D, Banta JV, Foley CL: **Not all rods are Harrington – an overview of spinal instrumentation in scoliosis treatment.** *Pediatric Radiology* 2000, **30**:110-118.
23. Winter RB: **Innovation in surgical technique. The story of spine surgery.** *Clinical Orthopedics and Related Research* 2000, **378**:9-14.
24. Hawes M: **Impact of spine surgery on signs and symptoms of spinal deformity.** *Pediatr Rehabil* 2006, **9(4)**:318-39.
25. Transfeldt EE: **Complications of treatment.** In *Moe's textbook of scoliosis and other spinal deformities* 3rd edition. Edited by: Lonstein, J, Bradford D, Winter R, Oglivie J. Philadelphia, PA:W.B. Saunders; 1995:551-482.
26. Farley FA, Caird MS: **Pancreatitis after posterior spinal fusion for AIS.** *Journal of Spinal Disorders* 2001, **14**:268-270.
27. Mehta DI, Festa C, Dabney K: **Acute pancreatitis in children with idiopathic vs. neuromuscular scoliosis post surgical repair.** *Gastroenterology* 2001, **120**:3261-3263.
28. Roush TF, Crawford AH, Berlin RE, Wolf RK: **Tension pneumothorax as complication of video-assisted therscopic surgery**

- for anterior correction of IS in an adolescent female. *Spine* 2001, **26**:448-450.
29. Shapiro G, Green DW, Fatica NS, Boachie-Adjei O: **Medical complications in scoliosis surgery.** *Current Opinion in Pediatrics* 2001, **13**:36-41.
 30. Laplaza FJ, Weidmann RF, Fealy S, Moustafellos E, Illueca M, Burke SW, Boachie-Adjei O: **Pancreatitis after surgery in AIS: incidence and risk factors.** *Journal of Pediatric Orthopedics* 2002, **22**:80-83.
 31. Sucato DJ, Girgis M: **Bilateral pneumothoraces, pneumomediastinum, pneumoperitoneum, pneumoretro-peritoneum, and subcutaneous emphysema following intubation with a double-lumen endotracheal tube for thoracoscopic anterior spinal release and fusion in a patient with IS.** *Journal of Spinal Disorders & Techniques* 2002, **15**:133-138.
 32. Weissmann JS, Annas CL, Epstein AM: **Error reporting and disclosure systems. Views from hospital leaders.** *Journal of the American Medical Association* 2005, **293**:1359-1366.
 33. Bradford DS, Tay BK, Hu SS: **Adult scoliosis: surgical indications, operative management, complications and outcomes.** *Spine* 1999, **24**:2617-2629.
 34. Mielke CH, Lonstein JE, Denis F, Vandenbrink K, Winter RB: **Surgical treatment of AIS: a comparative analysis.** *Journal of Bone and Joint Surgery* 1989, **71-A**:1170-1177.
 35. Mc Donnell MF, Glassman SD, Dimar JR, Puno RM, Johnson JR: **Perioperative complications of anterior procedures on the spine.** *Journal of Bone and Joint Surgery* 1996, **76-A**:839-847.
 36. Tsiirikos AI, Chang WN, Dabney KW, Miller F, Glutting J: **Reduced life expectancy in pediatric patients with cerebral palsy and neuromuscular scoliosis who underwent spinal fusion.** *Developmental Medicine and Child Neurology* 2003, **45**:677-682.
 37. Rizzi PE, Winter RB, Lonstein JE, Denis F, Perra JH: **Adult spinal deformity and respiratory failure.** *Spine* 1997, **22**:2517-2531.
 38. Branthwaite MA: **Cardiopulmonary consequences of unfused IS.** *British Journal of Diseases of the Chest* 1986, **80**:360-369.
 39. Rittmeister M, Leyendecker K, Kruth A, Schmitt E: **Cauda equina compression due to a laminar hook: a late complication of posterior instrumentation in scoliosis surgery.** *European Spine Journal* 1999, **8**:417-420.
 40. Krodel A, Rehmert JC, Hamburger C: **Spinal cord compression caused by the rod of a Harrington instrumentation device: a late complication in scoliosis surgery.** *European Spine Journal* 1997, **6**:208-210.
 41. Mineiro J, Weinstein SL: **Delayed postoperative paraparesis in scoliosis surgery – a case report.** *Spine* 1997, **22**:1668-1672.
 42. Bridwell KH, Lenke LG, Baldus C, Blanke K: **Major intraoperative neurologic deficits in pediatric and adult spinal deformity patients. Incidence and etiology at one institution.** *Spine* 1998, **23**:324-331.
 43. Klemme WR, Burkhalter W, Polly DW, Dahl LF, Davis DA: **Reversible ischemic myelopathy during scoliosis surgery: a possible role for IV lidocaine.** *Journal of Pediatric Orthopedics* 1999, **19**:763-765.
 44. Mueller KL, Loder RT, Eggenberger ER, Farley FA: **Horner's syndrome after posterior spinal fusion in a child. A case report.** *Spine* 2000, **25**:2836-2837.
 45. Kluba T, Giehl JP: **A surprising case of paresis following scoliosis correction.** *Eur Spine J* 2001, **26(6)**:1495-1499.
 46. Takahashi S, Delecrin J, Passuti N: **Intraspinal metallosis causing delayed neurologic symptoms after spinal instrumentation surgery.** *Spine* 2001, **26**:1495-1499.
 47. Rose JB, Markowitz SD, Gundlapalli SP, Fishkin S, Ecker ML: **Posterior inferior cerebellar artery infarction: an unusual complication of posterior spinal fusion surgery in an adolescent with IS.** *Anesthesiology* 2004, **100**:1308-1310.
 48. Early SD, Kay RM, Maguire MF, Skaggs DL: **Delayed neurologic injury due to bone graft migration into the spinal canal following scoliosis surgery.** *Orthopedics* 2003, **26**:515-516.
 49. Papin P, Arlet V, Marchesi D, Rosenblatt B, Aebi M: **Unusual presentation of spinal cord compression related to misplaced pedicle screws in thoracic scoliosis.** *European Spine Journal* 1999, **8**:156-159.
 50. Bagchi K, Mohaideen A, Thomson JD, Foley LC: **Hardware complications in scoliosis surgery.** *Pediatric Radiology* 2002, **32**:465-475.
 51. Mooney JF, Bernstein R, Hennrikus WL, MacEwen GD: **Neurological risk management in scoliosis surgery.** *Journal of Pediatric Orthopedics* 2002, **22**:683-689.
 52. Eck KR, Bridwell KH, Ungacta FF, Riew KD, Lapp MA, Lenke LG, Baldus C, Blanke K: **Complications and results of long adult deformity fusions down to L4, L5 and the sacrum.** *Spine* 2001, **26**:E182-E192.
 53. Nilsson U: **Vertebral epiphyseodesis of the thoracic curve in the operative treatment of IS.** *Acta Orthopaedica Scandinavica* 1969, **40**:237-345.
 54. Moreland MS: **Outcome of scoliosis fusion-is stiff and straight better?** *Stud Health Technol Inform* 2002, **91**:492-497.
 55. Behensky H, Krismer M, Bauer R: **Comparison of spinal mobility after Harrington and Cotrel-Dubousset instrumentation.** *Journal of Spinal Disorders* 1998, **11**:155-162.
 56. Engsborg JR, Bridwell KH, Beitenbach AK, Ulrich ML, Baldus C, Blanke K, Lenke LG: **Preoperative gait comparisons between adults undergoing long spinal deformity fusion surgery.** *Spine* 2001, **26**:2020-2028.
 57. Goldberg CJ, Moore DP, Fogarty EE, Dowling FE: **The effect of brace treatment on incidence of surgery.** *Spine* 2001, **26**:42-47.
 58. Engsborg JR, Bridwell KH, Wagner JM, Uhrich ML, Blanke K, Lenke LG: **Gait changes as the result of deformity reconstruction surgery in a group of adults with lumbar scoliosis.** *Spine* 2003, **28**:1836-1844.
 59. Winter RB, Carr P, Mattson HL: **A study of functional spinal motion in women after instrumentation and fusion for deformity or trauma.** *Spine* 1997, **22**:1760-1764.
 60. Deviren V, Verven S, Kleinstueck F, Antinnes J, Smith JA, Hu SS: **Predictor of flexibility and pain patterns in thoracolumbar and lumbar IS.** *Spine* 2002, **27**:2346-2349.
 61. Morcuende JA, Arauz S, Weinstein SL: **Stress fracture of the hip and pubic rami after fusion to the sacrum in an adult with scoliosis: a case report.** *Iowa Orthopaedic Journal* 2000, **20**:79-84.
 62. Winter RB, Silverman BJ: **Degenerative spondylolisthesis at the L4-L5 in a 32-year-old female with previous fusion for IS: a case report.** *J Orthop Surg (Hong Kong)* 2003, **11(2)**:202-206.
 63. Fuchs PD, Styles B, Iwinski H, Pellet J: **Traumatic C6-C7 dislocation in a 14 year old with posterior spinal fusion for IS.** *Journal of Trauma, Injury, Infection, Critical Care* 2001, **51**:1004-1007.
 64. Cochran T, Irstam L, Nachemson A: **Long term anatomic and functional changes in patients with AIS treated by Harrington rod fusion.** *Spine* 1983, **8**:576-584.
 65. Burton DC, Asher MA, Lai SM: **Patient-based outcomes analysis of patients with single torsion thoracolumbar-lumbar scoliosis treated with anterior or posterior instrumentation. An average 5- to 9-year followup.** *Spine* 2002, **27**:2363-2367.
 66. Lenke LG, Engsborg JR, Ross SA, Reitenbach A, Blanke K, Bridwell KH: **Prospective dynamic functional evaluation of gait and spinal balance following spinal fusion in AIS.** *Spine* 2001, **26**:E330-E337.
 67. Cook S, Asher MA, Lai SM, Shobe J: **Reoperation after primary posterior instrumentation and fusion for idiopathic scoliosis, toward defining late operative site pain of unknown cause.** *Spine* 2000, **25**:463-468.
 68. Voos K, Boachie-Adjei O, Rawlins BA: **Multiple vertebral osteotomies in the treatment of rigid adult spine deformities.** *Spine* 2001, **26**:526-533.
 69. Islam NC, Wood KB, Transfeldt EE, Winter RB, Denis F, Lonstein JE, Ogilvie JW: **Extension of fusions to the pelvis in IS.** *Spine* 2001, **26**:166-173.
 70. Ginsburg HH, Goldstein LA, Robinson SC, Haake P, Devanny JR, Chan DPK, Suk S: **Back pain in postoperative IS. Long term follow-up study.** *Spine* 1979, **6**:518-523.
 71. Skaggs DL, Samuelson MA, Hale JM, Kay RM, Tolo VT: **Complications of posterior iliac crest bone grafting in spine surgery in children.** *Spine* 2000, **25**:2400-2402.
 72. Hatch RS, Sturm PF, Wellborn CC: **Late complication after single-rod instrumentation.** *Spine* 1998, **23**:1503-1505.
 73. Souttanis K, Mantelos G, Pagiatakis A, Soucacos PN: **Late infection in patients with scoliosis treated with spinal instrumentation.** *Clinical Orthopedics and Related Research*.
 74. Muschik M, Wiebke L, Schlenzka D: **Implant removal for late-developing infection after instrumental posterior spinal fusion for scoliosis: reinstrumentation reduces loss of correc-**

- tion. A retrospective analysis of 45 cases.** *European Spine Journal* 2004, **13**:645-651.
75. Clark CE, Shufflebarger HL: **Late developing infection in instrumental IS.** *Spine* 1999, **24**:1909-1913.
 76. Sponseller PD, LaPorte DM, Hungerford MW: **Deep wound infections after neuromuscular scoliosis surgery.** *Spine* 2000, **25**:2461-2466.
 77. Richards BS, Emara KM: **Delayed infections after posterior TSRH spinal instrumentation for IS. Revisited.** *Spine* 2001, **26**:1990-1996.
 78. Tribus CB, Garvey KE: **Full-thickness thoracic laminar erosion after posterior spinal fusion associated with late-presenting infection.** *Spine* 1995, **28**:E194-E197.
 79. Andersson DI: **Persistence of antibiotic resistant bacteria.** *Current Opinion in Microbiology* 2003, **6**:452-456.
 80. Gaine WJ, Andrew SM, Chadwick P, Cooke E, Williamson F, Bradley R: **Late operative site pain with Isola posterior instrumentation requiring implant removal: Infection or metal reaction.** *Spine* 2001, **26**:583-587.
 81. Vila RW, King HA, Adler S, Wilson CB: **Delayed infection after elective spinal instrumentation and fusion: a retrospective analysis of 8 cases.** *Spine* 1997, **22**:2444-2450.
 82. Nuttall GA, Horlocker TT, Santrach PJ, Oliver WC, Dekutoski MB, Bryant S: **Predictors of blood transfusions in spinal instrumentation and fusion surgery.** *Spine* 2000, **25**:596-601.
 83. Eastlund DJ: **Bone transplantation and bone banking.** In *Moe's textbook of scoliosis and other spinal deformities* 3rd edition. Edited by: Lonstein, J, Bradford D, Winter R, Oglivie J. Philadelphia, W.B. Saunders; 1995:581-594.
 84. **Enter for Disease Control. Epidemiologic notes and reports transmission of HIV through bone transplantation : case report and public health recommendations. Morbidity and Mortality.** *Weekly Report* 1988, **37**:597-599.
 85. Somonds RJ, Homberg SD, Hurwith RL, Coleman TR, Bottenfield S, Conley LJ, Kohlenberg SH, Castro KG, Dahan BA, Schable CA: **Transmission of HIV from seronegative organ and tissue donor.** *New England Journal of Medicine* 1992, **326**:726-732.
 86. Woolf SK, Gross RH: **Perceptions of allograft safety and efficacy among spinal deformity surgeons.** *Journal of Pediatric Orthopedics* 2001, **21**:767-771.
 87. Lonstein JE: **Idiopathic scoliosis.** In *Moe's textbook of scoliosis and other spinal deformities* 3rd edition. Edited by: Lonstein, J, Bradford D, Winter R, Oglivie J. Philadelphia, PA:W.B. Saunders; 1995:219-256.
 88. Swank S, Lonstein JE, Moe JH, Winter RB, Bradford DS: **Surgical treatment of adult scoliosis, a review of 222 cases.** *J Bone Joint Surg Am* 1981, **63-A(2)**:268-287.
 89. Rinella A, Bridwell K, Kim Y, Rudzki J, Edwards C, Roh M, Lenke L, Berra A: **Late complications of adult IS primary fusions to L4 and above.** *Spine* 2004, **29**:318-325.
 90. Lee CS, Nachemson AL: **The crankshaft phenomenon after posterior Harrington fusion in skeletally immature patients with thoracic or thoracolumbar IS followed to maturity.** *Spine* 1997, **22**:58-67.
 91. Roberto RE, Lonstein JE, Winter RB, Danis F: **Curve progression in Risser stage 0 or I patients after posterior spinal fusion for IS.** *Journal of Pediatric Orthopedics* 1997, **17**:718-725.
 92. Arlet V, Marchesi D, Papin P, Aebi M: **Decompensation following scoliosis surgery: treatment by decreasing the correction of the main thoracic curve or 'letting the spine go'.** *European Spine Journal* 2000, **9**:156-160.
 93. LaGrone MO: **Loss of lumbar lordosis; a complication of spinal fusion for scoliosis.** *Orthopedic Clinics of North America* 1988, **19**:383-393.
 94. Enli IT, Tuzuner M, Akalin S, Kis M, Aydin E, Taandogan R: **Spinal imbalance and decompensation problems in patients with Cotrel-Dubousset instrumentation.** *European Spine Journal* 1996, **5**:380-386.
 95. Lee GA, Betz RR, Clements DH, Huss GK: **Proximal kyphosis after posterior spinal fusion in patients with IS.** *Spine* 1999, **24**:795-799.
 96. D'Andrea L, Betz RR, Lenke L, Harms J, Clements DH, Lowe T: **The effect of continued posterior spinal growth on sagittal contour in patients treated by anterior instrumentation for IS.** *Spine* 2000, **25**:813-818.
 97. Bynd SH, Chen PQ: **Proximal kyphosis after short posterior fusion for thoracolumbar scoliosis.** *Clinical Orthopedics and Related Research* 2003, **411**:152.
 98. Van Ooij A, van Belle A, Timmer R, van Rhijn L: **The destroyed lung syndrome report of a case after Harrington rod instrumentation and fusion for IS.** *Spine* 2002, **27**:E337-E341.
 99. Wood KB, Transfeldt EE, Oglivie JW, Schendel MJ, Bradford DS: **Rotational changes of the vertebral-pelvic axis following Cotrel-Dubousset instrumentation.** *Spine* 1991, **16**:S404-S408.
 100. Wood KB, Schendel MJ, Dekutoski MB, Boachie-Adjei O, Heithoff KH: **Thoracic volume changes in scoliosis surgery.** *Spine* 1996, **21**:718-723.
 101. Wood KB, Olsewski J, Schendel M, Boachie-Adjei O, Gupta M: **Rotational changes of the vertebral pelvic axis safter sublaminar instrumentation in AIS.** *Spine* 1997, **22**:51-57.
 102. Pratt RK, Webb JK, Burwell RG, Cole AA: **Changes in surface and radiographic deformity after universal spine system for right thoracic adolescent IS. Is rib hump reassertion a mechanical problem of the thoracic rib cage rather than an effect of relative anterior spinal overgrowth?** *Spine* 2001, **26**:1778-1787.
 103. Barrett DS, MacLean JGB, Bettan J, Ransford AO, Edgar MA: **Costoplasty in AIS: objective results in 55 patients.** *Journal of Bone and Joint Surgery* 1993, **75-B**:881-885.
 104. Winter RB: **Flail chest secondary to excessive rib resection in IS: case report.** *Spine* 2002, **27**:668.
 105. Al-Binali AM, Sigalet D, Goldstein S, Al-Garni A, Robertson M: **Acute lower gastrointestinal bleeding as a late complication of spinal instrumentation.** *Journal of Pediatric Surgery* 2001, **26**:498-500.
 106. D'Souza R, Doshi A, Bhojraj S, Shetty P, Udawadia Z: **Massive pleural effusion as the presenting feature of a subarachnoid-pleural fistula.** *Respiration* 2002, **69**:96-99.
 107. Grossmann W, Ward WT: **Central retinal artery occlusion after scoliosis surgery with a horseshoe headrest.** *Spine* 1993, **18**:1226-1228.
 108. Hari JK, Zerlin JM, Cohen M, Kayes K, Rink RC: **Ureteral compression and obstruction by spine rods.** *Pediatric Radiology* 1998, **28**:115-116.
 109. Holland NR, Kostuik JP: **Continuous electromyographic monitoring to detect nerve root injury during thoracolumbar scoliosis surgery.** *Spine* 1997, **22**:2547-2550.
 110. Cummings RJ: **Recurrent meningitis secondary to infection after spinal arthrodesis with instrumentation.** *Journal of Bone and Joint Surgery* 1998, **80-A**:722-724.
 111. Zein NN, Perrault J, Camilleri M: **Recurrent vomiting following Harrington rod instrumentation of the spine.** *Journal of Pediatric Gastroenterology and Nutrition* 1995, **22**:318-320.
 112. Hokama A, Tomiyama R, Kishimoto K, Kinjo F, Saito A, Matayoshi M: **Chronic intermittent vomiting after scoliosis surgery.** *Gut* 2004, **53**:222.
 113. Kennedy RH, Cooper MJ: **An unusually severe case of the cast syndrome.** *Postgraduate Medical Journal* 1983, **59**:539-540.
 114. Vitale MG, Higgs GB, Liebling MS, Roth N, Roye DP: **Superior mesenteric artery syndrome after segmental instrumentation: a biomechanical analysis.** *American Journal of Orthopedics* 1999, **28**:461-467.
 115. Lonstein JE: **Salvage and reconstructive surgery.** In *Moe's textbook of scoliosis and other spinal deformities* 3rd edition. Edited by: Lonstein, J, Bradford D, Winter R, Oglivie J. Philadelphia, PA: W.B. Saunders; 1995:387-398.
 116. Neyt JG, Weinstein SL: **Fracture-dislocation of the lumbar spine after arthrodesis with instrumentation for IS.** *J Bone Joint Surg Am* 1999, **81-A(1)**:111-114.
 117. Nana A, Gugala Z, Lindsey RW, Caram PM, Dickson JH: **Bending of the Cotrel-Dubousset instrumentation after direct trauma: a case report.** *Spine* 2000, **25**:891-894.
 118. Bago J, Ramirez M, Pellise F, Villanueva C: **Survivorship analysis of Cotrel-Dubousset instrumentation in IS.** *European Spine Journal* 2003, **12**:435-439.
 119. Verven SH, Kao H, Deviren V, Bradford D: **Management of thoracic pseudarthrosis in the adult: is combined surgery necessary?** *Proceedings, Scoliosis Research Society 36th Annual Meeting, Cleveland OH* 2001.
 120. Deckey JE, Court C, Bradford DS: **Loss of sagittal plane correction after removal of spinal implants.** *Spine* 2000, **25**:2453-2460.
 121. Weinstein SL, Dolan LA, Spratt KF, Peterson KK, Spoonamore MJ, Ponseti IV: **Health and function of patients with untreated id-**

- opathic scoliosis: A 50 year natural history study. *JAMA* 2003, **289**:559-567.
122. Dolan LA, Weinstein SL: **Surgical rates after observation and bracing for adolescent idiopathic scoliosis: an evidence-based review.** *Spine* **32(19 Suppl)**:S91-S100. 2007 Sep 1;
 123. Dolan LA, Donnelly MJ, Spratt KF, Weinstein SL: **Professional opinion concerning the effectiveness of bracing relative to observation in adolescent idiopathic scoliosis.** *J Pediatr Orthop* 2007, **27(3)**:270-6.
 124. Goldberg CJ, Moore DP, Fogarty EE, Dowling FE: **Scoliosis: a review.** *Pediatr Surg Int* . 2007 Sep 22.
 125. Weiss HR, Weiss G, Petermann F: **Incidence of curvature progression in idiopathic scoliosis patients treated with scoliosis in-patient rehabilitation (SIR): an age- and sex-matched controlled study.** *Pediatr Rehabil* 2003, **6**:23-30.
 126. Nachemson AL, Peterson LE: **Effectiveness of treatment with a brace in girls who have adolescent idiopathic scoliosis. A prospective, controlled study based on data from the Brace Study of the Scoliosis Research Society.** *J Bone Joint Surg Am* 1995, **77(6)**:815-22.
 127. Danielsson AJ, Hasselius R, Ohlin A, Nachemson AL: **A prospective study of brace treatment versus observation alone in adolescent idiopathic scoliosis: a follow-up mean of 16 years after maturity.** *Spine* **32(20)**:2198-207. 2007 Sep 15;
 128. **Oxford Centre for Evidence-based Medicine Levels of Evidence 2001** [<http://www.cebm.net/?o=1011>].
 129. Weiss HR: **Is there a body of evidence for the treatment of patients with Adolescent Idiopathic Scoliosis (AIS)?** *Scoliosis* 2007, **2**:19. 31st December 2007
 130. Weiss HR: **Adolescent Idiopathic Scoliosis – case report of a patient with clinical deterioration after surgery.** *Patient Safety in Surgery* 2007, **1**:7. 19th December 2007
 131. Weiss HR: **Adolescent Idiopathic Scoliosis – an indication for surgery? A systematic review.** *Disabil Rehabil* 2008, **30(10)**:799-807.
 132. Weiss HR, Goodall D: **Treatment of Adolescent Idiopathic Scoliosis (AIS) according to present evidence. A systematic review.** *Eur J Phys Rehabil Med* 2008, **44(2)**:177-93.
 133. Weiss HR, Bohr S: **Conservative Treatment in patients with scoliosis due to Prader Willi Syndrome.** *Proceedings of the 5th. International Conference on Conservative Management of Spinal Deformities, Athens* . April 3rd – 5th 2008.
 134. Weiss HR: **Conservative treatment in patients with severe congenital scoliosis – presentation of three cases.** *Proceedings of the 5th. International Conference on Conservative Management of Spinal Deformities, Athens* . April 3rd – 5th 2008.
 135. Carreon LY, Puno RM, Lenke LG, Richards BS, Sucato DJ, Emans JB, Erickson MA: **Non-neurologic complications following surgery for adolescent idiopathic scoliosis.** *J Bone Joint Surg Am* 2007, **89(11)**:2427-32.
 136. **SOSORT scoliosis library** [<http://www.sosort.org/documents/scoliosislibrary.pdf>]
 137. **SOSORT scoliosis library (update 2007)** [<http://www.sosort.org/documents/scoliosislibrary2007.pdf>]
 138. Ko AL, Song K, Ellenbogen RG, Avellino AM: **Retrospective review of multilevel spinal fusion combined with spinal cord transection for treatment of kyphoscoliosis in pediatric myelomeningocele patients.** *Spine* **32(22)**:2493-501. 2007 Oct 15;
 139. Mohamad F, Parent S, Pawelek J, Marks M, Bastrom T, Faro F, Newton P: **Perioperative complications after surgical correction in neuromuscular scoliosis.** *J Pediatr Orthop* 2007, **27(4)**:392-7.
 140. Schmelzer-Schmied N, Ochs BG, Carstens C, Lill CA: **[Experience in operations for scoliosis in patients with cerebral palsy].** *Z Orthop Ihre Grenzgeb* 2006, **144(3)**:322-7.
 141. Teli MG, Cinnella P, Vincitorio F, Lovi A, Grava G, Brayda-Bruno M: **Spinal fusion with Cotrel-Dubouset instrumentation for neuropathic scoliosis in patients with cerebral palsy.** *Spine* **31(14)**:E441-7. 2006 Jun 15;
 142. Edwards BT, Zura R, Bertrand S, Leonard S, Pellett J: **Treatment of neuromuscular scoliosis with posterior spinal fusion using the Galveston technique: a retrospective review and results of 62 patients.** *J Long Term Eff Med Implants* 2003, **13(6)**:437-44.
 143. Wild A, Sella K, Jäger M, Raab P, Krauspe R: **[One- or two-step instrumentation for thoracolumbar scoliosis due to myelomeningocele?].** *Z Orthop Ihre Grenzgeb* 2003, **141(1)**:59-64.
 144. Sarwahi V, Sarwark JF, Schafer MF, Backer C, Lee M, King EC, Aminian A, Grayhack JJ: **Standards in anterior spine surgery in pediatric patients with neuromuscular scoliosis.** *J Pediatr Orthop* 2001, **21(6)**:756-60.
 145. Banit DM, Iwinski HJ Jr, Talwalkar V, Johnson M: **Posterior spinal fusion in paralytic scoliosis and myelomeningocele.** *J Pediatr Orthop* 2001, **21(1)**:117-25.
 146. Arlet V: **Anterior thoracoscopic spine release in deformity surgery: a meta-analysis and review.** *Eur Spine J* 2000, **9(Suppl 1)**:17-23.
 147. Sponseller PD, Young AT, Sarwark JF, Lim R: **Anterior only fusion for scoliosis in patients with myelomeningocele.** *Clin Orthop Relat Res* 1999:117-24.
 148. Stella G, Ascani E, Cervellati S, Bettini N, Scarsi M, Vicini M, Magillo P, Carbone M: **Surgical treatment of scoliosis associated with myelomeningocele.** *Eur J Pediatr Surg* 1998, **8(Suppl 1)**:22-5.
 149. Benson ER, Thomson JD, Smith BG, Banta JV: **Results and morbidity in a consecutive series of patients undergoing spinal fusion for neuromuscular scoliosis.** *Spine* **23(21)**:2308-17. 1998 Nov 1;
 150. Matsumura T, Kang J, Nozaki S, Takahashi MP: **[The effects of spinal fusion on respiratory function and quality of life in Duchenne muscular dystrophy].** *Rinsho Shinkeigaku* 1997, **37(2)**:87-92.
 151. Frischhut B, Sterzinger W, Rachbauer F, Klestil T, Krismir M, Bauer R: **Surgical treatment of neuropathic scoliosis: morphologic and functional outcome.** *Arch Orthop Trauma Surg* 1997, **116(6-7)**:367-72.
 152. Ramirez N, Richards BS, Warren PD, Williams GR: **Complications after posterior spinal fusion in Duchenne's muscular dystrophy.** *J Pediatr Orthop* 1997, **17(1)**:109-14.
 153. Shapiro F, Sethna N, Colan S, Wohl ME, Specht L: **Spinal fusion in Duchenne muscular dystrophy: a multidisciplinary approach.** *le Nerve* 1992, **15(5)**:604-14.
 154. Banta JV: **Combined anterior and posterior fusion for spinal deformity in myelomeningocele.** *Spine* 1990, **15(9)**:946-52.
 155. Brown JC, Zeller JL, Swank SM, Furumasu J, Warath SL: **Surgical and functional results of spine fusion in spinal muscular atrophy.** *Spine* 1989, **14(7)**:763-70.
 156. Boachie-Adjei O, Lonstein JE, Winter RB, Koop S, vanden Brink K, Denis F: **Management of neuromuscular spinal deformities with Luque segmental instrumentation.** *J Bone Joint Surg Am* 1989, **71(4)**:548-62.
 157. Brown JC, Swank S, Specht L: **Combined anterior and posterior spine fusion in cerebral palsy.** *Spine* 1982, **7(6)**:570-3.
 158. Gui L, Savini R, Vicenzi G, Ponzio L: **Surgical treatment of poliomyelitic scoliosis.** *Ital J Orthop Traumatol* 1976, **2(2)**:191-205.
 159. Gayet LE: **[Surgical treatment of scoliosis due to Duchenne muscular dystrophy].** *Chirurgie* 1999, **124(4)**:423-31.
 160. Chataigner H, Grelet V, Onimus M: **[Surgery of the spine in Duchenne's muscular dystrophy].** *Rev Chir Orthop Reparatrice Appar Mot* 1998, **84(3)**:224-30.
 161. Glassman SD, Hamill CL, Bridwell KH, Schwab FJ, Dimar JR, Lowe TG: **The impact of perioperative complications on clinical outcome in adult deformity surgery.** *Spine* **32(24)**:2764-70. 2007 Nov 15;
 162. Cho KJ, Suk SI, Park SR, Kim JH, Kim SS, Choi WK, Lee KY, Lee SR: **Complications in posterior fusion and instrumentation for degenerative lumbar scoliosis.** *Spine* **32(20)**:2232-7. 2007 Sep 15;
 163. Pateder DB, Kebaish KM, Cascio BM, Neubaer P, Matusz DM, Kostuik JP: **Posterior only versus combined anterior and posterior approaches to lumbar scoliosis in adults: a radiographic analysis.** *Spine* **32(14)**:1551-4. 2007 Jun 15;
 164. Pateder DB, Park YS, Kebaish KM, Cascio BM, Buchowski JM, Song EW, Shapiro MB, Kostuik JP: **Spinal fusion after revision surgery for pseudarthrosis in adult scoliosis.** *Spine* **31(11)**:E314-9. 2006 May 15;
 165. Ali RM, Boachie-Adjei O, Rawlins BA: **Functional and radiographic outcomes after surgery for adult scoliosis using third-generation instrumentation techniques.** *Spine* **28(11)**:1163-9. 2003 Jun 1; discussion 1169-70.
 166. Emami A, Deviren V, Berven S, Smith JA, Hu SS, Bradford DS: **Outcome and complications of long fusions to the sacrum in adult spine deformity: luque-galveston, combined iliac and sacral screws, and sacral fixation.** *Spine* **27(7)**:776-86. 2002 Apr 1;

167. Lapp MA, Bridwell KH, Lenke LG, Daniel Riew K, Linville DA, Eck KR, Ungacta FF: **Long-term complications in adult spinal deformity patients having combined surgery a comparison of primary to revision patients.** *Spine* 26(8):973-83. 2001 Apr 15;
168. Simmons ED Jr, Kowalski JM, Simmons EH: **The results of surgical treatment for adult scoliosis.** *Spine* 1993, 18(6):718-24.
169. Boachie-Adjei O, Dendrinios GK, Ogilvie JW, Bradford DS: **Management of adult spinal deformity with combined anterior-posterior arthrodesis and Luque-Galveston instrumentation.** *Spinal Disord* 1991, 4(2):131-41.
170. Kostuik JP, Hall BB: **Spinal fusions to the sacrum in adults with scoliosis.** *Spine* 1983, 8(5):489-500.
171. Diab M, Smith AR, Kuklo TR, Spinal Deformity Study Group: **Neural complications in the surgical treatment of adolescent idiopathic scoliosis.** *Spine* 32(24):2759-63. 2007 Nov 15
172. Muschik MT, Kimmich H, Demmel T: **Comparison of anterior and posterior double-rod instrumentation for thoracic idiopathic scoliosis: results of 141 patients.** *Eur Spine J* 2006, 15(7):1128-38. Epub 2006 Feb 10.
173. Coe JD, Arlet V, Donaldson W, Berven S, Hanson DS, Mudiyan R, Perra JH, Shaffrey CI: **Complications in spinal fusion for adolescent idiopathic scoliosis in the new millennium. A report of the Scoliosis Research Society Morbidity and Mortality Committee.** *Spine* 31(3):345-9. 2006 Feb 1;
174. Remes V, Helenius I, Schlenzka D, Yrjönen T, Ylikoski M, Poussa M: **Cotrel-Dubousset (CD) or Universal Spine System (USS) instrumentation in adolescent idiopathic scoliosis (AIS): comparison of mid-term clinical, functional, and radiologic outcomes.** *Spine* 29(18):2024-30. 2004 Sep 15;
175. Asher M, Lai SM, Burton D, Manna B, Cooper A: **Safety and efficacy of Isola instrumentation and arthrodesis for adolescent idiopathic scoliosis: two- to 12-year follow-up.** *Spine* 29(18):2013-23. 2004 Sep 15;
176. Götzte C, Slomka A, Götzte HG, Pözl W, Liljenqvist U, Steinbeck J: **[Long-term results of quality of life in patients with idiopathic scoliosis after Harrington instrumentation and their relevance for expert evidence].** *Z Orthop Ihre Grenzgeb* 2002, 140(5):492-8.
177. Benli IT, Akalin S, Kis M, Citak M, Kurtulus B, Duman E: **The results of anterior fusion and Cotrel-Dubousset-Hopf instrumentation in idiopathic scoliosis.** *Eur Spine J* 2000, 9(6):505-15.
178. Weis JC, Betz RR, Clements DH 3rd, Balsara RK: **Prevalence of perioperative complications after anterior spinal fusion for patients with idiopathic scoliosis.** *J Spinal Disord* 1997, 10(5):371-5.
179. Humke T, Grob D, Scheier H, Siegrist H: **Cotrel-Dubousset and Harrington Instrumentation in idiopathic scoliosis: a comparison of long-term results.** *Eur Spine J* 1995, 4(5):280-3.
180. O'Neill JA, Engler GL: **Evaluation of spinous process wire fixation with Harrington instrumentation for idiopathic scoliosis.** *J Spinal Disord* 1988, 1(3):211-8.
181. Kaneda K, Fujiya N, Satoh S: **Results with Zielke instrumentation for idiopathic thoracolumbar and lumbar scoliosis.** *Clin Orthop Relat Res* 1986:195-203.
182. Ayyaz M, Alanay A, Yazici M, Acaroglu E, Akalan N, Aksoy C: **Safety and efficacy of posterior instrumentation for patients with congenital scoliosis and spinal dysraphism.** *J Pediatr Orthop* 2007, 27(4):380-6.
183. Benli IT, Duman E, Akalin S, Kiçik M, Aydin E, Un A: **[An evaluation of the types and the results of surgical treatment for congenital scoliosis].** *Acta Orthop Traumatol Turc* 2003, 37(4):284-98.
184. Shono Y, Abumi K, Kaneda K: **One-stage posterior hemivertebra resection and correction using segmental posterior instrumentation.** *Spine* 26(7):752-7. 2001 Apr 1;
185. Kahanovitz N, Brown JC, Bonnett CA: **The operative treatment of congenital scoliosis. A report of 23 patients.** *Clin Orthop Relat Res* 1979:174-82.
186. Akbarnia BA, Marks DS, Boachie-Adjei O, Thompson AG, Asher MA: **Dual growing rod technique for the treatment of progressive early-onset scoliosis: a multicenter study.** *Spine* 30(17 Suppl):46-57. 2005 Sep 1;
187. Coran DL, Rodgers WB, Keane JF, Hall JE, Emans JB: **Spinal fusion in patients with congenital heart disease. Predictors of outcome.** *Clin Orthop Relat Res* 1999:99-107.
188. Hod-Feins R, Abu-Kishk I, Eshel G, Barr Y, Anekstein Y, Mirovsky Y: **Risk factors affecting the immediate postoperative course in pediatric scoliosis surgery.** *Spine* 32(21):2355-60. 2007 Oct 1;
189. Guigui P, Blamoutier A, Groupe d'Etude de la Scoliose: **[Complications of surgical treatment of spinal deformities: a prospective multicentric study of 3311 patients].** *Rev Chir Orthop Reparatrice Appar Mot* 2005, 91(4):314-27.
190. Chen H, Qiu Y, Wang B, Yu Y, Zhu ZZ, Zhu LH: **Autogenous tibial strut grafts used in severe kyphoscoliosis: surgical policies and preliminary results.** *Chin Med J (Engl)* 118(15):1245-50. 2005 Aug 5;
191. McDonnell MF, Glassman SD, Dimar JR 2nd, Puno RM, Johnson JR: **Perioperative complications of anterior procedures on the spine.** *J Bone Joint Surg Am* 1996, 78(6):839-47.
192. Liu SL, Huang DS: **Scoliosis in China. A general review.** *Clin Orthop Relat Res* 1996:113-8.
193. Michel CR: **[Neurologic complications of surgery for spinal deformities].** *Chirurgie* 1995, 120(11):1994-36.
194. Carlizo H, Ouaknine M: **[Neurologic complications of surgery of the spine in children].** *Chirurgie* 1995, 120(11):1994-26.
195. Michel F, Rubini J, Grand C, Bérard J, Kohler R, Michel CR: **[Neurological complications of surgery for spinal deformities].** *Rev Chir Orthop Reparatrice Appar Mot* 1992, 78(2):90-100.
196. Floman Y, Micheli LJ, Penny JN, Riseborough EJ, Hall JE: **Combined anterior and posterior fusion in seventy-three spinally deformed patients: indications, results and complications.** *Clin Orthop Relat Res* 1982:110-22.
197. Duhaime M, Labelle P, Lebel M, Simoneau R, Poitras B, Rivard CH, Marton D: **[Treatment of idiopathic scoliosis by the Harrington technique. Experience from the Ste-Justine Hospital, Montreal].** *Chir Pediatr* 1982, 23(1):17-22.
198. Richards BS, Hasley BP, Casey VF: **Repeat surgical interventions following "definitive" instrumentation and fusion for idiopathic scoliosis.** *Spine* 31(26):3018-26. 2006 Dec 15;
199. Lehman RA Jr, Lenke LG, Keeler KA, Kim YJ, Cheh G: **Computed tomography evaluation of pedicle screws placed in the pediatric deformed spine over an 8-year period.** *Spine* 32(24):2679-84. 2007 Nov 15;
200. Yingsakmongkol W, Hangsaphuk N, Lerdlam S: **The accuracy of pedicle screw placement in thoracic spine using the Funnel technique in idiopathic scoliosis.** *J Med Assoc Thai* 2007, 90(1):96-105.
201. Liljenqvist UR, Halm HF, Link TM: **Pedicle screw instrumentation of the thoracic spine in idiopathic scoliosis.** *Spine* 22(19):2239-45. 1997 Oct 1;
202. Yu B, Zhang JG, Qiu GX, Wang YP, Yang XY: **Video-assisted thoracoscopic correction and fusion of scoliosis.** *Chin Med Sci J* 2007, 22(3):144-51.
203. Bomback DA, Charles G, Widmann R, Boachie-Adjei O: **Video-assisted thoracoscopic surgery compared with thoracotomy: early and late follow-up of radiographical and functional outcome.** *Spine J* 2007, 7(4):399-405. Epub 2007 Feb 5.
204. Lonner BS, Kondrachov D, Siddiqi F, Hayes V, Scharf C: **Thoracoscopic spinal fusion compared with posterior spinal fusion for the treatment of thoracic adolescent idiopathic scoliosis. Surgical technique.** *J Bone Joint Surg Am* 2007, 89(Suppl 2 Pt. 1):142-56.
205. Picetti GD 3rd, Pang D, Bueff HU: **Thoracoscopic techniques for the treatment of scoliosis: early results in procedure development.** *Neurosurgery* 2002, 51(4):978-84.
206. Roush TF, Crawford AH, Berlin RE, Wolf RK: **Tension pneumothorax as a complication of video-assisted thoracoscopic surgery for anterior correction of idiopathic scoliosis in an adolescent female.** *Spine* 26(4):448-50. 2001 Feb 15;
207. Betz RR, Kim J, D'Andrea LP, Mulcahey MJ, Balsara RK, Clements DH: **An innovative technique of vertebral body stapling for the treatment of patients with adolescent idiopathic scoliosis: a feasibility, safety, and utility study.** *Spine* 28(20):255-65. 2003 Oct 15;
208. Kim YJ, Bridwell KH, Lenke LG, Rhim S, Cheh G: **Pseudarthrosis in long adult spinal deformity instrumentation and fusion to the sacrum: prevalence and risk factor analysis of 144 cases.** *Spine* 31(20):2329-36. 2006 Sep 15;
209. Benli IT, Ates B, Akalin S, Citak M, Kaya A, Alanay A: **Minimum 10 years follow-up surgical results of adolescent idiopathic sco-**

- liosis patients treated with TSRH instrumentation. *Eur Spine J* 2007, **16**(3):381-91.
210. Sweet FA, Lenke LG, Bridwell KH, Blanke KM, Whorton J: **Prospective radiographic and clinical outcomes and complications of single solid rod instrumented anterior spinal fusion in adolescent idiopathic scoliosis.** *Spine* **26**(18):1956-65. 2001 Sep 15;
 211. Marchesi DG, Aebi M: **Pedicle fixation devices in the treatment of adult lumbar scoliosis.** *Spine* 1992, **17**(8 Suppl):304-9.
 212. Osebold WR, Mayfield JK, Winter RB, Moe JH: **Surgical treatment of paralytic scoliosis associated with myelomeningocele.** *J Bone Joint Surg Am* 1982, **64**(6):841-56.
 213. Michel CR, Onimus M, Kohler R: **[The Dwyer operation in the surgical treatment of scoliosis].** *Rev Chir Orthop Reparatrice Appar Mot* 1977, **63**(3):237-55.
 214. Majd ME, Castro FP Jr, Holt RT: **Anterior fusion for idiopathic scoliosis.** *Spine* **25**(6):696-702. 2000 Mar 15;
 215. Beguiristain J, del Rio J, Duarte J, Barros J, Silva A, Villas C: **Corrosion and late infection causing delayed paraparesis after spinal instrumentation.** *J Pediatr Orthop B* 2006, **15**(5):320-3.
 216. Thompson AG, Marks DS, Sayampanathan SR, Piggott H: **Long-term results of combined anterior and posterior convex epiphysiodesis for congenital scoliosis due to hemivertebrae.** *Spine* **20**(12):1380-5. 1995 Jun 15;
 217. Marks DS, Sayampanathan SR, Thompson AG, Piggott H: **Long-term results of convex epiphysiodesis for congenital scoliosis.** *Eur Spine J* 1995, **4**(5):296-301.
 218. Bollini G, Docquier PL, Viehweger E, Launay F, Jouve JL: **Thoracolumbar hemivertebrae resection by double approach in a single procedure: long-term follow-up.** *Spine* **31**(15):1745-57. 2006 Jul 1;
 219. Lazar RD, Hall JE: **Simultaneous anterior and posterior hemivertebra excision.** *Clin Orthop Relat Res* 1999:76-84.
 220. Winter RB, Lonstein JE: **Congenital scoliosis with posterior spinal arthrodesis T2-L3 at age 3 years with 41-year follow-up. A case report.** *Spine* **24**(2):194-7. 1999 Jan 15;
 221. Winter RB, Lonstein JE: **Congenital thoracic scoliosis with unilateral unsegmented bar and concave fused ribs: rib osteotomy and posterior fusion at 1 year old, anterior and posterior fusion at 5 years old with a 36-year follow-up.** *Spine* **32**(26):E841-4. 2007 Dec 15;
 222. Hasenboehler EA, Choudhry IK, Newman JT, Smith WR, Ziran BH, Stahel PF: **Bias towards publishing positive results in orthopedic and general surgery: a patient safety issue?** *Patient Safety in Surgery* 2007, **1**:4. 27 November 2007
 223. Danielsson AJ: **What impact does spinal deformity correction for adolescent idiopathic scoliosis make on quality of life?** *Spine* **32**(19 Suppl):S101-8. 2007 Sep 1;
 224. Watanabe K, Hasegawa K, Hirano T, Uchiyama S, Endo N: **Evaluation of postoperative residual spinal deformity and patient outcome in idiopathic scoliosis patients in Japan using the scoliosis research society outcomes instrument.** *Spine* **32**(5):550-4. 2007 Mar 1;
 225. Andersen MO, Christensen SB, Thomsen K: **Outcome at 10 years after treatment for adolescent idiopathic scoliosis.** *Spine* **31**(3):350-4. 2006 Feb 1;
 226. Weigert KP, Nygaard LM, Christensen FB, Hansen ES, Bunker C: **Outcome in adolescent idiopathic scoliosis after brace treatment and surgery assessed by means of the Scoliosis Research Society Instrument 24.** *Eur Spine J* 2006, **15**(7):1108-17.
 227. Watanabe K, Hasegawa K, Hirano T, Uchiyama S, Endo N: **Use of the scoliosis research society outcomes instrument to evaluate patient outcome in untreated idiopathic scoliosis patients in Japan: part I: comparison with non-scoliosis group: preliminary/limited review in a Japanese population.** *Spine* **30**(10):1197-201. 2005 May 15;
 228. Niemeier T, Bovingloh AS, Grieb S, Schaefer J, Halm H, Kluba T: **Low back pain after spinal fusion and Harrington instrumentation for idiopathic scoliosis.** *Int Orthop* 2005, **29**(1):47-50.
 229. Padua R, Ceccarelli E, Aulisa AG, Pitta L, Aulisa L: **Outcome of Harrington surgery for idiopathic scoliosis. SF-36 and Roland questionnaires assessment.** *Stud Health Technol Inform* 2002, **88**:404.
 230. Rinella A, Lenke L, Peelle M, Edwards C, Bridwell KH, Sides B: **Comparison of SRS questionnaire results submitted by both parents and patients in the operative treatment of idiopathic scoliosis.** *Spine* **29**(3):303-10. 2004 Feb 1;
 231. Merola AA, Haheer TR, Brkaric M, Panagopoulos G, Mathur S, Kohani O, Lowe TG, Lenke LG, Wenger DR, Newton PO, Clements DH 3rd, Betz RR: **A multicenter study of the outcomes of the surgical treatment of adolescent idiopathic scoliosis using the Scoliosis Research Society (SRS) outcome instrument.** *Spine* **27**(18):2046-51. 2002 Sep 15;
 232. Wilson PL, Newton PO, Wenger DR, Haheer T, Merola A, Lenke L, Lowe T, Clements D, Betz R: **A multicenter study analysing the relationship of a standardized radiographic scoring system of adolescent idiopathic scoliosis and the Scoliosis Research Society outcomes instrument.** *Spine* **27**(18):2036-40. 2002 Sep 15;
 233. Asher M, Min Lai S, Burton D, Manna B: **The reliability and concurrent validity of the scoliosis research society-22 patient questionnaire for idiopathic scoliosis.** *Spine* **28**(1):63-9. 2003 Jan 1;
 234. Götze C, Slomka A, Götze HG, Potzl W, Liljenqvist U, Steinbeck J: **[Long-term results of quality of life in patients with idiopathic scoliosis after Harrington instrumentation and their relevance for expert evidence].** *Z Orthop Ihre Grenzgeb* 2002, **140**(5):492-8.
 235. Götze C, Liljenqvist UR, Slomka A, Götze HG, Steinbeck J: **Quality of life and back pain: outcome 16.7 years after Harrington instrumentation.** *Spine* **27**(13):1456-63. discussion 1463-4. 2002 Jul 1;
 236. Pratt RK, Burwell RG, Cole AA, Webb JK: **Patient and parental perception of adolescent idiopathic scoliosis before and after surgery in comparison with surface and radiographic measurements.** *Spine* **27**(14):1543-50. 2002 Jul 15;
 237. Koch KD, Buchanan R, Birch JG, Morton AA, Gatchel RJ, Browne RH: **Adolescents undergoing surgery for idiopathic scoliosis: how physical and psychological characteristics relate to patient satisfaction with the cosmetic result.** *Spine* **26**(19):2119-24. 2001 Oct 1;
 238. Sweet FA, Lenke LG, Bridwell KH, Blanke KM, Whorton J: **Prospective radiographic and clinical outcomes and complications of single solid rod instrumented anterior spinal fusion in adolescent idiopathic scoliosis.** *Spine* **26**(18):1956-65. 2001 Sep 15;
 239. Padua R, Padua S, Aulisa L, Ceccarelli E, Padua L, Romanini E, et al.: **Patient outcomes after Harrington instrumentation for idiopathic scoliosis: a 15- to 28-year evaluation.** *Spine* **26**(11):1268-73. 2001 Jun 1;
 240. White SF, Asher MA, Lai SM, Burton DC: **Patients' perceptions of overall function, pain, and appearance after primary posterior instrumentation and fusion for idiopathic scoliosis.** *Spine* **24**(16):1693-9. 1999 Aug 15;
 241. Haheer TR, Gorup JM, Shin TM, Homel P, Merola AA, Grogan DP, Pugh L, Lowe TG, Murray M: **Results of the Scoliosis Research Society instrument for evaluation of surgical outcome in adolescent idiopathic scoliosis. A multicenter study of 244 patients.** *Spine* **24**(14):1435-40. 1999 Jul 15;
 242. Moses S, Last U, Mahler D: **After aesthetic rhinoplasty: new looks and psychological outlooks on post-surgical satisfaction.** *Aesthetic Plast Surg* 1984, **8**(4):213-7.
 243. Crigger NJ, Meek VL: **Toward a theory of self-reconciliation following mistakes in nursing practice.** *J Nurs Scholarsh* 2007, **39**(2):177-83.
 244. Kitayama S, Snibbe AC, Markus HR, Suzuki T: **Is there any "free" choice? Self and dissonance in two cultures.** *Psychol Sci* 2004, **15**(8):527-33.
 245. Simmons VN, Webb MS, Brandon TH: **College-student smoking: an initial test of an experiential dissonance-enhancing intervention.** *Addict Behav* 2004, **29**(6):1129-36.
 246. Stone J: **Self-consistency for low self-esteem in dissonance processes: the role of self-standards.** *Pers Soc Psychol Bull* 2003, **29**(7):846-58.
 247. Haheer TR, Merola A, Zipnick RI, Gorup J, Mannor D, Orchowski J: **Meta-analysis of surgical outcome in adolescent idiopathic scoliosis. A 35-year English literature review of 11,000 patients.** *Spine* **20**(14):1575-84. 1995 Jul 15;
 248. Smith PL, Donaldson S, Hedden D, Alman B, Howard A, Stephens D, Wright JG: **Parents' and patients' perceptions of postoperative appearance in adolescent idiopathic scoliosis.** *Spine* **31**(20):2367-74. 2006 Sep 15;

249. Sponseller PD, Cohen MS, Nachemson AL, Hall JE, Wohl ME: **Results of surgical treatment of adults with idiopathic scoliosis.** *J Bone Joint Surg Am* 1987, **69(5)**:667-75.
250. Dickson JH, Erwin WD, Rossi D: **Harrington Instrumentation and Arthrodesis for Idiopathic Scoliosis: A twenty-one year follow-up.** *J Bone Joint Surg Am* 1990, **72**:678-683.
251. **Health care purchasing news – Controlling conflicts of interest** [<http://www.hpnonline.com/inside/2006-05/HPNOnline.com-%20Clinical%20Business%20Strategies%20-%200605.html>]
252. **The New York Times – Medtronic to Pay \$1.35 Billion to Inventor** [<http://www.nytimes.com/2005/04/23/business/23medtronic.html?ex=1271908800&en=f2b6a791c937140a&ei=5090&partner=rssuserland&emc=rss>]
253. **The New York Times – The Spine as Profit Center** [http://www.nytimes.com/2006/12/30/businessspine.html?_r=1&page-wanted=1&ei=5070&en=736f736c5e853a2f&ex=1177560000&ores_login]
254. Kotwicki T, Kinel E, Stryla W, Szulc A: **Estimation of the stress related to conservative scoliosis therapy: an analysis based on BSSQ questionnaires.** *Scoliosis* 2007, **2**:1. 3 January 2007

Publish with **BioMed Central** and every scientist can read your work free of charge

"BioMed Central will be the most significant development for disseminating the results of biomedical research in our lifetime."

Sir Paul Nurse, Cancer Research UK

Your research papers will be:

- available free of charge to the entire biomedical community
- peer reviewed and published immediately upon acceptance
- cited in PubMed and archived on PubMed Central
- yours — you keep the copyright

Submit your manuscript here:
http://www.biomedcentral.com/info/publishing_adv.asp

