

Versatility of a single upper border miniplate to treat mandibular angle fractures: A clinical study

Access this article online

Website:

www.amsjournal.com

DOI:

10.4103/2231-0746.92784

Quick Response Code:



P. Satish Kumaran, Lalitha Thambiah¹

Consultant Maxillofacial Surgeon, ¹Consultant Dental Surgeon, Department of Oral and Maxillofacial Surgery, Annaswamy Mudaliar General Hospital, Bourdillon Road, Off M. M. Road, Bangalore - 560005, India

Address for correspondence:

Dr. Satish Kumaran P, Consultant Maxillofacial Surgeon, #1 Moore Market Square, Bourdillon Road, Off M. M. Road, Fraser Town, Bangalore, Karnataka - 560 005, India.
E-mail: arcott21@yahoo.com

ABSTRACT

Context: Mandibular fractures are among the most common of facial fractures. Fractures of the mandibular angle are associated with the highest incidence of postsurgical infection of all mandibular fractures. The treatment of facial fractures has traditionally involved reestablishment of a functional dental occlusion with various types of intermaxillary fixation. Treatment modalities range from simple maxillo-mandibular fixation to rigid internal fixation of the bone fragments. **Aims:** The aim of this study was to determine the versatility of the single noncompression miniplate to treat the fractures of the mandibular angle with access via an intraoral route. **Materials and Methods:** Cases of unfavorable fractures of the mandibular angle were selected for the study of intraoral surgical management of mandibular angle fractures using a single 2.0-mm noncompression miniplate. **Statistical Analysis and Results:** An observational study was carried out on treatment of fractures of the angle of the mandible, and the findings were recorded and presented. **Conclusions:** We studied the versatility of the single noncompression miniplate to treat the fractures of the mandibular angle and found no complications associated with superior border miniplate fixation of mandibular angle fractures.

Keywords: Angle fractures, intraoral, miniplate

INTRODUCTION

Mandibular fractures are among the most common of facial fractures. They may be the result of falls, road traffic accidents, and interpersonal violence or may even be caused as complications of tooth extraction among other factors.

Any treatise on mandibular fractures must be opened first with a discussion of the history of mandible fractures and the evolution of treatment. Writings on mandible fractures appeared as early as 1650 B.C. when an Egyptian (Edwin Smith) papyrus described the examination, diagnosis, and treatment of mandible fractures. Hippocrates then described the use of circumdental wires and external bandaging. In 1180, a Latin book from Salerno in Italy first described the importance of gaining proper occlusion. *Cirurgia* in 1492 mentioned use of maxillomandibular fixation. In 1795, Chopart and Desault described the use of elevator and depressor muscles on mandible fragments. In 1819, John Rhea

Barton described his Barton bandage. In 1866, Gunning described his Gunning splint.

Fractures of the mandibular angle are associated with the highest incidence of postsurgical infection of all mandibular fractures due to the biomechanics of mandibular function.

The main focus of mandibular fracture treatment is surgical repositioning and internal skeletal fixation. The healing complications to be analyzed are infection in the fracture line and malocclusion.^[1]

The treatment of facial fractures has traditionally involved reestablishment of a functional dental occlusion with various types of intermaxillary fixation. Patients treated with intermaxillary fixation have a restricted airway, loose excess weight, and are more vulnerable to the sequelae of postoperative hemorrhage

and edema. Also, intermaxillary fixation for 8 weeks may cause marked thinning and disruption of the normal organization of the articular cartilage.^[2]

Treatment modalities range from simple maxillomandibular fixation to rigid internal fixation of the bone fragments.

During the past decade, the surgical treatment of mandibular fractures has advanced significantly. Rigid internal fixation and early return to function have replaced the use of wire osteosynthesis and prolonged use of maxillomandibular fixation. The use of miniplates has regained acceptance.^[3]

The four revised principles of the AO/ASIF (1994) are as follows:

- 1) Anatomic reduction
- 2) Functionally stable fixation (previously "rigid fixation")
- 3) Atraumatic surgical technique
- 4) Immediate active function^[4]

Rigid internal fixation of mandibular fractures eliminates the need for intermaxillary fixation and facilitates stable anatomic reduction while reducing the risk of postoperative displacement of the fractured fragments, allowing immediate return to function.^[5]

The advantages of a transoral approach with miniplates include less risk of facial nerve damage and formation of hypertrophic scar, ease of adaptation, ability to confirm occlusion during surgery, and early mobilization of the patient and are also less likely to be palpable because of their smaller size and thinner profile.

Removal of the plate is also easier as it may be performed in the outpatient setup.^[4] Only teeth in the line of injury that are sufficiently mobile, have root exposure in markedly distracted fractures, or interfere with either reduction or fixation of fractures are extracted.^[6]

Studies prove that rigid internal fixation with miniplates and screws provide a cost-effective means of handling mandible fractures in our patient population. Rigid fixation is associated with rapid bone healing by primary intention, which reduces the risk of infection by reduced mobility of the fracture and absence of pseudoarthrosis, excellent stabilization at the fracture site, and increased postoperative three-dimensional stability. Less potential for relapse and elimination or shortening of the intermaxillary period of immobilization results in early and complete restoration of function.^[7]

The aim of this study was to determine the versatility of the single noncompression miniplate to treat the fractures of the mandibular angle.

MATERIALS AND METHODS

The study was conducted in the Department of Oral and Maxillofacial Surgery, Annaswamy Mudaliar General Hospital, Bangalore, between August 2005 and January 2011.

A total of 29 cases of unfavorable fractures of the mandibular angle were selected for the study of intraoral surgical management of mandibular angle fractures using a single 2.0-mm noncompression

miniplate.

In all cases, thorough preoperative evaluation was done and the patients were admitted as inpatients and treated. Orthopantomographs were the radiographic investigation of choice for all patients.

ARMAMENTARIUM

Miniplate Specifications

The dimensions and composition of the miniplates and screws used in this study are as follows:

Plates Composition – Stainless Steel

- a. Length: 26 mm
- b. Thickness: 2.0 mm

Screws Composition – Stainless Steel

- a. Type: noncompression, self-tapping monocortical screws with round head
- b. Diameter: 2 mm
- c. Thread length: 6 mm screws (closer to root area)
8 mm screws (away from root area)

Drill Bit Composition – tungsten carbide

- a. Diameter: 1.7 mm
- b. Type: straight, cross cut

Handpiece

- a. RPM: 25,000-30,000 rpm
- b. Type: micromotor
- c. Design: Straight
- d. Coolant used: external saline irrigation

Plating kit

- a. Plate holding forceps
- b. Reduction forceps (towel clip type)
- c. Screw holder
- d. Screw driver
- e. Plate bending forceps

SURGICAL TECHNIQUE

Reduction and fixation of unfavorable mandibular angle fracture through intraoral approach

The surgical procedure was done under aseptic conditions under general anesthesia and nasoendotracheal intubation, except for one case where submental intubation was preferred because of inability to intubate nasally.

The placement of IMF was deferred with in all except in two cases where the operating surgeon decided to use Ivy Loops and in two cases where arch bars were placed in another center and were used intraoperatively.

After infiltration with 2% Xylocaine with Adrenaline, the incision was placed intraorally, with the cutting cautery, over the external oblique ridge starting from the distal aspect of second molar and extending over the ascending ramus posteriorly about 1 cm superior to occlusal plane. A mucoperiosteal flap is reflected along

the superior and lateral aspect of the mandible taking care to preserve the integrity of the lingual mucoperiosteum. A Howarth or Ward's periosteal elevator was used to raise the full-thickness mucoperiosteal flap and fracture site was exposed.

In eight cases the third molar was extracted as the fracture line had extended through the tooth to vertically fracture it or horizontally to fracture one root.

The fracture was either reduced manually by the assisting surgeon and held into place with occlusion established or as mentioned previously in four cases after reduction occlusion was maintained through the use of Ivy Loops or arch bars and IMF.

A four-hole noncompression plate was adapted along the medial side of the external oblique ridge. The plate was contoured and adapted with plate bending forceps and held in position with either the plate holding forceps or with a pair of mosquito forceps.

The first drill hole was placed closest to the fracture site on the distal fragment using 2-mm bur and copious amounts of saline irrigation. The plate was stabilized with a 2-mm stainless steel screw. The second hole was placed on the closest to the fracture anteriorly and stabilized as mentioned previously. The other two

holes were similarly placed and stabilized.

The first two holes were stabilized with 6-mm long screws to prevent trauma to the molars and the outer screws were 8 mm long.

The occlusion and alignment of the fracture line were checked and the screws tightened. If IMF had been placed, it was removed. The wound was irrigated with normal saline and the wound was approximated with 3-0 Vicryl. None of the patients were placed on postoperative.

All the patients were discharged on the third active postoperative day. Antibiotics were maintained for 5 days postoperatively.

All patients were advised soft diet and given oral hygiene instructions.

Follow-up period was for a maximum of 3 months with review being done at 5 days, 15 days, 1 month, and 3 months with instructions to report to the department if the patient had problems [Figures 1-5].

STATISTICAL ANALYSIS AND RESULTS

In our study, 29 cases were treated for angle fracture in our hospital during 2005 to 2010. Assaults and road traffic accidents were the most common etiological factors as observed in our study. The angle fracture on the left side was found to be slightly more common than the right side. Preoperatively cross bite was present in all cases. 59% of the cases had associated parasymphysis fractures and 3% had associated zygomatic complex and zygomatic arch fractures. 35% of the cases had no associated fractures [Figure 6].

Intraoperatively, a four-hole noncompression plate was adapted along the medial side of the external oblique ridge. All surgeries were performed by single surgeon. Postoperatively, the Neurological complications were observed in three cases (10%) such as paraesthesia and anesthesia. Infection of the operative site was observed in three cases (10%) Miniplate removal was done only in one case (3%) and the other cases were treated by

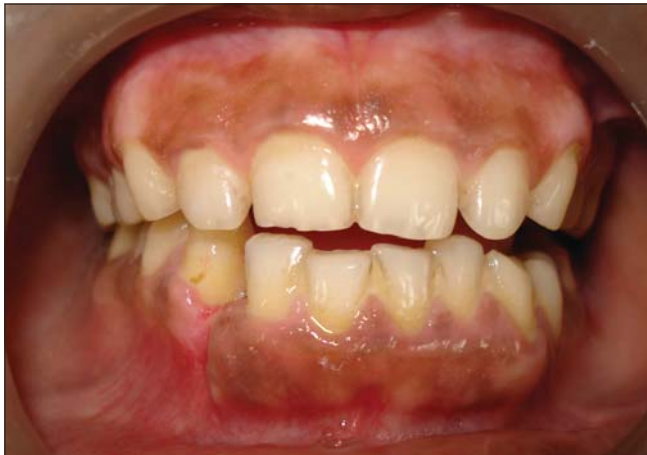

Figure 1: Preoperative deranged occlusion

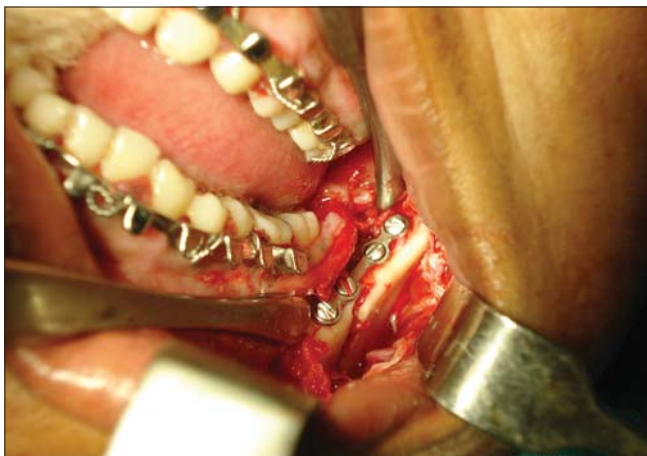

Figure 2: Plate Fixation

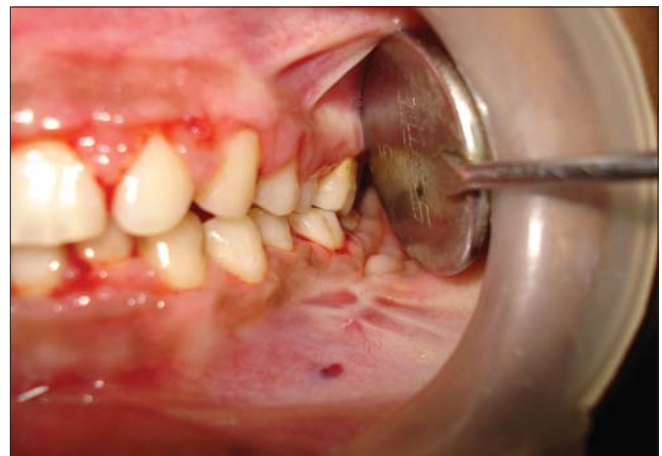

Figure 3: Postoperative Occlusion

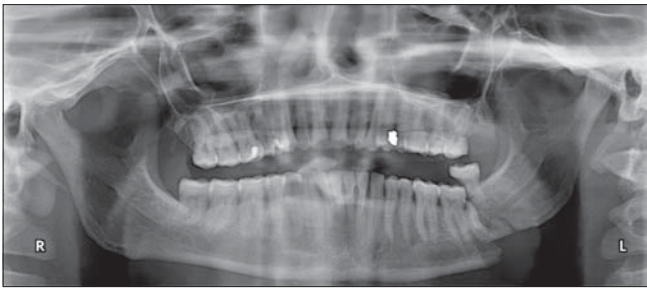


Figure 4: Preoperative radiograph

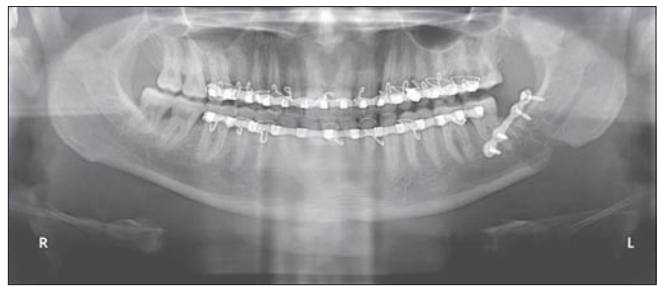


Figure 5: Postoperative radiograph

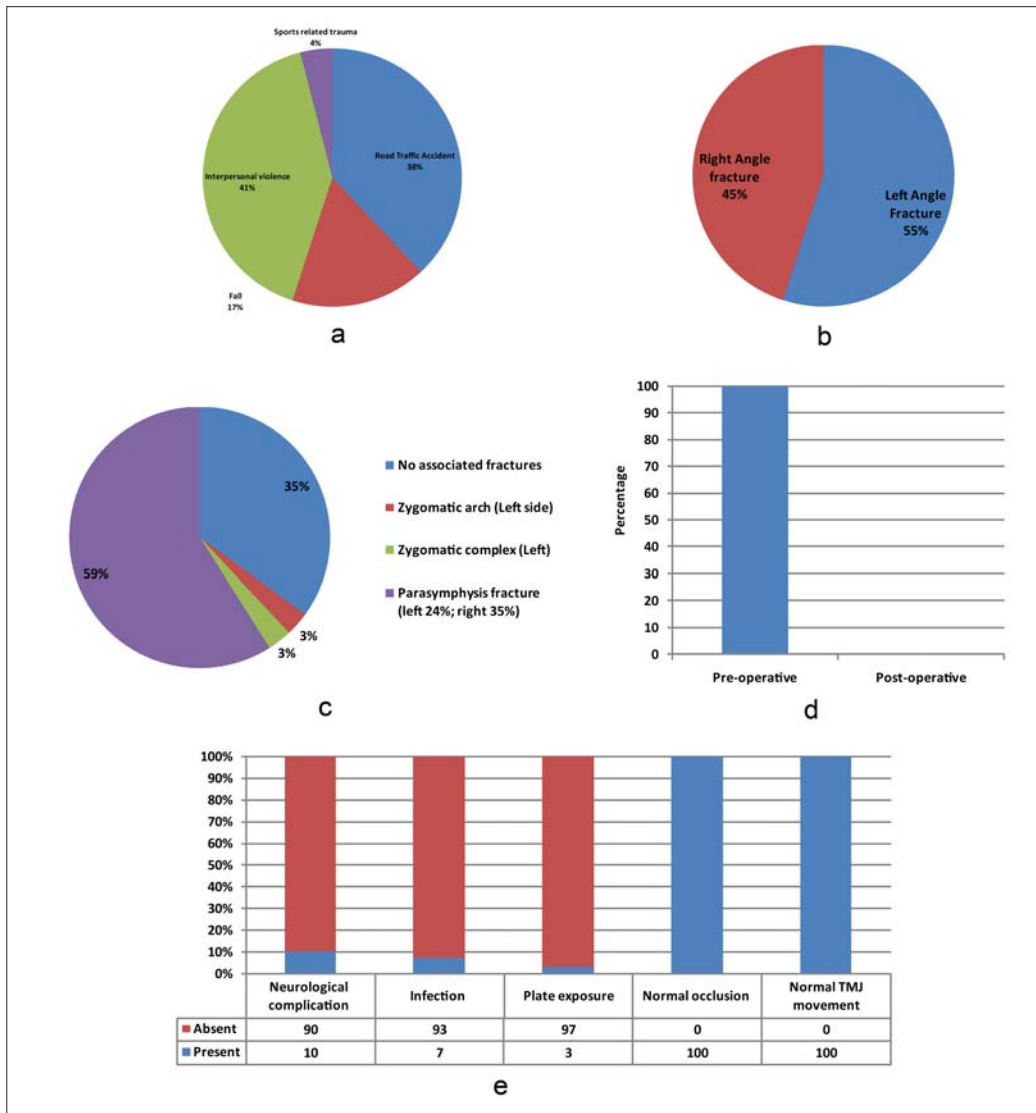


Figure 6: (a) Distribution of study population based on etiology fracture (b) Side of the angle fracture (c) Distribution of associated fracture (d) Preoperative and postoperative cross bites (e) Distribution of postoperative outcomes of the study population

antibiotics and irrigation. Plate exposure was observed in one case (3%). We have achieved good occlusion and TMJ movements in all cases (100%) [Figure 6].

An observational study was carried out on treatment of fractures of the angle of the mandible and the findings were recorded and presented.

DISCUSSION

The methods of treatment of angle fractures are as follows:

1. Closed reduction
2. Open reduction:
 - a. Rigid
 - b. Nonrigid fixation

- c. External fixation
- d. Internal fixation

The methods of rigid internal fixation are solitary miniplate osteosynthesis, solitary lag screw osteosynthesis, miniplate osteosynthesis, Dynamic Compression Plates (AO/ASIF principles), and AO reconstruction plate.

An importance of classification of mandibular fractures relates to dissection of the fracture line and effect of muscle action on the fracture fragments. Thus, fractures may be classified as:

- a. Vertically favorable or unfavorable
- b. Horizontally favorable or unfavorable

Muscles attached to the ramus masseter, temporal and medial pterygoid displace the proximal segment upward and medially when the fractures are unfavourable; conversely these same muscles tend to impact the bone, minimizing displacement in horizontal and vertical favorable fractures. Fonseca *et al.*^[8] have mentioned these facts.

Choi *et al.*^[9] showed that two-miniplate fixation technique provides better stability compared with Champy's method. Ellis III^[10] in his article on AO reconstruction plates mentions the complications of the extraoral scar through which the plate is inserted. The possibility of injury to the marginal mandibular branch of facial nerve is high. Scolozzi *et al.*^[11] report that with comminuted fractures the surgeon must perform an osteosynthesis capable of supporting full functional load and reinitializing tension forces while maintaining fractures fragments in anatomic position. This is not possible by any technique, except AO reconstruction plate.

Compression plates according to AO/ASIF principle have an inherent set of disadvantages.

The bicortical screws used cause sensory disturbances along path of inferior alveolar nerve in many cases.

Postoperative malocclusion rates are also high which attributed to the difficulties in bending the rigid plate.

The transoral approach provides inadequate access to allow correct reduction and immobilization.

After reviewing the pros and cons of all the available techniques of open reduction and internal fixation, we decided to concentrate on the use solitary of miniplate superior border osteosynthesis as per Champy's technique to treat noncomminuted angle fractures.

In the early 1970s, Champy *et al.*^[12] proposed the intraoral application of monocortical miniplates to treat mandibular angle fractures. They showed that miniplates achieved the goal of osteosynthesis by neutralizing undesirable tensile forces while retaining favorable compressive forces during function. They determined the ideal line of osteosynthesis is where the miniplate fixation is most stable.

Following Champy's method, 29 cases of mandibular angle fractures were treated in our department with ORIF. All cases

were done under GA. An incision design as suggested by Gerard *et al.*^[13] was adopted.

Minimum amount of periosteum was stripped off, as the periosteum also serves to preserve the fracture hematoma which if upset is one of the factors that may lead to improper or late bony union. Laing^[14] and Schierle *et al.*^[15] showed that one of the dangers is the unnecessary stripping of periosteum and consequent devascularization of the bone.

The use of intraoperative IMF was used only in four cases in our study.

Dimitroulis *et al.*^[16] and Fordyce *et al.*^[17] in their articles mention the advantages of using a free hand technique to reduce and stabilize mandibular fractures before fixation. The operating time is decreased, leading to decreased cost to patient.

Also the damage caused by wire ligatures to teeth as mentioned by Lello *et al.*^[18] on the gingiva, periodontium and the tooth are avoided.

In all cases, except four, no intraoperative IMF was used and the fracture was manually reduced and held in position by the senior most surgeon (consultant) while the junior surgeon or postgraduate trainee did the fixation with plates and screws.

In keeping with Champy's principles, the four-hole miniplate was adapted and placed along the buccal shelf of external oblique ridge. Champy *et al.*^[12] studied these movements with regard to a mathematical model of the mandible and as a result was able to determine the ideal line of osteosynthesis to overcome these displacing forces. By placing the plate at the most biomechanically favorable site, the thickness of the plate can be kept to a minimum with consequent advantage of increased malleability. The small size of the plate insures that only a minimal mucoperiosteal flap need be raised on the buccal and labial aspect. Thus, major blood supply to mandible is preserved because integrity of periosteal attachment along the lingual aspect and inferior border of mandible is not disturbed.

The number of screws, the length of the screws, the size of plate, and the location of plate in angle fracture treatment have a direct bearing on the functional load that can be carried.

Assael^[19] concluded that 2.7-mm diameter screws with 2-mm thickness plate held great functional load.

In all our cases we used, 2-mm four-hole plate and gap and 2 mm × 6 mm plate screws for holes closer to the tooth and 2 mm × 8 mm screws for holes away from the tooth.

In common with Ellis,^[20] Champy,^[12] and Cawood^[21] no postoperative IMF of any kind was used.

Only one patient in our study developed any postoperative occlusal discrepancy, but as he was satisfied completely with the wholly functional occlusal outcome, no adjunctive intermaxillary fixation was placed. All patients were asked to maintain soft diet and strict oral hygiene instructions were given.

Ellis^[4,20] states that complications associated with miniplate fixation, though usually less severe and minor, are nevertheless present.

In our study, one patient presented with plate infection (but at the parasymphysis). The region was treated with normal saline irrigation and no antibiotics were administered. The same patient also complained of paraesthesia at the parasymphyseal region and was the only one to undergo plate removal.

One other patient reported with complaint of anesthesia, again at parasymphyseal region, but this resolved within 6 months. No plate removal was done here.

There is much controversy regarding the tooth in the line of fracture. In our study, only teeth that were fractured were extracted. In accordance with Ellis,^[22] third molars in line of fracture, which were fractured vertically, were extracted.

Our study agrees with Zachariades *et al.*,^[23] who said that miniplate fixation is a precise technique that requires more time and stated that the occlusion should be exact to the millimeter before plating is commenced.

The results of our study failed to agree with that of Nakamura *et al.*^[24] who found in his study that miniplates used to treat fractures are plagued with a high complication rate. Also, in all cases except one, which was not angle plating, plate removal was not done in any other case. Our study found no complications associated with superior border miniplate fixation of mandibular angle fractures.

CONCLUSION

We would like to conclude by saying that use of a single miniplate in the upper border could be considered as a definitive treatment plan for angle fractures. Although similar studies have been reported in the literature, there are still controversies regarding the line of treatment for angle fracture such as location of the plates, number of plates to be used, and the approach to be employed. Therefore, the study at this juncture would be an invaluable tool for the surgeon to decide an appropriate treatment plan. Although 29 cases is a small number, the results we have obtained are significant and further study in this direction is warranted.

REFERENCES

1. Hermund NU, Hillerup S, Kofod T, Schwartz O, Andreasen JO. Effect of early or delayed treatment upon healing of mandibular fractures: A systemic literature review. *Dent Traumatol* 2008;24:22-6.
2. Brown JS, Grew N, Taylor C, Miller BG. Intermaxillary fixation compared to miniplate osteosynthesis in management of the fractured mandible – An audit. *Br J Oral Maxillofac Surg* 1991;29:308-11.

3. Benninger MS, Gupta N, Gilmore K. Intraoperative infectious disease exposure to otolaryngology operating room personnel. *Laryngoscope* 1991;101:1276-9.
4. Ellis E 3rd. Treatment methods for fractures of the mandibular angle. *Int J Oral Maxillofac Surg* 1999;28:243-52.
5. Marcantonio G, Viera H. Fixation of mandibular fractures with 2.0 mm miniplates: Review of 191 cases. *J Oral Maxillofac Surg* 2003;61:430-6.
6. Chuong R, Donoff RB, Guralnick WC. A retrospective analysis of 327 mandibular fractures. *J Oral Maxillofac Surg* 1983;41:305-9.
7. Souyris F, Lamarche JP, Mirfakhrai AM. Treatment of mandibular fractures by intraoral placement of bone plates. *J Oral Surg* 1980;38:33-5.
8. Fonseca RJ, Walker RW, Betts NJ, Barber HD. *Oral and Maxillofacial Trauma* 3rd Edition, Volume 1, 2005:487-490
9. Choi BH, Kim KN, Kang HS. Clinical and *in vitro* evaluation of mandibular angle fractures fixation with the two-miniplate system. *Oral Surg Oral Med Oral Pathol Oral Radiol Endod* 1995;79:692-5.
10. Ellis E 3rd. Treatment of mandibular angle fractures using the AO reconstruction plate. *J Oral Maxillofac Surg* 1993;51:250-4.
11. Scolozzi P, Richter M. Treatment of severe mandibular fractures using AO reconstruction plates. *J Oral Maxillofac Surg* 2003;61:458-61.
12. Champy M, Lodde JP, Schmidt R, Jaeger JH, Muster D. Mandibular osteosynthesis by miniature screwed plates via a buccal approach. *J Oral Maxillofac Surg* 1978;6:14-21.
13. Gerard N, D'Innocenzo R. Modified technique for adapting a mandibular angle superior border plate. *J Oral Maxillofac Surg* 1995;53:220-1.
14. Laing PG. Problems in the use of metals as surgical implants. *J Dent Res* 1966;45:1660-1.
15. Schierle HP, Schmelzlen R, Rahn B, Pytik C. One or two plate fixation of mandibular angle fractures? *J Craniomaxillofac Surg* 1997;25:162-8.
16. Dimitroulis G. Management of fractured mandibles without use of intermaxillary fixation. *J Oral Maxillofac Surg* 2002;60:1435-8.
17. Fordyce AM, Lalani Z, Songra AK, Carton AT, Hawkesford JE. Intermaxillary fixation is not usually necessary to reduce mandibular fractures. *Br J Oral Maxillofac Surg* 1999;37:52-7.
18. Lello JL, Lello GE. The effect of interdental continuous loop wire splinting and intermaxillary fixation on the marginal gingival. *Int J Oral Maxillofac Surg* 1988;17:249-52.
19. Assael L. Evaluation of rigid internal fixation of mandibular fractures performed in the teaching laboratory. *J Oral Maxillofac Surg* 1993;51:1315-9.
20. Ellis E 3rd, Walker LR. Treatment of mandibular angle fractures using one non-compression miniplate. *J Oral Maxillofac Surg* 1996;54:864-71.
21. Cawood JL. Small plate osteosynthesis of mandibular fractures. *Br J Oral Maxillofac Surg* 1985;23:77-91.
22. Ellis E 3rd. Outcomes of patients with teeth in the line of mandibular angle fractures treated with stable internal fixation. *J Oral Maxillofac Surg* 2002;60:863-5.
23. Zachariades N, Mezitis M, Rallis G. An audit of mandibular fractures treated by intermaxillary fixation, intraosseous wiring and compression plating. *Br J Oral Maxillofac Surg* 1996;34:293-7.
24. Nakamura S, Takenoshita Y, Oka M. Complications of miniplate osteosynthesis for mandibular fractures. *J Oral Maxillofac Surg* 1980;52:233-8.

Cite this article as: Kumaran PS, Thambiah L. Versatility of a single upper border miniplate to treat mandibular angle fractures: A clinical study. *Ann Maxillofac Surg* 2011;1:160-5.

Source of Support: Nil, **Conflict of Interest:** None declared.