

# Neurodegeneration with Brain Iron Accumulation

Amit Batla<sup>1,2,3</sup>, Chandana Gaddipati<sup>4,5</sup>

<sup>1</sup>Honorary Consultant Neurologist, National Hospital for Neurology and Neurosurgery, Queen Square, <sup>2</sup>Department of Clinical and Movement Neuroscience, UCL Queen Square Institute of Neurology, <sup>3</sup>Consultant Neurologist, Luton and Dunstable University Hospital, NHS Foundation Trust, Luton, United Kingdom, <sup>4</sup>Consultant Neurologist, St Joseph's Hospital, <sup>5</sup>Consultant Neurologist, Vanita Vaidysala, Guntur, Andhra Pradesh, India

## Abstract

The term NBIA encompasses a heterogeneous group of inherited disorders characterized clinically by progressive extra pyramidal syndrome and pathologically by excessive iron deposition in brain, primarily affecting the basal ganglia (globus pallidus mainly). The hallmark of this syndrome is the age specific phenotypic presentation and intraphenotypic heterogeneity. NBIA's at present include ten subtypes with genes identified in nine subtypes. They form an important differential diagnosis for the phenotype of global developmental delay in infancy/childhood to dystonia-parkinsonism or isolated parkinsonism at all ages and also for the isolated craniocervical dystonia of adult onset. There needs to be a high index of clinical suspicion for this syndrome and the evaluation includes MRI brain T2\* weighted imaging which reveal symmetrical iron deposition in bilateral globus pallidi and other basal ganglia. The T2\* imaging pattern of iron deposition varies amongst the different subtypes and the combination of clinical phenotype and MRI signature makes it easier to confidently make a diagnosis of NBIA and to recommend genetic testing. The treatment to date is mostly symptomatic with targeted therapies on the horizon.

**Keywords:** NBIA, global developmental delay, dystonia parkinsonism, parkinsonism

## INTRODUCTION

Pathological accumulation of iron in basal ganglia or other areas of brain has been known to be associated with a progressive disorder of nervous system since 1920s.<sup>[1]</sup> Hallervorden–Spatz disease was in common usage for several decades. Due to advances in science that have unmasked several underlying genetic mutations in patients with brain iron accumulation<sup>[2]</sup> and also because of the links of Julius Hallervorden and Hugo Spatz Nazi Germany in 1920s, this has been replaced by neurodegeneration with brain iron accumulation (NBIA).<sup>[2-4]</sup> NBIA are a heterogeneous group of genetically determined disorders that are characterized by iron deposition in several brain areas including basal ganglia manifesting with a progressive, extrapyramidal symptoms<sup>[1]</sup> (dystonia, parkinsonism, chorea), sometimes with pyramidal signs, cognitive dysfunction, or ocular abnormalities.

NBIA's demonstrate wide heterogeneity in the phenotype, not only between subtypes but also among a given subtype. NBIA's are “ultrare” with a prevalence of <1/1,000,000 affected<sup>[2]</sup> but remain a differential diagnoses in both pediatric and adult-onset neurodegenerative diseases, and most neurologists or pediatric consultants will possibly encounter a handful of cases in their lifetime. It can be a difficult condition to diagnose and this article reviews current understanding of NBIA's to help clinicians with diagnosis and management of NBIA's.

## HOW TO DIAGNOSE?

The diagnosis of NBIA requires the following: (1) identification of the phenotypes that are associated with NBIA, (2) magnetic resonance imaging (MRI) brain [with iron detecting sequences

T2\*/susceptibility-weighted imaging (SWI)/gradient recalled echo] demonstrating deposition of iron in basal ganglia with or without white matter changes on T2-weighted imaging, and (3) genetic testing for identification of specific subtype of the disease.

## GENETICS OF NBIA

Several clearly defined and undefined genetic defects/mutations can lead to NBIA [Table 1]. Historically, PANK2 was first to be identified,<sup>[3]</sup> but over the past 2 decades, several conditions have been identified that manifest with NBIA. Since 2004, aceruloplasminemia (described in 1987, gene identified in 2000) and neuroferritinopathy (identified in 2001) have been included in NBIA.<sup>[5]</sup> Seitelberger disease, also called infantile neuroaxonal dystrophy, was later renamed as PLA2G6-associated neurodegeneration (PLAN) is caused by mutations in phospholipase A2 gene.<sup>[6]</sup> Causative pathogenic mutation for Woodhouse–Sakati syndrome was identified as c2orf37 mutation (also called as DCAF17 mutation) in 2008.<sup>[7]</sup> The invention of high-field MRI in 1980s and later addition of sequences that could identify iron deposition in

**Address for correspondence:** Dr. Amit Batla,  
UCL Queen Square Institute of Neurology, Queen Square,  
London WC1N 3BG, United Kingdom.  
E-mail: a.batla@ucl.ac.uk

This is an open access journal, and articles are distributed under the terms of the Creative Commons Attribution-NonCommercial-ShareAlike 4.0 License, which allows others to remix, tweak, and build upon the work non-commercially, as long as appropriate credit is given and the new creations are licensed under the identical terms.

**For reprints contact:** reprints@medknow.com

**DOI:** 10.4103/aian.AIAN\_481\_18

**Table 1: The current OMIM classification of NBIA**

NBIA subtype	Genetic mutation	Inheritance
NBIA 1 (pantothenate kinase-associated neurodegeneration)	PANK2	Autosomal recessive
NBIA 2 (PLA2G6-associated neurodegeneration)		
2a (infantile neuroaxonal dystrophy)	PLA2G6	Autosomal recessive
2b (atypical neuroaxonal dystrophy, Karak syndrome)	PLA2G6	Autosomal recessive
NBIA 3 (neuroferritinopathy)	FTL1	Autosomal dominant
NBIA 4 (mitochondrial membrane protein-associated neurodegeneration)	c19orf12	Autosomal recessive
NBIA 5 (Beta-propeller-protein-associated neurodegeneration)	WDR45	X-linked dominant
NBIA 6 (COASY protein-associated neurodegeneration)		
	COASY	Autosomal recessive
Aceruloplasminemia	Ceruloplasmin	Autosomal recessive
Fatty acid hydroxylase-associated neurodegeneration (FAHN)	Fatty acid 2 hydroxylase	Autosomal recessive
Woodhouse-Sakati syndrome	DCAF17 (c2orf37)	Autosomal recessive
Kufor-Rakeb syndrome (PARK 9)	ATP13A2	Autosomal recessive

basal ganglia has helped clinicians to expand the spectrum of NBIA disorders.<sup>[8]</sup>

The common genetic causes of NBIA are summarized in Table 1, pathological features in Table 2, and pathogenesis in Table 3.

It can be debated whether accumulation of iron in the brain is the primary process responsible for the degenerative changes, or secondary to neurodegeneration. Iron deposition in brain is known to be part of normal aging and also commonly seen in MRI scans in other neurodegenerative disorders such as Parkinson’s disease, multiple sclerosis, and multisystem atrophy. Contemporary understanding favors that the following factors play an important role in causing cell loss and iron accumulation:<sup>[9]</sup> (1) mitochondrial dysfunction – mitochondria are the iron sink in cells and iron recycling in them is through mitophagy and lysosomal degradation of iron-containing proteins. Altered mitochondrial fitness may hence affect iron turnover, (2) cell degeneration mediated through reactive oxygen species (specifically PANK2, PLA2G6), (3) altered lipid metabolism (PANK2, COASY, PLA2G6, FA2H, c19orf12), and (4) altered mitophagy and autophagy (WDR 45, ATP13A2).

Differences in the relative contribution of each of the above processes can explain the heterogeneous pathological picture and possibly explain the varying phenotypes. The clinicopathologic variability is well known in NBIA. The 10 subtypes can be further regrouped as follows:<sup>[9]</sup>

- A. NBIA caused by defects in genes coding for proteins involved in lipid metabolism in lipid membrane homeostasis: pantothenate kinase-associated neurodegeneration (PKAN), PLAN, fatty acid 2 hydroxylase-associated neurodegeneration (FAHN), mitochondrial membrane protein-associated neurodegeneration (MPAN), COASY protein-associated neurodegeneration (COPAN).
- B. NBIA caused by defects in gene coding for proteins for iron metabolism: aceruloplasminemia, neuroferritinopathy.
- C. Other forms of NBIA – Beta-propeller-protein-associated

neurodegeneration (BPAN), Kufor–Rakeb syndrome, Woodhouse–Sakati syndrome.

## PHENOTYPE–GENOTYPE CORRELATION OF NBIA

### NNBIA 1: PKAN

PKAN is one of the most common forms of NBIA encountered in clinical practice. PKAN can have heterogeneous phenotypes and it can be of classic and atypical variants.<sup>[12]</sup>

*Classic form of NBIA* has onset in the first decade with gait or postural difficulty secondary to dystonia as the presenting symptom. Earlier in the course, focal (cranial or limb musculature) dystonia is common. Axial dystonia predominates as disease advances. Oromandibular dystonia is common and jaw opening dystonia can be associated with a characteristic geste “antagoniste” that resembles a praying mantis. This geste with the patient touching the chin with both hands characteristically clenched into a fist with flexion at the elbows has been called “mantis sign,” a pathognomic of PKAN.<sup>[13]</sup> Dystonic opisthotonus or back arching has also been described as a characteristic feature of NBIA related to PANK2 and PLA2G6 mutations.<sup>[14]</sup> There can be mild developmental delay and corticospinal tract involvement. Retinitis pigmentosa and oculomotor abnormalities suggestive of midbrain degeneration (like square wave jerks and poor convergence) may be present.<sup>[12]</sup> Seizures, chorea, and parkinsonism are rare.<sup>[15]</sup> Recurrent episodes of status dystonicus though rare are described in the classic variant.<sup>[12,15]</sup> The patient usually loses ambulation within 10–15 years in the classic form.

*Atypical form* is characterized by onset in the second or third decade of life (rarely in seventh and eighth decades).<sup>[16]</sup> The atypical disease has less severe dystonia and rigidity with slower progression to parkinsonism when compared with classic presentation.

Within atypical variant, four predominant movement disorder phenotypes have been described.

**Table 2: The gross pathological features of various NBIA subtypes**

Gene	Gross morphology	Iron	Axonal spheroids	Lewy body pathology	Tau pathology	Gliosis
PANK2	Neuronal loss in GP, reduced myelin, normal SN	GP neurons, glia, microglia macrophages, perivascular and iron dusting	GP Ubq, APP, NF	No	Occasional tangles and threads	GP and widespread
COASY	Proposed similar to PANK2					
C9orf12	Neuronal loss in GP, reduced myelin, GP, and SN atrophy	GP neurons, macrophages, less in astrocytes	Ubq in cortex, GP, SN, caudate, putamen, brainstem	Severe Lewy bodies and Lewy neurites, GP, SN, cortex, striatum	Rare tau	Widespread
PLA2G6	Cerebellar, cortical, GP and brain stem atrophy, SNPr particularly affected. Cerebellar granular cells >purkinje cells	GP and sparse in SNPr	Severe p-NF, Ubq, APP, alpha-syn	Severe Lewy bodies and Lewy neurites. Ubq, alpha-syn	Early-onset hyperphosphorylated tau inclusions, threads, and tangles in cortex	Variable
FA2H	Proposed brainstem atrophy and demyelination		Proposed white matter lesions and enlarged axons			
WDR45	SN >GP, neuronal loss, cerebellar atrophy, purkinje and granule layer, cortical atrophy	Strongest in SN, also GP and glia	GP, SN plus thalamus	No	Tau tangles, hippocampus, cortex, putamen, few in atrophied SN and GP	Putamen and thalamus
ATP13A2			Peripheral biopsies show demyelination and cytoplasmic inclusions in nerve and muscle tissue			
DCAF17/c2orf37			Peripheral biopsies show denervation of muscle tissue			
CP	Severe neuronal loss in putamen, dentate nucleus. Neuronal atrophy and iron in visceral organs	Neuronal loss in cerebellum, GP >SN, cortex, perivascular and astrocytic terminals	Iron-laden globular structures in glia and variable in neurons	Unknown	Unknown	Yes
FTL	Mild atrophy in the cerebellum, cortex, putamen. GPe and SN mildly affected	Cerebellum and putamen, glia, perivascular, and perineuronal	Yes, GP, Ubq, and NF. Ferritin and iron-laden inclusions in glia >neurons GP, putamen, thalamus, and cerebellar cortex	Unknown	Few	Yes, but some atrophy too

APP: Amyloid precursor protein; GPe: Globus pallidus externa; GPi: Globus pallidus interna; NF: Neurofilament; SNc: Substantia nigra pars compacta; SNPr: Substantia nigra pars reticulata; Ubq: Ubiquitin; alpha syn: Alpha synuclein

The *dystonic phenotype* has early focal limb dystonia, dystonic tremor,<sup>[17]</sup> action-induced dystonia, and oromandibular dystonia with progression to generalized dystonia. Varying degrees of spasticity are seen. Although rare, PKAN can be seen in late-onset focal dystonia, and a patient with isolated blepharospasm at the age of 55 years has been described with PKAN.<sup>[16]</sup>

The *parkinsonism phenotype* should be easy to pick up in young patients who have bradykinesia, rigidity, and rest tremor or gait impairment. Speech abnormalities of stuttering,

palilalia, hyophonia, and spasmodic dysphonia are common and these might be the sole presenting feature or part of the early disease in a teenager or young adult. The parkinsonism can be levodopa responsive.<sup>[12,17]</sup>

The *other phenotypes* that have been reported include isolated drug responsive freezing of gait,<sup>[18]</sup> a choreic phenotype with senile chorea-like presentation,<sup>[19]</sup> motor tics and vocal tics,<sup>[20]</sup> altered sleep architecture,<sup>[21]</sup> and HARP syndrome (hypobetalipoproteinemia, acanthocytosis, retinitis pigmentosa, and pallidal degeneration).<sup>[22,23]</sup>

**Table 3: Pathogenesis of NBIAS**

Genes coding for proteins helping lipid metabolism and membrane homeostasis	Effect of gene mutation
PKAN	Defective enzymatic activity, accumulation of N-pantothenyl cysteine, free cysteine, chelates iron which accumulates. <sup>[9,10]</sup>
COPAN	Decreased/absent activity of this enzyme hampers synthesis of coenzyme A and lipid synthesis, mitochondrial dysfunction. <sup>[9]</sup>
PLAN	Defective PLA2G6 activity, inability to repair the oxidized and damaged phospholipids. So axonal damage ensues leads to axonal degeneration. <sup>[10]</sup>
FAHN	Hydroxy fatty acids are precursor to ceramide synthesis, ferritin is known to associate with myelin, and faulty myelin causes iron accumulation. <sup>[10]</sup>
Genes coding for proteins of iron metabolism	Effect of gene mutation
Mutation in the gene encoding ceruloplasmin	Absent ceruloplasmin, reduced export of iron, so accumulation of extracellular transferrin free iron, oxidative damage and degeneration.
Mutation in the ferritin light chain	Variant ferritin causes unsafe iron storage, increased cytosolic free iron and reactive oxygen species formation, degeneration
Other forms of NBIA	Effect of gene mutation
WDR45	Encoding of a truncated or destabilized WDR 45, disrupted autophagy, impaired elimination of abnormal and toxic protein, cellular stress and death.
ATP13A2 is a lysosomal P-type ATPase divalent cation transporter Mutation in DCAF17 (also called c2orf37 <sup>[7]</sup> )	Its mutation leads to the disruption of autophagy. <sup>[11]</sup> It is a nucleolus protein and exact function is not known.

NBIA: Neurodegeneration with brain iron accumulation; PKAN: Pantothenate kinase-associated neurodegeneration; COPAN: COASY protein-associated neurodegeneration; PLAN: PLA2G6-associated neurodegeneration; FAHN: Fatty acid 2 hydroxylase-associated neurodegeneration

## NBIA 2: PLAN

This syndrome has a continuum of three age distinct but overlapping phenotypes<sup>[24-26]</sup> of classic infantile neuroaxonal dystrophy, atypical neuroaxonal dystrophy of childhood onset including Karak syndrome and PLA2G6-related dystonia parkinsonism (PARK 14) of adult onset.

*Classic infantile neuroaxonal dystrophy (NBIA 2a)* is characterized by dystrophic axons found on nerve biopsy and is a devastating syndrome of neurodevelopmental regression. It accounts for 85% of the PLAN cases.<sup>[26]</sup> The onset of disease is between 6 months and 2 years of age, with axial hypotonia, psychomotor retardation which progresses to gait disturbances (due to ataxia or postural instability).<sup>[27]</sup> The axial hypotonia is unique to this variant of PLAN and is not seen in other variants. Strabismus, nystagmus and optic atrophy, and progressive pyramidal dysfunction with bulbar involvement<sup>[27,28]</sup> are seen as disease advances. Generalized seizures have been reported.<sup>[29]</sup> Many patients die in the first decade.

*Atypical neuroaxonal dystrophy (NBIA 2b)* has a childhood onset between 1 and 6 years of age.<sup>[15]</sup> The presentation is with gait instability (ataxia or postural instability) with dyspraxia and speech regression with two-thirds of patient showing optic atrophy. The disease progresses with spastic tetraparesis, nystagmus, seizures, dystonia, dysarthria, and cognitive disturbances with neuropsychiatric features.

*Karak syndrome* described by Mubaidin *et al.*<sup>[30]</sup> in 2003 is similar to atypical childhood-onset PLAN and is due to

homozygous missense mutation in PLA2G6 in 2006,<sup>[31]</sup> so it is grouped under atypical neuroaxonal dystrophy (NAD) category in 2009.

*Adult-onset PLAN/PLA2G6-associated dystonia parkinsonism/PARK 14I.* This is an adolescent or adult-onset condition with subacute levodopa dystonia (blepharospasm, foot dystonia as presenting symptoms) parkinsonism (rigidity and bradykinesia seen in majority), cognitive decline, oculomotor abnormalities, psychiatric features, and pyramidal signs.<sup>[32]</sup> Cerebellar symptoms and signs are generally absent. Autonomic dysfunction (bladder or bowel disturbances) if present can be an important clue to the diagnosis of PLAN as this is not a feature of other NBIA subtypes. Neuropsychiatric features can be a presenting feature. The oculomotor disturbances like supranuclear gaze palsy, slow saccades, fragmented saccades, nystagmus, and apraxia of eyelid opening can be seen.<sup>[33]</sup> The parkinsonism is levodopa responsive and patients can develop levodopa-induced dyskinesia.<sup>[27,34,35]</sup>

## NBIA 3: Neuroferritinopathy

This is the only autosomal dominantly inherited subtype of NBIA caused by mutation in ferritin light chain.<sup>[36]</sup> Unlike other common NBIA, the onset of neuroferritinopathy is in midlife.<sup>[37]</sup> The phenotype is of slowly progressive movement disorder with subtle cognitive deficits. The movement disorder has a focal onset chorea (39.7%), lower limb dystonia (38.5%), parkinsonism (6%), tics (1.2%), tremor (7.2%), and cerebellar ataxia (4.2%).<sup>[38]</sup> There is striking asymmetry throughout the disease.<sup>[37]</sup> The triad of oromandibular dyskinesia (65%) and impairment of voice and speech (dysarthrophonia)

with action-specific facial dystonia (63%) is specific to neuroferritinopathy. Pyramidal dysfunction, oculomotor abnormalities (slow saccades, apraxia of eyelid opening, limitation of vertical eye movements), sleep disturbances, vibration, and proprioception loss can develop later. Frontal executive dysfunction may develop early<sup>[39]</sup> or late. A case of adult-onset isolated craniocervical dystonia with later development of parkinsonism identified as NFT has also been described.<sup>[16]</sup>

#### NBIA 4: MPAN

This is an autosomal recessive NBIA described by Hartig *et al.* caused by mutations in *c19orf12* gene.<sup>[40]</sup> The mean age of onset is 11 years.<sup>[41]</sup> The condition is characterized by progressive spastic paraplegia, parkinsonism unresponsive to L-DOPA treatment, and psychiatric or behavioral symptoms, with variable optic atrophy and motor axonal neuropathy. The onset of the disease is similar to that seen in PKAN and PLAN with gait or speech abnormalities, focal dystonia restricted to feet and hands, and oromandibular dystonia, with early pyramidal dysfunction (lower limbs more affected than upper limbs).

Motor axonal neuropathy has been observed in 39%–44% of the patients.<sup>[40,41]</sup> In advanced disease, progressive muscle atrophy makes the differentiation from atypical PKAN and PLAN easier. Optic atrophy has been reported in 74% of patients.<sup>[41]</sup> Cognitive decline is very common with inattention, hyperactivity, emotional lability, depression, and stereotypic hand movements.

#### NBIA 5: BPAN

This X-linked dominant disease previously called as SENDA<sup>[21,22]</sup> has been renamed as BPAN after the causative gene mutation in *WDR45* gene was identified in 2012.<sup>[42]</sup>

There are two phases of disease progression in SENDA. In childhood, there is generally delayed speech and motor development with ataxic gait with preserved gait stability till adolescence/adulthood<sup>[43]</sup> usually in late adolescence early adulthood, there is a deterioration of neurological status with rapid development of parkinsonism, dystonia, and cognitive decline. Seizures can be seen in childhood but are rare later in the course. The parkinsonism is levodopa responsive with early development of motor fluctuations and disabling dyskinesias. The dystonia starts in the upper limbs with possible development of camptocormia. There is rapid progression of disease with spastic paraparesis and dysphagia. Hypersomnolence with shortened sleep onset latency on multiple sleep latency test (MSLT) and abnormal rapid eye movement (REM) sleep can be seen. A characteristic dance-like movement of extremities with onset of sleep has been noted. A Rett's syndrome-like phenotype with repetitive midline hand wringing movements has been reported<sup>[43]</sup> and is one of the important differentials for atypical Rett's phenotype. In advanced stages, patients are bed-bound and profoundly demented. Colobomata, astigmatism, myopia, and loss of pupillary ruff are the ocular abnormalities reported.

#### NBIA 6: COPAN

A homozygous mutation of *COASY*, which encodes for coenzyme A synthesis, causes this condition.<sup>[44]</sup> The cases reported in literature had normal development till the age of 2 years but later developed gait abnormality which progressed to spastic quadriparesis with dystonia parkinsonism. Oromandibular dystonia, cognitive decline, and mild axonal neuropathy have been described in the patients with this NBIA.

#### Aceruloplasminemia

Aceruloplasminemia is caused by mutation in ceruloplasmin gene<sup>[45]</sup> with an average age at diagnosis of 51 years. A clinical triad of retinal degeneration, diabetes mellitus, and neurologic symptoms/signs and anemia predates the development of diabetes and neurological symptoms. In a recent review,<sup>[46]</sup> the most common presenting symptom was cerebellar dysfunction in 71%, hyperkinetic movement disorder in 64% (dystonia-blepharospasm and oromandibular dystonia, tremor, chorea), parkinsonism in 20%, and cognitive dysfunction in 60% (apathy and memory impairment).

#### Fatty acid 2 hydroxylase-associated neurodegeneration

The mutation in the gene encoding for fatty acid 2 hydroxylase was identified in 2010.<sup>[47]</sup> The phenotype is similar to that of infantile PLAN and many other leukodystrophies with onset in the first decade of gait impairment and falls progressing to spastic quadriparesis, dystonia, cerebellar dysfunction, variable optic atrophy, divergent strabismus, and seizures. Most of the patients became wheelchair-bound by adolescence.<sup>[47]</sup> Axonal neuropathy was reported in a single family.<sup>[48]</sup>

#### Kufor-Rakeb syndrome

This NBIA disorder was described in 1994 from Jordan.<sup>[49]</sup> The chromosome 1p locus was designated as *PARK9* locus for the monogenic parkinsonian phenotype. The causative compound heterozygous gene mutation was identified in 2006 in lysosomal *ATP13A2*. It is a syndrome of juvenile-onset parkinsonism, spasticity, supranuclear gaze palsy,<sup>[25]</sup> and cognitive features (visual hallucinations and dementia). Oculogyric dystonic spasms, facial-facial-finger mini-myoclonus and autonomic dysfunction are variably associated.

Parkinsonism is initially responsive to levodopa with early development of disabling dyskinesias and hallucinations. Dystonia develops in 50% of the cases later in the disease course.<sup>[49]</sup> Cerebellar features are rare, but there is marked olfactory dysfunction. In the first ever case of Kufor-Rakeb syndrome reported from India recently, a novel nonsense mutation in *ATP13A2*, clinically he had no cognitive dysfunction, myoclonus, or hallucinations and a slow clinical progression.<sup>[50]</sup>

#### Woodhouse-Sakati syndrome

This is a rare neuroendocrine disorder described in 1983. The causative gene mutation was identified in *c2orf37* gene in 2008.<sup>[7]</sup> The clinical presentation is dysmorphic facies (alopecia, high forehead, malocclusion), hypogonadism, diabetes mellitus, mental retardation, sensorineural deafness,

and extrapyramidal features. Seizures, polyneuropathy, thyroid dysfunction, keratoconus, and syndactyly of hand or feet have been described in some of the cases. Thrombocytopenia has been reported in a family of three affected siblings from India.<sup>[51]</sup> The extrapyramidal features and diabetes may not develop till late teens or early adulthood. The movement disorder phenotype is reported only in 50% cases as a combination of focal onset chorea and dystonia with progression and later gait difficulty and immobilization. Eye movements are normal. Deafness and cognitive decline or mental retardation is seen in 75% of patients. This syndrome forms an important differential diagnosis for deafness dystonia phenotype from Mohr–Tranebjærg disease.

### Leukoencephalopathy with dystonia and motor neuropathy – SCP2 mutations

#### A new NBIA phenotype?

There are two case reports of this condition in the literature to date. The causative mutation was identified to be in the

gene encoding sterol carrier protein leading to its deficiency. It was first described in 2006 in a 45-year-old male with a 28-year history of spasmodic torticollis, spinocerebellar ataxia, and motor neuropathy.<sup>[52]</sup> MRI brain showed no iron deposition of basal ganglia, but a leukoencephalopathy and hyperintense thalamus and pons (butterfly-like lesions) with no iron deposition. In 2015, the second case was reported of a 55-year-old male with a 20-year history of spinocerebellar ataxia, gait disturbance, and deafness with no extrapyramidal disturbances,<sup>[53]</sup> but MRI brain demonstrated iron deposition and no leukoencephalopathy.

#### GTPBP2 mutations and NBIA

A family of three siblings<sup>[54]</sup> have been described with this mutation presenting with delayed developmental milestones and later developed action dystonia of hands and feet, ataxia motor neuronopathy, and cognitive decline (low IQ and neuropsychiatric disturbances). MRI brain of all the three siblings demonstrated hypointense globus pallidi and

**Table 4: Imaging features in NBIA**

NBIA subtype	Genetic mutation	Radiology (MRI brain with T2/T2*/SWI sequences) bilateral hypointensities in basal ganglia
PKAN	PANK2	Eye of the tiger appearance in GP, mid hypointensity in SN [Figure 1a] The eye of the tiger appearance may fade as disease advances. It is neither pathognomonic nor specific to PKAN as it is found in COPAN, neuroferritinopathy, and non-NBIA disorders such as multiple sclerosis, multisystem atrophy, and carbon mono oxide poisoning <sup>[57]</sup>
PLAN Infantile neuroaxonal dystrophy Atypical neuroaxonal dystrophy PLAN DP/PARK 14	PLA2G6	Cerebellar and vermian atrophy with callosal thinning and vertical orientation, calvar hypertrophy <i>Inconsistent iron deposition in GP, SN<sup>[32]</sup></i> Cerebellar atrophy and callosal changes in some cases <i>Inconsistent iron deposition in GP, SN. Cerebral T2 white matter hyperintensities</i>
Neuroferritinopathy	Ferritin light chain	Cortical pencil sign <sup>[58]</sup> [Figure 1b] Hypointense caudate, putamen, thalamus, GP, SN, and red nucleus
MPAN	C19orf12	GP and SN hypointense with hyperintense streaking of medial medullary lamina of GP Cortical and cerebellar atrophy
BPAN COPAN	WDR45 COASY	“Halo” in SN (T1 hyperintensity) with T2 GP and cerebral peduncles Eye of the tiger Hypointense SN, GP with swelling of caudate and putamen
Aceruloplasminemia	Ceruloplasmin	Hypointense caudate, putamen, thalamus, GP, SN, and red nucleus Hypointensities in cerebellum
FAHN	Fatty acid 2 hydroxylase	GP more hypointense than SN Confluent subcortical and periventricular cerebral T2 white matter hyperintensities Atrophy of cerebellum, medulla and spinal cord <sup>[1]</sup>
Kufor-Rakeb syndrome	ATP13A2	Hypointense GP, caudate, and putamen Cerebellar brainstem and pyramidal atrophy
Woodhouse-Sakati syndrome	DCAF17/c2orf37	Hypointense GP, SN with widespread and confluent cerebral T2 white matter hyperintensities
Leukoencephalopathy with dystonia and motor neuropathy	SCP2	Hypointense GP and SN with butterfly-like lesions in thalamus and pons
New NBIA	GTPBP2	Hypointense GP and SN with cerebellar vermian atrophy

NBIA: Neurodegeneration with brain iron accumulation; MRI: Magnetic resonance imaging; SWI: Susceptibility-weighted imaging; PKAN: Pantothenate kinase-associated neurodegeneration; GP: Globus pallidus; SN: Substantia nigra; PLAN: PLA2G6-associated neurodegeneration; MPAN: Mitochondrial membrane protein-associated neurodegeneration; BPAN: Beta-propeller-protein-associated neurodegeneration; COPAN: COASY protein-associated neurodegeneration; FAHN: Fatty acid 2 hydroxylase-associated neurodegeneration

substantia nigra on T2\* imaging with cerebellar vermian atrophy. The causative mutation was in the GTPBP gene encoding for GTP-binding protein 2 (GTP superfamily are enzymes involved in cell proliferation and differentiation, intracellular transport).

**Radiological features of NBIA**

MRI brain (T1, T2, T2\*, and FSE) sequences are very useful for the diagnosis and to differentiate between various NBIA syndromes<sup>[55]</sup> [Table 4].

Within the brain parenchyma, there are certain areas that are inherently rich in iron – globus pallidus, substantia nigra, red nucleus, dentate nucleus, putamen, and thalamus. With normal aging, there is an increased iron deposition within basal ganglia and dentate nuclei.

In NBIA, there is symmetric distribution of excess iron accumulation in the iron-rich areas of the brain mentioned above. Iron appears isointense on T1-weighted and hypointense on T2-weighted imaging. Calcium also appears isointense on T1 and hypointense on T2, but computed tomography (CT) scan differentiates the two as calcium is hyperintense than the surrounding brain parenchyma on CT and iron is isointense.

The MRI workup of NBIA is incomplete without T2\*-weighted acquisitions and/or SWI imaging. They enhance this degree of hypointensity (described as “blooming”). All NBIA subtypes reveal iron deposition in globus pallidi on MRI but differ in the co-occurrence of other findings.<sup>[56]</sup>

**Approach to a patient with suspected NBIA**

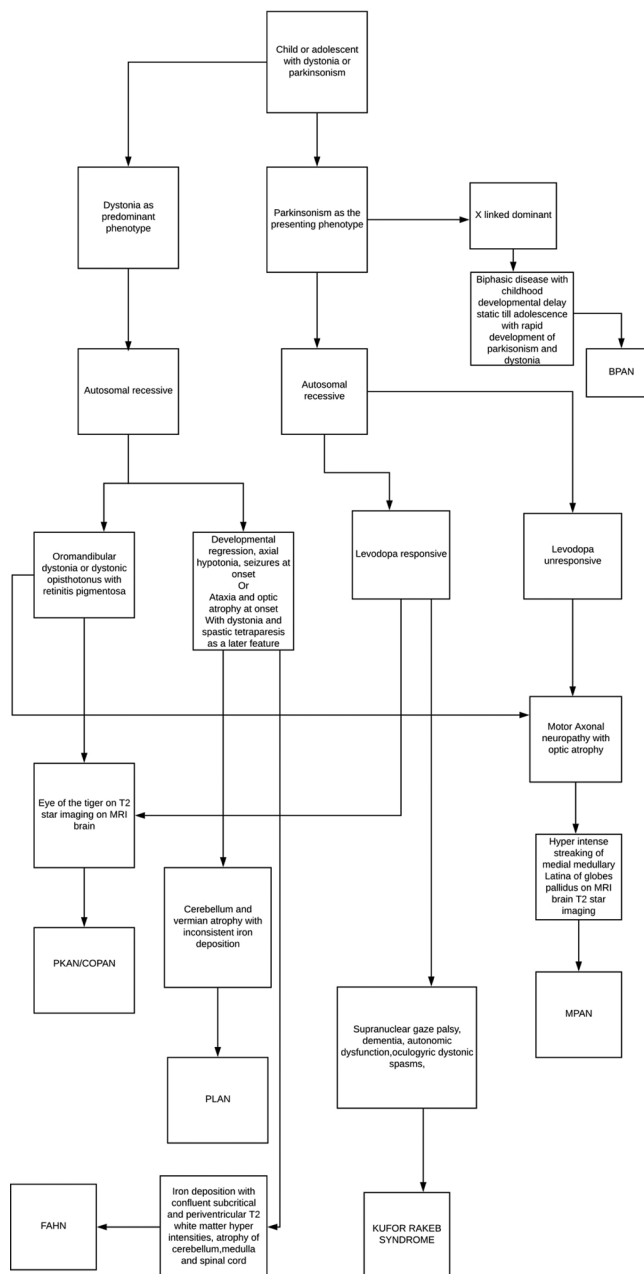
Usually in a pediatric or neurology/movement disorders clinic, a clinician encounters a patient with a mixed bag of neurological symptoms/signs and an abnormal MRI brain showing iron deposition [Flowcharts 1 and 2]. Sometimes the report from a radiologist can state NBIA with classic features like “eye of a tiger sign” that can ease the diagnostic burden. More commonly, we as clinicians will have to unjumble the puzzle with a revisit and look for more clinical clues that facilitate diagnosis. Genetic diagnosis is not always possible as most of the mutations have been described in a small group of patients. A detailed clinical history and examination can be very helpful. It is not always easy to get the correct age of onset, course, and progression. One should look for associated features such as retinitis pigmentosa, optic atrophy, peripheral neuropathy, seizures, cognitive decline/neuropsychiatric features, cerebellar features, and endocrine abnormalities.

The next step is to investigate toward the specific subtype with laboratory, electrophysiological, and MRI of brain with iron-specific sequences.

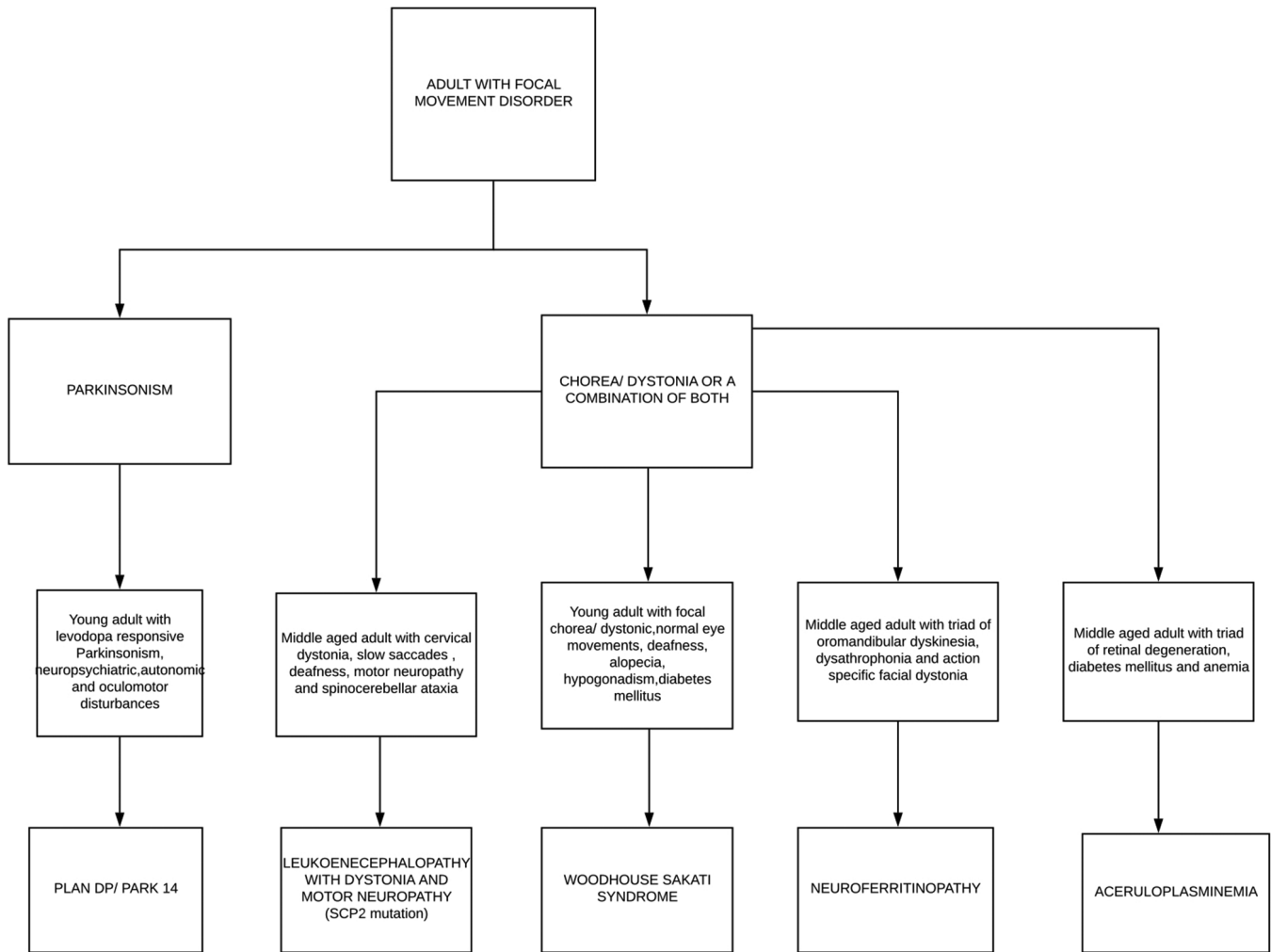
Laboratory investigations include hemogram for anemia, serum and urine copper levels, serum ceruloplasmin, serum ferritin, iron levels, blood sugar, and hormone level testing for hypogonadism where appropriate. Neuroferritinopathy has low serum ferritin levels with all other parameters being normal, whereas aceruloplasminemia has low or absent serum

ceruloplasmin, elevated ferritin, low iron, and low serum copper but normal urinary copper and raised blood sugar levels. Serum hormonal assays are to be done in suspected cases of Woodhouse–Sakati syndrome.

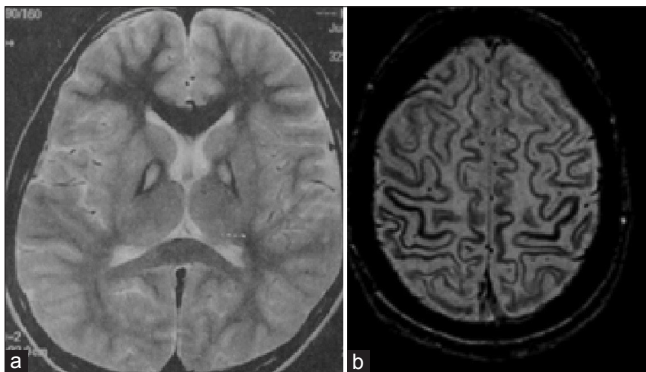
Electroencephalogram can be helpful if seizures are in question as in PLAN- Infantile neuroaxonal dystrophy (INAD) and atypical NAD (but not in PLAN-DP), FAHN, BPAN, and Woodhouse–Sakati syndrome. Electromyography studies should be done to look for sensorimotor neuropathy in case neuropathy is suspected as in PLAN and motor neuronopathy/ axonopathy in MPAN. Sleep analysis can help in investigating and managing reduced sleep time insomnia and sleep apnea. Abnormal REM sleep with decreased sleep-onset latency



**Flowchart 1:** Approach to child/adolescent with suspected NBIA



**Flowchart 2:** Approach to an adult with suspected NBIA



**Figure 1:** (a) Eye of the tiger appearance of pkan on T2 weighted imaging of brain (b) Pencil lining of the cortex on mri susceptibility weighted imaging of brain

and hypersomnolence can be seen in BPAN and may require polysomnography and MSLT to look for this.

MRI is usually available by the time one starts thinking of NBIA, but a detailed MRI with iron-specific sequences and T2 W images can help narrow down the diagnosis.

Genetic testing can confirm the diagnosis, but not all NBIA cases will have either of the mutations described and there are still some unknown NBIA. The advancement of genetic diagnosis and whole genome sequencing has meant that sometimes one may see a patient in clinic for the first time who comes with a genetic diagnosis. This is not easy to interpret genetic results in an asymptomatic patient or in someone with minimal signs. It is important to understand that not all mutations in the known genes causing NBIA are pathogenic, so one must be careful in interpreting genetic results. OMIM usually lists commonly known mutations but one might want to seek help from an expert neurogeneticist who has a better understanding of these mutations and have access to larger genetic databases to confirm in case of a doubt about pathogenicity of a newly found mutation with minimal or no clinical signs. MRI can help as well to look for changes in asymptomatic patients with these mutations.

## MANAGEMENT

Although there are some trials currently underway for specific treatments, the management of NBIA to date remains



symptomatic. A multidisciplinary approach to therapy is recommended with a combination of medical, surgical, and good supportive/nursing care/physiotherapy. Medical therapy for dystonia with trihexiphenidyl and spasticity with benzodiazepines and baclofen can be tried, but the response is variable and not sustained.<sup>[15]</sup> Botulinum toxin therapy is particularly useful for drug-resistant dystonia especially oromandibular dystonia and salivary gland toxin injections for drooling in advanced cases. In patients with NBIA and parkinsonism, levodopa trial is always justified. Parkinsonism in PKAN is not levodopa responsive; whereas in PLAN (childhood-onset and dystonia parkinsonism), MPAN, BPAN, and Kufor–Rakeb syndrome respond initially but early development of disabling dyskinesias and hallucinations can be seen. Dopamine agonists should be used very cautiously in NBIA, especially with neuropsychiatric or cognitive problems as evidence of success is limited.

A preliminary study of deferipirone, an oral iron chelator, showed robust reduction in brain iron on brain MRI in patients with PKAN, but no measurable benefit in clinical disease outcomes.<sup>[59]</sup>

Intrathecal baclofen pump can be used for symptomatic management of dystonia/spasticity where oral medications have failed or are not advisable in view of dysphagia. Of recent interest is a novel intraventricular baclofen delivery in nine children which included one PKAN patient,<sup>[60]</sup> but additional studies are required.

Deep brain stimulation has been offered to very few patients with NBIA and there are insufficient data in literature to guide usage of deep brain stimulation (DBS). This can be reviewed with local teams with expertise in DBS management of dystonia and Parkinson's on a case-to-case basis. In a patient with PKAN, some improvement was noted after bilateral globus pallidus interna (gpi) DBS (improvement in Burke-Fahn-Marsden Dystonia Rating Scale (BFMDRS)). It was not persistent and the benefit diminished with time.<sup>[19]</sup> The dystonic storm of patients with classical PKAN is resistant to drugs and GPi DBS has been reported to be life-saving.<sup>[61]</sup>

Good supportive care with a multidisciplinary team including physiotherapy, occupational therapy psychology support, speech and language therapy, and nursing care remains the mainstay of management of patients with NBIA.

### Financial support and sponsorship

Nil.

### Conflicts of interest

There are no conflicts of interest.

### REFERENCES

- Hallervorden J, Spatz H. Peculiar disease in the extrapyramidal system with special involvement of the globus pallidus and the substantia nigra. *Z Gesamte Neurol Psychiatr* 1922;79:254-302.
- Hogarth P. Neurodegeneration with brain iron accumulation: Diagnosis and management. *J Mov Disord* 2015;8:1-13.
- Zhou B, Westaway SK, Levinson B, Johnson MA, Gitschier J, Hayflick SJ. A novel pantothenate kinase gene (PANK2) is defective in Hallervorden-Spatz syndrome. *Nat Genet* 2001;28:345-9.
- Shevell M. Hallervorden and history. *N Engl J Med* 2003;348:3-4.
- Thomas M, Hayflick SJ, Jankovic J. Clinical heterogeneity of neurodegeneration with brain iron accumulation (Hallervorden-Spatz syndrome) and pantothenate kinase-associated neurodegeneration. *Mov Disord* 2004;19:36-42.
- Morgan NV, Westaway SK, Morton JEV, Gregory A, Gissen P, Sonek S, *et al.* PLA2G6, encoding a phospholipase A2, is mutated in neurodegenerative disorders with high brain iron. *Nature Genet* 2006;38:752-4. Note: Erratum: *Nature Genet* 2006;38:957.
- Alazami AM, Al-Saif A, Al-Semari A, Bohlega S, Zlitni S, Alzahrani F, *et al.* Mutations in C2orf37, encoding a nucleolar protein, cause hypogonadism, alopecia, diabetes mellitus, mental retardation, and extrapyramidal syndrome. *Am J Hum Genet* 2008;83:684-91.
- Schenck JF, Zimmerman EA. High-field magnetic resonance imaging of brain iron: Birth of a biomarker? *NMR Biomed* 2004;17:433-45.
- Levi S, Finazzi D. Neurodegeneration with brain iron accumulation: Update on pathogenic mechanisms. *Front Pharmacol* 2014;5:1-20.
- Arber CE, Li A, Houlden H, Wray S. Review: Insights into molecular mechanisms of disease in neurodegeneration with brain iron accumulation: Unifying theories. *Neuropathol App Neurobiol* 2016;42:220-41.
- Ramonet D, Podhajska A, Stafa K, Sonnay S, Trancikova A, Tsika E, *et al.* PARK9-associated ATP13A2 localizes to intracellular acidic vesicles and regulates cation homeostasis and neuronal integrity. *Hum Mol Genet* 2012;21:1725-43.
- Hayflick SJ, Westaway SK, Levinson B, Zhou B, Johnson MA, Ching KH, *et al.* Genetic, clinical, and radiographic delineation of Hallervorden-Spatz syndrome. *N Engl J Med* 2003;348:33-40.
- Petrović IN, Kresojević N, Ganos C, Svetel M, Dragašević N, Bhatia KP, *et al.* Characteristic “forceful” geste antagoniste in oromandibular dystonia resulting from pantothenate kinase-associated neurodegeneration. *Mov Disord Clin Pract* 2014;1:112-4.
- Stamelou M, Lai SC, Aggarwal A, Schneider SA, Houlden H, Yeh TH, *et al.* Dystonic opisthotonus: A “red flag” for neurodegeneration with brain iron accumulation syndromes? *Mov Disord* 2013;28:1325-9.
- Kurian MA, McNeill A, Lin J-P, Maher ER. Childhood disorders of neurodegeneration with brain iron accumulation (NBIA). *Develop Med Child Neurol* 2011;53:394-404.
- Brugger F, Kagi G, Pandolfo M, Mencacci N, Batla A, Wiethoff S, *et al.* Neurodegeneration with brain iron accumulation (NBIA) syndromes presenting with late onset craniocervical dystonia: An illustrative case series. *Mov Disord Clin Pract* 2017;4:254-7.
- Aggarwal A, Schneider SA, Houlden H, Silverdale M, Paudel R, Paisan-Ruiz C, *et al.* Indian subcontinent NBIA: Unusual phenotypes, novel PANK2 mutations, and undetermined genetic forms. *Mov Disord* 2010;25:1424-31.
- Lee JH, Park J, Ryu HS, Park H, Kim YE, Hong JY, *et al.* Clinical heterogeneity of atypical pantothenate kinase-associated neurodegeneration in Koreans. *J Mov Disord* 2016;9:20-7.
- Grimes DA, Lang AE, Bergeron C. Late adult onset chorea with typical pathology of Hallervorden Spatz syndrome. *J Neurol Neurosurg Psychiatry* 2000;69:392-5.
- Pellechia MT, Valente EM, Cif L, Salvi S, Albanese A, Scarano V, *et al.* The diverse phenotype and genotype of pantothenate kinase associated neurodegeneration. *Neurology* 2005;64:1810-2.
- Schneider SA, Hardy J, Bhatia KP. Syndromes of neurodegeneration with brain iron accumulation (NBIA): An update on clinical presentations, histological and genetic underpinnings, and treatment considerations. *Mov Disord* 2012;27:42-53.
- Gregory A, Polster BJ, Hayflick SJ. Clinical and genetic delineation of neurodegeneration with brain iron accumulation. *J Med Genet* 2009;46:73-80.
- Ching KH, Westaway SK, Gitschier J, Higgins JJ, Hayflick SJ. HARP syndrome is allelic with pantothenate kinase associated neurodegeneration. *Neurology* 2002;58:1673-4.
- Paisan-Ruiz C, Bhatia KP, Li A, Hernandez D, Davis M, Wood NW, *et al.* Characterization of PLA2G6 as a locus for dystonia-parkinsonism.

- Ann Neurol 2009;65:19-23.
25. Schneider SA, Bhatia KP. Excess iron harms the brain: The syndromes of neurodegeneration with brain iron accumulation (NBIA), *J Neural Transm* 2013;120:695-703.
  26. Kurian MA, Hayflick SJ. Pantothenate kinase-associated neurodegeneration (PKAN) and PLA2G6-associated neurodegeneration (PLAN): Review of two major neurodegeneration with brain iron accumulation (NBIA) phenotypes. *Int Rev Neurobiol* 2013;110:49-71.
  27. Kurian MA, Morgan NV, MacPherson L, Foster K, Peake D, Gupta R, *et al.* Phenotypic spectrum of neurodegeneration associated with mutations in the PLA2G6 gene (PLAN). *Neurology* 2008;70:1623-9.
  28. Gregory A, Westaway SK, Holm IE, Kotzbauer PT, Hogarth P, Sonek S, *et al.* Neurodegeneration associated with genetic defects in phospholipase A (2). *Neurology* 2008;71:1402-9.
  29. Scheithauer BW, Forno LS, Dorfman LJ, Kane CA. Neuroaxonal dystrophy (Seitelberger's disease) with late onset, protracted course and myoclonic epilepsy. *J Neurol Sci* 1978;36:247-58.
  30. Mubaidin A, Roberts E, Hampshire D, Dehyyat M, Shurbaji A, Mubaidien M, *et al.* Karak syndrome: A novel degenerative disorder of the basal ganglia and cerebellum. *J Med Genet* 2003;40:543-6.
  31. Morgan NV, Westaway SK, Morton JEV, Gregory A, Gissen P, Sonek S, *et al.* PLA2G6, encoding a phospholipase A2, is mutated in neurodegenerative disorders with high brain iron. *Nature Genet* 2006;38:752-4.
  32. Paisan-Ruiz C, Bhatia KP, Li A, Hernandez D, Davis M, Wood NW, *et al.* Characterization of PLA2G6 as a locus for dystonia-parkinsonism. *Ann Neurol* 2009;65:19-23.
  33. Erro R, Balint B, Kurian MA, Brugger F, Picillo M, Bhatia KP, *et al.* Early ataxia and subsequent Parkinsonism: PLA2G6 mutations cause a continuum rather than three discrete phenotypes. *Mov Disord Clin Pract* 2016 doi: 10.1002/mdc3.12319.
  34. Shi CH, Tang BS, Wang L, Lv ZY, Wang J, Luo LZ, *et al.* PLA2G6 gene mutation in autosomal recessive early-onset parkinsonism in a Chinese cohort. *Neurology* 2011;77:75-81.
  35. Giri A, Guven G, Hanagasi H, Hauser AK, Erginul-Unaltuna N, Bilgic B, *et al.* PLA2G6 mutations related to distinct phenotypes: A new case with early-onset Parkinsonism. *Tremor Other Hyperkinet Mov (N Y)* 2016;6:363.
  36. Curtis ARJ, Fey C, Morris CM, Bindoff LA, Ince PG, Chinnery PF, *et al.* Mutation in the gene encoding ferritin light polypeptide causes dominant adult-onset basal ganglia disease. *Nature Genet* 2001;28:350-4.
  37. Chinnery PF, Crompton DE, Birchall D, Jackson MJ, Coulthard A, Lombès A, *et al.* Clinical features and natural history of neuroferritinopathy caused by the FTL1 460insA mutation. *Brain* 2007;130:110-9.
  38. Kumar N, Rizek P, Jog M. Neuroferritinopathy: Pathophysiology, presentation, differential diagnoses and management. *Tremor Other Hyperkinet Mov* 2016;6:355.
  39. Keogh MJ, Singh B, Chinnery PF. Early neuropsychiatry features in neuroferritinopathy. *Mov Disord* 2013;28:1310-3.
  40. Hartig MB, Iuso A, Haack T, Kmiec T, Jurkiewicz E, Heim K, *et al.* Absence of an orphan mitochondrial protein, C19orf12, causes a distinct clinical subtype of neurodegeneration with brain iron accumulation. *Am J Hum Genet* 2011;89:543-50.
  41. Hogarth P, Gregory A, Kruer MC, Sanford L, Wagoner W, Natowicz MR, *et al.* New NBIA subtype: Genetic, clinical, pathologic, and radiographic features of MPAN. *Neurology* 2013;80:268-75.
  42. Haack TB, Hogarth P, Kruer M, Gregory A, Wieland T, Schwarzmayr T, *et al.* Exome sequencing reveals de novo mutations in WDR45 causing a phenotypically distinct, X-linked dominant form of NBIA. *Am J Hum Genet* 2012;7:11444-9.
  43. Hayflick SJ, Kruer MC, Gregory A, Haack TB, Kurian MA, Houlden HH, *et al.*  $\beta$ -Propeller protein-associated neurodegeneration: A new X-linked dominant disorder with brain iron accumulation. *Brain* 2013;136(Pt 6):1708-17.
  44. Dusi S, Valletta L, Haack TB, Tsuchiya Y, Venco P, Pasqualato S, *et al.* Exome sequence reveals mutations in CoA synthase as a cause of neurodegeneration with brain iron accumulation. *Am J Hum Genet* 2014;94:11-22.
  45. Harris ZL, Takahashi Y, Miyajima H, Serizawa M, MacGillivray RTA, Gitlin JD. Aceruloplasminemia: Molecular characterization of this disorder of iron metabolism. *Proc Natl Acad Sci* 1995;92:2539-43.
  46. Kono S, Miyajima H. Aceruloplasminemia. In: Rosenberg RN, Pascual JM, editors. *Rosenberg's Molecular and Genetic Basis of Neurological and Psychiatric Disease*. 5<sup>th</sup> ed. Waltham: Academic Press; 2015. p. 495-506.
  47. Kruer MC, Paisan-Ruiz C, Boddaert N, Yoon MY, Hama H, Gregory A, *et al.* Defective FA2H leads to a novel form of neurodegeneration with brain iron accumulation (NBIA). *Ann Neurol* 2010;68:610-8.
  48. Pierson TM, Simeonov DR, Sincan M, Adams DA, Markello T, Golas G, *et al.* Exome sequencing and SNP analysis detect novel compound heterozygosity in fatty acid hydroxylase-associated neurodegeneration. *Eur J Hum Genet* 2012;20:476-9.
  49. Najim al-Din A, Wriekat A, Mubaidin A, Dasouki M, Hiari M. Pallido-pyramidal degeneration, supranuclear upgaze paresis and dementia: Kufor-Rakeb syndrome. *Acta Neurol Scand* 1994;89:347-52.
  50. Prashanth LK, Murugan S, Kamath V, Gupta R, Jadav R, Sreekantaswamy S, *et al.* First report of Kufor-Rakeb syndrome (PARK 9) from India, and a novel nonsense mutation in ATP13A2 gene. *Mov Disord Clin Pract* 2015;2:326-7.
  51. Koshy G, Danda S, Thomas N, Mathews V, Viswanathan V. Three siblings with Wood house Sakati syndrome in an Indian family. *Clin Dysmorph* 2008;17:57-60.
  52. Ferdinandusse S, Kostopoulos P, Denis S, Rusch H, Overmars H, Dillmann U, *et al.* Mutations in the gene encoding peroxisomal sterol carrier protein X (SCPx) cause leukoencephalopathy with dystonia and motor neuropathy. *Am J Hum Genet* 2006;78:1046e52.
  53. Horvath R, Lewis-Smith D, Douroudis K, Duff J, Keogh M, Pyle A, *et al.* SCP2 mutations and neurodegeneration with brain iron accumulation. *Neurology* 2015;85:1909e11.
  54. Jaber E, Rohani M, Shahidi GA, Nafissi S, Arefian E, Soleimani M, *et al.* Identification of mutation in GTPBP2 in patients of a family with neurodegeneration accompanied by iron deposition in the brain. *Neurobiol Aging* 2016;38:216.
  55. Kruer MC, Boddaert N, Schneider SA, Houlden H, Bhatia KP, Gregory A, *et al.* Neuroimaging features of neurodegeneration with brain iron accumulation. *AJNR* 2011;33:407-14.
  56. McNeill A, Birchall D, Hayflick SJ, Gregory A, Schenk JF, Zimmerman EA, *et al.* T2\* and FSE MRI distinguishes four subtypes of neurodegeneration with brain iron accumulation. *Neurology* 2008;70:1614-9.
  57. Chang CL, Lin CM. Eye of the tiger sign is not pathognomonic of pantothenate kinase associated neurodegeneration in adult cases. *Brain Behav* 2011;1:55-66.
  58. Batla A, Adams ME, Erro R, Ganos C, Balint B, Mencacci NE, *et al.* Cortical pencil lining in neuroferritinopathy: A diagnostic clue. *Neurology* 2015;84:1816-8.
  59. Zorzi G, Zibordi F, Chiapparini L, Bertini E, Russo L, Piga A, *et al.* Iron-related MRI images in patients with pantothenate kinase-associated neurodegeneration (PKAN) treated with deferiprone: Results of a phase II pilot trial. *Mov Disord* 2011;26:1756-1759.
  60. Albright AL, Ferson SS. Intraventricular baclofen for dystonia: Techniques and outcomes. *Clinical article. J Neurosurg Pediatr* 2009;3:11-4.
  61. Kyriagis M, Grattan-Smith P, Scheinberg A, Teo C, Nakaji N, Waugh M. Status dystonicus and Hallervorden-Spatz disease: Treatment with intrathecal baclofen and pallidotomy. *J Pediatr Child Health* 2004;40:322-5.