

## Neoadjuvant capecitabine, bevacizumab and radiotherapy for locally advanced rectal cancer: results of a single-institute Phase I study

Yoshitaka MIKI<sup>1</sup>, Kiyoshi MAEDA<sup>2</sup>, Masako HOSONO<sup>1,\*</sup>, Hisashi NAGAHARA<sup>2</sup>,  
Kosei HIRAKAWA<sup>2</sup>, Yasuhiko SHIMATANI<sup>1</sup>, Shinichi TSUTSUMI<sup>1</sup> and Yukio MIKI<sup>1</sup>

<sup>1</sup>Department of Radiology, Osaka City University Graduate School of Medicine, 1-4-3 Asahimachi, Abeno-ku, Osaka 545–8585, Japan

<sup>2</sup>Department of Surgical Oncology, Osaka City University Graduate School of Medicine, Osaka 545-8585, Japan

\*Corresponding author. Department of Radiology, Osaka City University Graduate School of Medicine, 1-4-3, Asahimachi, Abeno-ku, Osaka 545–8585, Japan. Tel: +81-6-6645-3831; Fax: +81-6-6646-6655; Email: mhosono@med.osaka-cu.ac.jp

(Received 8 December 2013; revised 11 June 2014; accepted 17 June 2014)

The aim of this Phase I clinical trial was to assess the feasibility and safety of capecitabine-based preoperative chemoradiotherapy (CRT) combined with bevacizumab and to determine the optimal capecitabine dose for Japanese patients with locally advanced rectal cancer. Patients with cT3/T4 rectal cancer were eligible. Bevacizumab was administered at 5 mg/kg intravenously on Days 1, 15 and 29. Capecitabine was administered on weekdays concurrently with pelvic radiotherapy at a daily dose of 1.8 Gy, totally to 50.4 Gy. Capecitabine was initiated at 825 mg/m<sup>2</sup> twice daily at Dose Level 1, with a planned escalation to 900 mg/m<sup>2</sup> twice daily at Dose Level 2. Within 6.1–10.3 (median, 9.4) weeks after the completion of the CRT, surgery was performed. Three patients were enrolled at each dose level. Regarding the CRT-related acute toxicities, all of the adverse events were limited to Grade 1. There was no Grade 2 or greater toxicity. No patient needed attenuation or interruption of bevacizumab, capecitabine or radiation. All of the patients received the scheduled dose of CRT. All of the patients underwent R0 resection. Two (33.3%) of the six patients had a pathological complete response, and five (83.3%) patients experienced downstaging. In total, three patients (50%) developed postoperative complications. One patient developed an intrapelvic abscess and healed with incisional drainage. The other two patients healed following conservative treatment. This regimen was safely performed as preoperative CRT for Japanese patients with locally advanced rectal cancer. The recommended capecitabine dose is 900 mg/m<sup>2</sup> twice daily.

**Keywords:** rectal cancer; chemoradiotherapy; capecitabine; bevacizumab

### INTRODUCTION

In Western countries, preoperative chemoradiotherapy (CRT) is currently recognized as the standard treatment for locally advanced rectal cancer (LARC) because it improves the local control rate [1–4]. In Japan, extended surgery has been the gold standard, and the abdominoperineal resection (APR) technique involves a wide perineal skin incision and, together with resection of ischioanal adipose tissue and the elevator ani muscle, securing a wider circumferential tumor-free margin than in a standard Western APR. Additionally, it is reported that lateral lymph node dissection improves local control in the treatment of advanced rectal cancer at or below the peritoneal reflection [5]. Recently, the surgical strategy in

Japan has become more conservative. For example, laparoscopic excision for LARC has rapidly become widespread. Therefore, preoperative CRT should play a more important role in LARC treatment in Japan [6].

The addition of 5-fluorouracil (5-FU) to preoperative radiotherapy (RT) has been shown to improve the pathological complete response (pCR) rate and downstaging compared with RT alone [7–10]. In particular, capecitabine, an oral fluorouracil analog, has been used as a standard chemotherapeutic agent for colorectal cancer [11, 12]. Capecitabine is a pro-drug of 5-FU; the final step of its conversion to the active form of 5-FU is performed by thymidine phosphorylase, which is at higher concentrations in most tumor tissue than in most normal healthy tissue [13]. This theoretically allows low

systemic toxicity. Recent large Phase III studies have confirmed that capecitabine is non-inferior to 5-FU as a component of neoadjuvant RT for rectal cancer [12, 14, 15]. Therefore, preoperative capecitabine-based CRT is now a standard treatment for LARC.

The addition of bevacizumab, a humanized monoclonal antibody against vascular endothelial cell growth factor, to chemotherapy has been shown to improve survival in patients with metastatic colorectal cancer [16–18]. In contrast, the addition of bevacizumab to preoperative CRT for the treatment of low rectal cancer is considered a ‘double-edged sword’ for the patients. While the treatment may significantly enhance the tumor response and result in increased survival, the development of bevacizumab-related complications, such as increased bleeding tendency, thrombosis, gastrointestinal perforation and delayed wound healing, may lead to a poor outcome. However, there have been few studies on the safety and efficacy of bevacizumab in combination with neoadjuvant CRT for rectal cancer. It remains uncertain whether bevacizumab increases toxicity during CRT and postoperative surgical complications.

Several studies have shown that preoperative CRT using capecitabine and bevacizumab is feasible and improves the local control rate [19–23]. However, the safety and efficacy need to be evaluated in further large-scale studies.

The goal of this study was to clarify whether bevacizumab could be safely combined with standard capecitabine-based CRT and to determine the optimal capecitabine dose for treating Japanese patients with LARC.

## MATERIALS AND METHODS

### Patients and eligibility criteria

This study was approved by the Institutional Review Board at our hospital. Each patient gave his/her written informed consent prior to any study procedure. This study was conducted in accordance with the Declaration of Helsinki.

The patient pretreatment work-up comprised a complete history, physical examination, full blood cell count, serum biochemistry analysis, assessment of the carcinoembryonic antigen levels, chest radiography, rectosigmoidoscopy, a computed tomography (CT) scan of the whole body and magnetic resonance imaging (MRI) of the pelvis.

Eligible patients had a histologically verified adenocarcinoma of the rectum with the inferior margin within 5 cm of the anal verge, as assessed by rectosigmoidoscopy. The tumor had to have evidence of T3/T4 disease or any T disease with positive locoregional lymph nodes detected by CT and MRI. The disease was considered resectable at the time of entry in all cases, with no evidence of distant metastases. Other key inclusion criteria were: age 20–75 years; World Health Organization (WHO) performance status of 0–2; adequate bone marrow, liver, renal and cardiac function; no prior radiotherapy, chemotherapy or any molecular targeting therapy for

rectal cancer; no other co-existing malignancy or malignancy within the last five years prior to enrollment other than non-melanoma skin cancer or *in situ* carcinoma of the cervix; no severe concurrent medical or psychiatric illness; and no known hypersensitivity to the study drugs. None of the patients was pregnant or lactating.

### Radiotherapy

The treatment schema is shown in Fig. 1. The patients received radiation.

All patients were administered 3–4 MBq/kg [<sup>18</sup>F]fluoro-2-deoxyglucose (FDG). After an uptake time of 90 min, the patients were scanned in a supine position on a PET/CT hybrid scanner (Biograph 16, Siemens, Germany). For each patient, a planning CT scan of the entire pelvis from the lower abdomen to below the ischial tuberosities was obtained at 3-mm intervals. The CT dataset was transferred to the Pinnacle Version 9.0 (Philips, Eindhoven, the Netherlands), treatment-planning system to outline the volumes of interest.

RT was delivered using a four-field conformal coplanar technique (antero–posterior, postero–anterior, right lateral, and left lateral fields), and a linear accelerator (Synergy, Elekta, Sweden) was employed with a photon energy of 10 MV. A total dose of 50.4 Gy was given in 1.8-Gy fractions, five fractions per week, over 5.6 weeks. CT with co-registered FDG PET and MRI was used to delineate the targets. The primary tumor and any involved lymph nodes were defined as the gross tumor volume (GTV). In brief, the GTV was delineated by two experienced radiation oncologists via a comprehensive technique using rectosigmoidoscopy, contrast-enhanced CT scanning, MRI and the multiple-threshold method for FDG activity [24]. For this method, thresholds were defined as 2.5 standardized uptake value (SUV), 35% and 20% of the maximum FDG activity for tumors of <2 cm, 2–5 cm and >5 cm, respectively. Clinical target volume (CTV) 1 was defined as the GTV of the primary tumor by adding a margin of 2 cm in the cranio–caudal direction and 0.5 cm in the lateral and antero–posterior directions. CTV 2 was defined as the GTV of the lymph nodes by adding a margin of 0.5 cm. CTV 3 was defined as the mesorectum, presacral and internal iliac nodal region when the T stage was T3. Additionally, CTV 3 included the external iliac nodal region when the T stage was T4. Planning target volume (PTV) 1 included CTV 1, 2 and 3

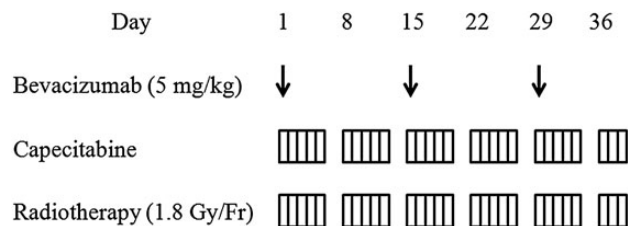


Fig. 1. Chemoradiotherapy schema.

plus a 1-cm expansion at all borders. This volume was treated to 45 Gy. PTV 2 included CTV 1 and 2 plus a 1-cm expansion at all borders. A boost of 5.4 Gy was given to PTV 2.

### Chemotherapy

Capecitabine was administered twice daily on the radiation days. Based on previous Phase I dose-finding studies that investigated the feasibility of using RT and capecitabine [25–27], a dose of 825 mg/m<sup>2</sup> or 900 mg/m<sup>2</sup> bid was recommended. These two dose levels were also evaluated in combination with bevacizumab for Phase II studies in Western countries [19, 21–23]. Therefore, in this study, capecitabine was initiated at 825 mg/m<sup>2</sup> bid every 12 h at Dose Level 1, with a planned escalation to 900 mg/m<sup>2</sup> bid at Dose Level 2. Three patients were planned for each dose level. If no more than one of the three patients assigned to a given dose level of capecitabine suffered from a severe adverse event, then the patients were changed to the next dose level. In brief, capecitabine was withheld in cases of Grade 2 or higher hand–foot syndrome, Grade 3 or greater neutropenia, mucositis, or gastrointestinal toxic reactions that did not respond to medical management. When the toxicity resolved to Grade 0–1, treatment was continued at a decreased dose (900 to 825, 825 to 700 mg/m<sup>2</sup> bid). If there was a second occurrence, capecitabine was discontinued. If toxicity required a dosing delay or the interruption of all study drugs for more than three weeks, the patient was withdrawn from the study.

Bevacizumab was administered at 5 mg/kg intravenously every two weeks, on Days 1, 15 and 29. The schedule of bevacizumab was modified in the event of Grade 2–3 thrombotic, hemorrhagic, proteinuric, hypertensive or allergic adverse events. The drug was withdrawn in cases of Grade 4 toxicity, Grade 3 toxicity not resolved to Grade 1 within four weeks, or gastrointestinal perforation.

During treatment, the patients were evaluated biweekly. Clinical examinations, complete blood counts and serum biochemical analyses were performed. Adverse events were assessed according to the National Cancer Institute Common Toxicity Criteria (NCI-CTC) Version 4.0.

### Surgery

Principally, within 6–8 weeks after the completion of the CRT, surgery with total mesorectal excision was performed. Patients whose surgery was delayed only because of issues in the surgical unit, not because of their condition, were included in the evaluation as long as the delay was <11 weeks. In the previous comparable Phase II study, the results of treatment in which the interval between preoperative chemotherapy and surgery was 6–11 weeks were evaluated [19]. Postoperative complications were recorded not only during the hospital admission but also during the first 30 d after discharge. The severity of surgical complications

was scored using the Clavien–Dindo classification of surgical complications [28].

For patients who achieved a histopathological R0 resection, adjuvant chemotherapy was recommended. The recommended treatment comprised capecitabine 1250 mg/m<sup>2</sup> orally twice daily on Days 1–14 every three weeks for eight cycles (six months).

### Histopathology

A pathological evaluation of the surgical specimen was performed. Pathological complete response after preoperative CRT was defined as the absence of cancer cells. The tumor regression grade (TRG), as described by Mandard *et al.*, was used to classify the pathological response to neoadjuvant CRT: TRG 1 was complete regression; TRG 2 was the presence of rare residual cancer cells scattered through the fibrosis; TRG 3 was an increase in the number of residual cancer cells, but with fibrosis predominating; TRG 4 was residual cancer outgrowing fibrosis; TRG 5 was no regressive changes [29].

## RESULTS

### Patient characteristics

In this study, between March 2011 and May 2012, six Japanese patients were enrolled and treated with neoadjuvant CRT. Their characteristics are summarized in Table 1. Five (83.3%) patients had cT3 disease, and one (16.7%) patient had cT4 disease. Lymph node involvement was detected in

**Table 1.** Patient characteristics

Characteristics	
Age (years)	
Mean (range)	64 (46–74)
Gender, <i>n</i> (%)	
Male	4 (66.7)
Female	2 (33.3)
WHO performance status, <i>n</i> (%)	
0	6 (100)
TN clinical stage, <i>n</i> (%)	
T3N1	2 (33.3)
T3N2	3 (50)
T4N0	1 (16.7)
Distance from anal verge, cm	
Median (range)	2 (0.5–5)
CRT to surgery, week	
Median (range)	9.4 (6.1–10.3)

WHO = World Health Organization, CRT = chemoradiotherapy.

five (83.3%) patients. In all patients, the primary tumor was situated <5 cm from the anal verge.

### CRT-related toxicity

The frequency and grade of treatment-related acute toxicities are summarized in Table 2. All of the adverse events were limited to Grade 1. There was no toxicity of Grade 2 or greater. Bevacizumab-related toxicity (such as hypertension, thrombosis, proteinuria, or gastrointestinal perforation) was not observed in any of the patients.

No patient needed attenuation or interruption of bevacizumab, capecitabine or RT. All of the patients received the scheduled dose of CRT. All preoperative treatment procedures for the CRT were completed on an outpatient basis.

**Table 2.** Acute toxicities during neoadjuvant chemoradiotherapy

Toxicity	Capecitabine dose (mg/m <sup>2</sup> bid)	
	825	900
	<i>n</i> (%)	<i>n</i> (%)
	<b>Grade 1 (<i>n</i> = 3)</b>	<b>Grade 1 (<i>n</i> = 3)</b>
Hematological		
Leukocytopenia	3 (100)	1 (33.3)
Neutropenia		
Anemia		
Thrombocytopenia	3 (100)	1 (33.3)
Non-hematological		
Diarrhea	2 (66.7)	1 (33.3)
Anorexia	1 (33.3)	
Hand-foot syndrome		1 (33.3)
Anal pain	2 (66.7)	2 (66.7)

**Table 3.** Individual patient characteristics and treatment response

Patient	Capecitabine dose (mg/m <sup>2</sup> bid)	Pretreatment stage	Postsurgical stage	Surgical Outcome	TRG scale
1	825	T3N1M0	T0N0M0	R0	1
2	825	T4N0M0	T3N2M0	R0	4
3	825	T3N2M0	T2N0M0	R0	2
4	900	T3N2M0	T3N0M0	R0	4
5	900	T3N1M0	T0N0M0	R0	1
6	900	T3N2M0	T2N0M0	R0	3

TRG = tumor regression grade.

### Surgery and pathological results

All of the patients underwent definitive surgery. Radical resection was achieved in all patients. APR was performed in five patients, and sphincter-preserving surgery was performed in one patient.

Pathological examination showed that an adequate distal section margin and negative circumferential margins were achieved in all patients. TRG 1 (pCR) was recorded in two patients (33.3%), and TRG 2 was recorded in one patient (16.7%; Table 3). According to the correlation between the pathological TNM stage and pretreatment TNM status, both T-downstaging and N-downstaging was observed in five patients (83.3%).

### Postoperative surgical complications

The postoperative surgical complications are summarized in Table 4. There were no postoperative deaths. In total, three patients (50%) developed complications (perineal wound infection in one patient, an intrapelvic abscess and perineal fistula in one patient, and anastomotic leakage in one patient). The patient who developed an intrapelvic abscess healed with incisional drainage. The other patients healed with conservative treatment without surgical intervention. We did not observe bleeding complications or thromboembolic events.

## DISCUSSION

Although many studies have demonstrated that the addition of bevacizumab to chemotherapy prolongs the survival of patients with metastatic colorectal cancer [16–18], the efficacy and safety of adding neoadjuvant bevacizumab to CRT were unclear. Several previous studies reported that the addition of bevacizumab to capecitabine-based neoadjuvant CRT increased the pathological response rate and had a potential long-term survival benefit in patients with rectal cancer (Table 5) [19–23]. In these studies, it was reported that although most of the adverse events during CRT were mild, some patients had Grade 3 or greater severe adverse

**Table 4.** Postoperative surgical complications (events during admission and 30 days after discharge)

Surgical complication	Capecitabine dose (mg/m <sup>2</sup> bid)					
	825			900		
	Grade I	Grade II	Grade IIIa	Grade I	Grade II	Grade IIIa
Perineal wound infection					1 (16.7%)	
Perineal fistula	1 (16.7%)					
Intrapelvic abscess			1 (16.7%)			
Anastomotic leakage	1 (16.7%)					

events (e.g. diarrhea, neutropenia, leukocytopenia, or anal pain).

In our study, preoperative CRT using capecitabine combined with bevacizumab was safely undertaken up to the capecitabine Dose Level 2 without severe adverse events. The adverse events that occurred during CRT were limited to Grade 1. All of the patients completed the scheduled dose of CRT without interruption. Bevacizumab-related toxicity (such as hypertension, thrombosis, proteinuria, or gastrointestinal perforation) did not occur in our patients.

One of the reasons why severe toxicity was not observed in our study may have been the weekday-on/weekend-off administration of capecitabine. In some previous studies, capecitabine was administered continuously during CRT. In those studies, the adverse events were relatively frequent and resulted in treatment interruption or discontinuation [21, 22]. The weekday-on/weekend-off schedule is one of the standard regimens used for preoperative CRT for rectal cancer. Ngan *et al.* and Pentheroudakis *et al.* also reported that the rates of adverse events were lower for the weekday-on/weekend-off schedule compared with the continuous schedule [26, 30]. In the former report, as a single regimen, the dose level of capecitabine was safely escalated up to 900 mg/m<sup>2</sup> bid combined with 50.4 Gy pelvic irradiation. Although the optimal dose of capecitabine combined with bevacizumab is unclear, the efficacy of the two weekday-on/weekend-off schedules in our study was demonstrated in previous reports [19, 23]. Our study indicated that these two capecitabine dose levels combined with bevacizumab can also be safely adopted in Japanese patients.

According to the pathological examination, downstaging was observed in five patients (83.3%), including two patients (33.3%) with pCR. This rate was not inferior to previous reports that used capecitabine on a continuous schedule [21, 22]. Although the efficacy and safety will need to be evaluated in further large-scale studies, our results suggest that the addition of bevacizumab to weekday-on/weekend-off CRT can increase the rate of pCR or downstaging without severe adverse events.

Concerning postoperative wound complications, the frequency in our study was relatively high in the patients who underwent APR. Specifically, postoperative complications were found in three patients (50%). One patient developed an intrapelvic abscess and healed with incisional drainage (16.7%). The other two patients healed following conservative treatment, without the need for surgical intervention (33.3%). However, the postoperative complications rate was similar to that reported in previous studies of standard CRT without bevacizumab. Swellengrebel *et al.* studied the surgical complications of 138 patients with LARC who underwent preoperative capecitabine-based CRT and reported that surgical complications were observed in 50% of patients, and surgical intervention was required in 21.7% of the patients [31]. In that study, the most frequently observed complication was associated with the perineal wound (37%). Therefore, our study suggested that the addition of bevacizumab does not seem to be related to an increased risk of wound complications. Recently, a Phase I study of preoperative CRT for rectal cancer reported that RT of 45 Gy to the pelvis and up to 50.4 Gy to the primary rectal tumor with concurrent capecitabine, bevacizumab and erlotinib was well tolerated and achieved a high pCR rate (44%) [32]. On the other hand, it has been reported that without RT, neoadjuvant chemotherapy combined with bevacizumab for high-risk rectal cancer caused severe bevacizumab-related toxicity adverse events in a Japanese Phase II trial [6]. The severity of the mechanism-based adverse events related to bevacizumab seemed to be variable in combined therapies and probably according to race. Although Dalles *et al.* reported that the quantity and the nature of the surgery-associated spectrum of complications followed by a preoperative bevacizumab-containing CRT regimen were comparable in each bevacizumab-based approach, combination with bevacizumab should be adopted with caution, and the safety and efficacy of each treatment regimen must be evaluated individually [33, 34].

In the previous Phase I dose-determining studies that investigated the feasibility of using RT and capecitabine [25–27], a dose of either 825 mg/m<sup>2</sup> or 900 mg/m<sup>2</sup> bid was



**Table 5.** Previous reports on results of neoadjuvant chemoradiotherapy for locally advanced rectal cancer

Author	Year	Patients	Radiotherapy		Capecitabine		Bevacizumab		Diarrhea		Another side-effect	Treatment interruption because of side-effect (%)		
			Total dose (Gy)	Fractionation (Gy/Fr)	Dose (mg/m <sup>2</sup> , bid)	Administration day (days/week)	Dose (mg/kg)	Administration day (Day)	pCR (%)	All grade (%)			Grade III/IV (%)	Grade III/IV (%)
Crane <i>et al.</i>	2010	25	50.4	45/25 + 5.4/3	900	5	1, 15, 29	5	1, 15, 29	32	unclear	0	(+)	28
Koukourakis <i>et al.</i>	2011	19	34	30.6/9 + 3.4/1	600	5	1, 15	5	1, 15	36.8	73.7	10.5	(+)	0
Resch <i>et al.</i>	2011	8	45	45/25	825	5	1, 15, 29	5	1, 15, 29	25	37.5	25	(+)	(+)
Gasparini <i>et al.</i>	2011	43	50.4	45/25 + 5.4/3	825	5	Day 1–38	5	–14, 1, 15, 29	14	35.7	7.1	(+)	9.5 (abort)
Velenik <i>et al.</i>	2011	61	50.4	45/25 + 5.4/3	825	5	Day 1–38	5	–14, 1, 15, 29	13.3	37.7	1.6	(+)	11.5
Our study	2013	6	50.4	45/25 + 5.4/3	825 or 900	5	1, 15, 29	5	1, 15, 29	33.3	50	0	(–)	0

All patients in Koukourakis's study received amifostine. pCR = pathological complete response.

recommended. In our study, there were no differences in the CRT-related toxicity or postoperative surgical complications between the two doses. We therefore recommend using a dose of 900 mg/m<sup>2</sup> bid in the upcoming Phase II studies for patients with LARC to determine the effectiveness of concurrent full-dose RT combined with bevacizumab.

In summary, preoperative RT combined with capecitabine and bevacizumab enhanced pCR for Japanese patients with LARC. The recommended capecitabine dose is 900 mg/m<sup>2</sup> bid. Further studies should be conducted to clarify the safety and efficacy of this preoperative CRT.

## ACKNOWLEDGEMENTS

The trial registration number is: UMIN000005289.

## FUNDING

Funding to pay the Open Access publication charges for this article was provided by Department of Radiology, Osaka City University Graduate School of Medicine.

## REFERENCES

1. Kapiteijn E, Maijnen CAM, Nagtegaal ID *et al.* Preoperative radiotherapy combined with total mesorectal excision for resectable rectal cancer. *N Engl J Med* 2001;**345**:638–46.
2. Colorectal Cancer Collaborative Group. Adjuvant radiotherapy for rectal cancer: a systematic overview of 8507 patients from 22 randomised trials. *Lancet* 2001;**358**:1291–304.
3. Bosset JF, Collette L, Callais G *et al.* Chemotherapy with preoperative radiotherapy in rectal cancer. *N Engl J Med* 2006;**355**:1114–23.
4. Swedish Rectal Cancer Trial. Improved survival with preoperative radiotherapy in resectable rectal cancer. *N Engl J Med* 1997;**336**:980–7.
5. Kusters M, Beets GL, van de Velde CJH *et al.* A comparison between the treatment of low rectal cancer in Japan and the Netherlands, focusing on the patterns of local recurrence. *Annals of Surg* 2009;**249**:229–35.
6. Uehara K, Hiramatsu K, Maeda A *et al.* Neoadjuvant oxalipatin and capecitabine and bevacizumab without radiotherapy for poor-risk rectal cancer: N-SOG 03 phase II trial: *Jpn J Clin Oncol* 2013;**43**:964–71.
7. Gerard JP, Conroy T, Bonnetain F *et al.* Preoperative radiotherapy with or without concurrent fluorouracil and leucovorin in T3–4 rectal cancers: results of FFCD9203. *J Clin Oncol* 2006;**24**:4620–5.
8. Sauer R, Fietkau R, Wittekind C *et al.* Adjuvant vs neoadjuvant radiochemotherapy for locally advanced rectal cancer: the German trial CAO/ARO/AIO-94. *Colorectal Dis* 2003;**5**:406–15.
9. Roh MS, Colangelo LH, O'Connell MJ *et al.* Preoperative multimodality therapy improves disease-free survival in patients with carcinoma of the rectum: NSABP R-03. *J Clin Oncol* 2009;**27**:5124–30.

10. Van Cutsem E, Twelves C, Cassidy J *et al*. Oral capecitabine compared with intravenous fluorouracil plus leucovorin in patients with metastatic colorectal cancer: results of a large phase III study. *J Clin Oncol* 2001;**19**:4097–106.
11. Cassidy J, Twelves C, A Van Cutsem E *et al*. First-line oral capecitabine therapy in metastatic colorectal cancer: a favourable safety profile compared with intravenous 5-fluorouracil/leucovorin. *Ann Oncol* 2002;**13**:566–75.
12. Das P, Lin EH, Bhatia S *et al*. Preoperative chemoradiotherapy with capecitabine versus protracted infusion 5-fluorouracil for rectal cancer: a matched pair analysis. *Int J Radiat Oncol Biol Phys* 2006;**66**:1378–83.
13. Koukourakis GV, Zacharias G, Tsalafoutas J *et al*. Capecitabine for locally advanced and metastatic colorectal cancer: a review. *World J Gastrointest Oncol* 2010;**2**:311–21.
14. Saif MW, Hashmi S, Zelterman D *et al*. Capecitabine vs continuous infusion 5FU in neoadjuvant treatment of rectal cancer. A retrospective review. *Int J Colorectal Dis* 2008;**32**:139–45.
15. Chang AK, Wong AO, Jenken DA. Preoperative capecitabine and pelvic radiation in locally advanced rectal cancer—is it equivalent to 5-FU infusion plus leucovorin and radiotherapy? *Int J Radiat Oncol Biol Phys* 2010;**76**:1413–9.
16. Welch S, Spithoff RB, Rumble RB *et al*. Bevacizumab combined with chemotherapy for patients with advanced colorectal cancer: a systematic review. *Ann Oncol* 2010;**21**:1152–62.
17. Chau I, Cunningham D. Treatment in advanced colorectal cancer: what, when and how? *Br J Cancer* 2009;**100**:1704–19.
18. Pfeiffer P, Qvortrup C, Eriksen JG. Current role of antibody therapy in patients with metastatic colorectal cancer. *Oncogene* 2007;**26**:3661–78.
19. Crane CH, Eng C, Feig BW *et al*. Phase II trial of neoadjuvant bevacizumab, capecitabine, and radiotherapy for locally advanced rectal cancer. *Int J Radiat Oncol Biol Phys* 2010;**76**:824–30.
20. Koukourakis MI, Giatromanolaki A, Tsoutsou P *et al*. Bevacizumab, capecitabine, amifostine, and preoperative hypofractionated accelerated radiotherapy (HYPOARC) for rectal cancer: a phase II study. *Int J Radiat Oncol Biol Phys* 2011;**80**:492–8.
21. Velenik V, Ocvrik J, Music M *et al*. Neoadjuvant capecitabine, radiotherapy, and bevacizumab (CRAB) in locally advanced rectal cancer: results of an open-label phase II study. *Radiat Oncol* 2011;**6**:105–12.
22. Gasparini G, Torino F, Ueno T *et al*. A phase II study of neoadjuvant bevacizumab plus capecitabine and concomitant radiotherapy in patients with locally advanced rectal cancer. *Angiogenesis* 2012;**15**:141–50.
23. Resch G, De Vries A, Ofner D *et al*. Preoperative treatment with capecitabine, bevacizumab and radiotherapy for primary locally advanced rectal cancer – a two stage phase II clinical trial. *Radiother Oncol* 2012;**102**:10–3.
24. Okubo M, Nishimura Y, Nakamatsu K *et al*. Radiation treatment planning using positron emission and computed tomography for lung and pharyngeal cancers: a multiple-threshold method for [<sup>18</sup>F]fluoro-2-deoxyglucose activity. *Int J Radiat Oncol Biol Phys* 2010;**77**:350–6.
25. Dunst J, Reese T, Sutter T *et al*. Phase I trial evaluating the concurrent combination of radiotherapy and capecitabine in rectal cancer. *J Clin Oncol* 2002;**20**:3983–91.
26. Ngan SYK, Michael M, Mackay J *et al*. A phase I trial of preoperative radiotherapy and capecitabine for locally advanced, potentially resectable rectal cancer. *Br J Cancer* 2004;**91**:1019–24.
27. Ben-Josef E. Capecitabine and radiotherapy as neoadjuvant treatment for rectal cancer. *Am J Clin Oncol* 2007;**30**:649–55.
28. Clavien PA, Barkun J, de Oliveira ML *et al*. The Clavien–Dindo classification of surgical complications: five year experience. *Annals of Surg* 2002;**250**:187–96.
29. Mandard AM, Dalibard F, Mandard JC *et al*. Pathologic assessment of tumor regression after preoperative chemoradiotherapy of esophageal carcinoma. Clinicopathologic correlations. *Cancer* 1994;**73**:2680–6.
30. Pentheroudakis G, Pappas P, Golfnopoloulos V *et al*. Weekday on–weekday off oral capecitabine: a phase I study of a continuous schedule better simulating protracted fluoropyrimidine therapy. *Cancer Chemother Pharmacol* 2007;**60**:733–9.
31. Swellengrebel HAM, Marijnen CAM, Verwaal V *et al*. Toxicity and complications of preoperative chemoradiotherapy for locally advanced rectal cancer. *Br J Surg* 2011;**98**:418–26.
32. Das P, Eng C, Rodriguez-Bigas MA *et al*. Preoperative radiation therapy with concurrent capecitabine, bevacizumab, and erlotinib for rectal cancer: a phase I trial. *Int J Radiat Oncol Biol Phys* 2014;**88**:301–5.
33. Dellas K, Buller J, Gorz GJ *et al*. Analysis of bevacizumab-based preoperative radiochemotherapy in patients with locally advanced rectal cancer on surgery-associated spectrum of complications. *Ann Surg Oncol* 2014;**21**:1352–60.
34. Mangoni M, Vozenin MC, Biti G *et al*. Normal tissues toxicities triggered by combined anti-angiogenic and radiation therapies: hurdles might be ahead. *Br J Cancer* 2012;**107**:308–14.