American Journal of Case Reports

ISSN 1941-5923
© Am J Case Rep, 2016; 17: 950-956
DOI: 10.12659/AJCR.899764

Received: 2016.05.27
Accepted: 2016.08.11
Published: 2016.12.15

A Case Report and Literature Review of Eculizumab Withdrawal in Atypical Hemolytic-Uremic Syndrome

Authors' Contribution:
Study Design A
Data Collection B
Statistical Analysis C
Data Interpretation D
Manuscript Preparation E
Literature Search F
Funds Collection G

ABCDEF Borja Quiroga
ADE Alberto de Lorenzo
CDE Cristina Vega
BDF Fernando de Alvaro

Nephrology Unit, HM Hospitals, Madrid, Spain

Corresponding Author: Borja Quiroga, e-mail: borjaqg@gmail.com
Conflict of interest: None declared

Patient: Female, 37
Final Diagnosis: SHUa
Symptoms: Abdominal discomfort • nausea • weakness
Medication: —
Clinical Procedure: —
Specialty: Nephrology

Objective: Unusual clinical course

Background: Recent advances in the treatment of atypical hemolytic-uremic syndrome (aHUS) have resulted to better long-term survival rates for patients with this life-threatening disease. However, many questions remain such as whether or not long-term treatment is necessary in some patients and what are the risks of prolonged therapy.

Case Report: Here, we discuss the case of a 37-year-old woman with CFH and CD46 genetic abnormalities who developed aHUS with severe renal failure. She was successfully treated with three doses of rituximab and a three month treatment with eculizumab. After eculizumab withdrawal, symptoms of thrombotic micro-angiopathy (TMA) recurred, therefore eculizumab treatment was restarted. The patient exhibited normal renal function and no symptoms of aHUS at one-year follow-up with further eculizumab treatment.

Conclusions: This case highlights the clinical challenges of the diagnosis and management of patient with aHUS with complement-mediated TMA involvement. Attention was paid to the consequences of the treatment withdrawal. Exact information regarding genetic abnormalities and renal function associated with aHUS, as well as estimations of the relapse risk and monitoring of complement tests may provide insights into the efficacy of aHUS treatment, which will enable the prediction of therapeutic responses and testing of new treatment options. Improvements in our understanding of aHUS and its causes may facilitate the identification of patients in whom anti-complement therapies can be withdrawn without risk.

MeSH Keywords: Complement C5a • Hemolytic-Uremic Syndrome • Thrombotic Microangiopathies

Full-text PDF: http://www.amjcaserep.com/abstract/index/idArt/899764

2541 1 2 41

This work is licensed under Creative Common Attribution-NonCommercial-NoDerivatives 4.0 International (CC BY-NC-ND 4.0)

Background

The term atypical hemolytic-uremic syndrome (aHUS) applies to a heterogeneous group of diseases, which have in common thrombotic micro-angiopathy (TMA) associated with some degree of renal failure, and frequently progress to end-stage renal disease or death [1]. Compared with typical HUS, aHUS (5–10% of the HUS cases) is associated with a poor prognosis [2]. Multiple underlying disease mechanisms are likely to be involved in aHUS. In some patients with aHUS, the primary underlying pathology involves a complement abnormality such as genetic mutation or the presence of an autoantibody to a complement component. The degree to which complement components are implicated in other forms of aHUS is currently unknown [3].

The complement cascade is the basis of innate immunity, and its regulation involves a delicate balance between complement activity (for pathogen surveillance), and complement control (for the avoidance of host damage and disease) [4]. All of the three complement pathways (classical, alternative, and lectin) converge on the C3 complement. Unlike the classical and lectin pathways, activation of the alternative pathway does not require initiators, thus hydrolysis of C3 can occur spontaneously [4–6]. Regulators of this process include: CFH, complement factor I (CFI), MPC (CD46), complement factor B (CFB), and C3. Inherited and acquired genetic mutations which affect these proteins are found in 60–70% of patients with the diagnoses of aHUS [3,7], which recently has been described as complement-mediated TMA [8]. These mutations lead to continuous activation of the alternative complement pathway. This over-activation results in endovascular cell injury and damage to the host tissues, which is very characteristic in TMA-disorders [4,7].

Common variants in the genes encoding for CFH, CD46, and CFH-related proteins are known to be additional risk factor for the development of aHUS. Indeed, CFH mutations are the most common genetic abnormalities in aHUS (accounting for 25% of cases) and they are associated with poor prognosis regarding recurrence rates and development of chronic renal disease [9]. However, several studies have shown that only a CD46 aHUS-risk haplotype is associated with disease in patients that already present with other mutations [10,11].

Cases of aHUS may be sporadic or familial. Familial aHUS may display either autosomal dominant or autosomal recessive forms of inheritance. Environmental triggers, such as infections, medications, pregnancy, and systemic diseases have been reported to be precipitating factors for aHUS [5].

The penetrance of familial aHUS is only approximately 60% [7,12] because the coexistence of a trigger and mutations (rare) or aHUS-risk haplotypes (common) in the complement genes is necessary for the manifestation of the disease [10]. If the patients clinical history does not suggest any of the diseases associated with TMA, then the diagnosis of complement-mediate TMA should be made by exclusion and appropriate treatment should be initiated [3].

Plasma exchange and plasma transfusion have traditionally been the first-line therapies for TMA [4,13–16]. However, the finding that complement deregulation is fundamental to the disease has led to the implementation of targeted therapies, such as eculizumab, a monoclonal antibody that blocks the activation of the terminal complement pathway [13,17]. Eculizumab has been reported to be effective in controlling hemolysis, improving renal function, and promoting the withdrawal of plasma therapy [17]. Prior to the availability of anti-complement therapy, the 5-year risk for end-stage renal disease (ESRD) associated with aHUS was high (50–80%) and was related to the underlying genetic abnormality [1,3]. Anti-complement therapy has improved the long-term health and quality of life of both children and adults with complement-mediated TMA [3,18].

However, experience with eculizumab today is still limited. Many questions in relation to the treatment duration remain unanswered [15,19]. The current treatment process is that C5 blockade should be maintained in aHUS patients to prevent relapses and reactivation of the renal TMA process. However the risk of treatment-related adverse events and the high cost of the therapy, dictate a necessity for studies with the aim to investigate further the results of treatment withdrawal and alternative therapeutic options.

We describe the case of a woman with CFH and CD46 genetic abnormalities who developed aHUS with severe renal impairment. Short-term treatment with eculizumab and rituximab was initially successful. However, TMA recurred after the withdrawal of eculizumab. She was once again successfully treated when eculizumab was reintroduced for the duration of one year. We also reviewed the existing literature regarding eculizumab withdrawal in aHUS. For the review, we searched by using the terms “atypical hemolytic-uremic syndrome”, “eculizumab withdrawal”, “complement-mediated TMA” in PubMed.

Case Report

A 37-year-old female smoker with no remarkable family history was admitted to our hospital after she had experienced malaise, weakness, nausea, loss of appetite, and abdominal pain for four days. Otherwise, she was asymptomatic and denied being on any regular or new treatments. She had previously suffered three episodes of severe anemia and thrombocytopenia

This work is licensed under Creative Common Attribution-NonCommercial-NoDerivatives 4.0 International (CC BY-NC-ND 4.0)

without renal involvement at the ages of two, five and 18 years. All of these episodes had been treated with plasma exchange and resolved completely.

On admission to the hospital, the results of respiratory, cardiac, and abdominal examinations were normal, except for the presence of peripheral edema. The patient was normotensive, eupneic, and afebrile. Before admission, the patient reported that her urine output was normal. Initial laboratory tests results indicating TMA were: a low hemoglobin level (6.3 g/dL), low platelet count ($121\times10^3/\mu L$), high serum lactate dehydrogenase (1.916 U/L), and the presence of schistocytes in a peripheral blood smear. Haptoglobin was undetectable and direct Coombs test was negative. Results also revealed severe acute renal failure, with serum creatinine of 11.5 mg/dL, serum sodium 132 mmol/L and serum potassium 6 mmol/L, mild proteinuria (urine analysis by dipstick gave a result of 3+, equivalent to 2–5 g/24 hour). Urine sedimentation showed 10–15 red cells per high-power field (hpf) and 5–10 leukocytes per hpf. A renal ultrasonography was normal and a computed tomography (CT) scan revealed mild bilateral pleural effusion. ADAMTS13 activity was normal and direct Coombs test was negative, so diagnosis of thrombotic thrombocytopenic purpura (TTP) and immune-mediated hemolytic anemia were eliminated. The patient denied any digestive symptoms (no diarrhea) and all microbiology studies were negatives (stool culture for STEC which would be indicative of Shiga-toxin HUS; HIV serology, influenza assay, and blood or pulmonary cultures). In view of these results, a preliminary diagnosis of aHUS was made. We therefore decided to start plasmapheresis. Complete immunology studies (which were normal) and complement test were conducted prior to plasmapheresis initiation. The patient was treated with five sessions of plasmapheresis, steroids at a dose of 1.5 mg/kg per day and 48 hours of continuous hemofiltration followed by 14 daily sessions of hemodialysis without any response. A percutaneous renal biopsy was performed and the results demonstrated the presence of TMA with diffuse glomerular damage and multiple intracapillary thrombi. Acute and chronic inflammatory cells had infiltrated the glomeruli and interstitium. Irregular glomerular basement-membrane thickening secondary to focal endothelial-cell proliferation was prominent. The small arteries and arterioles exhibited severe intimal hyperplasia and focal intraluminal thrombi. Intratubular hyaline casts were also observed. On the basis of the accumulated results, a no complement-mediated aHUS was excluded.

Treatment with eculizumab was initiated following previous vaccination against meningitis B, and 14-day prophylactic treatment of intravenous levofloxacin. Eculizumab was administered following an induction schedule at a dose of 900 mg IV per week for four weeks, 1,200 mg on the fifth week, followed by a maintenance phase with a dose of 1,200 mg every two weeks. Plasmapheresis was discontinued before the first dose of eculizumab and steroids were progressively tapered (less 10 mg/day every week). Following the two initial doses of eculizumab neither the renal function nor the hemolysis parameters improved, so plasmapheresis was resumed in combination with corticosteroids (1 mg/kg per day). Moreover, the patient received a dose of rituximab (375 mg/m^2) per week for three weeks (Figure 1). After a total of four doses of eculizumab and three doses of rituximab, renal function improved, therefore, the hemodialysis sessions were stopped. Six weeks following admission, the patient was discharged in good health, and the laboratory studies revealed progressive amelioration of renal dysfunction and hematological abnormalities with serum creatinine of 4.0 mg/dL. The patient reported no adverse effects from any of the treatments. Eculizumab was maintained throughout 12 more doses. During follow-up, creatinine and anemia continued to improve slowly but progressively (creatinine nadir of 2.5 mg/dL). At that time, eculizumab was discontinued followed by close monitoring of the patient. After three months of the anti-complement therapy discontinuation, the creatinine level was 3.2 mg/dL and abnormal hemolysis parameters were highly suggestive of TMA recurrence (Figure 1). Besides, genetic testing revealed, that the levels of complement factor H (CFH) and membrane cofactor protein (MCP, encoded by CD46) were below normal ranges. A mutation in the CD46 gene (c.390-1G>C) was detected, which is associated with increased risk of aHUS. The CD46 mutation was also present in the patient's mother and brother. Moreover, the patient was homozygous for a polymorphic variant CFH haplotype that also increases the risk of aHUS. On the basis of these results, eculizumab treatment at dose of 900 mg followed by maintenance at a dose of 1,200 mg every two weeks was started again. Two weeks later, renal function and hemoglobin and platelet levels had returned to normal. After one year of further treatment with eculizumab, the patient's renal function remained almost normal with a creatinine level of 1.4 mg/dL and she exhibited no signs or symptoms of aHUS (Figure 1).

Discussion

We present a case of a patient with a very aggressive complement-mediated aHUS and rapid early recurrence after withdrawal of eculizumab, which was successfully resolved after restarting eculizumab.

The optimal duration of aHUS treatment and the correlations between genetic abnormalities and prognosis are not yet known. Historically, clinicians prefer to discontinue the plasma therapy for aHUS as soon as the patient is in remission, and treatment cessation has been included in the official recommendation for the management of this disease [14,15]. By

This work is licensed under Creative Common Attribution-NonCommercial-NoDerivatives 4.0 International (CC BY-NC-ND 4.0)

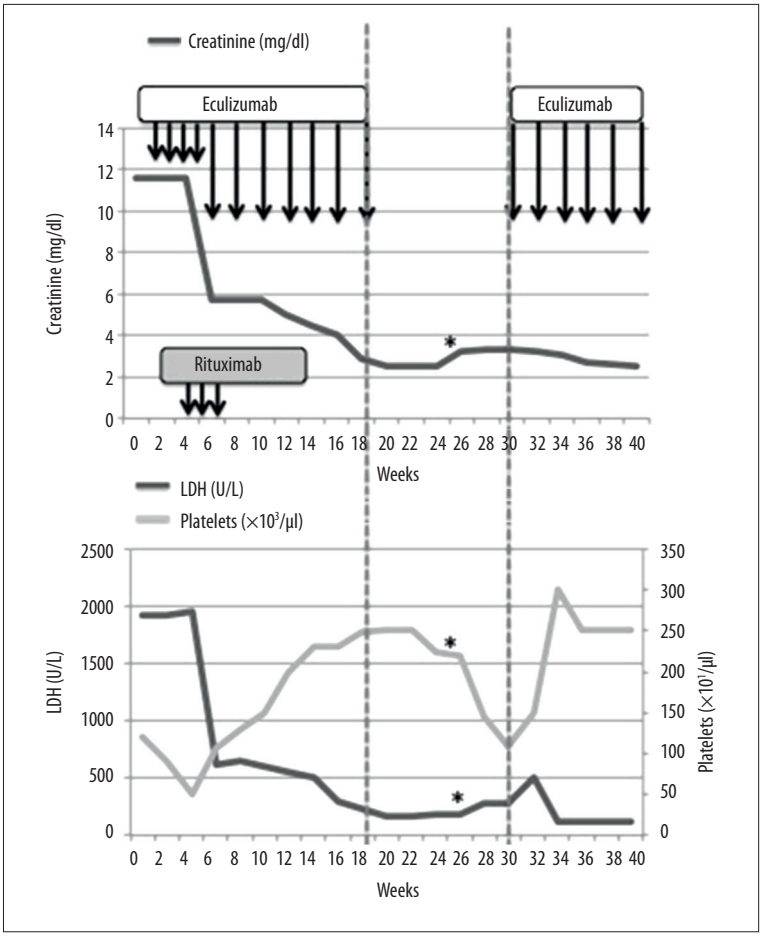

Figure 1. Hematologic parameters and renal function in a patient with aHUS after treatment with eculizumab and rituximab. Eculizumab was administered following an induction dose of 900 mg IV per week for four weeks, 1,200 mg at week five, followed by maintenance dose of 1,200 mg every two weeks until week 18. Moreover, the patient received a dose of rituximab (375 mg/m^2) during weeks three, four, and five. Hematological and renal parameters showing TMA recurrence during weeks 24–28 (*). Restart of eculizumab at week 30 and consequently normalization of TMA parameters.

contrast, individuals with genetic defects in the complement system are frequently plasma treatment-dependent and require long-term weekly or biweekly plasma therapy to maintain remission [9]. Similarly, early cessation of eculizumab treatment is associated with a recurrence of aHUS [3,19,20], probably because eculizumab is a terminal cascade blocking agent, and C3 convertase initially remains active in the glomerular vasculature [9]. A sustained course of treatment could be optimal to maintain the inhibition of complement activity. However, the very high cost of eculizumab and the unknown long-term effects of this treatment suggest that when deciding the optimal duration of treatment multiple variables should be considered [21].

Several investigators have attempted to design individualized therapeutic schedules including the use of eculizumab and withdrawal protocols to avoid the risk of irreversible aHUS relapse [22–27].

The monitoring of the complement-pathway activity tests might provide insight into the efficacy of aHUS treatment and enable the prediction of therapeutic responses and the implementation of new treatment possibilities [24]. A consensus has not yet been reached regarding the role of complement biomarker profiling (that is, measuring complement breakdown products and complement activity) as a tool for characterizing patients with aHUS [3]. Several biomarkers have been proposed [23,25,26] for the measurement of complement functional activity, including the membrane attack complex (C5b–C9), C3, and C5. Other measurable disease-activity markers, such as haptoglobin, serum lactate dehydrogenase, hemoglobin, platelets count, and creatinine or proteinuria may also be useful. Eculizumab concentrations have also been considered [19].

Contradictory results have been reported following the withdrawal of eculizumab in the treatment of aHUS [21,28–35] (Table 1). However, it is clearly imperative to calibrate the eculizumab withdrawal to the relapse risk factors and patient prognosis. It has been reported that mutations in CFH, CFB, CFI, and C3 are all associated with poor outcomes in aHUS; the risks of ESRD or death at 3–5 years of follow-up are as high as 77% among patients with CFH mutations and 30–40% in individuals with CFI, CFB, or C3 mutations [3,4,7]. These patients should therefore be considered as candidates for sustained anti-complement treatment [9,19,20]. Strict monitoring with twice-weekly urine dipstick tests has also been suggested [21,24] for the

This work is licensed under Creative Common Attribution-NonCommercial-NoDerivatives 4.0 International (CC BY-NC-ND 4.0)

Table 1. Outcomes due to complement anomaly after eculizumab withdrawal in nine patients with atypical hemolytic uremic syndrome (HUS) involving their native kidneys. Adapted from Loirat et al. [19] and Fakhouri et al. [31].

	Age (years)	Compl. alteration	Eculizumab duration until withdrawal	Relapse	Creatinine at presentation (first onset) (mg/dL)	Cr at last (mg/dL)	Familial back ground	Trigger
Carr et al. [28]	20	CFH mut	9 months	Yes	Dialysis	Free of dialysis	Non identified	Post cesarean
Fakouri et al. (p1) [31]	26	CFH+CFI mut	19 months	No	Dialysis	70	Yes	Postpartum
Ardissimo et al. (p2) [21]	37.7	CFH mut	14 months	Yes	1.41	1.15	Non identified	Non identified
Ardissimo et al. (p3) [21]	52.7	CFI mut	1.5 months	No	1.03	0.88	Non identified	Non identified
Ardissimo et al. (p4) [21]	34.8	CFI mut	11.5 months	No	2.72	2.21	Non identified	Non identified
Fakhouri et al. (p2) [31]	22	MPC mut	8 weeks	No	2.34	0.84	Yes	Diarrhea
Fakouri et al. (p4) [31]	49	Anti CFH Ab	8 weeks	No	3.5	0.88	No	Non identified
Ardissimo et al. (p7) [21]	19	Anti CFH Ab	5.5 months	No	1.33	1.06	Non identified	Non identified
Canigral et al. [35]	32	None identified	6 months	No	4.42	0.88	No	Hysterectomy

early detection of relapse, which can be treated with the immediate re-initiation of complement blockade. Some investigators have discouraged the discontinuation of eculizumab therapy in patients with severe extra-renal manifestations [19] after kidney transplantation [36,37], and when the glomerular filtration rate is <20 mL/min/1.73 m^2 at the time of aHUS presentation [38].

In some cases, eculizumab can be safely discontinued. Theoretically, in the case of antibody-mediated aHUS, the elimination of the antibody and the maintenance of immunosuppression therapy may be sufficient to control the syndrome [1,22,23]. An international consensual approach to the management of aHUS in children [19] recommended cessation of eculizumab therapy when the anti-CFH antibody titre is <1,000 AU/mL. Eculizumab cessation has also been recommended for antibody titres <2.5 times the upper limit of normal [38]. Immune suppression with cyclophosphamide or rituximab without anti-complement therapy has proved beneficial in antibody-mediated aHUS [39] Furthermore, withdrawal of eculizumab might be successful in individuals with isolated CD46 [9,19,20].

In individuals in whom TMA has been controlled but renal function has not recovered, eculizumab has occasionally been discontinued, but this experience is currently too limited to justify a recommendation of continuous treatment with eculizumab for individuals on long-term dialysis routinely. A mutation in C5 that predicts a poor response to eculizumab has been described in a Japanese population. In individuals with aHUS who fail to respond to eculizumab, plasma exchange should be recommenced, and genetic analysis of C5 should be performed [40,41] (Figure 2).

Taking into account the genetic results, the history of several episodes of TMA, and the aggressive relapse of the disease, our patient was presumably at high risk for the development of ESRD and recurrence of aHUS, even though she presented with a CD46 mutation which is associated with a better prognosis than a mutation in CFH. We postulated that

This work is licensed under Creative Common Attribution-NonCommercial-NoDerivatives 4.0 International (CC BY-NC-ND 4.0)

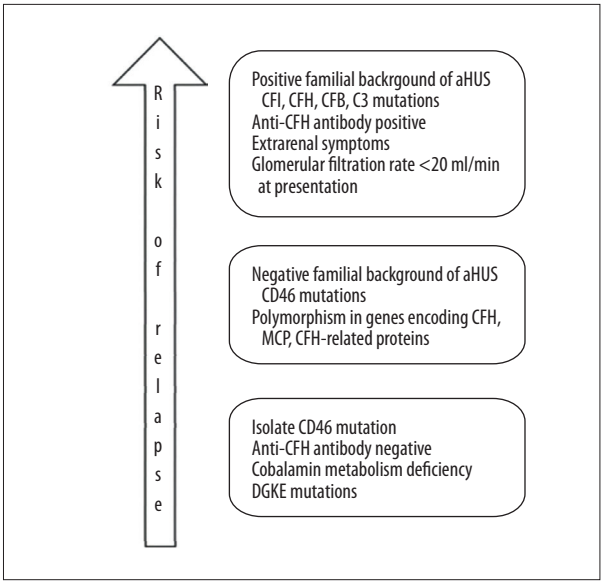

Figure 2. Graphic representation of aHUS relapse risk after eculizumab withdrawal. In the cases of the third figure, eculizumab is not indicated since their pathology does not always seem to involve the complement system.

the aforementioned criteria could be a good reason to avoid discontinuation of eculizumab in these types of patients and long-term maintenance treatment with eculizumab could be beneficial and appropriate.

Additional studies are required to provide more information on the utility of routine complement-pathway functional tests and other biomarkers, as well as genetic studies, to determine the eculizumab dosing schedules for individual patients. The current evidence does not support the cessation of eculizumab treatment in patients with CFH, CFB, CFI, or C3 mutations, whereas therapy could be stopped if close monitoring is performed in patients with mutations associated with better prognosis. However, our case report demonstrated that the withdrawal of eculizumab in patients with CD46 mutations is not always safe. An improved understanding of the interplay between different genetic alterations and multi-organ pathology in aHUS is required to determine which patients will benefit the most from a long-term anti-complement treatment.

Conclusions

This case highlights the clinical challenges of the diagnosis and management of patient with aHUS with complement-mediated TMA involvement. Attention was paid to the consequences of treatment withdrawal. Exact information regarding genetic abnormalities and renal function associated with aHUS, as well as estimation of the relapse risk and the monitoring of complement tests may provide insights into the efficacy of aHUS treatment, which will enable the prediction of therapeutic responses and the testing of new treatment options.

Conflict of interests

None.

References:

1. Fremeaux-Bacchi V, Fakhouri F, Garnier A et al: Genetics and outcome of atypical hemolytic uremic syndrome: A nationwide French series comparing children and adults. Clin J Am Soc Nephrol, 2013; 8(4): 554–62
2. Moake JL: Thrombotic microangiopathies. N Engl J Med, 2002; 347(8): 589–600
3. Nester CM, Barbour T, de Cordoba SR et al: Atypical aHUS: State of the art. Mol Immunol, 2015; 67(1): 31–42
4. Noris M, Remuzzi G: Atypical hemolytic-uremic syndrome. N Engl J Med, 2009; 361(17): 1676–87
5. Cataland SR, Wu HM: Atypical hemolytic uremic syndrome and thrombotic thrombocytopenic purpura: Clinically differentiating the thrombotic microangiopathies. Eur J Intern Med, 2013; 24(6): 486–91
6. Roumenina LT, Jablonski M, Hue C et al: Hyperfunctional C3 convertase leads to complement deposition on endothelial cells and contributes to atypical hemolytic uremic syndrome. Blood, 2009; 114(13): 2837–45
7. Noris M, Caprioli J, Bresin E et al: Relative role of genetic complement abnormalities in sporadic and familial aHUS and their impact on clinical phenotype. Clin J Am Soc Nephrol, 2010; 5(10): 1844–59
8. Kemper C, Pangburn MK, Fishelson Z: Complement nomenclature 2014. Mol Immunol, 2014; 61(2): 56–58
9. Wong EKS, Goodship THJ, Kavanagh D: Complement therapy in atypical haemolytic uraemic syndrome (aHUS). Mol Immunol, 2013; 56(3): 199–212
10. Ermini L, Goodship THJ, Strain L et al: Common genetic variants in complement genes other than CFH, CD46 and the CFHRs are not associated with aHUS. Mol Immunol, 2012; 49(4): 640–48
11. Esparza-Gordillo J, Goicoechea de Jorge E, Buil A et al: Predisposition to atypical hemolytic uremic syndrome involves the concurrence of different susceptibility alleles in the regulators of complement activation gene cluster in 1q32. Hum Mol Genet, 2005; 14(5): 703–12
12. Caprioli J, Noris M, Brioschi S et al: Genetics of HUS: the impact of MCP, CFH, and IF mutations on clinical presentation, response to treatment, and outcome. Blood, 2006; 108(4): 1267–79
13. Scully M, Goodship T: How I treat thrombotic thrombocytopenic purpura and atypical haemolytic uraemic syndrome. Br J Haematol, 2014; 164(6): 759–66
14. Campistol JM, Arias M, Ariceta G et al: An update for atypical haemolytic uraemic syndrome: Diagnosis and treatment. A consensus document. Nefrologia, 2015; 35(5): 421–47
15. Taylor CM, Machin S, Wigmore SJ, Goodship THJ: Clinical practice guidelines for the management of atypical haemolytic uraemic syndrome in the United Kingdom. Br J Haematol, 2010; 148(1): 37–47
16. Ariceta G, Besbas N, Johnson S et al: Guideline for the investigation and initial therapy of diarrhea-negative hemolytic uremic syndrome. Pediatr Nephrol, 2009; 24(4): 687–96
17. Legendre CM, Licht C, Muus P et al: Terminal complement inhibitor eculizumab in atypical hemolytic-uremic syndrome. N Engl J Med, 2013; 368(23): 2169–81
18. Rafiq A, Tariq H, Abbas N, Shenoy R: Atypical hemolytic-uremic syndrome: A case report and literature review. Am J Case Rep, 2015; 16: 109–14
19. Loirat C, Fakhouri F, Ariceta G et al: An international consensus approach to the management of atypical hemolytic uremic syndrome in children. Pediatr Nephrol, 2016; 31(1): 15–39

This work is licensed under Creative Common Attribution-NonCommercial-NoDerivatives 4.0 International (CC BY-NC-ND 4.0)

20. Campistol JM, Arias M, Ariceta G et al: An update for atypical haemolytic uraemic syndrome: Diagnosis and treatment. A consensus document. Nefrologia, 2013; 33(1): 27–45
21. Ardissino G, Testa S, Possenti I et al: Discontinuation of eculizumab maintenance treatment for atypical hemolytic uremic syndrome: A report of 10 cases. Am J Kidney Dis, 2014; 64(4): 633–37
22. Dragon-Durey M-A, Sethi SK, Bagga A et al: Clinical features of anti-factor H autoantibody-associated hemolytic uremic syndrome. J Am Soc Nephrol, 2010; 21(12): 2180–87
23. Heinen S, Pluthero FG, van Eimeren VF et al: Monitoring and modeling treatment of atypical hemolytic uremic syndrome. Mol Immunol, 2013; 54(1): 84–88
24. Cugno M, Gualtierotti R, Possenti I et al: Complement functional tests for monitoring eculizumab treatment in patients with atypical hemolytic uremic syndrome. J Thromb Haemost, 2014; 12(9): 1440–48
25. Cugno M, Tedeschi S, Ardissino G: Tailored eculizumab regimen for patients with atypical hemolytic uremic syndrome: Requirement for comprehensive complement analysis: comment. J Thromb Haemost, 2015; 13(3): 485–86
26. Xie L, Nester CM, Reed AI et al: Tailored eculizumab therapy in the management of complement factor H-mediated atypical hemolytic uremic syndrome in an adult kidney transplant recipient: A case report. Transplant Proc, 2012; 44(10): 3037–40
27. Mussoni MP, Veneziano FA, Boetti L et al: Innovative therapeutic approach: Sequential treatment with plasma exchange and eculizumab in a pregnant woman affected by atypical hemolytic-uremic syndrome. Transfus Apher Sci, 2014; 51(2): 134–36
28. Carr R, Cataland SR: Relapse of aHUS after discontinuation of therapy with eculizumab in a patient with aHUS and factor H mutation. Ann Hematol, 2013; 92(6): 845–46
29. Alachkar N, Bagnasco SM, Montgomery RA: Eculizumab for the treatment of two recurrences of atypical hemolytic uremic syndrome in a kidney allograft. Transpl Int, 2012; 25(8): e93–95
30. Chatelet V, Fremeaux-Bacchi V, Lobbedez T et al: Safety and long-term efficacy of eculizumab in a renal transplant patient with recurrent atypical hemolytic-uremic syndrome. Am J Transplant, 2009; 9(11): 2644–45
31. Fakhouri F, Delmas Y, Provot F et al: Insights from the use in clinical practice of eculizumab in adult patients with atypical hemolytic uremic syndrome affecting the native kidneys: an analysis of 19 cases. Am J Kidney, 2014; 63(1): 40–48
32. Cornec-Le Gall E, Delmas Y, De Parscau L et al: Adult-onset eculizumab-resistant hemolytic uremic syndrome associated with cobalamin C deficiency. Am J Kidney, 2014; 63(1): 119–23
33. Gulleroglu K, Fidan K, Hancer VS et al: Neurologic involvement in atypical hemolytic uremic syndrome and successful treatment with eculizumab. Pediatr Nephrol Berl Ger, 2013; 28(5): 827–30
34. Pu JJ, Sido A: Successful discontinuation of eculizumab therapy in a patient with aHUS. Ann Hematol, 2014; 93(8): 1423–25
35. Canigral C, Moscardo F, Castro C et al: Eculizumab for the treatment of pregnancy-related atypical hemolytic uremic syndrome. Ann Hematol, 2014; 93(8): 1421–22
36. Kasapoglu U, Ruhi C, Tugcu M et al: Prophylactic eculizumab use in kidney transplantation: A review of the literature and report of a case with atypical hemolytic uremic syndrome. Ann Transplant, 2015; 20: 714–19
37. Santos AHJ, Casey MJ, Wen X et al: Outcome of kidney transplants for adults with hemolytic uremic syndrome in the U.S.: A ten-year database analysis. Ann Transplant, 2014; 19: 353–61
38. Ardissino G, Possenti I, Tel F et al: Discontinuation of eculizumab treatment in atypical hemolytic uremic syndrome: An update. Am J Kidney, 2015; 66(1): 172–73
39. Lionet A, Provot F, Glowacki F et al: A case of adult atypical haemolytic uraemic syndrome related to anti-factor H autoantibodies successfully treated by plasma exchange, corticosteroids and rituximab. NDT Plus, 2009; 2(6): 458–60
40. Razzak M: Anaemia: Mutations in C5 explain eculizumab resistance. Nat Rev Nephrol, 2014; 10(4): 182
41. Nishimura J, Yamamoto M, Hayashi S et al: Genetic variants in C5 and poor response to eculizumab. N Engl J Med, 2014; 370(7): 632–39

This work is licensed under Creative Common Attribution-NonCommercial-NoDerivatives 4.0 International (CC BY-NC-ND 4.0)