

# Occult Andersson lesions in patients with ankylosing spondylitis: undetectable destructive lesions on plain radiographs

Ji-Chen Huang, Bang-Ping Qian, Yong Qiu, Bin Wang, Yang Yu, Shi-Zhou Zhao

Department of Spine Surgery, Affiliated Drum Tower Hospital, Medical School of Nanjing University, Nanjing, Jiangsu 210008, China.

## Abstract

**Background:** Andersson lesions (ALs) are not uncommon in ankylosing spondylitis (AS). Plain radiography (PR) is widely used for the diagnosis of ALs. However, in our practice, there were some ALs in AS patients that could not be detected on plain radiographs. This study aimed to propose the concept of occult ALs and evaluate the prevalence and radiographic characteristics of the occult ALs in AS patients.

**Methods:** A total of 496 consecutive AS patients were admitted in the Affiliated Drum Tower Hospital, Medical School of Nanjing University between April 2003 and November 2019 and they were retrospectively reviewed. The AS patients with ALs who met the following criteria were included for the investigation of occult ALs: (1) with pre-operative plain radiographs of the whole-spine and (2) availability of pre-operative computed tomography (CT) and/or magnetic resonance imaging (MRI) of the whole-spine. The occult ALs were defined as the ALs which were undetectable on plain radiographs but could be detected by CT and/or MRI. The extensive ALs involved the whole discovertebral junction or manifested as destructive lesions throughout the vertebral body. Independent-samples *t* test was used to compare the age between the patients with only occult ALs and those with only detectable ALs. Chi-square or Fisher exact test was applied to compare the types, distribution, and radiographic characteristics between detectable and occult ALs as appropriate.

**Results:** Ninety-two AS patients with a mean age of  $44.4 \pm 10.1$  years were included for the investigation of occult ALs. Twenty-three patients had occult ALs and the incidence was 25% (23/92). Fifteen extensive ALs were occult, and the proportion of extensive ALs was significantly higher in detectable ALs (97% vs. 44%,  $\chi^2 = 43.66$ ,  $P < 0.001$ ). As assessed by PR, the proportions of osteolytic destruction with reactive sclerosis (0 vs. 100%,  $\chi^2 = 111.00$ ,  $P < 0.001$ ), angular kyphosis of the affected discovertebral units or vertebral body (0 vs. 22%,  $\chi^2 = 8.86$ ,  $P = 0.003$ ), formation of an osseous bridge at the intervertebral space adjacent to ALs caused by the ossification of the anterior longitudinal ligament (38% vs. 86%,  $\chi^2 = 25.91$ ,  $P < 0.001$ ), and an abnormal height of the affected intervertebral space were all significantly lower in occult ALs (9% vs. 84%,  $\chi^2 = 60.41$ ,  $P < 0.001$ ).

**Conclusions:** Occult ALs presented with more subtle radiographic changes. Occult ALs should not be neglected, especially in the case of extensive occult ALs, because the stability of the spine might be severely impaired by these lesions.

**Keywords:** Ankylosing spondylitis; Andersson lesions; Occult; Radiographic characteristics

## Introduction

Andersson lesions (ALs), first described in 1937, are a well-recognized complication in patients with ankylosing spondylitis (AS).<sup>[1-3]</sup> Apart from ALs, various terms have been used to describe this complication, including discitis, spondylodiscitis, destructive vertebral lesions, discovertebral lesions, and pseudarthrosis are used to describe this kind of complication. These various terms reflect the controversies in the etiology, pathophysiologic characteristics, and diagnostic criteria of ALs.<sup>[4-8]</sup> ALs mainly affect the discovertebral junction of the spine and may cause localized pain and tenderness. Some ALs can be asymp-

tomatic or present with back pain which is similar to the pain that may occur during the natural course of AS, which may only be detected on radiographic examination, many years later.<sup>[9]</sup> The delayed diagnosis and management of ALs may contribute to the patients' progressively deteriorating pain or kyphotic deformity, and may even cause neurologic deficits resulting from the overgrowth of fibrous or osseous tissue and subsequent spinal stenosis.<sup>[9,10]</sup>

Plain radiography (PR) is the most widely used imaging technique for the diagnosis of ALs. The vertebral segments affected by ALs can be localized on plain radiographs with high convenience and relatively low cost. However, some

## Access this article online

Quick Response Code:



Website:

www.cmj.org

DOI:

10.1097/CM9.0000000000001557

**Correspondence to:** Dr. Bang-Ping Qian, Affiliated Drum Tower Hospital, Medical School of Nanjing University, Zhongshan Road 321, Nanjing, Jiangsu 210008, China E-Mail: qianbangping@163.com

Copyright © 2021 The Chinese Medical Association, produced by Wolters Kluwer, Inc. under the CC-BY-NC-ND license. This is an open access article distributed under the terms of the Creative Commons Attribution-Non Commercial-No Derivatives License 4.0 (CCBY-NC-ND), where it is permissible to download and share the work provided it is properly cited. The work cannot be changed in any way or used commercially without permission from the journal.

Chinese Medical Journal 2021;134(12)

Received: 16-12-2020 Edited by: Ning-Ning Wang

ALs may be missed on plain radiographs, necessitating more advanced imaging techniques such as computed tomography (CT) and magnetic resonance imaging (MRI).<sup>[11,12]</sup> Chan *et al*<sup>[11]</sup> found that CT was superior to PR for the identification of the vacuum phenomenon, paravertebral soft tissue swelling, posterior element defects, and spinal stenosis in patients with AS, who had developed pseudarthrosis. In a study comparing PR and MRI for the detection of ALs in 62 patients with AS, whole-spine MRI detected ALs in 53 (85%) patients, while PR identified ALs in only 23 (37%) patients.<sup>[12]</sup>

In our practice, we have found that some ALs that are identifiable on CT and/or MRI are undetectable on plain radiographs. We, therefore, propose the term “occult ALs” to facilitate academic communication of this phenomenon. Occult ALs are defined as ALs that can be identified by CT and/or MRI but that are undetectable by PR. In contrast, detectable ALs are defined as ALs that can be detected on plain radiographs. A patient with AS is considered to have occult ALs if either of the following two criteria is satisfied: (1) no ALs are detectable on plain radiographs, whereas one or several ALs can be identified on CT and/or MRI, or (2) only one or several of the ALs are observed on plain radiographs, while the others are only detectable on CT and/or MRI.

The purpose of this study was three-fold: (1) to evaluate the prevalence of ALs and occult ALs in a large series of patients with AS; (2) to compare the types, distribution, and radiographic characteristics between detectable and occult ALs; and (3) to investigate the causes of occult ALs and the clinical relevance of detecting occult ALs by CT and/or MRI.

## Methods

### Ethical approval

This study was approved by the Institutional Review Board of Affiliated Drum Tower Hospital, Medical School of Nanjing University (No. 2011052) and informed consent was obtained from all patients.

### Patients

A retrospective review of 496 consecutive AS patients admitted in our institution between April 2003 and November 2019 was performed. After excluding tumors, tuberculosis, and other osteodestructive lesions of the spine, ALs were diagnosed to ascertain if any of the following findings were present<sup>[8,13-15]</sup>: (1) osteolytic destruction of the vertebral endplates and/or vertebral body with sclerosis on plain radiographs; (2) irregular vertebral and/or discovertebral osteolysis with reactive sclerosis on CT; and (3) irregular, low-signal intensity, or a mixture of hypointense and isointense signals of the intervertebral discs on the T1-weighted MRI, and irregular, low-signal intensity, mixture of isointense and hypointense signals, or a mixture of hyperintense, isointense, and hypointense signals of the intervertebral discs on the T2-weighted MRI. If the CT findings did not match with the MRI findings, the diagnosis of ALs was

based on CT. In total, 107 patients with AS had pre-operative ALs. To investigate the presence and radiographic characteristics of occult ALs, the AS patients with ALs who met both of the following criteria were included: (1) availability of pre-operative plain radiographs of the whole-spine and (2) with pre-operative CT and/or MRI of the whole-spine. Finally, 92 patients with AS, who had ALs, were enrolled in this study for further analysis. All 92 patients underwent surgery. Seventy patients underwent osteotomy because of severe thoracolumbar kyphosis, 47 of whom underwent osteotomy below or above the ALs, and 23 of whom underwent osteotomy through the ALs. Fixation covering the ALs without osteotomy was performed in 22 patients, nine of whom underwent posterior decompression at the ALs.

### Assessment of ALs by PR

The following features were assessed on plain radiographs of the whole-spine: erosion of the vertebral endplates and/or vertebral body, reactive sclerosis, height of the affected intervertebral space, angular kyphosis of the affected discovertebral units (DVUs) or vertebral body, dislocation of the AL site, and the formation of an osseous bridge at the intervertebral space adjacent to the ALs due to ossification of the anterior longitudinal ligament (OALL).

### Assessment of ALs by CT

The following features were evaluated on CT of the whole-spine: osteolytic destruction with reactive sclerosis, vacuum phenomenon, involvement of the posterior column, ossification of the posterior longitudinal ligament (OPLL), ossification of the ligamentum flavum (OLF), and dural ossification at the site of the ALs.

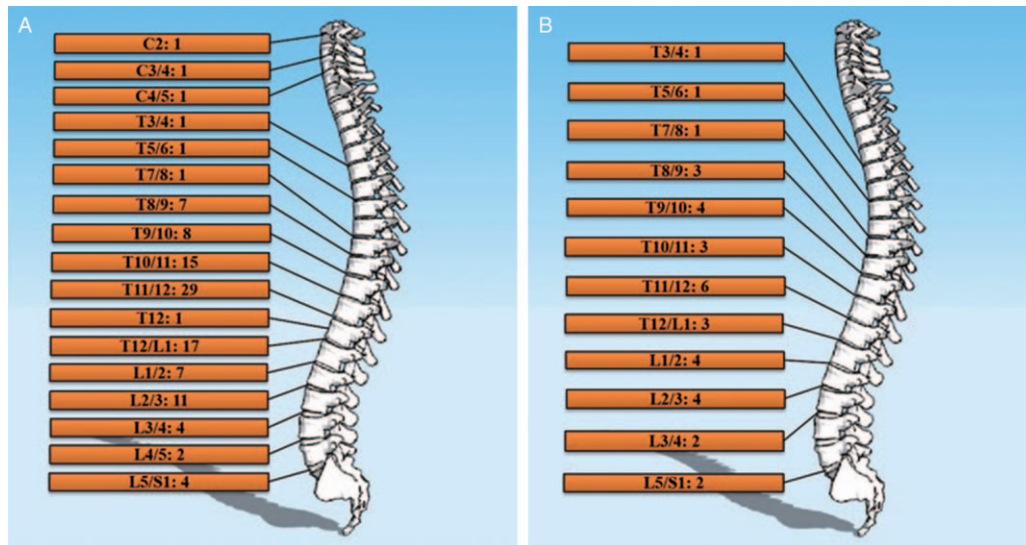
### Assessment of ALs by MRI

Whole-spine MRI was performed, and ALs were assessed via T1- and T2-weighted MRI sequences. The signal intensity of the affected intervertebral discs, subchondral bone marrow edema, and fat deposition was investigated by T1- and T2-weighted MRI.

Additionally, the presence and cause of spinal stenosis were assessed by CT and/or MRI. CT and/or MRI were also used to determine the level of ALs and the exact location of each AL. The ALs were classified into five types according to their location (modified from Kim *et al*<sup>[12]</sup>): Type 1 (central type), which was located at the middle third of the discovertebral junction; Type 2 (anterior peripheral type), located at the anterior third; Type 3 (posterior peripheral type), located at the posterior third; Type 4 (diffuse discs type), involving the whole discovertebral junction; and Type 5 (diffuse body type), characterized by destructive lesions throughout the vertebral body. Types 1 to 3 were defined as localized ALs, and Types 4 and 5 were regarded as extensive ALs in this study.

### Statistical analysis

Continuous variables were compared using an independent-samples *t* test. The Chi-square test or Fisher exact test



**Figure 1:** Distribution of ALs. The distribution of all the ALs (A) and the distribution of occult ALs (B). ALs: Andersson lesions; C: Cervical; L: Lumbar; T: Thoracic.

Table 1: Comparison of the types, distribution, and radiographic characteristics between detectable and occult ALs.				
Variables	Detectable ALs (n = 77)	Occult ALs (n = 34)	Statistics	P
Extensive ALs (n = 90)	75	15	43.66	<0.001
Distribution			-	0.034
Cervical spine (C1–C7)	3	0		
Thoracic spine (T1–T9/10)	8	10		
Thoracolumbar junction (T10–L2)	53	16		
Lumbar spine (L2/3–L5/S1)	13	8		
Osteolytic destruction of vertebral endplates and/or vertebral body with reactive sclerosis on plain radiographs (n = 77)	77	0	111.00	<0.001
Angular kyphosis of the affected DVUs or vertebral body on plain radiographs (n = 17)	17	0	8.86	0.003
OALL-induced formation of an osseous bridge at the intervertebral space adjacent to the ALs on plain radiographs (n = 79)	66	13	25.91	<0.001
An abnormal height of the affected intervertebral space on plain radiographs (n = 68)	65	3	60.41	<0.001
Dislocation at the AL site on plain radiographs (n = 9)	9	0	-	0.055
Involvement of posterior column (n = 70)	58	12	16.23	<0.001

AL: Andersson lesion; DVU: Discovertebral unit; OALL: Ossification of the anterior longitudinal ligament. "-":not available.

was applied to compare the categorical variables, as appropriate. Quantitative variables are expressed as mean ± standard deviation, and qualitative variables are expressed as raw numbers. Statistical analyses were performed by SPSS 18.0 software (IBM Corp., Armonk, NY, USA). A P value of <0.05 was considered statistically significant.

**Results**

**Types and distribution of ALs**

Of the 496 patients with AS, 107 patients had pre-operative ALs (incidence of 22%). Ninety-two patients with AS complicated by ALs (mean age, 44.4 ± 10.1 years) were included in the investigation of occult ALs, and 23 (25%) patients have occult ALs. The AS patients with only occult ALs were significantly younger than those with only detectable ALs (40.32 ± 12.62 vs. 45.93 ± 9.12 years,

respectively;  $t = -2.18$ ,  $P = 0.032$ ). The sex distribution was similar between patients with only occult ALs (17 men and two women) and those with only detectable ALs (55 men and 14 women) ( $P = 0.505$ ). Among the 92 patients, 80 had one AL each and 12 had multiple ALs. In total, 111 ALs were observed, among which 77 were detectable on plain radiographs (detectable ALs), while 34 were unidentifiable on plain radiographs (occult ALs). There were 21 localized ALs (Type 1:  $n = 16$ ; Type 2:  $n = 3$ ; Type 3:  $n = 2$ ) and 90 extensive ALs (Type 4:  $n = 88$ ; Type 5:  $n = 2$ ). The 90 extensive ALs were observed in 83 patients. All the patients with extensive ALs had back pain or neck pain located at the site of the ALs. Twelve (14.5%) of the eighty-three patients had compromised neurological function pre-operatively due to extensive ALs. Most of the ALs were located at the thoracolumbar junction (T10–L2,  $n = 69$ ) [Figure 1A]. The distribution of the ALs was significantly different between detectable and occult ALs ( $P = 0.034$ ) [Table 1]. The most common sites of detectable

ALs were the thoracolumbar junction ( $n = 53$ ) and lumbar spine ( $n = 13$ ), while occult ALs were most commonly located at the thoracolumbar junction ( $n = 16$ ) and thoracic spine ( $n = 10$ ). The distributions of all the ALs and occult ALs are shown in Figure 1.

### Findings on plain radiographs

Osteolytic destruction of the vertebral endplates and/or vertebral body with reactive sclerosis was observed in 77 ALs by PR, among which angular kyphosis of the affected DVUs or vertebral body was found in 17 ALs. Dislocation of the AL site and OALL-induced formation of an osseous bridge at the intervertebral space adjacent to the ALs were detected in nine and 66 ALs, respectively. Among the 75 detectable ALs with discovertebral junction involvement, 65 ALs showed an obviously abnormal height of the intervertebral space (widened or narrowed).

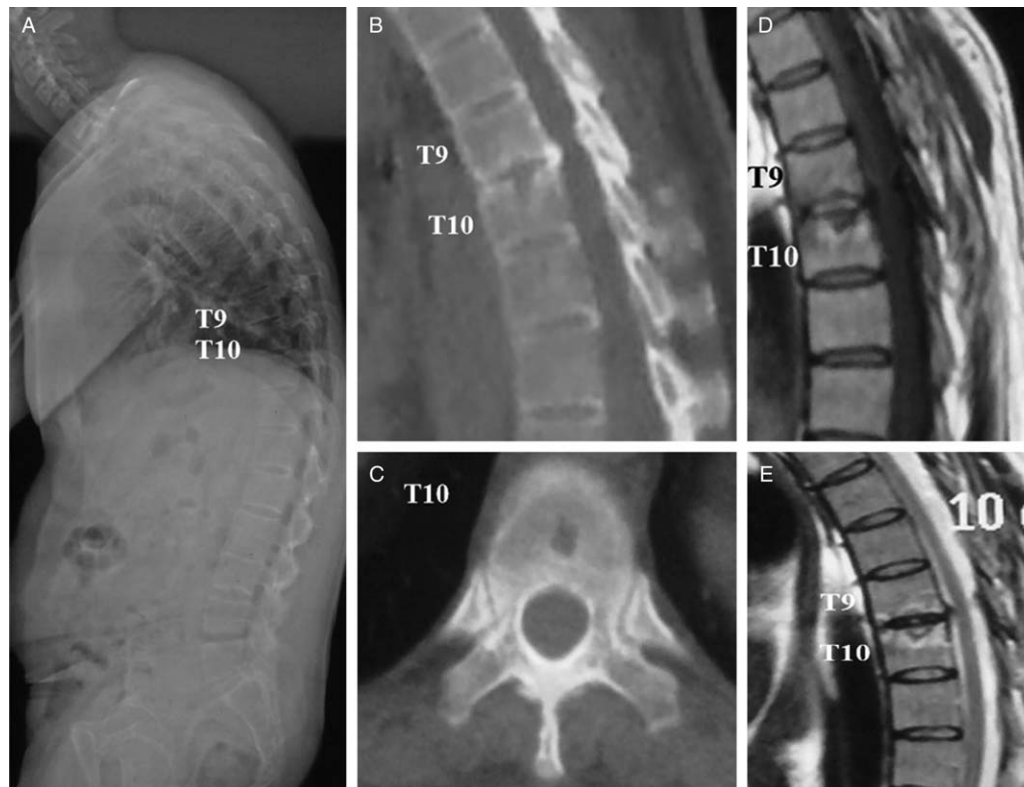
The level and exact location of the 34 occult ALs that were undetectable by PR were identified by CT and/or MRI [Figures 2–5]. The characteristics of these ALs on plain radiographs were then investigated after the determination of their location by CT and/or MRI. No obvious osteolysis of the vertebral endplates or vertebral body with reactive sclerosis was found on plain radiographs of the occult ALs. Additionally, no angular kyphosis or dislocation was observed at the occult AL site. OALL-induced formation of an osseous bridge at the intervertebral space adjacent to the

ALs was detected in 13 occult ALs. Only three occult ALs presented with an abnormal height of the intervertebral space. As assessed by PR, the proportions of osteolytic destruction with reactive sclerosis, angular kyphosis of the affected DVUs or vertebral body, OALL-induced formation of an osseous bridge at the intervertebral space adjacent to the ALs, and an abnormal height of the affected intervertebral space were all significantly lower in occult ALs than in detectable ALs ( $P < 0.05$ ) [Table 1]. The proportion of dislocation at the AL site was also much lower in occult than detectable ALs, although the difference did not reach statistical significance ( $P = 0.055$ ) [Table 1].

Erosion of the vertebral endplates and/or vertebral body with reactive sclerosis was observed in 75 (83%) extensive ALs on plain radiographs. An abnormal height of the affected intervertebral space was found in 67 (74.4%) extensive ALs on plain radiographs. Angular kyphosis of the affected DVUs and dislocation at the AL site were present in 17 and nine extensive ALs on plain radiographs, respectively.

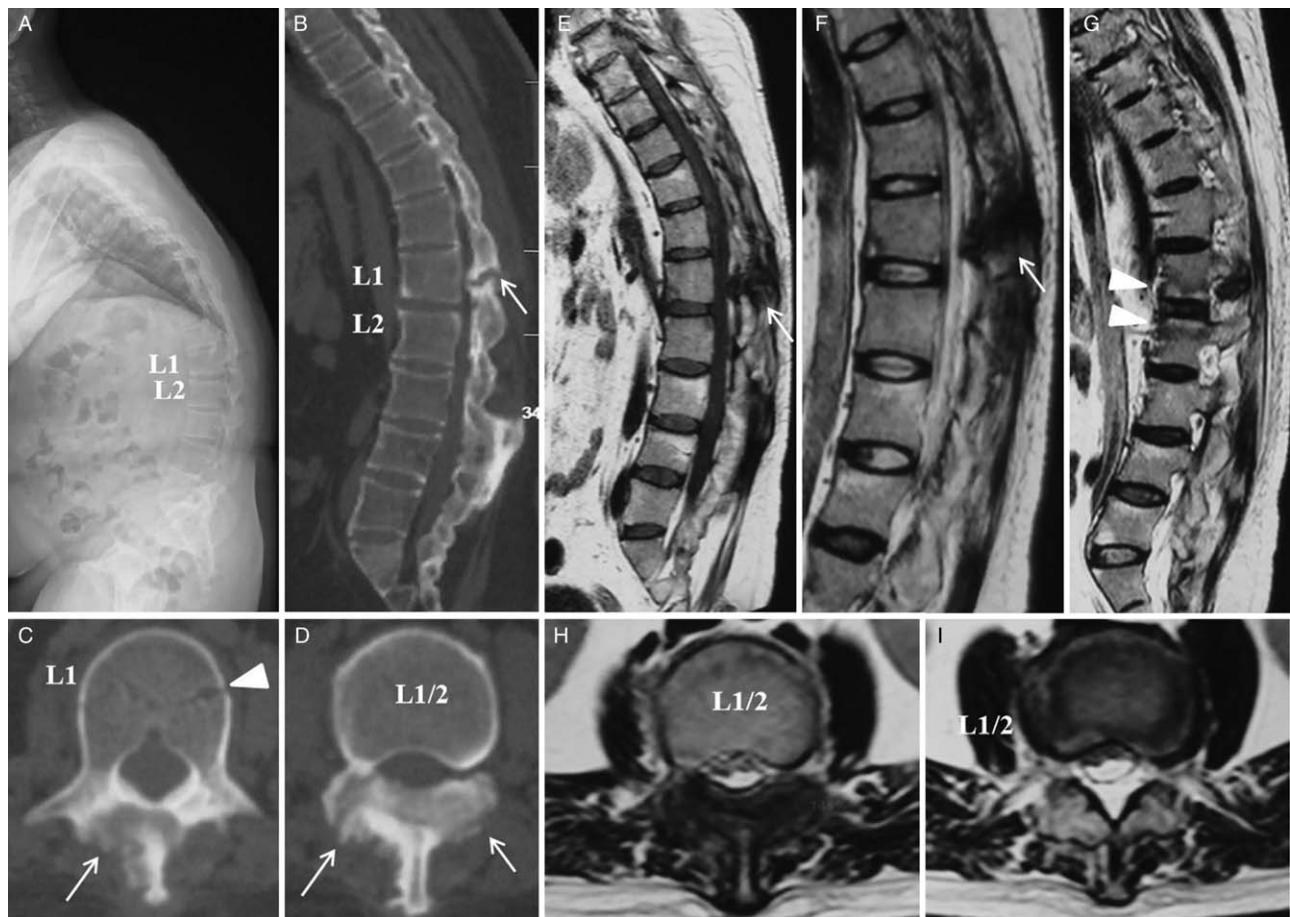
### CT characteristics of ALs

Whole-spine CT scans were available in 88 of the 92 patients with ALs, and 107 ALs were identified. All 107 ALs had irregular osteolysis with sclerosis on CT. The vacuum phenomenon on CT was observed in six ALs, and CT showed posterior column involvement in 75 ALs.

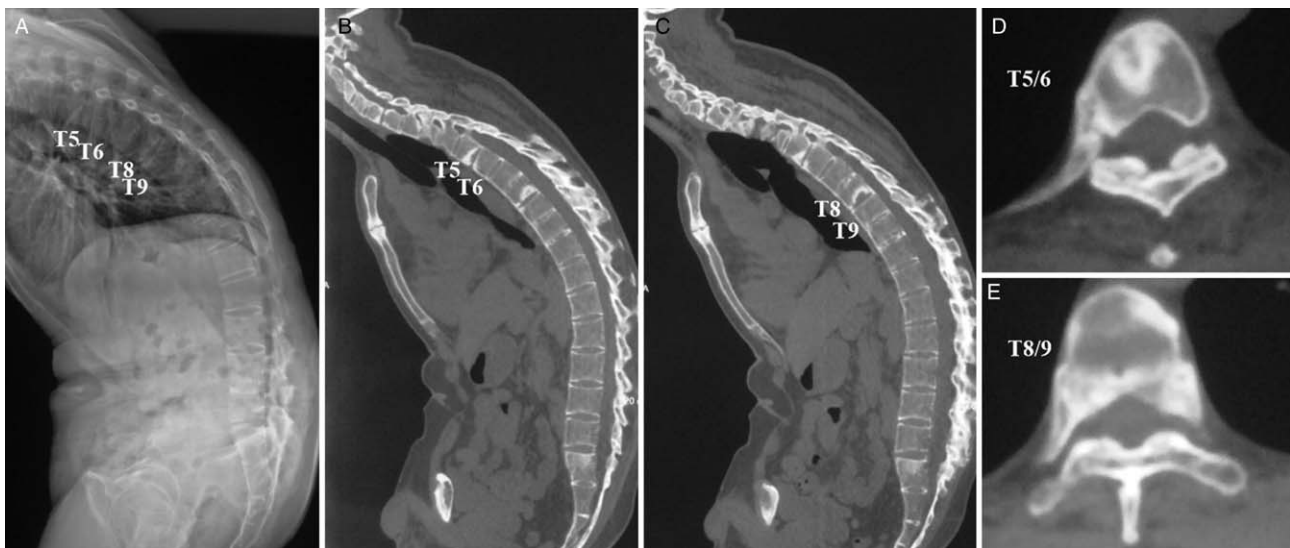


**Figure 2:** A 32-year-old male AS patient had T9/10-localized AL. Osteolytic destruction with reactive sclerosis was not observed on either T9 inferior endplate or T10 superior endplate on the plain radiograph (A); destructive lesions could be detected on T9 inferior endplate and T10 superior endplate on CT (B). On axial CT, osteolysis was clearly identified in the middle of T10 superior endplate (C); destruction of T9/10 DVUs was found on MRI (D), (E). Fatty degeneration of subchondral bone marrow with hyperintense signal on both T1- and T2-weighted MRI was detected in the AL (D), (E). AS: Ankylosing spondylitis; AL: Andersson lesion; CT: Computed tomography; DVU: Discovertebral unit; MRI: Magnetic resonance imaging.





**Figure 3:** A 23-year-old male AS patient had L1/2 AL. No ALs could be identified by PR (A); posterior element defect was found at L1/2 on sagittal CT (B, arrow); fracture line of L1 vertebral body was observed on axial CT (C, arrowhead). Osteolysis with osteosclerosis of lamina and articular processes was present at the AL (C and D, arrow); T1- and T2-weighted MRI showed irregular hypointense signal band in the posterior column at L1/2 level (E and F, arrow). Subchondral bone marrow edema was detected at L1/2 AL (G, arrow head). Destruction of posterior element and intervertebral disc was observed at L1/2 level (H) and (I). AS: Ankylosing spondylitis; AL: Andersson lesion; CT: Computed tomography; MRI: Magnetic resonance imaging; PR: Plain radiography.



**Figure 4:** A 38-year-old male AS patient presented with T5/6 and T8/9 ALs. Thoracolumbar kyphosis was observed on the plain radiograph of the whole-spine (A). The ALs were not identified by PR due to the interference of the projection of lungs and ribs (A); irregular discovertebral osteolysis with reactive sclerosis could be detected at T5/6 and T8/9 levels by both sagittal (B) and (C) and axial CT (D) and (E). AS: Ankylosing spondylitis; AL: Andersson lesion; CT: Computed tomography; PR: Plain radiography.

OPLL, OLF, or dural ossification was found in ten ALs by CT.

Whole-spine CT scans were available in 79 of the 83 patients with extensive ALs, and 84 extensive ALs were identified. Irregular osteolysis with sclerosis was found in all 84 ALs on CT. The vacuum phenomenon was observed in five extensive ALs.

### MRI manifestations of ALs

Whole-spine MRI scans were available in 69 of the 92 patients with ALs, and 86 ALs were detected (one AL was a transvertebral body lesion). The MRI signal changes of the ALs were interpreted as hypointense, hyperintense, or isointense signals compared with the signals of the normal spinal cord. All 85 ALs that affected the intervertebral discs exhibited an irregular hypointense signal ( $n=21$ ) or a mixture of hypointense and isointense signals ( $n=64$ ) of the intervertebral discs on T1-weighted MRI. Thirty-five ALs had an irregular low-intensity signal ( $n=7$ ) or a mixture of isointense and hypointense signals ( $n=28$ ) of the intervertebral discs on T2-weighted MRI. An irregular mixture of hyperintense, isointense, and hypointense signals of the intervertebral discs was observed in 50 ALs on T2-weighted MRI. The presence of an irregular hypointense signal of the intervertebral discs on both T1- and T2-weighted MRI was considered to be caused by fibrous tissue formations or necrosis of the intervertebral discs. The hyperintense signal of the intervertebral discs on T2-weighted MRI might have represented the residual nucleus pulposus.

Subchondral bone marrow edema was found in 32 ALs, which exhibited a hypointense signal on T1-weighted MRI and a hyperintense signal on T2-weighted MRI. Fatty degeneration of the subchondral bone marrow was detected in 21 ALs, which manifested as a hyperintense signal on both T1- and T2-weighted MRI.

Whole-spine MRI scans were available in 61 of the patients with extensive ALs, and 64 extensive ALs were detected. Spinal stenosis was observed in 23 extensive ALs on MRI.

Moreover, on CT and/or MRI, spinal stenosis was observed in 27 ALs, and the causes included overgrowth of fibrous tissue, OPLL, OLF, dural ossification, and dislocation of the AL site. Seventy-five (97%) of the seventy-seven detectable ALs were found to be extensive ALs, while only 15 (44%) of the 34 occult ALs were extensive ALs ( $\chi^2=43.66$ ,  $P<0.001$ ) [Table 1]. Involvement of the posterior column was detected in 70 ALs, 58 of which were detectable ALs. The proportion of posterior column involvement among detectable ALs (58/77, 75.3%) was significantly larger than those among occult ALs (12/34, 35.3%) ( $\chi^2=16.23$ ,  $P<0.001$ ) [Table 1].

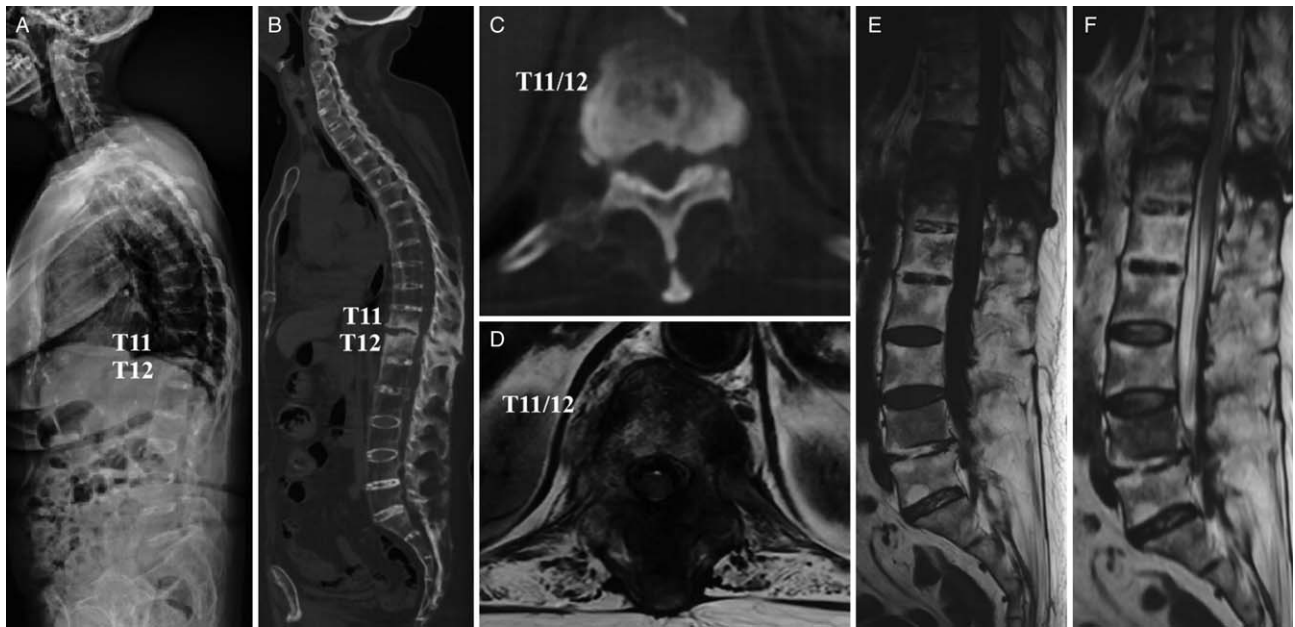### Discussion

Misdiagnosis and missed diagnosis of ALs in patients with AS are not uncommon. The possible reasons for misdiagnosis of ALs include unawareness of these lesions and their radiographic resemblance to other destructive

lesions of the spine, such as infective spondylodiscitis, spinal tuberculosis, and tumors.<sup>[10]</sup> Merely using PR to detect ALs may account for the missed diagnosis of these lesions. A study by Kim *et al*<sup>[12]</sup> revealed that PR might underestimate the prevalence of ALs. Moreover, radiographic analysis of ALs in the thoracic spine by PR may be relatively difficult because of the interference by the projection of the lungs.<sup>[12]</sup> Cawley *et al*<sup>[16]</sup> categorized ALs into localized and extensive lesions. Extensive ALs involved the whole discovertebral junction and sometimes even presented with a fracture of the posterior column.<sup>[16]</sup> Extensive lesions with three-column involvement impair the stability of the spine, which may cause severe neurological deficits if they are neglected. Most of the extensive ALs in the present study (75/90, 83%) were detectable on plain radiographs. The findings on plain radiographs may provide clues for the detection of extensive ALs, including erosion of the vertebral endplates and/or vertebral body with reactive sclerosis, a widened or narrowed affected intervertebral space, angular kyphosis of the affected DVUs, and dislocation at the AL site. However, our observation indicates that occult ALs, which are undetectable by PR, might even be present among extensive ALs. Therefore, the proposal of the concept of occult ALs and a thorough understanding of the radiographic characteristics of these lesions are of utmost clinical relevance in reducing the missed diagnosis of ALs and prevent potentially serious consequences of delayed diagnosis and treatment of ALs, especially occult extensive ALs.

A total of 22% of the patients with AS in this study presented with ALs, which is in agreement with previous studies, showing that the incidence of ALs in patients with AS ranges from 1% to 28%.<sup>[4,8,16,17]</sup> In this study, the patients with only occult ALs were markedly younger than those with only detectable ALs ( $t=-2.18$ ,  $P=0.032$ ). One possible explanation for this finding is that younger patients with AS might have a shorter disease duration, and their destructive lesions might be relatively mild, which increases the difficulty of identifying ALs by PR. With regard to the distribution of ALs, most were located at the thoracolumbar junction ( $n=69$ , 62%) in the present study; this is similar to the results reported by Park *et al*,<sup>[11]</sup> who found that 62 (62%) of 100 ALs were located at the thoracolumbar junction. Moreover, a significant difference was observed in the distribution of the ALs between detectable and occult ALs in this study. In the current study, detectable ALs occurred most frequently at the thoracolumbar junction ( $n=53$ ) and lumbar spine ( $n=13$ ), while occult ALs were most commonly observed at the thoracolumbar junction ( $n=16$ ) and thoracic spine ( $n=10$ ). Anatomical barriers such as the ribs or air in the lungs around the thoracic spine might make it difficult to clearly identify some ALs in the thoracic or thoracolumbar region.<sup>[3,12]</sup> This might explain the finding that occult ALs were most frequently found at the thoracolumbar and thoracic spine in this study.

Regarding the radiographic characteristics of detectable and occult ALs, osteolytic destruction with reactive sclerosis, angular kyphosis of the affected DVUs or vertebral body, OALL-induced formation of an osseous



**Figure 5:** A 67-year-old female AS patient presented with T11/12 extensive AL. The lesion was not detected on the full-length standing radiograph of the spine (A); the sagittal CT showed extensive destructive lesion through the three columns at the level of T11/12 (B). Osteolysis with sclerosis was observed on the axial CT (C); axial MRI (D) and sagittal MRI (E) and (F) revealed extensive destruction of both intervertebral disc and posterior elements at the T11/12 AL. AS: Ankylosing spondylitis; AL: Andersson lesion; CT: Computed tomography; MRI: Magnetic resonance imaging.

bridge at the intervertebral space adjacent to the ALs, and an abnormal height of the affected intervertebral space were all significantly less common in occult ALs by PR ( $P < 0.05$ ). Additionally, the proportion of posterior column involvement in occult ALs was significantly smaller than that in detectable ALs ( $P < 0.001$ ). These findings suggest that more subtle radiographic changes are present in occult ALs. Three possible explanations for the more subtle radiographic changes in occult ALs are as follows. First, the more subtle radiographic changes in occult ALs may be related to the relatively mild spinal ossification, which contributed to the less frequent formation of an osseous bridge at the intervertebral space adjacent to the occult ALs. Second, the mild inflammatory destruction was a possible reason for the subtle radiographic changes, including the much smaller proportion of osteolytic destruction with reactive sclerosis, angular kyphosis of the affected DVUs or vertebral body, and abnormal height of the affected intervertebral space observed on plain radiographs of occult ALs. Third, the subtle changes in occult ALs may be attributed to the patients' relatively young age and short disease duration of AS. This is supported by the findings of the present study that the patients with only occult ALs were significantly younger than those with only detectable ALs ( $40.32 \pm 12.62$  vs.  $45.93 \pm 9.12$  years, respectively;  $t = -2.18$ ,  $P = 0.032$ ).

A review of the 34 occult ALs in the current study reveals three possible reasons for the presence of occult ALs. First, some localized ALs might be undetectable by PR. The scope of localized AL involvement was relatively small, which made it difficult to detect some localized ALs on plain radiographs. Most ( $n = 19$ , 56%) of the occult ALs in this study were localized ALs. Moreover, the proportion of

extensive ALs was much higher among detectable ALs ( $\chi^2 = 43.66$ ,  $P < 0.001$ ), while localized ALs were more commonly observed among occult ALs. Second, our study showed that ALs might be difficult to identify by PR if the posterior column is predominantly involved, while the discovertebral junction and/or vertebral body were much less commonly affected. In a study by Chan *et al*,<sup>[11]</sup> a posterior column defect in one patient with AS who had developed pseudarthrosis was not detected by PR. Third, the ALs in the thoracic spine were prone to interference by the projection of the lungs and ribs. As shown in Figure 4, the patient had ALs at T5/6 and T8/9. Identification of these lesions by PR was difficult because of interference of the lungs and ribs. The two occult ALs were finally detected by CT.

Notably, although extensive ALs were much more frequently observed among detectable ALs ( $\chi^2 = 43.66$ ,  $P < 0.001$ ), they could also manifest as occult ALs. In clinical practice, CT and MRI are widely used for pre-operative evaluation of patients with AS, and occult ALs can be easily identified by pre-operative CT or MRI. However, our proposal of the concept of occult ALs has clinical significance because it may avoid the missed diagnosis of ALs in outpatients. At the initial visit of patients with suspected AS, radiographs of the spine and a CT scan of the sacroiliac joints are usually performed as the first step in attaining a definite diagnosis and evaluating the severity of spinal ossification and kyphosis. CT and MRI of the whole spine are not routinely performed for these patients if clear surgical indications are lacking. However, the results of this study indicate that extensive ALs can also manifest as occult ALs. If exclusively plain radiographs are taken, the diagnosis of some extensive ALs might be missed because of their occult nature on plain



films, which might lead to neurological compromise following even mild trauma, because of the pre-existing instability of the spine. Moreover, localized occult ALs also should not be ignored. On the one hand, localized occult ALs may contribute to back pain or neck pain. On the other hand, they may develop into extensive ALs. Therefore, our study provides useful information that CT or MRI should be performed in any patients with AS who develop sudden, aggravated, and localized pain or neurological symptoms, to determine whether occult ALs are present when no ALs are detectable on plain radiographs.

Another issue that deserves to be mentioned is the differences in treatment strategies between occult and detectable ALs, because the clinical symptoms and radiographic characteristics differ between these two types of ALs. The differences in treatment strategies predominantly involve the selection of conservative or surgical treatment and determination of the fixation levels. First, conservative treatment may be applied in occult ALs if the localized pain is very mild and no neurological deficits are present. In contrast, surgical treatment is usually needed for detectable ALs because most such ALs (97% in this study) manifest as extensive ALs and the localized pain is usually more severe. Second, if surgery is required, the length of fixation levels in detectable ALs is often larger than those in occult ALs because the proportion of extensive ALs is significantly larger among detectable ALs, as shown in the present study ( $P < 0.001$ ) [Table 1], and the stability of the spine may be more severely impaired in detectable ALs. Notably, clinical manifestations including pain, neurological deficits, and kyphosis should be considered during the selection of the treatment strategy in patients with AS who have ALs. The surgery should be performed when there is moderate to severe pain, neurological compromise, or severe kyphosis compromising the ability of looking straight forward or lying flat. If the patient has neither neurological deficits nor severe kyphosis, in situ fixation can be performed to relieve the pain. If a neurological deficit due to ALs is present, decompression at the AL site should be performed. Moreover, corrective osteotomy is needed when severe kyphosis is present.

Two main limitations of the present study should be acknowledged. First, this was a retrospective study. Fifteen (14%) of the one hundred and seven patients with ALs were excluded from the radiographic investigation of occult ALs because of the lack of both whole-spine CT and MRI, which might have contributed to some bias. Second, a bone scan may be theoretically valuable for the identification of occult ALs because it is sensitive for the detection of inflammatory changes. However, bone scans are relatively expensive and were not performed in the present study. It would be worthwhile to investigate the value of bone scans for the detection of occult ALs in future studies.

The incidence of ALs in AS patients was 22%, and the incidence of occult ALs in AS patients with ALs was 25% in this study. More subtle radiographic changes were present in occult ALs. Localized ALs, predominant

involvement of the posterior column, and interference by the projection of the lungs and ribs might be the reasons for the presence of occult ALs. Occult ALs should not be neglected; this is especially true for extensive occult ALs, because they might severely impair the stability of the spine and compromise the patient's neurological function.

### Funding

This study was supported by grants from the Jiangsu Provincial Medical Talent Program (No. ZDRCA 2016068), and the Jiangsu Provincial Key Medical Center (No. YXZXA2016009).

### Conflicts of interest

None.

### References

1. Park YS, Kim JH, Ryu JA, Kim TH. The Andersson lesion in ankylosing spondylitis: distinguishing between the inflammatory and traumatic subtypes. *J Bone Joint Surg Br* 2011;93:961–966. doi: 10.1302/0301-620X.93B7.26337.
2. Dave BR, Ram H, Krishnan A. Andersson lesion: are we misdiagnosing it? A retrospective study of clinico-radiological features and outcome of short segment fixation. *Eur Spine J* 2011;20:1503–1509. doi: 10.1007/s00586-011-1836-0.
3. de Vries MK, van Drumpt AS, van Royen BJ, van Denderen JC, Manoliu RA, van der Horst-Bruinsma IE. Discovertebral (Andersson) lesions in severe ankylosing spondylitis: a study using MRI and conventional radiography. *Clin Rheumatol* 2010;29:1433–1438. doi: 10.1007/s10067-010-1480-9.
4. Langlois S, Cedoz JP, Lohse A, Toussiot E, Wendling D. Aseptic discitis in patients with ankylosing spondylitis: a retrospective study of 14 cases. *Joint Bone Spine* 2005;72:248–253. doi: 10.1016/j.jbspin.2004.05.015.
5. Nikolaisen C, Nossent H. Early histology in ankylosing spondylitis related spondylodiscitis supports its inflammatory origin. *Scand J Rheumatol* 2005;34:396–398. doi: 10.1080/03009740510026625.
6. Frank P, Gleeson JA. Destructive vertebral lesions in ankylosing spondylitis. *Br J Radiol* 1975;48:755–758. doi: 10.1259/0007-1285-48-573-755.
7. Bron JL, de Vries MK, Snieders MN, van der Horst-Bruinsma IE, van Royen BJ. Discovertebral (Andersson) lesions of the spine in ankylosing spondylitis revisited. *Clin Rheumatol* 2009;28:883–892. doi: 10.1007/s10067-009-1151-x.
8. Qiao M, Qian BP, Qiu Y, Mao SH, Wang YH. Radiologic and pathological investigation of pseudarthrosis in ankylosing spondylitis: distinguishing between inflammatory and traumatic etiology. *J Rheumatol* 2019;46:259–265. doi: 10.3899/jrheum.171249.
9. Wei HY, Dong CK, Zhu YT, Zhou J, Yi P, Yang F, *et al.* A modified posterior wedge osteotomy with interbody fusion for the treatment of thoracolumbar kyphosis with Andersson lesions in ankylosing spondylitis: a 5-year follow-up study. *Chin Med J* 2020;133:165–173. doi: 10.1097/CM9.0000000000000594.
10. Wu M, Yan F, Ping A, Lei J. Effects of Andersson lesion treatment in ankylosing spondylitis: a medical record review study focused on medium- to long-term outcomes. *Int J Rheum Dis* 2020;23:753–762. doi: 10.1111/1756-185X.13826.
11. Chan FL, Ho EK, Chau EM. Spinal pseudarthrosis complicating ankylosing spondylitis: comparison of CT and conventional tomography. *AJR Am J Roentgenol* 1988;150:611–614. doi: 10.2214/ajr.150.3.611.
12. Kim SK, Shin K, Song Y, Lee S, Kim TH. Andersson lesions of whole-spine magnetic resonance imaging compared with plain radiography in ankylosing spondylitis. *Rheumatol Int* 2016;36:1663–1670. doi: 10.1007/s00296-016-3542-z.
13. Qian BP, Huang JC, Qiu Y, Wang B, Yu Y, Zhu ZZ, *et al.* Complications of spinal osteotomy for thoracolumbar kyphosis secondary to ankylosing spondylitis in 342 patients: incidence and risk factors. *J Neurosurg Spine* 2018;30:91–98. doi: 10.3171/2018.6.SPINE171277.



14. Russo VM, Casey AT. Andersson lesion in ankylosing spondylitis. *Spine J* 2014;14:1357. doi: 10.1016/j.spinee.2014.02.037.
15. Qian BP, Qiu Y, Wang B, Sun X, Zhu ZZ, Jiang J, *et al.* Pedicle subtraction osteotomy through pseudarthrosis to correct thoracolumbar kyphotic deformity in advanced ankylosing spondylitis. *Eur Spine J* 2012;21:711–718. doi: 10.1007/s00586-011-2054-5.
16. Cawley MI, Chalmers TM, Kellgren JH, Ball J. Destructive lesions of vertebral bodies in ankylosing spondylitis. *Ann Rheum Dis* 1972;31:345–358. doi: 10.1136/ard.31.5.345.
17. Rasker JJ, Prevo RL, Lanting PJ. Spondylodiscitis in ankylosing spondylitis, inflammation or trauma? A description of six cases. *Scand J Rheumatol* 1996;25:52–57. doi: 10.3109/03009749609082669.

---

**How to cite this article:** Huang JC, Qian BP, Qiu Y, Wang B, Yu Y, Zhao SZ. Occult Andersson lesions in patients with ankylosing spondylitis: undetectable destructive lesions on plain radiographs. *Chin Med J* 2021;134:1441–1449. doi: 10.1097/CM9.0000000000001557