

# Laparoscopic surgery

## Any role in patients with unexplained infertility and failed in vitro fertilization cycles?

Xiaoming Yu, MD, He Cai, MD, Jing Guan, MD\*, Xingbang Zheng, MD, Hongjing Han, MD

### Abstract

Patients who undergo several in-vitro fertilization (IVF) treatment cycles and fail to conceive present a frustrating problem to the clinician. When 1 cycle of IVF treatment fails, should we offer the couples to choose additional cycle of IVF instead of evaluation of the potential peritoneal factor? In cases of otherwise unexplained infertility, the investigation cannot be considered to be complete until laparoscopy has been performed. The aim of the study is to investigate the fertility outcome of laparoscopic treatment in infertile women with repeated IVF failures.

This is a retrospective case-control study conducted in a tertiary care, academic teaching hospital from January 2012 to December 2015. Patients recruited in this study were classified into 2 groups. Study group (n=45) were offered laparoscopy for evaluation of infertility, control group (n=45) elected to proceed to IVF without laparoscopy. Diagnostic laparoscopy and subsequent excision of suspected endometriotic lesions, lysis of adhesion and treatment of tubal pathology were performed when indicated.

Forty-four (97.8%) patients in study had pelvic pathologies and the treatment was performed at the same time. Twenty-four patients in study group conceived including 16 patients conceived spontaneously and 14 patients conceived with additional IVF following laparoscopy management. There was a significant difference in the ongoing pregnancy rates between patients conceived through IVF in study group and control group (41.9% vs 19.6%,  $P < .05$ ).

Laparoscopy in women with normal hysterosalpingography but recurrent IVF failures can detect unrecognized pelvic pathologies. Laparoscopy evaluation prior to additional cycle of IVF seems to improve the subsequent pregnancy rate.

**Abbreviations:** ART = assisted reproductive techniques, FET = frozen embryo transfer, HSG = hysterosalpingogram, IVF = in-vitro fertilization.

**Keywords:** adhesions, endometriosis, hysterosalpingography, IVF, laparoscopy, tubal pathology

### 1. Introduction

Current in-vitro fertilization (IVF) consumers are enjoying better success rates than early seekers, but only about a quarter of IVF cycles result in a live birth and many patients remain infertile after multiple IVF attempts. Recurrent IVF failure is distressing to patients and challenging to clinicians. Despite interventions have been proposed to improve IVF outcome after couples of failed cycles, only a few of which are evidence based.<sup>[1,2]</sup>

Laparoscopy, as the gold standard for the evaluation of the pelvis, was used to be the routine procedure for many reproductive physicians. It provides information on endometriosis, tubal

patency, and pelvic adhesions and a chance to fix these lesions concurrently.<sup>[3]</sup> However, advances in non-invasive techniques such as vaginal ultrasound or hysterosalpingography (HSG) have questioned the need for laparoscopy in the infertility workup. The role of laparoscopy, especially in women whose normal screening tests suggest that pelvic pathology seem to be unlikely. However, sometimes a “normal” pelvic imaging can be misleading, since HSG or ultrasonography cannot to rule out hydrosalpinges and endometriosis completely.<sup>[4]</sup> Furthermore, it has been shown that HSG is insufficient for predicting tubal potency for some patients with risk of pelvic adhesions, with a sensitivity between 0.0% and 83% and specificity between 50% and 90%.<sup>[5]</sup>

When initial IVF treatments fail, can we offer the couples to choose additional cycle of IVF instead of evaluation of the potential peritoneal factor? In cases of otherwise so called “unexplained infertility”, the investigation cannot be considered complete until laparoscopy has been performed.<sup>[6]</sup>

Our hypothesis is the positive findings on laparoscopic surgery can affect the management strategy which might decrease the stress of numbers of IVF cycle failure. The current study was to assess if the diagnosis and treatment of pelvic pathologies with laparoscopy is of role in improving the pregnancy outcome in patients with recurrent IVF failure.

### 2. Methods

#### 2.1. Ethical approval

All patients and their partners included in the study provided signed informed consent. Ethical approval Informed consents

Editor: Yan Li.

Popularizing application of appropriated health technology in Beijing (2018-TG-16).

The authors have no conflicts of interest to disclose.

Reproductive Medicine Center, Peking University People's Hospital, China.

\* Correspondence: Jing Guan, Reproductive Medicine Center, Peking University People's Hospital, 11#, Xizhimen Street, Beijing, China (e-mail: guanjing6302@yeah.net).

Copyright © 2019 the Author(s). Published by Wolters Kluwer Health, Inc. This is an open access article distributed under the terms of the Creative Commons Attribution-Non Commercial License 4.0 (CCBY-NC), where it is permissible to download, share, remix, transform, and buildup the work provided it is properly cited. The work cannot be used commercially without permission from the journal.

Medicine (2019) 98:13(e14957)

Received: 9 January 2019 / Received in final form: 25 February 2019 /

Accepted: 1 March 2019

<http://dx.doi.org/10.1097/MD.00000000000014957>

were obtained from all the patients, and the study was approved by the Human Research Ethics Committee of Peking University People's Hospital, Beijing, China.

## 2.2. Patients and study design

This is a retrospective case-control study of infertile women with 2 or more failed IVF cycles, in which 2 or more good quality embryos transferred. We reviewed medical records in the reproductive medicine center of Peking University People's hospital, between January 2012 and December 2015. Inclusion criteria were:

1. The patients' ages ranged from 25 to 40 years;
2. menstrual cycles with a duration of 25 to 35 days and no ovulatory dysfunction;
3. normal findings of pelvic ultrasonography and HSG assessment, without visible lesions that could cause implantation failure, for example: endometrial polyps, submucosal myomas, uterine septum and intrauterine adhesions;
4. hormonal values were within the normal range;
5. Semen analyses were normal according to the World Health Organization (WHO) criteria;<sup>[7]</sup>
6. negative for chlamydia antibody;
7. no previous surgical treatment for endometriosis; no previous oophorectomy or salpingectomy; and
8. Patients included in the study had failed to conceive after at least two cycles of IVF-ET when indicated. Patients with known endocrinopathy and alterations of male factor were excluded from the study.

Study group (n=45) were offered laparoscopy for further evaluation of infertility, control group (n=45) elected to proceed to IVF without laparoscopic evaluation.

Patient characteristics including age, duration of infertility, number of previous failed IVF cycles were recorded. Patients were interviewed via telephone every 6 months to record the clinical outcomes and livebirth rates. Women who got pregnant were asked whether pregnancy was achieved spontaneously or through IVF.

## 2.3. Surgery procedure

Laparoscopy was conducted under general endotracheal anesthesia. All surgeries were performed by the two senior reproductive laparoscopists (JG and XMY) and every surgical procedure was video recorded. After clinical examination diagnostic laparoscopy was performed to identify any possible pelvic pathology. Diluted methylene blue was injected transcervically which enabled distention of the tube and assessment of tubal patency. Particular attention was given to the tubal status: tubal blockage, the quality of the mucosa, and the tubal wall aspect during laparoscopy.<sup>[8]</sup> Endometriosis was staged according to the 1985 revised American Fertility Society classification scheme.<sup>[9]</sup>

Laparoscopic surgeries consisted of thorough ablation or excision of all peritoneal and non-peritoneal endometriotic lesions, lysis of adhesions, and appropriate management of tubal disease. Adhesions present were similarly lysed to restore pelvic anatomy. Surgical treatment of tubal pathologies included laparoscopic neosalpingostomy, fimbrioplasty and salpingectomy. The decision to repair or remove fallopian tubes is usually made intraoperatively based on status of the tube and tubal mucosa since operative success is dependent on the location, type and extend of tubal injury as we previously described.<sup>[10]</sup> If the

tube was severely damaged, salpingectomy was performed. Minor or moderate lesions were treated with laparoscopic neosalpingostomy.

## 2.4. Outcomes measurements

The primary outcome was live birth rate (defined as the proportion of women with delivery of living fetuses) and ongoing pregnancy rate (defined as the proportion of women with pregnancy beyond 24 or more weeks of gestation). Secondary outcomes were rates of clinical pregnancy (proportion of women with the observation of fetal heartbeat on ultrasound scan), and miscarriage (defined as the proportion of women with pregnancy loss before 24 weeks of gestation). Abnormal laparoscopy findings and surgery-related complications were also analyzed.

## 2.5. Statistical analysis

Statistical analyses were performed using a windows-based SPSS version 20.0 (SPSS Inc., Chicago, IL). Data were statistically described in terms of mean standard deviation (SD), or frequencies (number of cases) and percentage when appropriate. For continuous variables, a parametric *t* test was used to compare treatment groups. When comparing categorical data, Chi-Square test or Fisher exact test was performed. Statistical significance was defined as an alpha value of  $P < .05$ .

## 3. Results

The characteristics of the patients satisfied the eligibility criteria were summarized in Table 1. No one was lost to follow-up, however, 2 couples in the control group devoiced during follow-up. Therefore, a total of 88 infertile patients satisfied the eligibility criteria and were analyzed. No significant differences were shown between the 2 groups in terms of age, infertility duration, number of failed cycles and causes of infertility. No laparoscopy-related complications were reported.

Table 2 shows the main pathological findings revealed by laparoscopic surgery. Pelvic abnormalities were detected in 97.8% of cases, only 1 patient had no pathologic findings. Endometriosis (26/45) was the most common abnormalities detected in laparoscopy. Mild or minimal endometriosis was present in 15 women, moderate in 9, and severe in 2. Tubal lesions were diagnosed with mild in 4 women, moderate in 4, and severe in 6. Pelvic adhesions were found in 15 patients; in 4 cases

**Table 1**  
Characteristics of 45 patients with previously multiple implantation failures.

Variable	Group 1 (n=45)	Group 2 (n=43)	P value
Age, yr	33.4±4.7	34.6±4.3	NS
Duration of infertility, yr	5.7±3.8	6.0±2.9	NS
Infertility type, n (%)			
Primary	24 (53.3)	20 (46.5)	NS
Secondary	21 (46.7)	23 (53.5)	NS
Previous IVF cycles, n			
Oocyte aspiration	2.5±1.0	2.6±0.4	NS
Embryo transfer (including FET)	3.0±1.2	3.1±0.9	NS

Values are presented as mean±SD or frequencies (percentage).

FET=frozen embryo transfer, IVF=in vitro fertilization.

**Table 2**  
**Findings of laparoscopy (n=45).**

Variables	Frequency, n (%)
Normal	1 (2.2)
Endometriosis	26 (57.7)
Mild	15 (33.3)
Moderate	9 (20.0)
Severe	2 (4.4)
Tubal pathologies	14 (31.1)
Mild	4 (8.9)
Moderate	4 (8.9)
Severe	6 (13.3)
Pelvic adhesions	15 (33.3)
Isolated adhesions	4 (8.9)
With concurrent diseases	11 (24.4)

**Table 3**  
**Outcomes of IVF treatment in patients.**

Variable	Study group (n=26)	Control group (n=43)	P value
Cycles of IVF, n	31	51	
Clinical pregnancy rate/per cycle, n (%)	14 (45.2)	12 (23.5)	.05
Ongoing pregnancy rate/per cycle, n (%)	13 (41.9)	10 (19.6)	.04
Live birth rate/per cycle, n (%)	11 (35.5)	9 (17.6)	NS
Miscarriage rate (% of clinical pregnancies)	1 (7.1)	2 (16.7)	NS

NS: not significant.  
IVF = in-vitro fertilization.

no other pathology was observed but 11 of them had coexisting tubal lesions or endometriosis.

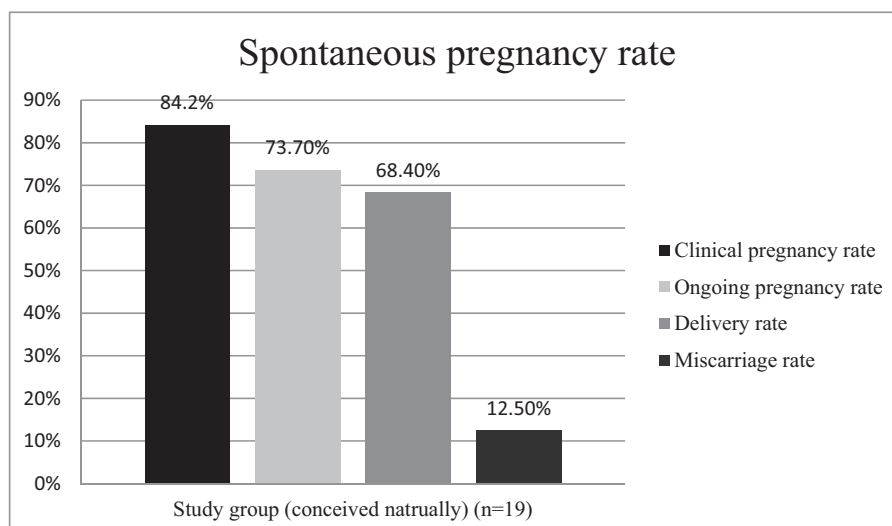
In the study group, 19 patients desired spontaneous pregnancy and among them 16 conceived postoperatively. The outcomes of natural pregnancy after surgery were shown in the Figure 1. The median interval between surgery and pregnancy was 5 months (ranged from 1–26 months). While the rest 26 patients in the study received IVF treatment following surgery and 14 conceived with IVF (Table 3). In the control group, 12 were conceived from repeat IVF cycles. Significant difference was found in the per cycle ongoing pregnancy rates between patients in study group and control group (41.9% vs 19.6%,  $P < .05$ ). A trend toward higher live birth rates that did not reach statistical significance was experienced among patients treated with laparoscopy (35.5% vs 17.6%,  $P > .05$ ). There were no significant differences observed in terms of miscarriage rates in 2 groups.

**4. Discussion**

In this current study, we encompassed a unique subset of infertile women with multiple failures of IVF cycle. In the study group, laparoscopy revealed pelvic abnormalities in 44 women (97.8%), dominated by endometriosis (26 cases), tubal diseases and pelvic

adhesions were observed in 14 and 15 cases, respectively. The study confirmed previous observations: Eva Littman et al<sup>[6]</sup> suggested that in their personal experience that more than 90% of the infertile couples without other identifiable infertility factors have endometriosis or other pelvic pathology, like adhesions, at the time of laparoscopy.

HSG has been most commonly used for the evaluation of tubal patency before undergoing IVF treatment. However, its sensitivity and specificity have been questioned in recent decades. Comparison between HSG and laparoscopy show discrepancies up to 45%.<sup>[11]</sup> A commonly referenced meta-analysis also reported the diagnosis of peritoneal adhesions based on HSG findings was unreliable.<sup>[12]</sup> Another study comparing the diagnostic value HSG and laparoscopy reported the positive and negatives predictive values of HSG for evaluation of bilateral tubal patency were 81.4% and 41.4%, respectively.<sup>[13]</sup> It means that HSG interpreted as normal in about half of the cases gives a false reassurance. The high incidence of positive pelvic pathology indicated that there are correctable abnormalities that are unfortunately missed by routine pelvic examination and usual imaging procedure. Laparoscopy seems to be essential in determining potential causes of repeated IVF failures for couples without recognized abnormalities by routine screening.



**Figure 1.** Cumulative spontaneous pregnancy rate after laparoscopy.

Another endpoint was to assess the reproductive outcomes after surgery. Based on our study, the laparoscopic treatment of all pelvic pathologies in women with otherwise unexplained infertility is likely to be beneficial since it might increase the chance of ongoing pregnancy or live birth. In the study group, we found that of 30 patients achieved pregnancy, including 16 patients conceived spontaneously and 14 with additional IVF cycle. Patients in our study group experienced repeated IVF cycles before surgery; however, they got pregnant successfully after the mini-invasive surgical approach. Compared to the study group, only 12 patients conceived from repeat IVF cycles in the control group. Significant difference was found in the per cycle ongoing pregnancy rates between the 2 groups (41.9% vs 19.6%,  $P < .05$ ). The findings demonstrate a favorable effect of laparoscopic surgery in IVF failure patients, showing that most were able to conceive once potential pelvic pathologies were identified and treated. Although the surgical role in the management of infertility has been largely supplanted by IVF, the positive significance of laparoscopy cannot be ignored. Sixteen cases of natural pregnancies post-surgery should be regarded as the effectiveness of the surgical procedure. In addition, compared to IVF, reproductive surgery has the potential to restore reproductive function resulting in multiple conceptions after one-time procedure.

An early study reported that infertile women have 6 to 8 times the rate of endometriosis compared with fertile women.<sup>[3]</sup> In our study, endometriosis is the most common positive pathologic findings in laparoscopy (57.7%, 26/45). Meuleman et al<sup>[14]</sup> reported that infertile women with normal ovulatory cycles and normospermic partners, have endometriosis in nearly 50% cases. Subjects included in our study were all patients with repeated IVF failures and this may account for some of the higher prevalence. In addition, the incidence of endometriosis could be underestimated since the diagnosis is often delayed several years from the onset of symptoms.<sup>[15]</sup> Thus, laparoscopic evaluation of endometriosis should not be bypassed or omitted. Several studies have suggested that even in IVF cycles, implantation rates in women with endometriosis tend to be lower than normal.<sup>[16]</sup> Barnhart et al<sup>[17]</sup> revealed that patients with endometriosis undergoing IVF had 50% of the chance of achieving pregnancy compared with tubal factor controls. In this sense, conditions that may impair implantation and successful conception should be corrected before administering IVF. It is our belief that the patients with failed multiple cycles of IVF may harbor a certain type of endometriosis that allows them to benefit from thorough surgical therapy. Littman et al<sup>[3]</sup> reported a 76% pregnancy rate after endometriosis surgery in women with prior failed IVF management. But it should be noted that most of the participants in their study were with mild endometriosis. We are not surprised that patients with stage III–IV endometriosis had poor clinical outcomes as compared with patients with milder endometriosis.

Tubal pathology is responsible for 30% to 35% of the infertility and up to 30% of patients undergoing IVF have hydrosalpinges.<sup>[18]</sup> We found the incidence of tubal abnormality was 31.1% which was comparable to those of the literature. The association of fallopian hydrosalpinges with decreased pregnancy and implantation rates in IVF cycles has been confirmed by overwhelming scientific evidence, and surgical correction of such lesions before IVF is normally advised.<sup>[19]</sup> It is worth noting that patients included in this study were those who had no hydrosalpinges prior to initial IVF treatment or abnormal ultrasound results before current surgery. A normal HSG and/or ultrasound can be misleading.<sup>[12,20]</sup> In regard to detection of

hydrosalpinges, sensitivity and specificity for the ultrasonographic images were 84.6% and 99.7%, respectively.<sup>[19]</sup> Meanwhile, we should not ignore that pelvic inflammation during multiple IVF cycles may be a factor that promotes the formation of hydrosalpinges.<sup>[21]</sup> In this study, laparoscopic neosalpingostomy were carried out in 8 cases with mild and moderate damages while the rest 6 cases with severe diseases underwent salpingectomy. In our previous study, we have shown that neosalpingostomy prior to IVF in women with mild-to moderate hydrosalpinges improve the outcome of subsequent IVF, while offering the potential for spontaneous conception.<sup>[10]</sup> We agree with other authors that if the fallopian tube is damaged beyond repair, salpingectomy is indicated.

Peritubal tubal adhesions adversely affect fertility has been clearly demonstrated.<sup>[22,23]</sup> Tulandi et al<sup>[23]</sup> investigated pregnancy rate in patients with peritubal adhesions. In their study, 69 women were treated by adhesiolysis and 78 were not treated. The cumulative pregnancy rate at 12 and 24 months follow-up was 32% and 45% in the treated group, much higher than that rate (11% and 16%) in the nontreated group.

Admittedly, our study has some limitations as the result of its retrospective nature with the inherent biases that are associated with such design, which may limit its generalizability. And the number of the study was limited and the issue should be investigated in larger studies. In addition, the cost effectiveness of surgery versus IVF was not covered in our study.

## 5. Conclusions

Meticulous laparoscopic surgery remains an effective tool in comprehensive evaluation of infertility, particularly for detecting peritoneal endometriosis, adhesions and tubal pathologies. Previously undiagnosed or subtle newly added pelvic abnormalities may be a significant cause of IVF failure. Further prospective studies are needed to validate the role of laparoscopic evaluation and treatment in this subset of infertile patients.

## Acknowledgments

We thank all the women enrolled in the study and gratefully acknowledge the assistance of the nursing staff at Peking University People's Hospital.

## Author contributions

He Cai and Xiaoming Yu contributed to write the original study. Jing Guan contributed to study concept. Xingbang Zheng assisted with the literature review. Hongjing Han contributed the revision of article. All authors have seen and approved the final version.

**Conceptualization:** Jing Guan.

**Data curation:** He Cai.

**Resources:** Xiaoming Yu, Xingbang Zheng.

**Writing – original draft:** Xiaoming Yu, He Cai.

**Writing – review & editing:** Jing Guan, Hongjing Han.

Jing Guan orcid: 0000-0001-6591-491X.

## References

- [1] Zeyneloglu HB, Onalan G. Remedies for recurrent implantation failure. *Semin Reprod Med* 2014;32:297–305.
- [2] Papathanasiou A, Bhattacharya S. Prognostic factors for IVF success: diagnostic testing and evidence-based interventions. *Semin Reprod Med* 2015;33:65–76.

- [3] Bulletti C, Panzini I, Borini A, et al. Pelvic factor infertility: diagnosis and prognosis of various procedures. *Ann N Y Acad Sci* 2008;1127:73–82.
- [4] Khalaf Y. ABC of subfertility tubal subfertility. *BMJ* 2003;327:610–3. doi: 10.1136/bmj.327.7415.610.
- [5] Montoya JM, Bernal A, Borrero C. Diagnostics in assisted human reproduction. *Reprod Biomed Online* 2002;5:198–210.
- [6] Littman E, Giudice L, Lathi R, et al. Role of laparoscopic treatment of endometriosis in patients with failed in vitro fertilization cycles. *Fertil Steril* 2005;84:1574–8.
- [7] Cooper TG, Noonan E, von Eckardstein S, et al. World health organization reference values for human semen characteristics. *Hum Reprod Update* 2010;16:231–45.
- [8] Mage G, Pouly JL, de Jolinière JB, et al. A preoperative classification to predict the intrauterine and ectopic pregnancy rates after distal tubal microsurgery. *Fertil Steril* 1986;46:807–10.
- [9] Revised American Fertility Society classification of endometriosis: 1985. *Fertil Steril* 1985;43:351–2.
- [10] Yu X, Cai H, Zheng X, et al. Tubal restorative surgery for hydrosalpinges in women due to in vitro fertilization. *Arch Gynecol Obstet* 2018;297:1169–73.
- [11] Saunders RD, Shwayder JM, Nakajima ST. Current methods of tubal patency assessment. *Fertil Steril* 2011;95:2171–9.
- [12] Swart P, Mol BW, van der Veen, et al. The accuracy of hysterosalpingography in the diagnosis of tubal pathology: a meta-analysis. *Fertil Steril* 1995;64:486–91.
- [13] Foroozanfar F, Sadat Z. Diagnostic value of hysterosalpingography and laparoscopy for tubal patency in infertile women. *Nurs Midwifery Stud* 2013;2:188–92.
- [14] Meuleman C, Vandenabeele B, Fieuws S, et al. High prevalence of endometriosis in infertile women with normal ovulation and normospermic partners. *Fertil Steril* 2009;92:68–74.
- [15] Nnoaham KE, Hummelshoj L, Webster P, et al. Impact of endometriosis on quality of life and work productivity: a multicenter study across ten countries. *Fertil Steril* 2011;96:366–73.
- [16] Mahutte NG, Arici A. Endometriosis and assisted reproductive technologies: are outcomes affected? *Curr Opin Obstet Gynecol* 2001;13:275–9.
- [17] Barnhart K, Dunsmoor-Su R, Coutifaris C. Effect of endometriosis on in vitro fertilization. *Fertil Steril* 2002;77:1148–55.
- [18] Cohen SB, Bouaziz J, Schiff E, et al. In vitro fertilization outcomes after placement of Essure microinserts in patients with hydrosalpinges who previously failed in vitro fertilization treatment: a multicenter study. *J Minim Invasive Gynecol* 2016;23:939–43.
- [19] Practice Committee of American Society for Reproductive Medicine in collaboration with Society of Reproductive Surgeons. Salpingectomy for hydrosalpinx prior to in vitro fertilization. *Fertil Steril* 2008;90:S66–8.
- [20] de Wit W, Gowrising CJ, Kuik DJ, et al. Only hydrosalpinges visible on ultrasound are associated with reduced implantation and pregnancy rates after in-vitro fertilization. *Hum Reprod* 1998;13:1696–701.
- [21] Elizur SE, Lebovitz O, Weintraub AY, et al. Pelvic inflammatory disease in women with endometriosis is more severe than in those without. *Aust N Z J Obstet Gynaecol* 2014;54:162–5.
- [22] Gomel V, Koninckx PR. Microsurgical principles and postoperative adhesions: lessons from the past. *Fertil Steril* 2016;106:1025–31.
- [23] Tulandi T, Collins JA, Burrows E, et al. Treatment-dependent and treatment-independent pregnancy among women with periadnexal adhesions. *Am J Obstet Gynecol* 1990;162:354–7.