

CASE REPORT**A successful new method for single left lobe recruitment**Knut Dybvik^{1,2}  | Erik W. Nielsen^{1,2,3,4}¹Department of Anesthesiology and Critical Care Medicine, Nordland Hospital Bodø, Bodø, Norway²Nord University, Bodø, Norway³University of Tromsø, Trømsø, Norway⁴University of Oslo, Oslo, Norway**Correspondence**Knut Dybvik, Intensive Care Unit, Department of Anesthesiology Critical Care Medicine Nordland Hospital, Bodø, Norway.
Email: kdybvik@gmail.com**Key Clinical Message**

Any gas will flow down the path of least resistance and highest compliance. This is a problem in the treatment of severe unilateral lung disease in the intensive care unit (ICU). Deep sedation interferes with the diaphragm's ability to distribute air into the lower lung. Spontaneous breathing in a conscious patient, in combination with mechanical ventilation via an endotracheal tube inserted into the left main stem bronchus, can recruit collapsed alveoli.

KEYWORDS

intratracheal intubation, lung compliance, single-lung ventilation, spontaneous breathing, tracheostomy, ventilation-perfusion ratio

1 | INTRODUCTION

Air or any other gas will flow down the path of least resistance and highest compliance. It creates a dilemma in traditional endotracheal intubation and mechanical ventilation of unilateral or asymmetric lung disease with unequal airway resistance and lung compliance. Differential lung ventilation (DLV) in intensive care is rarely used, and its evidence base is small. The advantages of independent lung ventilation in unilateral lung disease are the possibilities of applying different levels of positive end-expiratory pressure (PEEP), inspiratory pressure and volumes, different inspiratory-to-expiratory ratio, and even the possibility of giving different gas mixtures to the two lungs.¹ In DLV, the use of double-lumen endotracheal tubes is most common, but the method can have serious complications. Vocal cord trauma, airway ischemia and stenosis, pneumothorax, pneumomediastinum, subcutaneous emphysema, and displacement have been reported.² The use of double-lumen endotracheal tubes also requires deep sedation with its drawbacks.

We have previously presented a new DLV method combining two endotracheal tubes, one tube through a tracheostomy and one tube inserted orally.¹ In the present case, we modified this method. We combined conscious spontaneous breathing with mechanical ventilation of a remaining left

lobe through an endotracheal tube inserted into the left main stem bronchus via a tracheostoma.

2 | CASE HISTORY

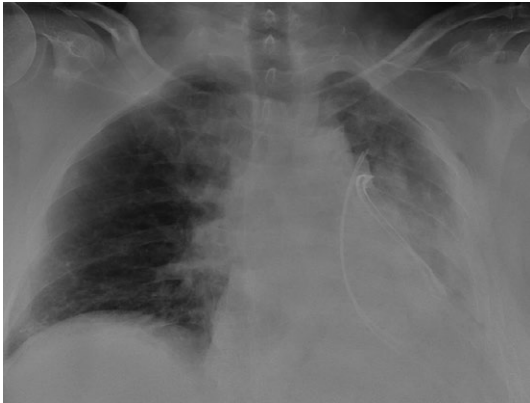
A 66-year-old male was admitted to the ICU in severe respiratory distress. The previous day, he underwent elective left-sided lower lobectomy due to cancer.

On postoperative day 1, a chest X-ray showed opacities and consolidation of the remaining left lobe as in pneumonia (Table 1, day 1). The trachea was intubated orally. Sedation and mechanical ventilation were started.

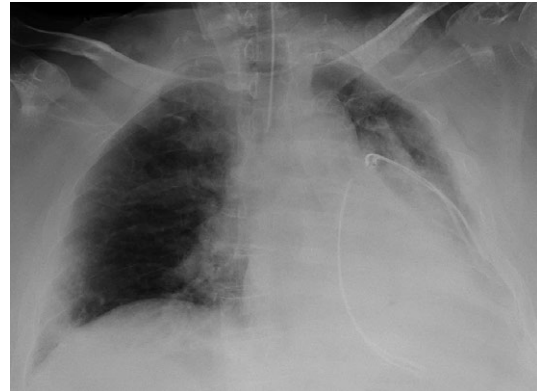Haemophilus influenzae was found in sputum cultures. The clinical situation did not improve (Table 1, day 2-A). A percutaneous dilatational tracheostomy was performed. For 3 days, we deployed our previously described method of DLV: mechanical ventilation of the right lung through the tracheal tube and mechanical ventilation of the left lung through a cuffed oral tube via the tracheostoma (Table 1, day 2-B and 2-C).¹ Lung aeration improved markedly (Table 1, day 5). Then, again both lungs were ventilated in combination via the trachea, this time through a tracheostomy tube. However, a chest X-ray on day 6 showed nearly total collapse of the left lunge (Table 1, day 6-A).

TABLE 1 Chest X-rays and illustrations before, during and after single left lobe recruitment**Day 1**

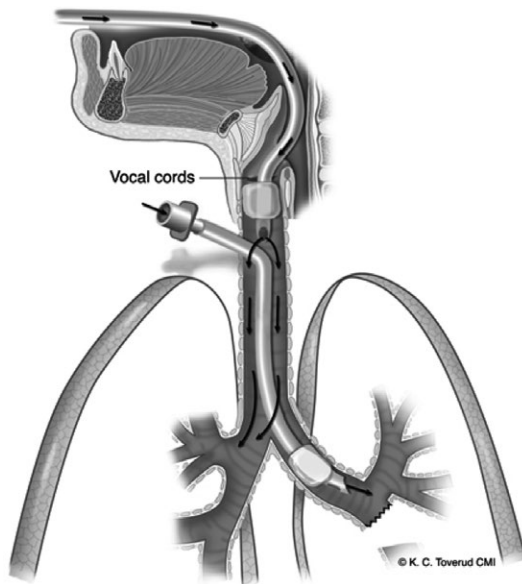
Postoperatively at the ICU after left-sided lower lobectomy prior to endotracheal intubation with mechanical ventilation. Two left-sided chest tubes.

**Day 2-A**

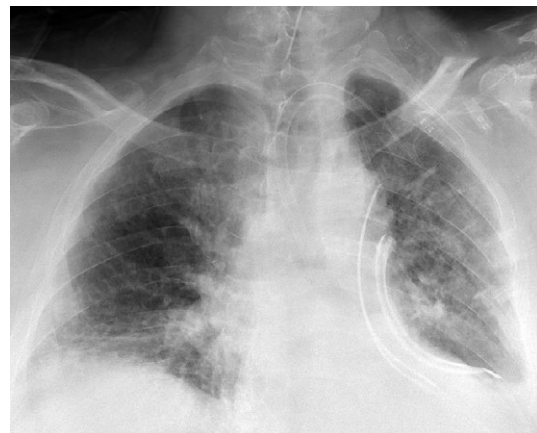
After 24 hours with mechanical ventilation via endotracheal tube.

**Day 2-B**

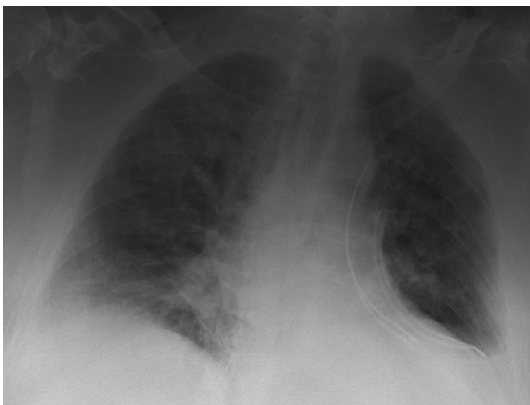Tracheostomy performed. Differential ventilation via endotracheal tube to right lung and long tracheostomy tube via main bronchus to left lung.

**Day 2-C**

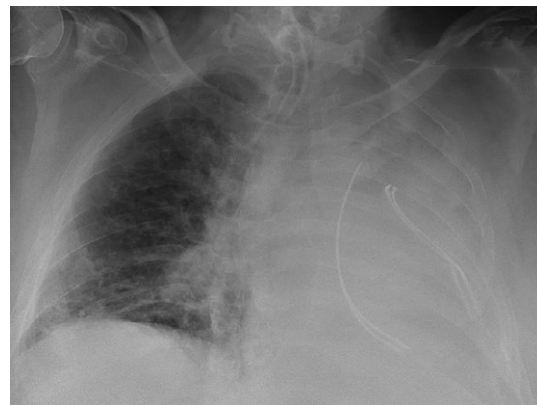
After one hour with differential ventilation.

**Day 5**

After 3 days of differential ventilation.

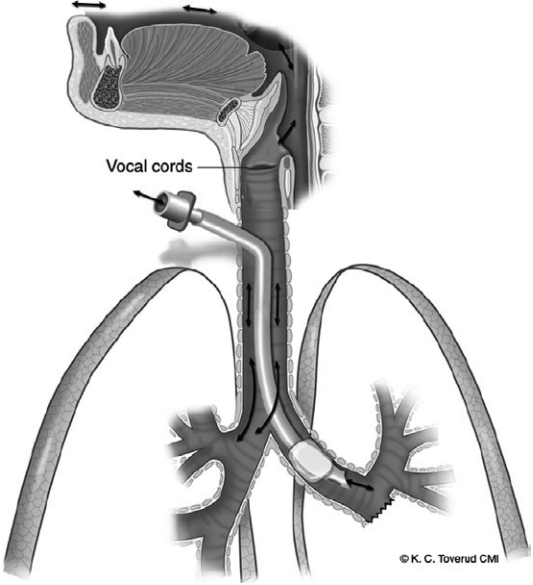



**Day 6-A**

After 1 day with nonselective ventilation via a tracheostomy tube.



(Continues)

TABLE 1 (Continued)

<p>Day 6-B Single mechanical ventilation of left lung via long tracheostomy tube through main bronchus. Spontaneous normal breathing with right lung through mouth and nose.</p>  <p>© K. C. Toverud CM</p>	<p>Day 6-C Two hours with single mechanical ventilation of left lung</p> 
<p>Day 7 One day of single mechanical ventilation of left lung.</p> 	<p>Day 11 One day of spontaneous normal breathing with both lungs. A 4-day period of single mechanical ventilation of left lung ended the previous day. Both left-sided chest tubes are removed.</p> 

We then inserted a cuffed oral tube (inner diameter 6.0 mm) over a left pointing curved tip suction catheter into the left main bronchus via the tracheostoma. (Table 1, day 6-B). Fiberoptic bronchoscopy was then performed through the left lung tube to exclude occlusion of the secondary left bronchi, and chest X-ray was also performed to verify correct tube placement. After toilet bronchoscopy, the ventilator was started with 10 cm H₂O pressure support and a PEEP of 14 cm H₂O. The orally inserted tracheal tube was removed and sedation stopped.

The remaining left lung expanded after two hours (Table 1, day 6-C). The patient was fully conscious. Spontaneous breathing of the right lung was normal and triggered simultaneously pressure support ventilation of left lung. The patient

could talk normally, as no tube passed through the glottis, and eat, drink, cooperate, sit in a bedside chair, and talk on the phone with relatives. He could also cough up sputum from the right lung. Pressure support was weaned over the next 3 days without collapse of the remaining left lung (Table 1, day 7), and the left bronchus was extubated on day 10. The patient was discharged in good condition on day 11.

3 | DISCUSSION

Complete unilateral lung collapse that results in hypoxemia and respiratory decompensation is one of the major

complications following pulmonary resection. As we have shown in this case, severe unilateral lung disease is difficult to treat with traditional endotracheal intubation and mechanical ventilation. Even an advanced form of DLV was not sufficient to keep the lung open permanently.¹ Our method of selective mechanical ventilation of the left lung, combined with normal breathing on the right lung, has, to our knowledge, not been described earlier.

The active use of the diaphragm probably helped improve air distribution in the dependent areas of the lungs. The idea and motivation come from basic respiratory physiology. The diaphragm is the most important muscle of inspiration. Thanks to the diaphragmatic contractions, gas is also pulled into the richly blood perfused alveoli in the pulmonary basis. More gas exchange can take place. The spontaneously contracting diaphragm provides a better distribution of ventilation in relation to perfusion. During deep sedation, the diaphragm remains inactive and passive positive pressure inspiration distributes the tidal volume to areas of better compliance which may not be richly blood perfused. Positive pressure ventilation results in greater air distribution to the non-gravity-dependent portion of the lung and also tends to increase blood flow even more toward gravity-dependent portions of lung.

The intubation of the left main bronchus via a tracheostoma was a key factor to keep a fully conscious and cooperative patient. Tracheostomy is so much better tolerated compared to oral intubation. Therefore, the need for sedation is decreased, and as a consequence, the diaphragm is kept active. When performed regularly, percutaneous tracheotomy is now a safe procedure with a low short-term complication rate.³ When performed by a small dedicated number of persons, we have previously shown that percutaneous tracheotomy is a safe procedure also with very low numbers of low long-term complications.⁴ Although our new method for single left lobe recruitment could seem complex at first, it was not complicated to perform. Once percutaneous tracheotomy is considered safe, also the rest of our procedure is safe.

The anatomic differences between the left and the right main bronchus make our method ideal for recruiting the left lung. At the same time, it is nearly impossible to use it in the right lung as the right main bronchus is much shorter than the left main bronchus. The respective mean length is in men 2.3 cm vs. 5.4 cm and in women 2.1 cm vs. 5.0 cm. Intubation of the left main bronchus is consequently less hazardous with respect to possible retrograde dislocation

into the trachea and antegrade occlusion of the secondary bronchi.

When performed by a small dedicated number of persons, differential ventilation of the lungs with this novel method is feasible and safe and may increase the likelihood of successful treatment of atelectatic left lungs refractory to conventional ventilator strategies.

CONFLICT OF INTERESTS

None declared.

AUTHORSHIP

KD developed the DLV method described in this paper, participated in treatment of the patient, and drafted the manuscript. EWN revised the manuscripts and performed critical reviews.

COMPLIANCE WITH ETHICAL STANDARDS

Written informed consent was obtained from the patient.

ORCID

Knut Dybwik  <http://orcid.org/0000-0002-2723-9279>

REFERENCES

1. Skjeflo GW, Dybwik K. A new method of securing the airway for differential lung ventilation in intensive care. *Acta Anaesthesiol Scand.* 2014;8(4):463-467.
2. Anantham D, Jagadesan R, Tiew PEC. Clinical review: independent lung ventilation in critical care. *Crit Care.* 2005;9(6):594-600.
3. Rosseland LA, Laake JH, Stubhaug A. Percutaneous dilatational tracheotomy in intensive care unit patients with increased bleeding risk or obesity. A prospective analysis of 1000 procedures. *Acta Anaesthesiol Scand.* 2011;55(7):835-841.
4. Storm B, Dybwik K, Nielsen EW. Late complications after percutaneous tracheostomy and oral intubation: evaluation of 1,628 procedures. *Laryngoscope.* 2015;126(5):1077-1082.

How to cite this article: Dybwik K, Nielsen EW. A successful new method for single left lobe recruitment. *Clin Case Rep.* 2018;6:2309–2312. <https://doi.org/10.1002/ccr3.1787>