

# Clinical Analysis of Cultured Epidermal Autograft (JACE) Transplantation for Giant Congenital Melanocytic Nevus

Kento Takaya, MD\*  
 Tatsuya Kato, MD\*  
 Tatsuyuki Ishii, MD\*  
 Shigeki Sakai, MD, PhD\*  
 Keisuke Okabe, MD, PhD\*  
 Noriko Aramaki-Hattori, MD,  
 PhD\*  
 Toru Asou, MD, PhD†  
 Kazuo Kishi, MD, PhD\*

**Background:** Cultured epidermal transplantation (JACE) is performed for giant congenital melanocytic nevus (GCMN), but there are few reports on its postoperative course and surgical content or indications. We aimed to investigate the postoperative course of GCMN patients undergoing cultured epidermal autograft transplantation and compare the outcomes between 2 nevus tissue resection methods.

**Methods:** Twelve GCMN patients aged 0 months to 8 years and 9 months were included in this single-center case series study. Cultured epidermal autograft transplantation was performed at 19 sites of the patients' extremities and trunks, after excision of the nevus either by using an electric dermatome, which we initially used in 2017, or by curettage with a sharp spoon and use of a hydrosurgery system (Versajet), which we started performing in 2018. Univariate and multivariate analyses were performed for factors associated with postoperative hypertrophic scar formation.

**Results:** In all cases, >90% of the grafts survived, and the dark brown color of the nevus was reduced. Average postoperative observation period was 16.5 months. Hypertrophic scar formation was observed postoperatively at 9 wound sites out of the 12 sites with GCMN removed with a dermatome and at only 1 site with GCMN removed by curettage with use of a hydrosurgery system. In the univariate and multivariate analyses, hypertrophic scar formation was associated with age at surgery.

**Conclusion:** In cultured epidermal autograft transplantation for GCMN, nevus tissue removal at an early age by curettage with use of a hydrosurgery system can provide good results while reducing complications, including recurrence and hypertrophic scar formation. (*Plast Reconstr Surg Glob Open* 2021;9:e3380; doi: 10.1097/GOX.0000000000003380; Published online 26 January 2021.)

## INTRODUCTION

Giant congenital melanocytic nevus (GCMN) is generally defined as a nevus with a diameter of  $\geq 20$  cm in adults and  $\geq 6$  cm on the trunk or  $\geq 9$  cm on the head in neonates.<sup>1</sup> The prevalence of GCMN is between 1/20,000 and 1/500,000.<sup>2</sup> The risk of transformation from GCMN to a malignant melanoma is between 0% and 3.8%,<sup>3</sup> but half of these cases were reported to develop before 3 years of age, and the prognosis after onset is poor. Therefore,

its timely treatment is essential.<sup>4</sup> In addition to the risk of malignant transformation, GCMN patients require treatment for cosmetic reasons.

GCMN is often difficult to resect simply owing to its size. One treatment for pigmented nevus is melanin destruction using a carbon dioxide (CO<sub>2</sub>) laser or a Q-switched yttrium aluminum garnet laser, but this method requires a longer time for epithelialization, and there is a high probability that the nevus cells still remained on the wound. Skin grafting is also another option for treating GCMN, but it carries the same risks as do laser therapy and leads to new scar formations at the donor site. At times, the curettage of the nevus tissue may be performed in newborns, but re-epithelialization may take a longer time, which increases the risk of infection. Moreover, this method can cause residual nevus cells in the deep layers.<sup>5</sup>

In Japan, the cultured epidermal autograft (CEA) (JACE; Japan Tissue Engineering Co., Ltd., Gamagori, Japan) was approved for use in 2007 and was covered by the National Health Insurance for burns exceeding 30%

From the \*Department of Plastic and Reconstructive Surgery, Keio University School of Medicine, Tokyo, Japan; and †Tokyo Cosmetic Surgery Clinic, Tokyo, Japan.

Received for publication October 2, 2020; accepted November 23, 2020.

Copyright © 2021 The Authors. Published by Wolters Kluwer Health, Inc. on behalf of The American Society of Plastic Surgeons. This is an open-access article distributed under the terms of the [Creative Commons Attribution-Non Commercial-No Derivatives License 4.0 \(CCBY-NC-ND\)](https://creativecommons.org/licenses/by-nc-nd/4.0/), where it is permissible to download and share the work provided it is properly cited. The work cannot be changed in any way or used commercially without permission from the journal.

DOI: 10.1097/GOX.0000000000003380

**Disclosure:** The authors have no financial interest to declare in relation to the content of this article.

of body surface area. From 2016, the insurance coverage has been extended to GCMN cases.

Based on our previous experience of transplanting enzymatically treated epidermal grafts for GCMN,<sup>6</sup> when CEA was used for GCMN, we first excised the nevus tissue with an electric dermatome. However, owing to the frequent formations of hypertrophic scars after surgery, we changed the method of nevus tissue removal in 2018. The new method used was curettage using a sharp spoon and residual lesion removal using a hydrosurgery system (Versajet; Smith & Nephew KK, Tokyo, Japan).

There are few reports of GCMN cases treated with CEA transplantation.<sup>7,8</sup> Previously reported cases of CEA transplantation resulted in lower engraftment rates than split-thickness skin grafts and severe scar contractures in the transplanted area.<sup>9</sup> In addition, no studies have been conducted on how to remove nevus tissue before CEA transplantation. In this study, we investigated the postoperative course of GCMN patients who underwent CEA transplantation and compared the results of 2 methods of excision of nevus tissue before transplantation. Furthermore, we investigated other factors involved in postoperative hypertrophic scar formation and clarified the optimal indication for CEA transplantation for GCMN.

## PATIENTS AND METHODS

This study was conducted in accordance with the Declaration of Helsinki, and the study protocol was reviewed and approved by the Medical Research Ethics Committee of Keio University (approval number: 20150394). Written informed consent was obtained from the parents or guardians of the patients before study participation, including consent to participate and to publish the findings.

### Patients

During the period from June 2017 to February 2019, we analyzed the data of GCMN patients ( $n = 12$ ) with nevus of  $\geq 6$ -cm diameter on the trunk or  $\geq 9$ -cm diameter on the head who underwent CEA transplantation at Keio University Hospital (Tokyo, Japan). There were 5 boys and 7 girls, with ages ranging from 0 month to 8 years and 9 months (average: 4 years and 10 months). CEA transplantation was performed on 19 sites among the 12 patients. None of the patients had other complications, including intraparenchymal or leptomeningeal deposition in the central nervous system. The duration of postoperative follow-up ranged from 6 to 21 months (average: 16.5 months).

## METHODS

### Preparation of CEA (JACE)

Skin extraction for CEA, GCMN removal, and CEA transplantation were performed during an independent surgery. For CEA creation, the procedure was performed under general anesthesia, and the skin from the abdomen with a size of  $2\text{ cm}^2$  was collected using a template with all skin layers. Then, the donor site was simply sutured. The

collected skin was immersed and preserved in 70% ethanol, and CEA was prepared by Japan Tissue Engineering Co., Ltd. (Gamagori, Japan).

### Nevus Tissue Removal and CEA Transplantation

At approximately 1 month after the skin removal, GCMN removal and CEA transplantation were performed under general anesthesia. The GCMN lesions were removed as much as possible either (1) by using an electric dermatome or (2) by performing curettage with a sharp spoon and use of a hydrosurgery system. The latter method was applied to all patients who underwent surgery after February 2018. For nevus removal using an electric dermatome, lesions with a thickness of 300–450  $\mu\text{m}$  were excised until the dark brown color of the nevus was reduced. The nevus was “curetted” by scraping from its center in the direction of the maximum relaxation line using a sharp spoon until the dark brown color of the nevus disappeared. The residual lesions were then removed using a hydrosurgery system. Curettage became more difficult around the lesion, but the procedure was relatively nontraumatic and avascular. The edges of this joint usually had to be shaved down using the scalpel. In some cases, the nevus tissues were vaporized with  $\text{CO}_2$  laser until the dark brown color was markedly reduced. Given that the patients were infants or children, extra precautions were taken to minimize blood loss. Immediately after the pigmented lesion was removed, a gauze was soaked in an epinephrine solution ( $\times 10,000$ ) and applied to the wound.

The CEA has a short side of 8 cm and a long side of 10 cm (effective area:  $80\text{ cm}^2$ ), and it was placed in a position that partially overlaps the wound after the removal of the nevus tissues. A silicone wound dressing (SI-Mesh, ALCARE Co. Ltd., Tokyo, Japan) was fixed on the CEA with a skin stapler (3M Japan Limited, Tokyo, Japan). The dressing was removed at 1 week after transplantation, under general anesthesia.

The postoperative course was evaluated for recurrence, grade of the hypertrophic scar, and presence or absence of surgery (cicatrization) for the hypertrophic scar. The grade of the hypertrophic scar was scored as follows: 0, none; 1, mild; and 2, severe. The distribution of patients according to the grade of the hypertrophic scar is shown in [Table 1](#).

### Statistical Analysis

Univariate and multivariate analyses were performed to determine whether there was a difference in the formation of hypertrophic scars by age at surgery, gender, site, and method of nevus resection (by using an electric dermatome or by curettage with use of a hydrosurgery system). IBM SPSS Statistics for Windows, version 25 (IBM Corp., Armonk, N.Y.) was used for the statistical analysis. Owing to the limited number of samples, it was difficult to ensure normality of data; thus, different statistical methods were used. Willcoxon’s rank sum test was used for age at surgery, the test for equal proportion was used for gender and method of nevus resection, and chi-squared test and Fisher’s exact test were used for the sites (19 sites

**Table 1. The Demographic and Clinical Characteristics of the Patients with GCMN Enrolled in This Study**

Patient No.	Gender	Age (mo)	Site	Resection Method for Nevus Tissue	Re-pigmentation	Hypertrophic Scar	Contracture Release Surgery	Take Ratio after 1 Week (%)
1	Men	96	Back, flank, thigh (back)	Use of a dermatome	+	Flank:2 Back:0	—	90
2	Women	101	Abdomen, thigh (front)		—	2	+	90
3	Women	47	Back, shoulder	Curettage + use of Versajet	—	2	—	95
4	Women	109	Buttock, thigh (back)		—	1	—	99
5	Men	101	Abdomen, buttock, thigh (back)		—	1	—	99
6	Men	91	Back, buttock, thigh (back)		—	2	—	90
7	Men	93	Abdomen, thigh (front)		—	2	+	90
8	Women	106	Abdomen, thigh (front)		—	2	—	90
9	Women	109	Buttock, thigh (back)		—	2	—	95
10	Women	20	Back, thigh (abdomen)		—	0	—	95
11	Men	22	Abdomen, thigh (front)		—	0	—	95
12	Men	14	Back		+	0	—	99
13	Women	17	Abdomen		—	0	—	95
14	Women	14	Upper arm (lateral)		—	1	—	95
15	Women	24	Upper arm (medial)	—	0	—	99	
16	Men	61	Back	+	0	—	99	
17	Women	12	Back	—	0	—	95	
18	Women	14	Abdomen	—	0	—	99	
19	Women	51	Back, buttock	—	0	—	90	

Hypertrophic scar scores: 0, none; 1, mild; 2, severe.

**Table 2. Results of the Univariate and Multivariate Analyses**

	Hypertrophic Scar		<i>P</i>	Univariate Analysis OR	Multivariate Analysis OR
	+	—			
Age	2.72	7.52	0.000	2.0* (1.4–3.3)	1.8* (1.2–3.0)
Female ratio	0.69	0.47	0.389		
Site					
Back	5	3	1		
Abdomen	3	4	1		
Buttock	2	4	1		
Upper arm	1	2	1		
Leg	2	6	1		
Curettage + Versajet	0.62	0.05	0.002	0.03* (0.00–0.3)	0.18 (0.01–2.3)

*P* < 0.05 was considered statistically significant.

with hypertrophic scars, 13 sites without scars). The multivariate analysis was performed using generalized estimation equations, taking into consideration the fact that there were multiple data obtained from the same patient (Table 2). *P* < 0.05 were considered statistically significant.

## RESULTS

The engraftment of CEA was >90% in all patients. In all cases, the color tone of the nevus improved postoperatively. No complications, such as seroma, hematoma, and infection, occurred. At approximately 1 week after the operation, re-epithelialization was observed.

In the cases that underwent nevectomy with an electric dermatome, the dark brown color tone was almost completely eliminated postoperatively. Six patients had hypertrophic scars at 9 sites after the surgery, with 2 patients having severe scar contracture requiring surgery for cicatrization. At 1 month after the operation, the dark brown color tone recurred at 1 site. In all patients, the wounds at the donor site healed at 1 week postoperatively with no adverse events.

Among the cases with nevus tissues excised by curettage with a sharp spoon and use of a hydrosurgery system, only 1 case had a hypertrophic scar formation after the surgery. In addition, although the color tone improved in

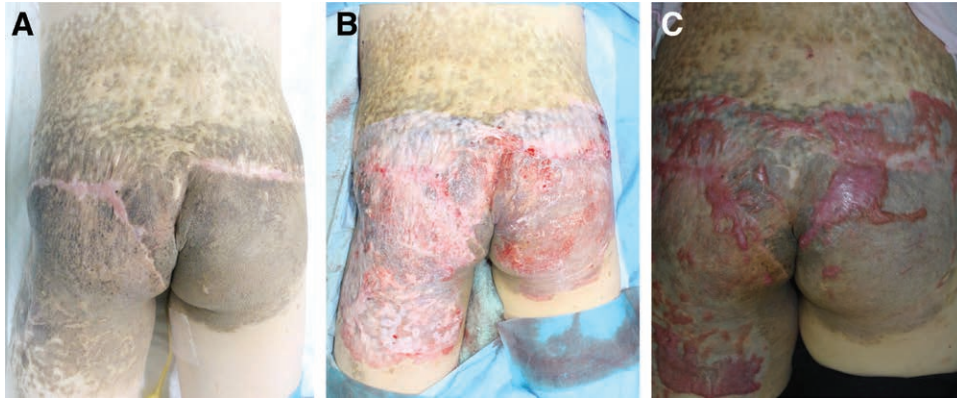
all these cases, the complete removal of the lesion was difficult. No other adverse events occurred in both the recipient and donor sites.

### Case 1 (Patient 3 in Table 1)

A 9-year-old girl had GCMN on the buttocks and both thighs. During childhood, split resections were performed twice for the nevus on the hip, but most of the lesions remained and the scar was expanding. Under general anesthesia, the entire area with a thickness of 300 μm was excised continuously by using an electric dermatome until the brown color disappeared. After excision, the CEA was transplanted, which showed good engraftment postoperatively. At 1 year after the operation, there was no recurrence of the dark brown color tone, but a hypertrophic scar was noted (Fig. 1).

### Case 2 (Patient 6 in Table 1)

An 8-year-old girl had GCMN on the abdomen, buttocks, and both thighs. Under general anesthesia, the entire area of GCMN on her buttocks and thighs with a thickness of 300 μm was excised continuously by using an electric dermatome until the dark brown color disappeared. After excision, the cultured epidermis was transplanted, which showed good engraftment postoperatively.



**Fig. 1.** A 9-year-old girl with GCMN on her buttocks and both thighs, treated with CEA transplantation. She has previously undergone split resection twice for the nevus of the buttocks. A, Before treatment. B, After dermabrasion. C, At 1 year after the operation, there was no recurrence of GCMN, but she had hypertrophic scar formation on her buttocks.

After the second half of the operation, there was no recurrence of the dark color tone, but a hypertrophic scar formed at the wound site (Fig. 2).

**Case 3 (Patient 8 in Table 1)**

A 1-year-old boy had GCMN on his back and waist. Under general anesthesia, the entire area of the nevus was removed by curettage using a sharp spoon until the brown color disappeared, and then the residual lesion was removed using a hydrosurgery system. After excision, the cultured epidermis was transplanted, which showed good engraftment postoperatively. At 6 months after the operation, there was no hypertrophic scar formation. The color tone of the site on his waist improved, but some dark color tone remained at the site on the back (Fig. 3).

**Case 4 (Patient 10 in Table 1)**

A one-year-old boy had GCMN on his back. Under general anesthesia, the entire area of the nevus was removed by curettage using a sharp spoon until the dark brown color disappeared, and then the residual lesion was removed using a hydrosurgery system. After excision, the cultured epidermis was transplanted, which showed good

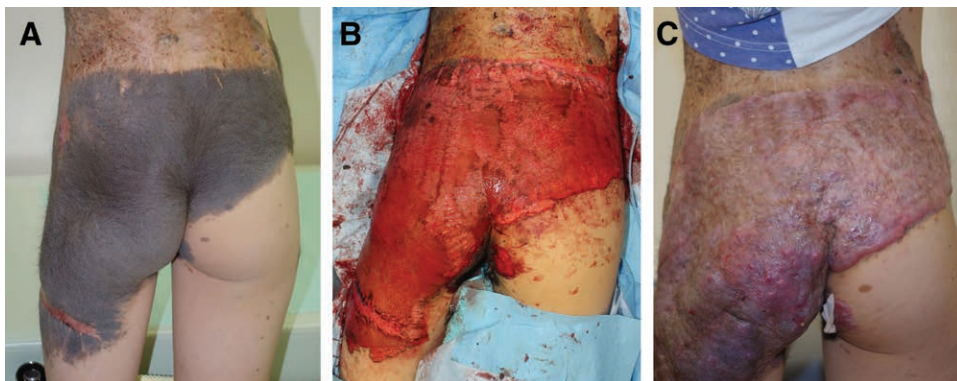
engraftment. At 4 months after the operation, there was no formation of hypertrophic scar and the color tone improved, but a mild brown color tone remained at the site and hair growth was observed (Fig. 4).

**Case 5 (Patient 1 in Table 1; a relapse case)**

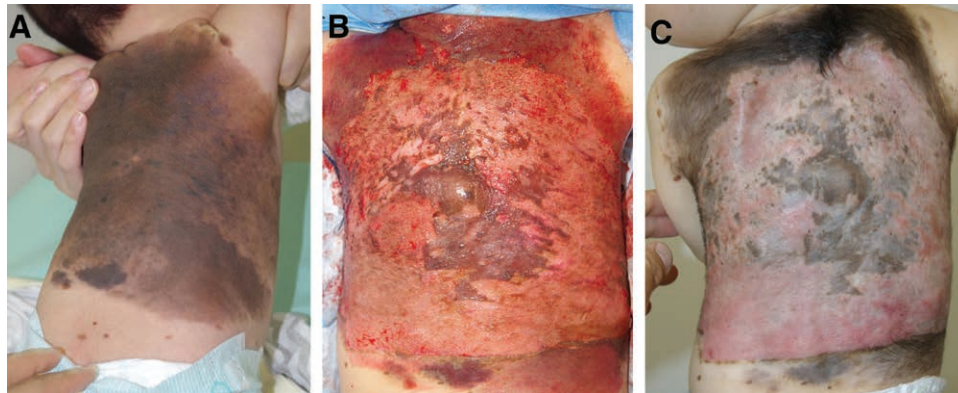
A 7-year-old boy had GCMN on the flank, buttocks, and both thighs. Under general anesthesia, the GCMN on the buttock with a thickness of 450 μm was excised continuously by using an electric dermatome until the brown color disappeared. The engraftment of the cultured epidermis was good, but the dark brown color tone recurred at 7 months after the operation. The pathological image of the nevus tissue showed a honeycomb formation of the nevus cells with pigmentation from the epidermal dermis boundary to the deep dermis and around the subcutaneous adipose tissue (Fig. 5).

**Correlation between Hypertrophic Scar Formation and Age at Surgery and Resection Methods of GCMN**

The results of the univariate analysis showed a significant correlation between the formation of hypertrophic scars and age at surgery [ $P < 0.001$ , odds ratio (OR) = 2.0



**Fig. 2.** An 8-year-old girl with a GCMN on her buttocks, treated with CEA transplantation. A, Before treatment. B, After dermabrasion. C, At 6 months after the operation, there was no recurrence of the nevus, but there was a marked hypertrophic scar on her buttocks.



**Fig. 3.** A 1-year-old boy with a GCMN on his back and waist, treated with CEA transplantation. A, Before treatment. B, After dermabrasion. C, At 4 months after the operation, there was no hypertrophic scar formation, but a light brown color tone of the nevus remained on his back.

(1.4–3.3)] and the resection method of using curettage and a hydrosurgery system [ $P = 0.002$ , OR = 0.03 (0.00–0.03)]. In the multivariate analysis, only age at surgery showed a correlation with hypertrophic scar formation [OR = 1.8 (1.2–3.0)] (Table 2). As a result, it is suggested that the younger the age at the time of surgery, the lower the risk of postoperative scarring.

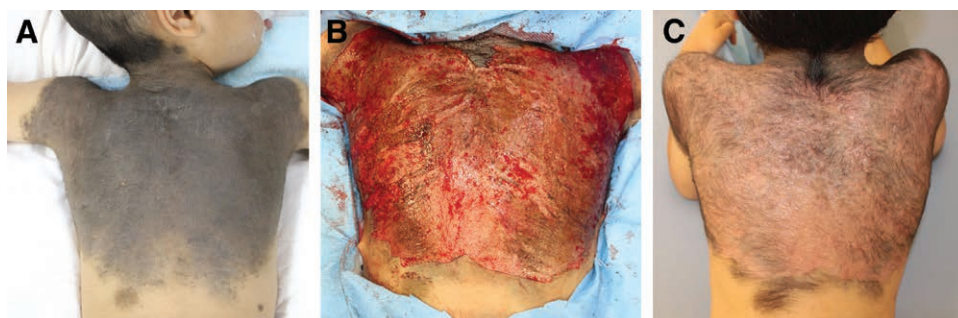
### DISCUSSION

The purpose of the treatment for GCMN is to improve the affected area's appearance and eliminate the risk of malignant transformation, and it is necessary to achieve complete disappearance of the dark color tone. In September 2016, CEA (JACE) was approved for the treatment of GCMN, which is difficult to treat using standard treatments. Our study is the first in Japan to report the postoperative course of several patients with GCMN treated by transplantation of the CEA.

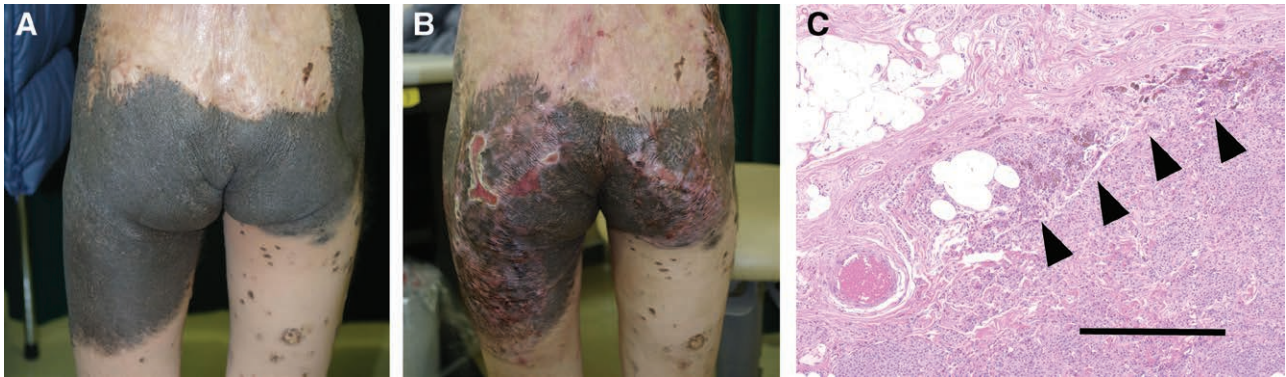
In all cases, CEA survived without adverse events, other than the hypertrophic scar formation, and the affected sites' dark brown color was reduced. To date, skin grafting,<sup>10</sup> scraping,<sup>11,12</sup> laser transpiration,<sup>13,14</sup> or reconstruction using a tissue expander<sup>15,16</sup> have been used as other treatment options for GCMN. However, skin grafting also leaves large scars at the donor sites, and the use of tissue expanders limits the size of GCMN that can be treated.

Given that laser treatments are performed frequently, the area that can be treated is limited. Epithelization takes a long period of time in cases treated by curettage, which increases the risk of hypertrophic scar formation and infection. On the other hand, previous reports indicate that the removal of nevus cells does not increase the risk of cancer at the treatment site.<sup>17,18</sup> In our experience, there were no adverse events at the transplantation site or the donor site, and the size of the donor site was very small, indicating that performing curettage is more practical than using the other existing methods.

Previously reported CEA transplants for GCMN had an engraftment rate of 68% (20%–93%), which is lower than that of comparative split-thickness skin grafts.<sup>9</sup> In this report, the nevus tissue has been resected on the fascia to prevent recurrence. GCMN nevus cells are estimated to be abundant in the lower two-thirds of the dermis and subcutaneous tissue,<sup>19</sup> allowing cells to invade adipose tissue or muscle even when all skin layers have been removed. Thus, the complete removal of GCMN is often not possible. We have previously reported that pigmented nevus cells remain around the skin appendages in the dermis, based on the histology of GCMN cases that had recurrence early after the curettage.<sup>20</sup> It is possible that the recurrence in our cases occurred through a similar mechanism. In all of our cases, the survival rate of CEA was  $\geq 90\%$ , which is



**Fig. 4.** A 1-year-old boy with a GCMN on his back, treated with CEA transplantation. A, Before treatment. B, After dermabrasion. C, At 6 months after the operation, there was no hypertrophic scar formation, but mild re-pigmentation and hair growth were observed.



**Fig. 5.** A 7-year-old boy with a GCMN on his buttocks, treated with CEA transplantation (patient 1 in Table 1). A, Before treatment. B, At 7 months after the operation, marked re-pigmentation was observed. C, Histological samples (hematoxylin and eosin staining) obtained after total skin resection showing pigmented nevus cells aggregating around the deep dermis and subcutaneous adipose tissue. Bar = 400  $\mu$ m.

considered to be due to the remaining components of the dermis. Some patients had a relapse or persistence of dark tones after transplantation, but engraftment rates suggest that it is better to leave the dermal component for CEA transplantation.

We compared the characteristics between the patients with nevus tissues resected by using an electric dermatome and those with nevus tissues resected by curettage and with the use of a hydrosurgery system. The results suggested that hypertrophic scars were more prominent in those who underwent excision using an electric dermatome. Although there was no significant difference in the multivariate analysis, the latter method may be able to prevent hypertrophic scars, which is an important issue with CEA.

Our statistical analysis also showed the correlation between hypertrophic scar formation after transplantation of CEA and age at surgery. These results suggest that the younger the age, the lesser the risk for postoperative hypertrophic scar formation. A previous report indicated that hypertrophic scar formation is negatively correlated with age and that younger patients tend to have hypertrophic scar formations.<sup>21</sup> However, this report investigated children aged  $\geq 10$  years, which differed from our case series, as our children were between 0 month and 8 years and 9 months of age. Thus, it is necessary to investigate patients treated by curettage with the use of a hydrosurgery system in a wide age group. In addition, it has been reported that the hydrosurgery system (Versaget) does not lead to hypertrophic scar formation when used in infants.<sup>22</sup> This method may be useful for removing nevus cells without complications.

This study has several limitations. First, it is difficult to ensure normality of data for the statistical analysis owing to the small number of cases. Second, confounding factors cannot be eliminated because the age at surgery and surgical procedures changed at the same time. Third, the bias of the nevus site between treatment groups is not sufficient to investigate whether transplantation in joints and moving parts affects the formation of hypertrophic scars. In the future, further studies should investigate a larger number of cases of CEA transplantation for GCMN to confirm our findings. As a result, CEA is a potential

treatment for GCMN that offers both treatment and cosmetic improvement.

## CONCLUSIONS

CEA transplantation for GCMN improves the affected area's color tone safely, and it only required a small donor site. When transplanting CEA for GCMN, it is recommended to perform surgery on patients at around the age of 1 year to prevent postoperative hypertrophic scar formation. Moreover, the removal of nevus tissue by curettage with the use of a hydrosurgery system might reduce the risk of hypertrophic scar formation after transplantation.

**Kento Takaya, MD**

Keio University School of Medicine

35 Shinanomachi, Shinjuku-ku

Tokyo 160-8582

Japan

E-mail address: [kento-takaya312@keio.jp](mailto:kento-takaya312@keio.jp)

## ACKNOWLEDGMENT

The authors acknowledge Dr. Tetsuhiro Yoshino, Center for Kampo Medicine, Keio University School of Medicine, for his help in the statistical analysis of the results of this study.

## REFERENCES

1. Kopf AW, Bart RS, Hennessey P. Congenital nevocytic nevi and malignant melanomas. *J Am Acad Dermatol.* 1979;1:123–130.
2. Castilla EE, da Graça Dutra M, Orioli-Parreiras IM. Epidemiology of congenital pigmented naevi: II. Risk factors. *Br J Dermatol.* 1981;104:421–427.
3. Zaal LH, Mooi WJ, Klip H, et al. Risk of malignant transformation of congenital melanocytic nevi: A retrospective nationwide study from the Netherlands. *Plast Reconstr Surg.* 2005;116:1902–1909.
4. Trozak DJ, Rowland WD, Hu F. Metastatic malignant melanoma in prepubertal children. *Pediatrics.* 1975;55:191–204.
5. Marghoob AA, Borrego JP, Halpern AC. Congenital melanocytic nevi: Treatment modalities and management options. *Semin Cutan Med Surg.* 2007;26:231–240.
6. Kishi K, Ninomiya R, Okabe K, et al. Treatment of giant congenital melanocytic nevi with enzymatically separated epidermal sheet grafting. *J Plast Reconstr Aesthet Surg.* 2010;63:914–920.

7. Morimoto N, Kakudo N, Kako A, et al. A case report of the first application of culture epithelial autograft (JACE) for giant congenital melanocytic nevus after its approval in Japan. *J Artif Organs*. 2018;21:261–264.
8. Maeda T, Morimoto N, Kakudo N, et al. Efficacy of cultured epithelial autograft after curettage for giant melanocytic nevus of the head. *Plast Reconstr Surg Glob Open*. 2018;6:e1827.
9. Gallico GG III, O'Connor NE, Compton CC, et al. Cultured epithelial autografts for giant congenital nevi. *Plast Reconstr Surg*. 1989;84:1–9.
10. Bauer BS, Vicari FA. An approach to excision of congenital giant pigmented nevi in infancy and early childhood. *Plast Reconstr Surg*. 1988;82:1012–1021.
11. De Raeve LE, Roseeuw DI. Curettage of giant congenital melanocytic nevi in neonates: A decade later. *Arch Dermatol*. 2002;138:943–947.
12. Zaal LH, Mooi WJ, Sillevs Smitt HJ. Results of early curettage of giant congenital melanocytic nevi; a report of eight cases and review of the literature. *Eur J Plast Surg*. 2008;30:257.
13. Reynolds N, Kenealy J, Mercer N. Carbon dioxide laser dermabrasion for giant congenital melanocytic nevi. *Plast Reconstr Surg*. 2003;111:2209–2214.
14. Kishi K, Okabe K, Ninomiya R, et al. Early serial Q-switched ruby laser therapy for medium-sized to giant congenital melanocytic naevi. *Br J Dermatol*. 2009;161:345–352.
15. Gonzalez Ruiz Y, López Gutiérrez JC. Multiple tissue expansion for giant congenital melanocytic nevus. *Ann Plast Surg*. 2017;79:e37–e40.
16. LoGiudice J, Gosain AK. Pediatric tissue expansion: indications and complications. *J Craniofac Surg*. 2003;14:866–872.
17. Chan YC, Giam YC. A retrospective cohort study of Southeast Asian patients with large congenital melanocytic nevi and the risk of melanoma development. *J Am Acad Dermatol*. 2006;54:778–782.
18. Zutt M, Kretschmer L, Emmert S, et al. Multicentric malignant melanoma in a giant melanocytic congenital nevus 20 years after dermabrasion in adulthood. *Dermatol Surg*. 2003;29:99–101; discussion 101.
19. Wu M, Yu Q, Gao B, et al. A large-scale collection of giant congenital melanocytic nevi: Clinical and histopathological characteristics. *Exp Ther Med*. 2020;19:313–318.
20. Kishi K, Matsuda N, Kubota Y, et al. Rapid, severe repigmentation of congenital melanocytic naevi after curettage and dermabrasion: Histological features. *Br J Dermatol*. 2007;156:1251–1257.
21. Berg P, Lindelöf B. Congenital nevocytic nevi: Follow-up of a Swedish birth register sample regarding etiologic factors, discomfort, and removal rate. *Pediatr Dermatol*. 2002;19:293–297.
22. Sivrioğlu N, Irkören S. Versajet hydrosurgery system in the debridement of skin necrosis after Ca gluconate extravasation: Report of 9 infantile cases. *Acta Orthop Traumatol Turc*. 2014;48:6–9.