

CASE REPORT

Synchronous AML and pancreatic neuroendocrine neoplasm, both successfully treated with somatostatin analogs and decitabine

Syed Ehsanullah^{1,2} and Nikolaos A Trikalinos^{1,2}¹Division of Oncology, Department of Medicine, Washington University School of Medicine, St Louis, Missouri, USA²Siteman Cancer Center, St Louis, Missouri, USACorrespondence should be addressed to S Ehsanullah: syedusman@wustl.edu

Summary

Downregulation of tumor suppression genes by DNA hypermethylation has been proposed as a potential cause of neuroendocrine neoplasm (NEN) formation. In this report, we present a patient simultaneously diagnosed with acute myeloid leukemia (AML) and a metastatic nonfunctioning pancreatic NEN. Because of the two competing diagnoses, he was treated with lanreotide, venetoclax and a long course of the hypomethylating agent decitabine. The AML responded to venetoclax and decitabine treatment while the PanNEN stabilized on lanreotide. Over multiple months of treatment, the PanNEN showed gradual tumor response, consistent with decitabine treatment effect, and the patient remained without disease progression for both malignancies. We believe that some PanNENs can benefit from treatment with hypomethylating agents such as decitabine. To support this, we review the relevant literature and suggest a mechanism for the efficacy of decitabine in our case.

Learning points:

- Neuroendocrine neoplasms are associated with an increased risk of second primary cancers.
- Epigenetic changes such as hypermethylation and inhibition of tumor suppressor genes might explain the development and behavior of certain NENs.
- The use of hypomethylating agents such as decitabine might have a role in the treatment of PanNENs. Future studies are needed to confirm that.

Background

Pancreatic neuroendocrine neoplasms (PanNEN) can be challenging to treat, owing to their rarity and heterogeneity. Their incidence and prevalence have increased in the last few decades and so has, thankfully,

our understanding of their pathogenesis. Unfortunately, systemic treatment options are still limited to somatostatin analogs, everolimus, sunitinib and peptide receptor radionuclide therapy, with preliminary data on the efficacy of capecitabine and temozolomide. Treatment becomes more complicated in the setting of a synchronous

secondary neoplasm, reported in about 2.8% of NENs (Kamp *et al.* 2012). In such patients, physicians must either prioritize treatment of the more aggressive malignancy or combine nonoverlapping agents to address all histologies. Here, we present a patient with no significant past medical history who was simultaneously diagnosed with a PanNEN and acute myelogenous leukemia (AML).

Case presentation

A 78-year-old patient with a past medical history of Barrett’s metaplasia but otherwise excellent performance status complained of acute abdominal pain. A CT scan and MRI of the abdomen demonstrated a 4.7 × 3.8 cm mass in the pancreas with pancreatic duct dilatation and obstruction of the superior mesenteric vein (SMV).

Based on a concern for adenocarcinoma histology, he underwent endoscopic ultrasound-guided biopsy demonstrating PanNEN with a Ki-67 of 10%. A gallium dotatate PET/CT showed somatostatin receptor avid primary pancreatic malignancy with mesenteric lymphadenopathy and multiple areas of osseous metastatic disease including manubrium and L2 vertebral body (Fig. 1). A fluorodeoxyglucose (FDG) PET/CT demonstrated only a mildly FDG avid pancreatic head neoplasm consistent with well-differentiated grade II histology. He did not have evidence of hormone hypersecretion. He discussed observation vs somatostatin analogs and agreed on treatment with lanreotide to prevent disease progression. On his first clinic follow-up, the patient was found to have significant hematological abnormalities, including anemia and thrombocytopenia (platelets of 15,000), as well as 37% myeloblasts on peripheral smear.

Investigation

Flow cytometry showed expression of CD45 (dim), CD33, CD117, CD13 (partial) and CD38, and MPO reactive. Bone

marrow biopsy confirmed the diagnosis of AML-M1 by WHO/FAB classification. Next-generation sequencing (NGS) on AML (MyeloSeq™) showed NPM1 exon 11, frameshift mutated (VAF 28%), FLT3 exon 14 ITT, IDH2 R140Q, exon 4 and missense (VAF 36%). NGS – FoundationOne™ on the PanNEN showed no actionable mutations or PD-L1 expression and stable microsatellite status. An IDH2 R140Q mutation in the PanNEN specimen was eventually found to be contaminated by leukemic cells with a VAF of 3%.

Treatment

He was started on a regimen of decitabine plus venetoclax for about 5 months followed by decitabine maintenance for his leukemia. He also continued on lanreotide given no presumed interactions between the agents and no overlapping toxicities after discussion with the bone marrow transplant service and the oncology pharmacy.

Outcome and follow-up

He had a complete hematologic and marrow remission of his AML and remained on maintenance decitabine. His neuroendocrine tumor burden remained stable on restaging imaging for about 12 months, but PET scan 16 months after diagnosis showed a significant decrease in primary pancreatic NEN size, from 4 × 4.6 cm to 3.8 × 3.2 cm with stable osseous lesions and no evidence of new disease. He remained without evidence of progression in any of his two malignancies but expired of a hemorrhagic cerebrovascular accident (CVA).

Discussion

In this case report, we present a patient with PanNEN who was exposed to hypomethylating agents because of a secondary diagnosis of acute myelogenous leukemia. Over

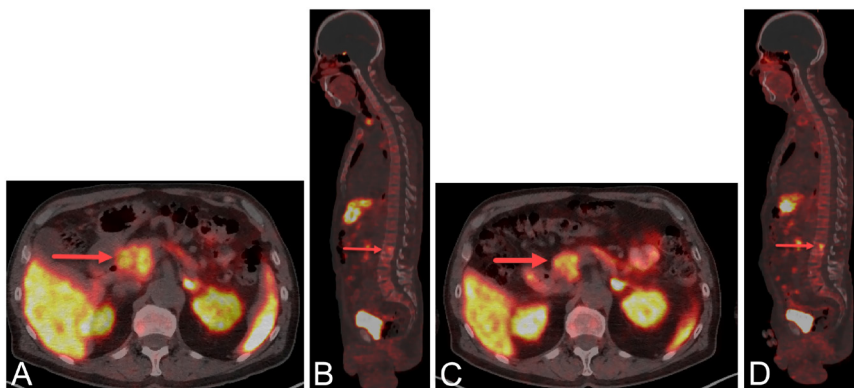


Figure 1

Treatment response with decitabine. (A) Trans-axial gallium dotatate PET/CT demonstrating large pancreatic head neuroendocrine tumor (4 × 4.6 cm) with metastatic disease. (B) Sagittal gallium dotatate PET/CT scan demonstrating metastatic L2 lesion, compatible with osseous metastatic disease. (C) Trans-axial gallium dotatate PET/CT demonstrating interval decrease in the size of pancreatic head mass 3.8 × 3.2 cm. (D) Sagittal gallium dotatate PET/CT scan demonstrating unchanged L2 lesion, compatible with stable to improved osseous metastatic disease.

a long period of time, there was an unexpected response in the PanNEN with tumor shrinkage, consistent with the late effect of decitabine.

Our patient did not have any actionable mutations, consistent with published literature on low-grade NENs. Epigenetic mechanisms, such as methylation, more than mutations in the more commonly described oncogenic genes (such as TP53 or RB1) have been implicated in the pathogenesis of some NENs. Methylation-specific polymerase chain reactions were conducted on well-differentiated pancreatic NENs to identify the transgressing methylation of tumor suppressor genes (INK4a/p16, APC, O6-MGMT, hMLH1, p73, E-cadherin, RAR- β , p14ARF, GST- π , TIMP3, and RASSF1A). In PanNENs, Ras-association domain gene family 1 (RASSF1 hypermethylation) was shown in about 75% of the cases in a small series with metastatic locations also showing the same hypermethylation and is more common in metastatic tumors compared to nonmetastatic ones. Hypermethylation of tumor suppressor genes is directly proportional to aggressive and metastatic NENs. A higher expanse of hypermethylation of tumor suppressor genes was exhibited in tumors larger than 5 cm and those associated with lymph node or hepatic metastases (House *et al.* 2003). It is also associated with tumor recurrence and patient survival.

Promoter methylation is also a frequent finding in gastrointestinal NETs (Pizzi *et al.* 2005). TIMP3 and MGMT promoter methylation has also been shown in about 40% of PanNENs. Gastrin-producing PanNENs frequently exhibit CDKN2A/p16INK4a promoter hypermethylation; it has been found in 52–62.5% of cases and is considered to be one of the first steps in gastrinoma tumorigenesis (de Wilde *et al.* 2012). Methylation of various promoters is a frequent finding in gastrointestinal NETs (Pizzi *et al.* 2005, Zhang *et al.* 2006) (RASSF1A and CTNNB1), bronchial NETs (Pelosi *et al.* 2010) (RASSF1A), as well as Merkel cell carcinomas (Lassacher *et al.* 2008) (RASSF1A). Adrenocortical cancers are generally hypomethylated but there is literature in hypermethylation of CDKN2A and GATA4. Moreover, malignant tumors more frequently demonstrate IGF2 promoter hypermethylation (Fonseca *et al.* 2012).

The effect of hypomethylating agents such as decitabine for the treatment of NENs is not well established but there is a signal pointing to its efficacy. Two bronchial neuroendocrine cell lines including carcinoid NCI-H727 and small cell lung cancer HTB-119 reexpressed RASSF1A mRNA after treatment with decitabine (Zhang *et al.* 2006). The pancreatic neuroendocrine cell line QGP1 was treated with decitabine with the restoration

of CDKN2A/p16INK4a and growth inhibition (Habbe *et al.* 2007). In the same line, 23 out of 48 genes showed a decrease in expression using cDNARDA after treatment with decitabine. Moreover, the NCI-H295R adrenocortical cancer cell line was treated with decitabine restoring the expression of hypermethylated genes; decitabine also inhibited proliferation by 39–47% at 5 days after treatment compared with control specimens. ($P = 0.03$) (Suh *et al.* 2010, Fonseca *et al.* 2012). These pre-clinical findings strongly suggest that hypomethylating agents may be effective in treating multiple types of NENs by restoring the expression of hypermethylated genes.

Significant treatment response was also seen in our case when our patient with panNEN was treated over long periods of time with a hypomethylating agent, decitabine, for his AML. The gradual outcome is consistent with a hypomethylating effect and not with response to lanreotide, an agent that has less than 3% chance of tumor regression and produced no tumor changes for the first 12 months of therapy. It is also not consistent with venetoclax administration, which was also limited (about 5 months) and was not associated with tumor size changes.

While we firmly believe that most of the NEN response in this patient is due to the hypomethylating effect of decitabine, the agent itself is not without significant side effects, and the delayed tumor response will have to be balanced against serious side effects including prolonged cytopenias. The patient in case developed thrombocytopenia and a hemorrhagic CVA while on decitabine and ultimately expired of that. Given limited options for treatment of PanNENs, we feel that hypomethylating agents should be carefully tried in a larger population with particular emphasis on dosing, tolerability and long-term side effects.

Declaration of interest

The authors declare that there is no conflict of interest that could be perceived as prejudicing the impartiality of this work.

Funding

This work did not receive any specific grant from any funding agency in the public, commercial or not-for-profit sector.

Patient consent

Patient is deceased.

Author contribution statement

N A T was one of the treating physicians. S E and N A T cowrote and edited the text.

References

- de Wilde RF, Heaphy CM, Maitra A, Meeker AK, Edil BH, Wolfgang CL, Ellison TA, Schulick RD, Molenaar IQ, Valk GD, *et al.* 2012 Loss of ATRX or DAXX expression and concomitant acquisition of the alternative lengthening of telomeres phenotype are late events in a small subset of MEN-1 syndrome pancreatic neuroendocrine tumors. *Modern Pathology* **25** 1033–1039. (<https://doi.org/10.1038/modpathol.2012.53>)
- Fonseca AL, Kugelberg J, Starker LF, Scholl U, Choi M, Hellman P, Akerstrom G, Westin G, Lifton RP, Bjorklund P, *et al.* 2012 Comprehensive DNA methylation analysis of benign and malignant adrenocortical tumors. *Genes, Chromosomes and Cancer* **51** 949–960. (<https://doi.org/10.1002/gcc.21978>)
- Habbe N, Bert T & Simon B 2007 Identification of methylation-associated gene expression in neuroendocrine pancreatic tumor cells. *Pancreatology* **7** 352–359. (<https://doi.org/10.1159/000107270>)
- House MG, Herman JG, Guo MZ, Hooker CM, Schulick RD, Lillemoe KD, Cameron JL, Hruban RH, Maitra A & Yeo CJ 2003 Aberrant hypermethylation of tumor suppressor genes in pancreatic endocrine neoplasms. *Annals of Surgery* **238** 423–431; discussion 31–32. (<https://doi.org/10.1097/01.sla.0000086659.49569.9e>)
- Kamp K, Damhuis RA, Feelders RA & de Herder WW 2012 Occurrence of second primary malignancies in patients with neuroendocrine tumors of the digestive tract and pancreas. *Endocrine-Related Cancer* **19** 95–99. (<https://doi.org/10.1530/ERC-11-0315>)
- Lassacher A, Heitzer E, Kerl H & Wolf P 2008 p14ARF hypermethylation is common but INK4a-ARF locus or p53 mutations are rare in Merkel cell carcinoma. *Journal of Investigative Dermatology* **128** 1788–1796. (<https://doi.org/10.1038/sj.jid.5701256>)
- Pelosi G, Fumagalli C, Trubia M, Sonzogni A, Rekhman N, Maisonneuve P, Galetta D, Spaggiari L, Veronesi G, Scarpa A, *et al.* 2010 Dual role of RASSF1 as a tumor suppressor and an oncogene in neuroendocrine tumors of the lung. *Anticancer Research* **30** 4269–4281.
- Pizzi S, Azzoni C, Bottarelli L, Campanini N, D'Adda T, Pasquali C, Rossi G, Rindi G & Bordi C 2005 RASSF1A promoter methylation and 3p21.3 loss of heterozygosity are features of foregut, but not midgut and hindgut, malignant endocrine tumours. *Journal of Pathology* **206** 409–416. (<https://doi.org/10.1002/path.1784>)
- Suh I, Weng J, Fernandez-Ranvier G, Shen WT, Duh QY, Clark OH & Kebebew E 2010 Antineoplastic effects of decitabine, an inhibitor of DNA promoter methylation, in adrenocortical carcinoma cells. *Archives of Surgery* **145** 226–232. (<https://doi.org/10.1001/archsurg.2009.292>)
- Zhang HY, Rumilla KM, Jin L, Nakamura N, Stilling GA, Ruebel KH, Hobday TJ, Erlichman C, Erickson LA & Lloyd RV 2006 Association of DNA methylation and epigenetic inactivation of RASSF1A and beta-catenin with metastasis in small bowel carcinoid tumors. *Endocrine* **30** 299–306. (<https://doi.org/10.1007/s12020-006-0008-1>)

Received in final form 6 May 2022

Accepted 17 May 2022

Accepted Manuscript published online 17 May 2022