



## Research Letter

# Imatinib-related hyperpigmentation of oral mucosa: Case report and literature review



Oral mucosal hyperpigmentation (OMH) is a common clinical finding presenting with focal or diffuse pattern, ranging from blue to brown-grey. OMH may be physiological or due to exogenous or endogenous factors, or even associated with systemic diseases.<sup>1</sup> A less common cause of melanotic pigmentation is the use of certain drugs, such as Imatinib.

Imatinib mesylate is a tyrosine kinase (TK) inhibitor which specifically targets TK encoded by the BCR-ABL, c-kit, and PDGF-R $\beta$  oncogenes.<sup>2</sup> BCR-ABL inhibition reduces cell proliferation and increases apoptosis in hematologic malignant cells. Whereas, anti c-kit activity of Imatinib inhibit cell proliferation in gastrointestinal stromal tumor. In 2003, Imatinib was recommended as first line medication for the management of chronic myeloid leukemia (CML). The treatment is well tolerated with low incidence of severe side effects. The most recurrent side effects include nausea and vomiting, diarrhea, headache, and lichenoid eruptions. Skin hypopigmentation is quite frequent, although hyperpigmentation has also been described. Conversely, intraoral side effects seem to be rare, with few cases of oral lichenoid reactions and OMH reported in literature.<sup>2</sup> The aim of this article is to present an unusual case of OMH of the hard palate due to Imatinib and to perform a literature review of this side effect.

In May of 2016, a 78-year-old man was referred to the dental clinic of Marche Polytechnic University, Ancona, Italy, by his general dental practitioner for evaluation of a painless OMH in the hard palate.

His medical history was significant for CML, diagnosed 4 years before. The patient has been treated with Imatinib (Gleevec®, Novartis, Switzerland) 400 mg daily for 4 years. No other drugs were reported in the past 2 years. He was a non-smoker and occasionally consume alcohol. The lesion had initially been observed by his dentist 10 months before.

Oral examination showed a diffuse symmetrical bluish pigmentation of the hard palate, with several inflamed minor salivary glands in the same area (Fig. 1A). Mucosal appearance, except for the color, was unchanged, and no other areas of hyperpigmentation on the oral mucosa, skin,

or fingernails were found. Based on recent blood tests and medical history, no specific cause for OMH was found. For this reason, an incisional biopsy was performed. Histological examination showed accumulation of 2–4  $\mu$ m brown, spherical bodies, located within the cells of the lamina propria. There was no melanocytic hyperplasia or melanosis of the basal cells in the epithelium (Fig. 1B).

Based on clinicopathological findings, a diagnosis of Imatinib-related OMH was made. The lesion was asymptomatic and, since it occurred on the hard-palate, there were no aesthetic problems. Therefore, the patient was reassured, and no treatment was deemed necessary.

Pigmentation of the oral mucosa may indicate a wide range of local lesions or conditions, including physiological pigmentation, melanotic macules, blue nevi, oral malignant melanoma, melanoacanthoma, tobacco-associated and post-inflammatory hyperpigmentation.<sup>1,3,4</sup>

Even exogenous pigments can be associated with pigmentations, such as amalgam tattoo. This is an iatrogenic displacement of metal particles in oral mucosa, characterized by solitary or multiple blue or grey-black lesions, ranging from 0.1 to 2 cm.<sup>1</sup>

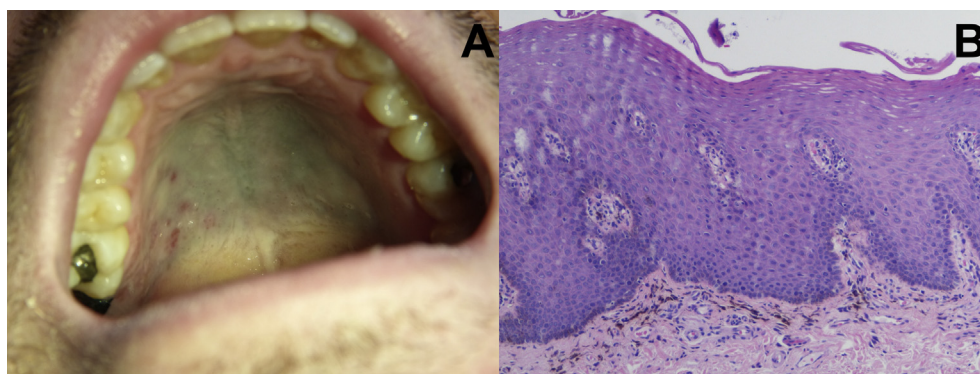
Pigmentation associated with systemic disease occurs as Café au lait macules or diffuse pigmentation involving mucosa and skin, due to an increase in melanin pigment within the basal cell layer.<sup>5</sup> OMH have been reported in hyperthyroidism, Peutz-Jeghers syndrome, Addison disease, Neurofibromatosis type 1, and other syndromes.<sup>1</sup>

Finally, drugs such as quinidine, minocycline, and oral contraceptives may cause oral pigmentation through direct deposition on oral surfaces, local accumulation, stimulation of melanin-related pathways, and bacterial metabolism.<sup>1</sup> Imatinib-related OMH is a rare event, and the present case is consistent with all previous case reports of OMH in patients taking Imatinib (Table 1).<sup>2</sup>

Of the 27 case reports found in literature (including the present case), 24 involved hard palate and only 3 cases were localized in gingiva. The age range was 13–72 years (mean age  $53.8 \pm 14.7$  years), without any sex preference.

<https://doi.org/10.1016/j.jds.2019.02.005>

1991-7902/© 2019 Association for Dental Sciences of the Republic of China. Publishing services by Elsevier B.V. This is an open access article under the CC BY-NC-ND license (<http://creativecommons.org/licenses/by-nc-nd/4.0/>).



**Figure 1** Palatal mucosa showing bluish diffuse hyperpigmentation (A). Accumulation of fine, brown, spherical and fusiform bodies within lamina propria (Haematoxylin-Eosin; x 200) (B).

23 patients suffered from CML, while the other 3 patients received Imatinib for other diseases.<sup>3,6</sup> Most of the patients showed a long-term use of Imatinib (mean  $6.6 \pm 4.2$  years, range 3 months–15 years).

The colours of OMH ranged from blue to grey-brown. Histopathological examination was made in 17 patients; all mucosal biopsies were performed in hard palate, revealing deposits of melanin and/or hemosiderin in the lamina propria. Since patients were always asymptomatic and

physicians do not routinely perform oral inspection, we hypothesize that this phenomenon is under-reported.

The molecular basis of Imatinib-related mucosal changes is not understood. It has been suggested an excessive melanin deposition through the stimulation of c-kit, which is normally expressed in several cell populations. The stimulation of c-kit leads to the transactivation of the tyrosinase pigmentation gene promoter in melanocytes, through the phosphorylation of Erk-2 protein. Therefore,

**Table 1** Cases of Imatinib-related OMH reported in literature.

Authors (year)	cases	age	sex	medical history	Imatinib (mg/day)	therapy (years)	oral sites	colour	biopsy
Singh and Bakhshi (2007)	1	13	W	CML	300	4	Gingivae	Bl-Bk	No
Lewis (2009)	1	70	M	CML	800	3	Palate	Gr	Yes
McPherson et al. (2009)	1	59	W	CML	—	6	Gingivae	Bl-Bk	No
Mattsson et al. (2011)	1	66	W	GIST	400	6	Palate	Bl-Br	Yes
	2	66	W	CML	400	6	Palate	Bl-Br	Yes
	3	64	W	CML	400	6	Palate	Bl-Br	No
Resende et al. (2012)	1	38	M	PHSCT	600	5	Palate	Bl	No
Wong et al. (2011)	1	43	W	CML	—	0.25	Palate	Gr	Yes
Steele et al. (2012)	1	48	M	CML	400	9	Palate	Gr	Yes
Yu et al. (2012)	1	42	M	CML	—	3	Palate	Gr-Br	Yes
Li et al. (2012)	1	29	W	PF	400	4	Palate	Bl-Bk	Yes
	2	53	M	CML	400	10	Palate	Bl-Gr	Yes
	3	64	M	CML	400	4	Palate	Bl-Gr	Yes
Khoo et al. (2013)	1	58	W	CML	400	5	Palate	Gr-purple	No
Hindocha and Clark (2014)	1	—	—	—	—	—	Palate	—	—
Song and Kang (2014)	1	58	M	CML	—	—	Palate	Gr	No
Roeker and Wolanskyj (2014)	1	65	W	CML	—	6	Palate	Bl	No
Agrawal et al. (2015)	1	32	W	CML	400	0.5	Teeth	Br	No
Lyne et al. (2015)	1	58	W	CML	400–600	13	Palate	Bl-Gr	Yes
Romeo et al. (2015)	1	72	W	CML	400	11	Palate	Bl-Gr	Yes
Shi et al. (2017)	1	—	—	CML	—	—	Palate	Bl-Gr	Yes
	2	—	—	CML	—	—	Palate	Bl-Gr	Yes
Bombeccari et al. (2017)	1	63	M	CML	400	9	Palate	Bl-Gr	Yes
Dixon and Yassin (2017)	1	57	M	CML	400	15	Palate	Bl-Gr	No
Di Tullio et al. (2018)	1	47	M	CML	400–800	14	Palate	Bl-Gr	Yes
Tosios et al. (2018)	1	61	M	CML	400	11	Palate	Gr-Bk	Yes
Present case	1	66	M	CML	400	4	Palate	Bl	Yes

CML: chronic myeloid leukemia; GIST: gastrointestinal stromal tumor; PHSCT: post-hematopoietic stem cell transplantation; Bl: blue; Br: brown; Bk: black; Gr: grey.

while c-kit inhibition induced by Imatinib on melanocytes can frequently lead to hypopigmentation, the pathogenetic mechanism of hyperpigmentation is still unknown. Furthermore, it is unclear why the mucosa of the hard palate is invariably affected by hyperpigmentation. It could be due to the large number of melanocytes contained in this tissue, in which Imatinib metabolites accumulate, or could be the wide expression of c-kit in the mesenchymal cells of oral cavity.<sup>3</sup>

Alexandrescu et al. hypothesized that Imatinib exacerbated genetic predisposition to hyperpigmentation that may be related to a c-kit mutation, which is activated rather than being inhibited by this drug.<sup>4</sup> Another theory suggests that Imatinib has a direct effect on melanocytes, but individual genetic or other factors are also requested for the development of pigmentation.<sup>5</sup> Instead, Li et al. supposed that hyperpigmentation might be correlated with the deposition of a drug-metabolite that may chelate melanin and iron, in a similar way to minocycline and antimalarial drugs.<sup>3</sup> However, further studies are required to clarify the accurate pathogenesis of OMH and the paradoxical stimulation of melanocytes induced by Imatinib.

### Conflicts of interest statement

The authors have no conflict of interest to declare. This research did not receive any specific grant from funding agencies in the public, commercial, or not-for-profit sectors.

### Appendix A. Supplementary data

Supplementary data to this article can be found online at <https://doi.org/10.1016/j.jds.2019.02.005>.

### References

1. Meleti M, Vescovi P, Mooi WJ, van der Waal I. Pigmented lesions of the oral mucosa and perioral tissues: a flow-chart for the diagnosis and some recommendations for the management. *Oral Surg Oral Med Oral Pathol Oral Radiol Endod* 2008;105:606–16.
2. Arora B, Kumar L, Sharma A, Wadhwa J, Kochupillai V. Pigmentary changes in chronic myeloid leukemia patients treated with imatinib mesylate. *Ann Oncol* 2004;15:358–9.
3. Li CC, Malik SM, Blaese BF, et al. Mucosal pigmentation caused by imatinib: report of three cases. *Head Neck Pathol* 2012;6:290–5.
4. Mascitti M, Santarelli A, Sartini D, et al. Analysis of nicotinamide N-methyltransferase in oral malignant melanoma and potential prognostic significance. *Melanoma Res* 2019;29:151–6.
5. Mattsson U, Halbritter S, Mörner Serikoff E, Christerson L, Warfvinge G. Oral pigmentation in the hard palate associated with imatinib mesylate therapy: a report of three cases. *Oral Surg Oral Med Oral Pathol Oral Radiol Endod* 2011;111:e12–6.
6. Alexandrescu DT, Dasanu CA, Farzanmehr H, Kauffman L. Persistent cutaneous hyperpigmentation after tyrosine kinase inhibition with imatinib for GIST. *Dermatol Online J* 2008;14. Available from: <https://escholarship.org/uc/item/472203p2>. [Accessed 18 January 2019].

Marco Mascitti\*

Elisa Luconi

Lucrezia Togni

*Department of Clinical Specialistic and Dental Sciences,  
Marche Polytechnic University, Ancona, Italy*

Alberta Barlattani

*Department of Clinical Sciences and Translational Medicine  
University of Rome "Tor Vergata", Rome, Italy*

Andrea Santarelli

*Department of Clinical Specialistic and Dental Sciences,  
Marche Polytechnic University, Ancona, Italy  
National Institute of Health and Science of Aging, INRCA,  
Ancona, Italy*

\*Corresponding author. Via Tronto 10, 60126, Ancona, Italy.

Fax: +39 071 2206221.

E-mail address: [marcomascitti86@hotmail.it](mailto:marcomascitti86@hotmail.it) (M. Mascitti)

Received 24 January 2019

Final revision received 28 January 2019

Available online 17 April 2019