

## Original Article

# Radiological anatomy of the C7 vertebra: Clinical implications in spine surgery

Fatih Keskin, Fatih Erdi, Alaaddin Nayman<sup>1</sup>, Ozan Babaoglu<sup>2</sup>, Kalkan Erdal, Ali Fahir Ozer<sup>3</sup>

Departments of Neurosurgery and <sup>2</sup>Radiology, Necmettin Erbakan University, Meram Faculty of Medicine, <sup>1</sup>Department of Radiology, Selcuk University, Faculty of Medicine, <sup>3</sup>Department of Neurosurgery, Koc University, Faculty of Medicine, Akyokus, Meram, Konya, Turkey

Corresponding author: Dr. Fatih Keskin, Department of Neurosurgery, Necmettin Erbakan University, Meram Faculty of Medicine, Akyokus/Meram, Konya, Turkey. E-mail: drfatihk@yahoo.com

Journal of Craniovertebral Junction and Spine 2015, 6:8

## Abstract

**Context:** This study was designed to understand and define the special radio-anatomic morphometry of C7 vertebra by using multidetector computed tomography (MDCT). **Aims:** The major aim of the study was to detect the gender- and side-related morphometric differences of C7 vertebra among subjects. **Setting and design:** Our radiology unit database scanned for MDCT sections of the C7 vertebra. **Materials and Methods:** A total of 214 patients (134 men, 80 women) were selected. A detailed morphometric evaluation of C7 was done. **Statistical analysis used:** T test, ANOVA. Lamina length ( $P < 0.001$ ), pedicle length ( $P < 0.001$ ), outer cortical ( $P = 0.01$ ) and inner cancellous pedicle ( $P < 0.001$ ) width, pedicle angle to sagittal plane ( $P < 0.001$ ) values were statistically significantly different on the right versus left side. When the results were stratified by gender, lamina length, inner cancellous lamina height, pedicle length, inner cancellous pedicle height, outer cortical pedicle width, lateral mass anteroposterior length, anteroposterior length of C7 corpus, height of C7 corpus ( $P < 0.001$ ), C6-7 ( $P = 0.013$ ) and C7-T1 disc height ( $P = 0.04$ ), transverse foramina perpendicular width at C7 ( $P = 0.046$ ) values were found to be statistically significantly different. Vertebral artery most commonly enters into the transverse foramina at C6 level. **Conclusions:** Gender and side differences are important factors for preoperative planning and showed significant differences among subjects. MDCT is a practical option for investigating the exact anatomical features of osseous structures.

**Key words:** C7 vertebra, gender, morphometry, multidetector computed tomography, side

## INTRODUCTION

While C7 vertebra is anatomically very similar to thoracic vertebra, the cervicothoracic junction presents numerous challenges to the spine surgeon in operation settings. The transition from the mobile, lordotic cervical spine to the fixed, kyphotic, thoracic segment,<sup>[1]</sup> Relative lack of epidural space and

the increased medial angulation needed for pedicle cannulation at C7 and important adjacent neural and vascular structures at these levels make surgical intervention more challenging and potentially hazardous.<sup>[2]</sup>

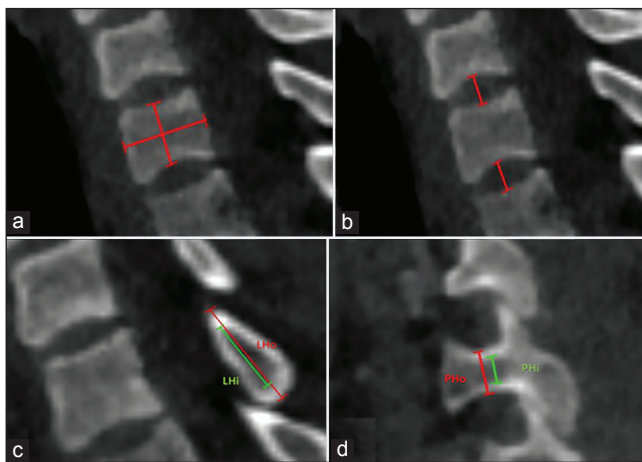
In daily spinal surgery practice, adequate interpretation of the data provided from computed tomography (CT) imaging is very crucial to visualize the relevant bone anatomy and make correct decisions. This situation is especially valid in the C7 vertebra, where morphometric measurements are vital factors that may limit surgical success. In this study, we used multidetector computed tomography (MDCT) imaging of randomly selected adult patients to define the anatomic morphometry of C7 vertebra. We compare our findings based on gender and side differences (right versus left) of C7 vertebra.

Access this article online	
Quick Response Code:	Website: <a href="http://www.jcvjs.com">www.jcvjs.com</a>
	DOI: 10.4103/0974-8237.151590

## MATERIALS AND METHODS

A total of 214 cervical spine MDCT scans (in 134 men and 80 women) were included in this study. After the Institutional Review Board approval, patients were randomly selected for study enrollment via a retrospective review of our hospital's radiology unit database. All patients were older than 20 years of age at the time of admission. All patients had undergone standardized axial bone-window CT scanning at C7 in a supine neutral position. Patients with CT scan evidence of bony or ligamentous injury, deformity, intraosseous pathology (e.g., tumor or infection), or advanced degenerative changes with disc space collapse and extensive spondylosis were excluded. All MDCT scans were carried out with a dual-source CT scanner, which has two X-ray tubes located at 95-degree angle and 128-channel two-detector row (Somatom Definition Flash, Siemens Healthcare Forchheim, Germany) in our center. CT acquisition parameters were as follows: Slice collimation 3 mm × 128 × 0.6 mm with a z-flying focal spot; gantry rotation time 500 ms; 100 kV and 65 mAs. Images were reconstructed with 1 mm slice thickness and 1 mm increment using a medium smooth tissue iterative reconstruction kernel (I26f).

All measurements were performed bilaterally. Lamina length, outer cortical and inner cancellous lamina height and lamina width, pedicle length to anterior vertebral body cortex, outer cortical and inner cancellous pedicle height and width, lateral mass anteroposterior length, C7 corpus anteroposterior length, C7 corpus height, C6-7 and C7-T1 disc heights were measured and recorded. Pedicle and lamina angle to sagittal plane were measured and recorded. The level of vertebral artery entrance into the transverse foramen and the presence of transverse foramina at C7 were determined. The transverse foramina maximal width and its perpendicular width if exists at C7 were measured [Figures 1-3].



**Figure 1:** a-d Sagittal MDCT scan at C7 showing measurement of vertebral corpus anteroposterior length and corpus height (a), C6-7 and C7-T1 disc height (b), inner cancellous (LHi) and outer cortical (LHo) lamina height (c), inner cancellous (PHi) and outer cortical (PHo) pedicle height of corresponding vertebra. MDCT: Multidetector computed tomography

## Statistical analyses

Statistical analysis was performed using SPSS 16.0 software package (SPSS, Chicago, IL). All continuous variables that measured only once per subject (C6-7 and C7-1 disc height, C7 corpus anteroposterior length, C7 corpus height, etc.) were analyzed with t test. Other variables that were stratified by side were analyzed with Two-Way Repeated Measures ANOVA. We analyzed the gender and side differences as main factors and observed the interactions between the parameters. Significance level was set to be 0.05.

## RESULTS

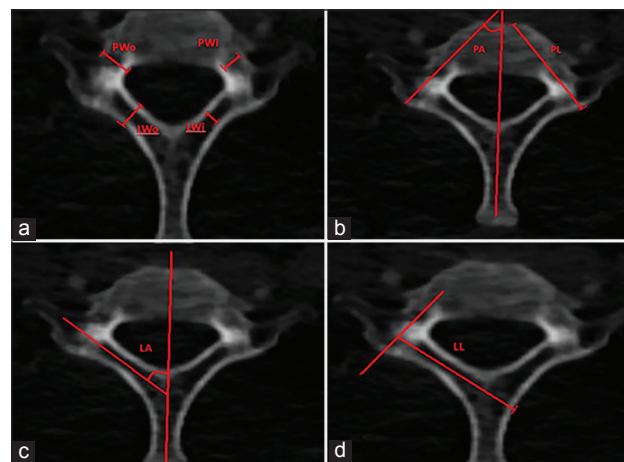
The results were presented as mean ± standard deviation (SD).

### Patient demographic data

The mean ± SD patient age was 37.60 ± 7.60 years (range, 20-49 years) in females and 34.21 ± 8.84 years (range, 20-50 years) in male patients. All patients were skeletally mature Turkish adults. There were 80 female and 134 male patients.

### Lamina length, outer cortical and inner cancellous lamina height, and outer cortical and inner cancellous lamina width

In female patients, the mean ± SD lamina length of C7 was 28.71 ± 2.03 mm at right side and 28.51 ± 2.15 mm at left side. In male patients, the mean ± SD lamina length of C7 was 31.34 ± 2.38 mm at right side and 30.61 ± 2.45 mm at left side [Table 1 and Figure 2d]. When the results were stratified by side, there was a statistically significant difference in lamina length on the right versus left side ( $P < 0.001$ ). There was a statistically significant difference in the lamina length based on gender ( $P < 0.001$ ).



**Figure 2:** Axial MDCT scan at C7 showing measurement of outer cortical (LWo) and inner cancellous (LWi) lamina width and outer cortical (PWo) and inner cancellous (PWi) pedicle width (a), pedicle length to anterior vertebral corpus (PL), pedicle angle to sagittal plane (PA) (b), Lamina angle to sagittal plane (LA) (c) and lamina length (LL) (d) of corresponding vertebra. MDCT: Multidetector computed tomography

In female patients, the mean  $\pm$  SD outer cortical lamina height of C7 was  $17.73 \pm 1.83$  mm at right side and  $17.52 \pm 1.66$  mm at left side. In male patients, the mean  $\pm$  SD outer cortical lamina height of C7 was  $19.57 \pm 1.90$  mm at right side and  $19.55 \pm 1.99$  mm at left side [Table 1 and Figure 1c]. When the results were stratified by side, there was no statistically significant difference in outer cortical lamina height on the right versus the left side ( $P = 0.293$ ). There was a statistically significant difference in the outer cortical lamina height based on gender ( $P < 0.001$ ).

In female patients, the mean  $\pm$  SD inner cancellous lamina height of C7 was  $11.51 \pm 1.66$  mm at right side and  $11.28 \pm 1.72$  mm at left side. In male patients, the mean  $\pm$  SD inner cancellous lamina height of C7 was  $13.26 \pm 2.04$  mm at right side and  $13.37 \pm 2.15$  mm at left side [Table 1 and Figure 1c]. When the results were stratified by side, there was no statistically significant difference in inner cancellous lamina height on the right versus left side ( $P = 0.575$ ). There was statistically significant difference in the inner cancellous lamina height based on gender ( $P < 0.001$ ).

In female patients, the mean  $\pm$  SD outer cortical lamina width of C7 was  $5.81 \pm 1.05$  mm at right side and  $5.98 \pm 1.11$  mm at left

side. In male patients, the mean  $\pm$  SD outer cortical lamina width of C7 was  $6.39 \pm 1.24$  mm at right side and  $6.43 \pm 1.16$  mm at left side [Table 1 and Figure 2a]. When the results were stratified by side, there was no statistically significant difference in outer cortical lamina width on the right versus left side ( $P = 0.052$ ). There was a statistically significant difference in the outer cortical lamina width based on gender ( $P = 0.001$ ).

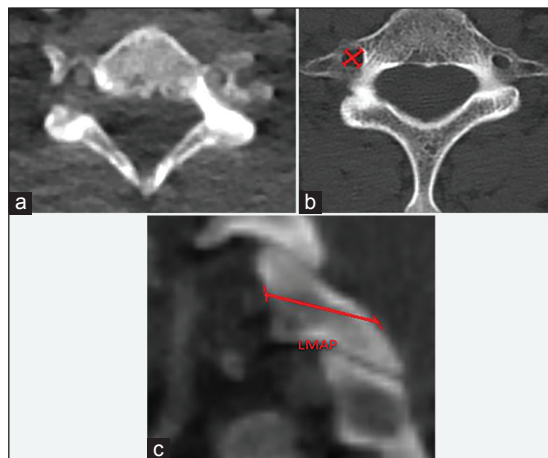
In female patients, the mean  $\pm$  SD inner cancellous lamina width of C7 was  $3.03 \pm 0.84$  mm at right side and  $3.10 \pm 0.90$  mm at left side. In male patients, the mean  $\pm$  SD inner cancellous lamina width of C7 was  $3.59 \pm 1.02$  mm at right side and  $3.43 \pm 0.93$  mm at left side [Table 1 and Figure 2a]. When the results were stratified by side, there was no statistically significant difference in inner cancellous lamina width on the right versus left side ( $P = 0.263$ ). There was a statistically significant difference in the inner cancellous lamina width based on gender ( $P < 0.001$ ).

### Pedicle length, outer cortical and inner cancellous pedicle height, and outer cortical and inner cancellous pedicle width

In female patients, the mean  $\pm$  SD pedicle length of C7 was  $31.52 \pm 2.73$  mm at right side and  $30.60 \pm 2.32$  mm at left side. In male patients, the mean  $\pm$  SD pedicle length of C7 was  $34.76 \pm 2.48$  mm at right side and  $33.25 \pm 2.58$  mm at left side [Table 2 and Figure 2b]. When the results were stratified by side, there was statistically significant difference in pedicle length on the right versus left side ( $P < 0.001$ ). There was a statistically significant difference in the pedicle length based on gender ( $P < 0.001$ ).

In female patients, the mean  $\pm$  SD outer cortical pedicle height of C7 was  $6.74 \pm 0.78$  mm at right side and  $6.70 \pm 0.75$  mm at left side. In male patients, the mean  $\pm$  SD outer cortical pedicle height of C7 was  $7.78 \pm 0.83$  mm at right side and  $7.72 \pm 0.92$  mm at left side [Table 2 and Figure 1d]. When the results were stratified by side, there was no statistically significant difference on the right versus left side ( $P = 0.339$ ). There was a statistically significant difference in the outer cortical pedicle height based on gender ( $P < 0.001$ ).

In female patients, the mean  $\pm$  SD inner cancellous pedicle height of C7 was  $3.36 \pm 0.58$  mm at right side and  $3.48 \pm 0.55$  mm



**Figure 3:** Axial MDCT scan at C7 showing the vertebral artery entry (a), C7 transverse foramina maximal diameter and its perpendicular diameter (b), Sagittal MDCT scan showed lateral mass anteroposterior length (c)

**Table 1: Lamina length, outer cortical and inner cancellous lamina height and outer cortical and inner cancellous lamina width**

Sex	Right lamina length (mm)	Right outer cortical lamina height (mm)	Right outer cortical lamina width (mm)	Right inner cancellous lamina height (mm)	Right inner cancellous lamina width (mm)
Female	28.71 $\pm$ 2.03	17.73 $\pm$ 1.83	5.81 $\pm$ 1.05	11.51 $\pm$ 1.66	3.03 $\pm$ 0.84
Male	31.34 $\pm$ 2.38	19.57 $\pm$ 1.90	6.39 $\pm$ 1.24	13.26 $\pm$ 2.04	3.59 $\pm$ 1.02
	Left lamina length	Left outer cortical lamina height	Left outer cortical lamina width	Left inner cancellous lamina height	Left inner cancellous lamina width
Female	28.51 $\pm$ 2.15	17.52 $\pm$ 1.66	5.98 $\pm$ 1.11	11.28 $\pm$ 1.72	3.10 $\pm$ 0.90
Male	30.61 $\pm$ 2.45	19.55 $\pm$ 1.99	6.43 $\pm$ 1.16	13.37 $\pm$ 2.15	3.43 $\pm$ 0.93

All values were presented as mean  $\pm$  SD

at left side. In male patients, the mean ± SD inner cancellous pedicle height of C7 was 4.24 ± 0.75 mm at right side and 4.41 ± 1.36 mm at left side [Table 2 and Figure 1d]. When the results were stratified by side, there was no statistically significant difference on the right versus left side (*P* = 0.055). There was a statistically significant difference based on gender (*P* < 0.001).

In female patients, the mean ± SD outer cortical pedicle width of C7 was 6.56 ± 0.83 mm at right side and 6.42 ± 0.83 mm at left side. In male patients, the mean ± SD outer cortical pedicle width of C7 was 7.16 ± 1.10 mm at right side and 6.99 ± 1.12 mm at left side [Table 2 and Figure 2a]. When the results were stratified by side, there was statistically significant difference in outer cortical pedicle width on the right versus left side (*P* = 0.01). There was a statistically significant difference based on gender (*P* < 0.001).

In female patients, the mean ± SD inner cancellous pedicle width of C7 was 3.47 ± 0.72 mm at right side and 3.67 ± 0.77 mm at left side. In male patients, the mean ± SD inner cancellous pedicle width of C7 was 4.16 ± 0.95 mm at right side and 4.38 ± 1.07 mm. at left side [Table 2 and Figure 2a]. When the results were stratified by side, there was statistically significant difference in inner cancellous pedicle width on the right versus left side (*P* < 0.001). There was a statistically significant difference based on gender (*P* < 0.001).

### Lateral mass anteroposterior length

In female patients, the mean ± SD lateral mass anteroposterior length of C7 was 10.05 ± 1.37 mm at right side and 10.10 ± 1.23 mm at left side. In male patients, the mean ± SD lateral mass anteroposterior length of C7 was 11.09 ± 1.57 mm at right side and 11.23 ± 1.56 mm at left side [Table 3 and Figure 3c]. When the results were stratified by side, there was no statistically significant difference in lateral mass anteroposterior length on the right versus left side (*P* = 0.38). There was a statistically significant difference in the lateral mass anteroposterior length based on gender (*P* < 0.001).

### C7 corpus anteroposterior length and height

In female patients, the mean ± SD anteroposterior length of C7 corpus was 15.42 ± 1.42 mm. In male patients, the mean ± SD anteroposterior length of C7 corpus was 16.99 ± 1.60 mm

[Table 4 and Figure 1a]. There was a statistically significant difference based on gender (*P* < 0.001).

In female patients, the mean ± SD height of C7 corpus was 12.44 ± 0.96 mm. In male patients, the mean ± SD height of C7 corpus was 14.27 ± 1.29 mm [Table 4 and Figure 1a]. There was a statistically significant difference based on gender (*P* < 0.001).

### C6-7 and C7-T1 disc heights

In female patients, the mean ± SD C6-7 disc height was 4.93 ± 0.74 mm. In male patients, the mean ± SD C6-7 disc height was 5.19 ± 0.74 mm [Table 5 and Figure 1b]. There was statistically significant difference based on gender (*P* = 0.013).

In female patients, the mean ± SD C7-T1 disc height was 4.51 ± 0.68 mm. In male patients, the mean ± SD C7-T1 disc height was 4.72 ± 0.74 mm [Table 5 and Figure 1b]. There was a statistically significant difference based on gender (*P* = 0.04).

### Pedicle and lamina angle to sagittal plane

In female patients, the mean ± SD pedicle angle to sagittal plane was 38.44 ± 4.0° in right and 37.20 ± 5.11° in left. In male patients, the mean ± SD pedicle angle to sagittal plane was 38.40 ± 4.18° in right and 36.56 ± 5.42° in left pedicle [Table 6 and Figure 2b]. When the results were stratified by side, there was a statistically significant difference on the right versus left side (*P* < 0.001). There was no statistically significant difference based on gender (*P* = 0.55).

In female patients, the mean ± SD lamina angle to sagittal plane was 50.15 ± 3.83° in right and 49.28 ± 3.89° in left. In male patients, the mean ± SD lamina angle to sagittal plane was 48.87 ± 4.79° in right and 48.58 ± 4.54° in left lamina [Table 6 and Figure 2c]. When the results were stratified by side, there was no statistically significant difference on the right versus left side (*P* = 0.09). There was no statistically significant difference based on gender (*P* = 0.56).

### The transverse foramina maximal width and its perpendicular width at C7

In female patients, the mean ± SD transverse foramina maximal width was 5.70 ± 1.70 mm in right and 5.45 ± 1.87 mm in left. In male patients, the mean ± SD transverse foramina maximal width was 5.69 ± 1.95 mm in right and 5.93 ± 2.03 mm in left

**Table 2: Pedicle length, outer cortical and inner cancellous pedicle height and outer cortical and inner cancellous pedicle width**

Sex	Right pedicle length (mm)	Right outer cortical pedicle height (mm)	Right outer cortical pedicle width (mm)	Right inner cancellous pedicle height (mm)	Right inner cancellous pedicle width (mm)
Female	31.52±2.73	6.74±0.78	6.56±0.83	3.36±0.58	3.47± 0.72
Male	34.76±2.48	7.78±0.83	7.16±1.10	4.24±0.75	4.16±0.95
	Left pedicle length (mm)	Left outer cortical pedicle height (mm)	Left outer cortical pedicle width (mm)	Left inner cancellous pedicle height (mm)	Left inner cancellous pedicle width (mm)
Female	30.60±2.32	6.70±0.75	6.42±0.83	3.48±0.55	3.67±0.77
Male	33.25±2.58	7.72±0.92	6.99±1.12	4.41±1.36	4.38±1.07

All values were presented as mean ± SD

[Table 7 and Figure 3b]. When the results were stratified by side, there was no statistically significant difference on the right versus left side ( $P = 0.975$ ). There was no statistically significant difference based on gender ( $P = 0.315$ ).

In female patients, the mean  $\pm$  SD transverse foramina perpendicular width at C7 was  $4.03 \pm 1.18$  mm in right and  $3.76 \pm 1.15$  mm in left. In male patients, the mean  $\pm$  SD transverse foramina perpendicular width at C7 was  $4.19 \pm 1.35$  mm in right and  $4.22 \pm 1.38$  mm in left [Table 7 and Figure 3b]. When the results were stratified by side, there was no statistically significant difference on the right versus left side ( $P = 0.231$ ). There was a statistically significant difference based on gender ( $P = 0.046$ ).

**Table 3: Lateral mass anteroposterior length**

Sex	Right lateral mass anteroposterior length (mm)	Left lateral mass anteroposterior length (mm)
Female	10.05 $\pm$ 1.37	10.10 $\pm$ 1.23
Male	11.09 $\pm$ 1.57	11.23 $\pm$ 1.56

All values were presented as mean  $\pm$  SD

**Table 4: C7 corpus anteroposterior length and height**

Sex	C7 corpus anteroposterior length (mm)	C7 corpus height (mm)
Female	15.42 $\pm$ 1.42	12.44 $\pm$ 0.96
Male	16.99 $\pm$ 1.60	14.27 $\pm$ 1.29

All values were presented as mean  $\pm$  SD.

**Table 5: C6-7 and C7-T1 disc heights**

Sex	C6-7 disc height (mm)	C7-T1 disc height (mm)
Female	4.93 $\pm$ 0.74	4.51 $\pm$ 0.68
Male	5.19 $\pm$ 0.74	4.72 $\pm$ 0.74

All values were presented as mean  $\pm$  SD.

**Table 6: Pedicle and lamina angle to sagittal plane**

Sex	Right pedicle angle to sagittal plane $^{\circ}$	Left pedicle angle to sagittal plane $^{\circ}$	Right lamina angle to sagittal plane $^{\circ}$	Left lamina angle to sagittal plane $^{\circ}$
Female	38.44 $\pm$ 4.0 $^{\circ}$	37.20 $\pm$ 5.11 $^{\circ}$	50.15 $\pm$ 3.83 $^{\circ}$	49.28 $\pm$ 3.89 $^{\circ}$
Male	38.40 $\pm$ 4.18 $^{\circ}$	36.56 $\pm$ 5.42 $^{\circ}$	48.87 $\pm$ 4.79 $^{\circ}$	48.58 $\pm$ 4.54 $^{\circ}$

All values were presented as mean  $\pm$  SD

**Table 7: The transverse foramina maximal width and its perpendicular width at C7**

Sex	Right transverse foramina maximal width (mm)	Left transverse foramina maximal width (mm)	Right transverse foramina perpendicular width (mm)	Left transverse foramina perpendicular width (mm)
Female	5.70 $\pm$ 1.70	5.45 $\pm$ 1.87	4.03 $\pm$ 1.18	3.76 $\pm$ 1.15
Male	5.69 $\pm$ 1.95	5.93 $\pm$ 2.03	4.19 $\pm$ 1.35	4.22 $\pm$ 1.38 mm

All values were presented as mean  $\pm$  SD.

### The presence of transverse foramina at C7 and the level of vertebral artery entrance into the transverse foramen

The right C7 transverse foramina were found in 77 (96.3%) female patients and 132 male (98.5%) patients. The left C7 transverse foramina were found in 79 (98.8%) female patients and 132 male (98.5%) patients.

In female patients the right vertebral artery enters into the transverse foramen at C3 in one patient (1.3%), at C4 in one patient (1.3%), at C5 in two patients (2.5%), at C6 in 76 patients (95%). The left vertebral artery enters into the transverse foramen at C4 in one patient (1.3%), at C5 in three patients (3.8%), at C6 in 74 patients (92.4%), and C7 in two patients (2.5%) [Table 8 and Figure 3a].

In male patients the right vertebral artery enters into the transverse foramen at C4 in one patient (0.7%), at C5 in seven patients (5.2%), at C6 in 124 patients (92.5%), and at C7 in 2 patients (1.5%). The left vertebral artery enters into the transverse foramen at C4 in one patient (0.7%), at C5 in 10 patients (7.5%), at C6 in 117 patients (87.3%), and at C7 in six patients (4.5%) [Table 8 and Figure 3a].

### DISCUSSION

In daily surgical practice, sufficient knowledge of anatomy in the region of interest and appropriate surgical technique may keep the surgeon away from undesirable complications. This rule is especially valid in the cervicothoracic junction (CTJ) due to complicated structure and different architecture of the region.<sup>[2-4]</sup>

Our patient group consisted of skeletally mature young adults. In this age group, C7 vertebra could injure especially in serious unstable traumas, neoplastic or infectious lesions.<sup>[5]</sup>

In the treatment of these lesions, different decompression, fixation, and fusion techniques with different type of instrumentation have been previously defined.<sup>[5-8]</sup>

Posterior fixation techniques include pedicle screwing, lateral mass screwing, intralaminar screwing<sup>[2]</sup> and transarticular fixation.<sup>[3]</sup> It has

**Table 8: The level of vertebral artery entrance into the transverse foramen**

Sex	Side	C3 %	C4 %	C5 %	C6 %	C7 %
Female	Right Vertebral Artery	1.3	1.3	2.5	95	
	Left Vertebral Artery		1.3	3.8	92.4	2.5
Male	Right Vertebral Artery		0.7	5.2	92.5	1.5
	Left Vertebral Artery		0.7	7.5	87.3	4.5

All values were presented as percentage (%)

been shown that posterior fixation in CTJ could provide stability in some types of injuries but complex lesions involving the anterior column require a combined anterior/posterior fixation.<sup>[6-8]</sup>

Lamina length, outer cortical and inner cancellous lamina height and lamina width, pedicle length to anterior vertebral body cortex, outer cortical and inner cancellous pedicle height and width, lateral mass anteroposterior length, pedicle and lamina angle to sagittal plane are important factors for posterior fixation. Our findings showed significant variation in lamina length, pedicle length, outer cortical and inner cancellous pedicle width, pedicle angle to sagittal plane based on side differences. In addition lamina length, inner cancellous lamina height, pedicle length, inner cancellous pedicle height, outer cortical pedicle width, lateral mass anteroposterior length at C7 vertebra were found to be significantly different between male and female subjects.

For anterior approaches, we studied anteroposterior length of C7 corpus, height of C7 corpus, and C6-7 and C7-T1 disc height. We also found significant differences between genders in all of these parameters.

The variance of vertebral artery and the anatomical features of the C7 pedicle with or without vertebral artery entry carry great importance for the prevention of serious complications. Vertebral artery can be damaged in an anterior and lateral approach such as corpectomy or foraminotomy, as well as a posterior approach with screwing.<sup>[9]</sup> Right C7 transverse foramina were found in 77 (96.3%) female patients and 132 male (98.5%) patients, while the left C7 transverse foramina were found in 79 (98.8%) female patients and 132 male (98.5%) patients in our series. The right vertebral artery enters into the transverse foramen at C7 in 2 male patients (1.5%) and the left vertebral artery enters into the transverse foramen at C7 in six male patients (4.5%). In female patients the right vertebral artery enters into the transverse

foramen at C7 in none of our patients and the left vertebral artery enters into the transverse foramen at C7 in two patients (2.5%). Vertebral artery enters into the transverse foramen at C6 in 87.3-95% of our patients. Wakao *et al.* reported a 95.6% C6 entry in 1.838 vertebral artery courses in 919 subjects. Our findings were consistent with their findings.<sup>[9]</sup>

## CONCLUSION

In this study, we highlighted the important structures and landmarks, from the radio-anatomic view, which will help us to understand important features and neurovascular relations of the C7 vertebra. The anatomical features of C7 vertebra vary significantly between genders and side of vertebra. These variations should be considered in detail during preoperative planning period.

## REFERENCES

- Ames CP, Bozkus MH, Chamberlain RH, Acosta FL Jr, Papadopoulos SM, Sonntag VK, et al. Biomechanics of stabilization after cervicothoracic compression-flexion injury. *Spine (Phila Pa 1976)* 2005;30:1505-12.
- Jang WY, Kim IS, Lee HJ, Sung JH, Lee SW, Hong JT. A computed tomography-based anatomic comparison of three different types of c7 posterior fixation techniques: Pedicle, intralaminar, and lateral mass screws. *J Korean Neurosurg Soc* 2011;50:166-72.
- Kim K, Isu T, Omura T, Morimoto D, Kobayashi S, Teramoto A. Transarticular fixation with a bioabsorptive screw for cervical spondylolisthesis. *World Neurosurg* 2014;81:843.e5-9.
- Vanek P, Bradac O, Delacy P, Lacman J, Benes V. Anterior interbody fusion of the cervical spine with Zero-P spacer: Prospective comparative study-clinical and radiological results at a minimum 2 years after surgery. *Spine (Phila Pa 1976)* 2013;38:E792-7.
- Ramieri A, Domenicucci M, Ciappetta P, Cellocchio P, Raco A, Costanzo G. Spine surgery in neurological lesions of the cervicothoracic junction: Multicentric experience on 33 consecutive cases. *Eur Spine J* 2011;20:S13-9.
- Fang HS, Ong GB, Hodgson AR. Anterior spinal fusion: The operative approaches. *Clin Orthop Relat Res* 1964;35:16-33.
- Fielding JW, Stillwell WT. Anterior cervical approach to the upper thoracic spine: A case report. *Spine (Phila Pa 1976)* 1976;1:158-61.
- Kreshak JL, Kim DH, Lindsey DP, Kam AC, Panjabi MM, Yerby SA. Posterior stabilization at the cervicothoracic junction. A biomechanical study. *Spine (Phila Pa 1976)* 2002;27:2763-70.
- Wakao N, Takeuchi M, Kamiya M, Aoyama M, Hirasawa A, Sato K, et al. Variance of cervical vertebral artery measured by CT angiography and its influence on C7 pedicle anatomy. *Spine (Phila Pa 1976)* 2014;39:228-32.

**How to cite this article:** Keskin F, Erdi F, Nayman A, Babaoglu O, Erdal K, Ozer AF. Radiological anatomy of the C7 vertebra: Clinical implications in spine surgery. *J Craniovert Jun Spine* 2015;6:30-5.

**Source of Support:** Nil, **Conflict of Interest:** None declared.