

CASE REPORT

Cardiac rhythm abnormalities during intravenous immunoglobulin G (IVIG) infusion in two newborn infants: coincidence or association?

Sinan Tufekci¹, Asuman Coban¹, Meltem Bor¹, Beril Yasa¹, Kemal Nisli² & Zeynep Ince¹

¹Division of Neonatology, Department of Pediatrics, Istanbul Medical Faculty, Istanbul University, Istanbul, Turkey

²Division of Pediatric Cardiology, Department of Pediatrics, Istanbul Medical Faculty, Istanbul University, Istanbul, Turkey

Correspondence

Sinan Tufekci, Department of Pediatrics, Istanbul University, Istanbul Medical Faculty, Newborn Intensive Care Unit, Fatih-Çapa/İstanbul, Turkey. Tel: +905324417882; Fax: +90 212 414 21 96; E-mail: sinantufekci28@hotmail.com

Funding Information

No sources of funding were declared for this study.

Received: 7 March 2015; Accepted: 30 April 2015

Clinical Case Reports 2015; 3(9): 731–734

doi: 10.1002/ccr3.329

Introduction

Supraventricular tachycardia (SVT) during or after intravenous immunoglobulin treatment in newborn infants have not been reported before. In the pediatric age group, Savaşan et al. [1] reported the development of supraventricular tachycardia during IVIG treatment in two 9-year-old boys. We report two newborn patients who developed supraventricular tachycardia during IVIG infusion and discuss the possible mechanisms.

Case Reports

Case 1

Baby D, was a female baby, born at 36^{4/7} weeks of gestation, with a birth weight of 3350 g, by spontaneous vaginal delivery to a 30-year-old, gravida 2, healthy mother. Apgar scores at 1 and 5 min were 9 and 10 and physical examination was normal. The blood group of the mother was ORh (+). The blood group of the baby was B Rh(+), with a hemoglobin level of 17.4 g/dL, hematocrit 52%,

Key Clinical Message

We report the occurrence of supraventricular tachycardia during intravenous immunoglobulin (IVIG) infusion. Supraventricular tachycardia was observed in two newborn patients during IVIG infusion. Both of the babies responded to adenosine treatment. Cardiorespiratory monitoring during IVIG infusion can be recommended because of the possibility of this potentially lifethreatening adverse effect.

Keywords

Cardiac rhythm abnormalities, intravenous immunoglobulin G, newborn.

direct Coombs test (+++), reticulocyte count 6.2%. At the 6th postnatal hour the bilirubin level was 2.8 mg/dL, which corresponded to a pathologic rate of increase (0.46 mg/dL/h). These findings were in accordance with an immune hemolysis due to ABO incompatibility and IVIG infusion was started to be given over 4 h. The patient was monitored during the infusion and 75 min after the start of the treatment, the heart rate suddenly increased to 260 beats/min. The electrocardiography showed narrow QRS supraventricular tachycardia (SVT). After the administration of adenosine 0.1 mg/kg, her heart rate returned to normal (144/min) (Fig. 1). An echocardiography was performed which showed patent foramen ovale and small patent ductus arteriosus. The patient was monitored for 2 days in the NICU and SVT episodes did not recur either during the hospitalization or the outpatient follow-up.

Case 2

Baby U, was a male baby, born at 38^{0/7} weeks of gestation, with a birth weight of 3720 g, to a 29-year-old,

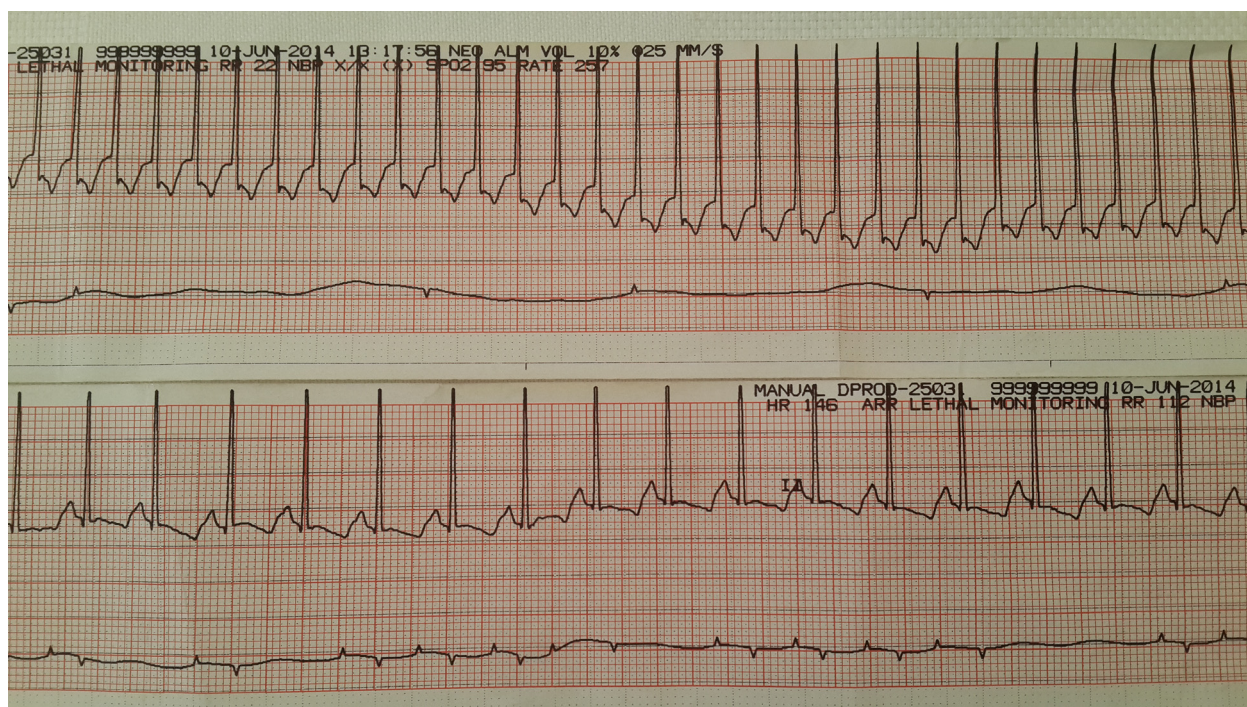


Figure 1. Supraventricular tachycardia during IVIG treatment and normal heart rhythm after the administration of adenosine.

gravida 2, healthy mother. Rh incompatibility and fetal cardiac dysrhythmia, in the form of premature atrial beats with block, had been diagnosed antenatally. Fetal ultrasonography and echocardiography were normal. The baby was born by cesarean section and Apgar scores at 1 and 5 min were 9 and 10. Delivery room examination was normal except I/VI systolic murmur of the heart. The baby was admitted to the NICU and cardiorespiratory monitoring was started because of the antenatal diagnosis. The initial heart rate was 144 beats/min and mean arterial blood pressure was 42 mmHg. Postnatal echocardiography showed patent ductus arteriosus and a small patent foramen ovale. The blood group of the mother was A Rh negative whereas the blood group of the baby was A Rh positive. Indirect Coombs test was reported to be positive at 1/8 dilution and direct Coombs test was (++++), with a reticulocyte count of 6%, hemoglobin 14.7 g/dL, hematocrit 44%. Umbilical cord bilirubin level was 3 mg/dL which increased to 4.1 mg/dL after 2 h which corresponded to a pathologic rate of increase (0.55 mg/dL/h). IVIG infusion was started to be given over 4 h. The patient was monitored during the infusion and 2 h after the start of the treatment the heart rate suddenly increased to 230 beats/min, the ECG showing narrow QRS supraventricular tachycardia. After treatment with 0.1 mg/kg adenosine, his heart rate returned to normal (Fig. 2). On the fifth and eighth days of life, SVT episodes recurred which were responsive to adenosine treat-

ment. The recordings of Holter monitoring also showed intermittent SVT episodes. On the ninth day, an SVT episode unresponsive to adenosine occurred which responded to digoxin and amiodarone treatment. On the 21st day of hospitalization, he was discharged home with amiodarone and digoxin therapy.

Discussion

The American Academy of Pediatrics recommended use of IVIG for hemolytic disease of the fetus and newborn which was associated with a decreased need for exchange transfusion for term and preterm infants with Rh and ABO incompatibility [2]. IVIG is used at a dose up to 1–2 g/kg. Although the mechanism of its action is not completely clear, IVIG is thought to bind to the Fc receptor in the reticuloendothelial system, thus reducing hemolysis and decreasing the rapid rise in bilirubin levels [3]. In our unit we use IVIG infusion for immune hemolysis due to ABO or Rh incompatibility with a dose of 1 g/kg over 4 h.

Adverse reactions are reported in up to 20% of intravenous immune globulin infusions in all age groups. These reactions occur more often when a patient is either receiving IVIG for the first time or changing from one preparation to another [4]. Serious adverse reactions are uncommon, most of them being minor and transient. Common examples include headache and mild, rate-related reactions, such as fever, nausea, vomiting, malaise, chills,

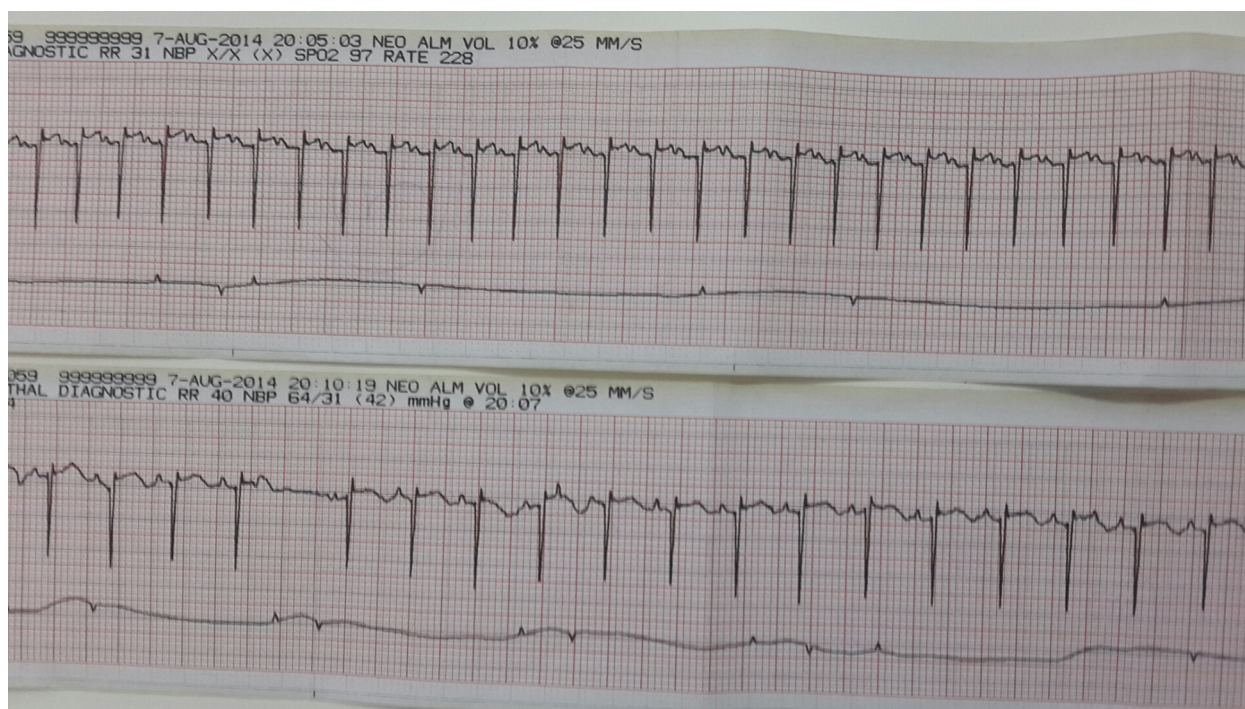


Figure 2. Supraventricular tachycardia during IVIG treatment and normal heart rhythm after the administration of adenosine.

dyspnea, blood pressure changes, tachycardia, flushing or urticaria. These reactions generally respond to temporary discontinuation of the infusion. Potentially serious systemic reactions of various types occur in 2–6% of patients [5]. These include thrombotic, hematologic, renal, and neurologic complications, as well as rare true anaphylactic reactions [6]. Patients with severe IgA deficiency and undetectable levels of serum IgA are at risk for rare anaphylaxis upon infusion of IVIG products that contain IgA. Patients with active infections may experience fever, rigor, and flu-like symptoms during infusion of IVIG, which is believed to result from lysis of bacteria and release of cytokines. Hematologic and thrombotic complications include neutropenia, hemolysis, and thrombotic and thromboembolic events. Renal complications of IVIG include acute kidney injury, hyponatremia and pseudohyponatremia [7].

Adverse events related to IVIG treatment are common but generally mild and usually clinically irrelevant in children. These include fever, headache, myalgia, chills, nausea, low back pain, and vomiting. Serious adverse events, such as aseptic meningitis and anaphylaxis, have also been reported with the administration of IVIG [8]. Kara et al. [9] described necrotizing enterocolitis in a newborn following intravenous immunoglobulin treatment for haemolytic disease.

Cardiovascular adverse effects related to IVIG infusion are sinus tachycardia, edema, facial flushing, chest tightness and changes in blood pressure [10]. Savaşan et al.

[1] described the development of SVT episodes during intravenous immunoglobulin G infusion in two children with thrombocytopenia. One of the patients had a history of supraventricular tachycardia, and the other one had preexisting long QT syndrome. To the best of our knowledge, no cardiac dysrhythmias during IVIG infusion have been reported in newborn infants before. Our first case had no history of documented cardiac dysrhythmia, whereas the second case had an antenatal history of premature atrial beats with block. The reentrant supraventricular tachycardia which developed postnatally seemed to be triggered by IVIG infusion.

Two explanations have been proposed for the development of dysrhythmia during IVIG infusion. The first explanation is the possibility of a direct effect of IVIG on the development of cardiac dysrhythmia. This is similar to the occurrence of immune hemolysis after IVIG administration which results from the interaction of immunoglobulin G with the erythrocytes, or similar to the mechanism proposed in the development of dysrhythmia in neonatal lupus syndrome [1, 11]. The second explanation is the possibility of an indirect reaction in a patient with an underlying cardiac problem. In this situation the cardiac dysrhythmia is not the result of a direct interaction between IVIG preparation and its target organ, but may be due to the mediators released during this interaction. Thus, it is very likely that an underlying cardiac disease may contribute to the development of a dysrhythmia.

In addition to these two possible mechanisms a third explanation may be the direct effect of the temperature of the infusate. Palabrica *et al.* [12] described hypothermia after intravenous immunoglobulin infusion in two patients. In our cases the IVIG solutions were heated before infusion per our NICU routines and the infusion time was 4 h. The body temperatures of the babies after the infusion were 36.9°C for the first baby and 36.4°C for the second baby, making the possibility of hypothermia unlikely.

In conclusion, we observed two newborn babies who developed SVT during IVIG infusion. Although a cause-and-effect relation cannot be shown clearly with these cases, which may well be coincidences, cardiorespiratory monitoring during IVIG infusions in the neonate can be recommended because of the possibility of this life-threatening adverse effect.

Conflict of Interest

None declared.

References

1. Savaşan, S., V. Tuzcu, I. Warriar, and P. Karpawich. 1997. Cardiac rhythm abnormalities during intravenous immunoglobulin G infusion for treatment of thrombocytopenia. *J. Pediatr. Hematol. Oncol.* 19:254–257.
2. Alarcon, P. A. D., E. J. Werner, and R. D. Cristensen. 2013. Chapter 6, Hemolytic disease of the fetus and newborn. Pp. 65–90 *in* M.E. Ross, P.E. Waldron, W.J. Cashore, ed. Neonatal hematology. 2nd ed. Cambridge Univ. Press, Edinburgh.
3. Ohls, R. K., A. Maheshwari, and R. A. Polin. 2012. Chapter 6, Diagnosis and treatment of immune-mediated and non-immune-mediated hemolytic disease of the newborn. Pp. 75–88 *in* S. Patel, ed. Hematology, immunology and infectious disease. 2nd ed. Elsevier Saunders, Philadelphia.
4. Pierce, L. R., and N. Jain. 2003. Risks associated with the use of intravenous immunoglobulin. *Transfus. Med. Rev.* 17:241–251.
5. Orange, J. S., E. M. Hossny, C. R. Weiler, M. Ballow, M. Berger, and F. A. Bonilla, *et al.* 2006. Use of intravenous immunoglobulin in human disease: a review of evidence by members of the Primary Immunodeficiency Committee of the American Academy of Allergy, Asthma and Immunology. *J. Allergy Clin. Immunol.* 117:S525–S553.
6. Stiehm, E. R. 2013. Adverse effects of human immunoglobulin therapy. *Transfus. Med. Rev.* 27:171–178.
7. Bonilla, F. A. 2008. Intravenous immunoglobulin: adverse reactions and management. *J. Allergy Clin. Immunol.* 122:1238–1239.
8. Sekul, E. A., E. J. Cupler, and M. C. Dalakas. 1994. Aseptic meningitis associated with high-dose intravenous immunoglobulin therapy: frequency and risk factors. *Ann. Intern. Med.* 121:259–262.
9. Kara, S., U. H. Ozkan, Y. Yılmaz, F.İ. Arikan, U. Dilmen, and Y. D. Bilge. 2013. Necrotizing enterocolitis in a newborn following intravenous immunoglobulin treatment for haemolytic disease. *J. Coll. Physicians Surg. Pak.* 23:598–600.
10. Blanchette, V. S., B. Luke, M. Andrew, *et al.* 1993. A prospective randomized trial of high dose intravenous immunoglobulin G therapy, oral prednisone therapy, and no therapy in childhood acute immune thrombocytopenic purpura. *J. Pediatr.* 123:989–995.
11. Thomas, M. J., S. A. Misbah, H. M. Chapel, *et al.* 1993. Hemolysis after high dose intravenous immunoglobulin. *Blood* 82:3789.
12. Palabrica, F. R., S. L. Kwong, and F. R. Padua. 2013. Adverse events of intravenous immunoglobulin infusions: a ten-year retrospective study. *Asia Pac. Allergy* 3:249–256.