



Contents lists available at ScienceDirect

International Journal of Surgery Case Reports

journal homepage: www.casereports.com

Retrograde Thyroidectomy for preservation of the External Branch of the Superior Laryngeal Nerve: A case series



Vijay Naraynsingh, Shamir Cawich, Dale Hassranah, Ravi Maharaj, Shariful Islam*, Yardesh Singh

Department of Clinical Surgical Sciences, The University of West Indies, St Augustine, Trinidad and Tobago

ARTICLE INFO

Article history:

Received 13 March 2017
Received in revised form 27 April 2017
Accepted 30 April 2017
Available online 15 May 2017

Keywords:

Multi-nodular goiter
Retro-grade thyroidectomy
External branch of superior laryngeal nerve injury
Recurrent laryngeal nerve injury

ABSTRACT

BACKGROUND: The external branch of the Superior Laryngeal nerve (EBSLN) is at high risk of injury in surgery for large multinodular goitre (MNG) since the upper pole is high in the neck, well cephalad to the EBSLN. We present a technique of drawing the lobe caudally by retrograde thyroidectomy in order to minimize nerve injury.

DESIGN & METHOD: All patients having surgery for benign MNG were included. Cases with previous thyroid surgery, malignant and toxic disease were excluded. The thyroid lobe was mobilized from its inferior aspect and capsular dissection performed cephalad with bipolar or ligasure cautery, lifting the gland off the trachea while separating it from the parathyroids and branches of the inferior thyroid vessels. The ligament of Berry is divided and the entire lobe freed, attached only by the superior pedicle which is drawn caudally well below the EBSLN prior to ligation. Patients were followed for voice change at 24 hours, 7 days and 3 months.

RESULTS: Ninety-one consecutive lobectomies were done in 60 patients, 31 bilateral. Forty-four (73%) patients had voice change at 24 h, 10 (11%) at 7 days and 1 at 3 months. The patient with persistent voice change complained of change in tone but not volume; vocal cords were normal on indirect laryngoscopy.

CONCLUSION: Retrograde thyroidectomy is recommended for large MNG where the EBSLN lies well below the upper pole; it minimizes risk to the nerve.

© 2017 The Authors. Published by Elsevier Ltd on behalf of IJS Publishing Group Ltd. This is an open access article under the CC BY-NC-ND license (<http://creativecommons.org/licenses/by-nc-nd/4.0/>).

1. Introduction

This paper documents a new technique, retrograde thyroidectomy, and its results. It is reported as a case series, compliant with the process criteria [1]. Because the hoarseness resulting from recurrent laryngeal nerve (RLN) injury is so profound, there has been much emphasis on RLN identification and preservation at thyroidectomy [2]. The RLN is also given prominence because, historically, it was commonly damaged at surgery; Billroth in 1877 reported a 36% injury to this nerve [3]. It is not surprising therefore, that Delbridge described the external branch of the superior laryngeal nerve (EBSLN) as the 'neglected' nerve in thyroid surgery although it is well recognized as a contributor to voice integrity [4]. Moreover, current advanced diagnostic techniques have demonstrated that injury to the EBSLN is more common than RLN injury [5–7]. Aluffi et al. documented 14% EBSLN injury and cited a range of 0–58% [8].

In our country, large multinodular non-toxic goiters (MNG) are common and adequate exposure of the superior thyroid vessels and EBSLN in these cases can be challenging as the enlarged gland frequently extends well cephalad to the thyroid cartilage and cricothyroid muscle resulting in high risk of EBSLN injury (Fig. 1). We have previously described a technique of 'Retrograde Thyroidectomy' to facilitate proper visualization of the upper pole vessels and the EBSLN [9]. We now report our experience with a case series of 91 consecutive lobectomies for MNG. Ethical approval was granted by the institutional ethics committee.

2. Technique

Through a standard Kocher's collar incision in the lower neck, the strap muscles are separated in the midline, not divided. Even in very large goiters, when the lobe is delivered medially, lateral retraction of the stretched strap muscles facilitates excellent exposure of the posteromedial part of the lobe without the need to divide these muscles. The enlarged lobe is mobilized medially, off the strap muscles and carotid sheath dividing the middle thyroid vein, if present. Any areolar tissue adherent to the lobe is peeled off its posteromedial surface. This is thoroughly and carefully done at

* Correspondence to: Dr. Shariful Islam, MBBS, DM, Registrar, General Surgery, San Fernando Teaching Hospital, Trinidad & Tobago.
E-mail addresses: sss1201198@yahoo.com, shar.islam7@hotmail.com (S. Islam).

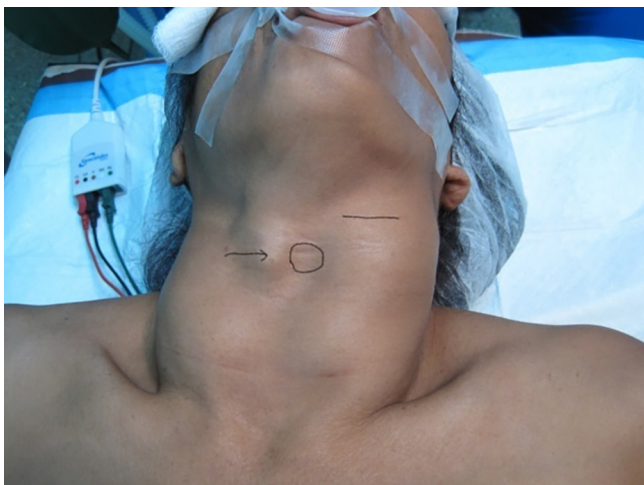

Fig. 1. The arrow showing the thyroid prominence or Adams apple, The circle indicates approximate site of crico-thyroid muscle and the line showing the cephalad extent of the enlarged left upper lobe, well cranial to the cricothyroid muscle and EBSLN.

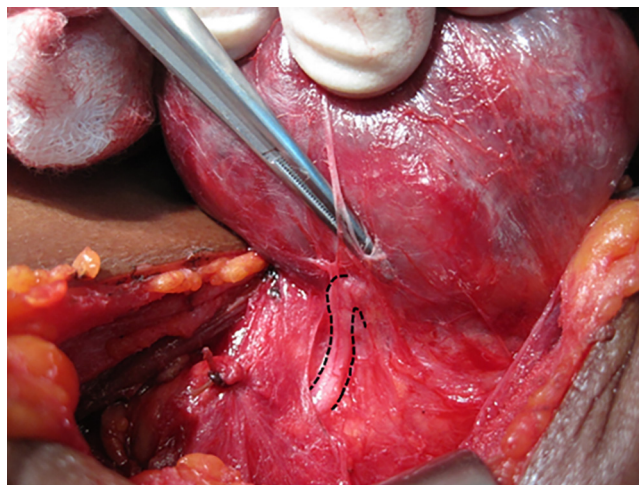


Fig. 3. Recurrent laryngeal nerve drawn upward and kinked against the posteromedial surface of the enlarged gland. Forceps demonstrating the plane and importance of capsular dissection.

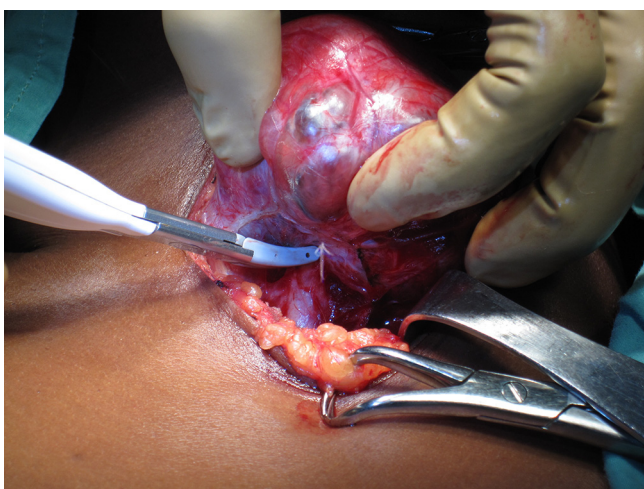


Fig. 2. Arrow showing the site of the ligament of Berry.

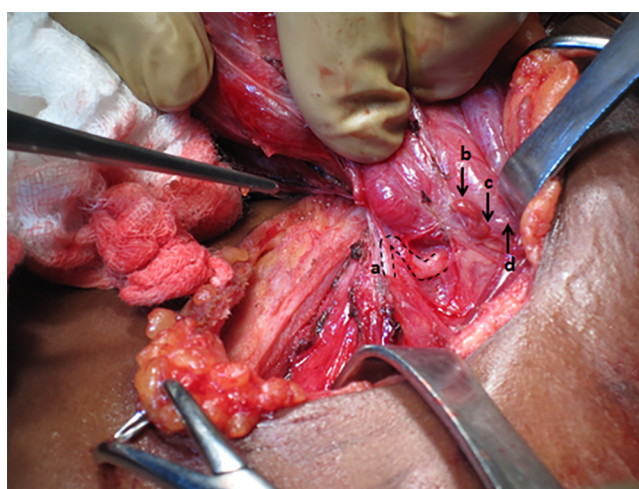


Fig. 4. (a) Kinked recurrent laryngeal nerve (b) inferior parathyroid gland (c) superior parathyroid gland (d) upper pole of thyroid.

the lower pole. The inferior thyroid veins are now divided and the lower pole, easily peeled off the trachea, is lifted into the wound.

Meticulous capsular dissection proceeds cephalad using ligasure or bipolar cautery. The isthmus is divided using cautery and the lobe is lifted off the trachea medially, but this is limited by the ligament of Berry (LB) (Fig. 2). The posteromedial aspect of the lobe is also mobilized by capsular dissection using the same technique. It is essential to stay against the capsule at all times since the RLN may be adherent, kinked upwards and drawn up to the capsule (Fig. 3). On approaching the LB the RLN and parathyroid often become easily visible (Fig. 4). By continuing capsular dissection from lateral to medial, the LB is divided using ligasure or bipolar cautery. Immediately on dividing the LB, the thyroid lobe ‘snaps forward’ off the trachea (Fig. 5). This opens the avascular plane between the posteromedial surface of the upper pole and the cricothyroid muscle. The upper lobe can be peeled off the larynx by finger dissection or a peanut swab. When the upper pole is completely mobilized off the larynx, the entire lobe is freely mobile, attached only by the upper pole vessels (Fig. 6a and b). Thus, the upper pole and its vessels can be delivered into the wound and visualized on all sides. The superior thyroid vessels and the upper pole are drawn caudally, well below the thyroid cartilage and the vessels ligated/coagulated close to the gland. At this level the EBSLN is cephalad and completely removed

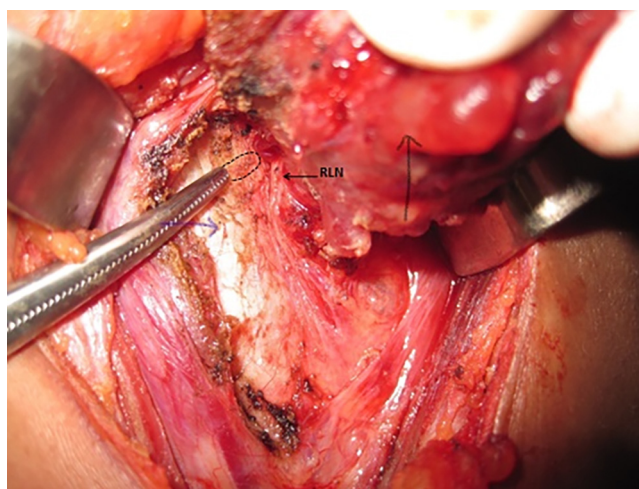


Fig. 5. Blue arrow indicating position of trachea, RLN- recurrent laryngeal nerve, black arrow showing thyroid lobe as it snaps forward after division of ligament of Berry (dotted line at artery forceps tip).

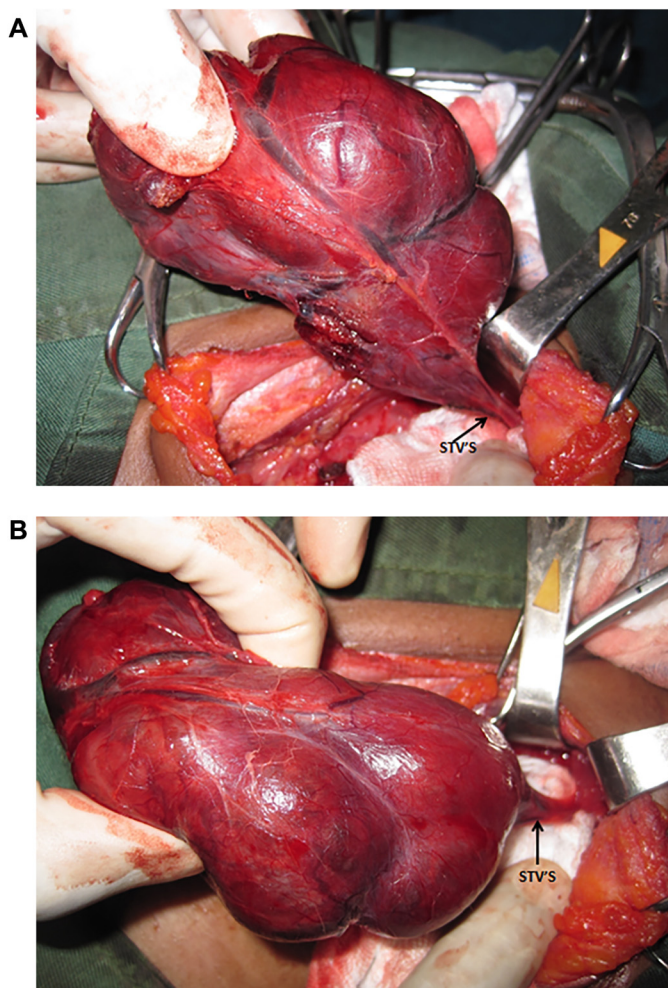


Fig. 6. (a) & (b) showing that the upper pole, drawn caudally, is freely mobile and attached only by superior thyroid vessels (STV'S).

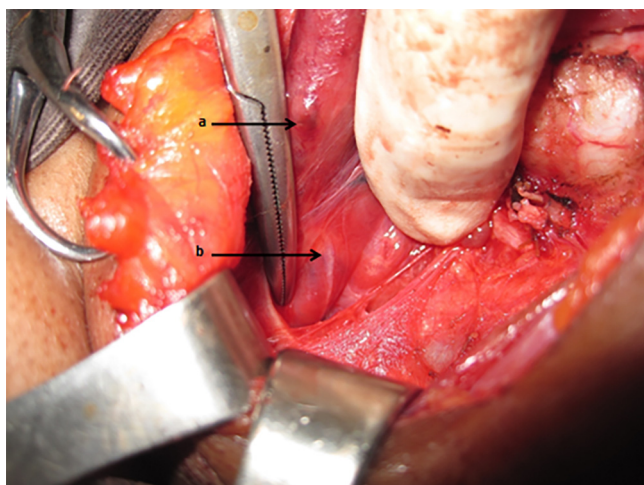


Fig. 7. (a) upper pole of thyroid gland (b) the external branch of superior laryngeal nerve.

from the risk of injury (Fig. 7). With such uncompromised visualization of the upper pole and its vessels, identification of the EBSLN becomes unnecessary.

3. Methods

Retrograde thyroidectomy was performed in all cases of benign non-toxic MNG by one senior surgeon (VN) at one hospital. Patients with preoperative voice change, previous neck surgery or malignant or toxic goiter were excluded. Pre-operative and post operative clinical voice assessment was done both by the surgeon and the patient, postoperatively at 1 day, 1 week and 3 months. If voice change persisted at 3 months, laryngoscopy is performed.

4. Results

Ninety-one lobectomies in 60 patients were done for MNG – 31 bilateral and 29 unilateral. There was tracheal deviation in 24 of the bilateral and 16 of the unilateral cases. The operating time ranged from 35 to 108 mins (mean 52 min). Although the RLN was seen in all cases (where it entered the larynx) it was not dissected out. The EBSLN was identified in 54 lobectomies (59%) but was not actively sought; care was taken to bring the upper pole well into the wound, by drawing it far caudally, clearly exposing the superior thyroid vessels and branches before ligation/division.

Drains were not used. Although 44 patients (73%) complained of some hoarseness on the first post-op day, 10 (11%) had mild voice change at 1 week and one complained of persistent voice change at 3 months. This patient described alteration of tone but not of volume. Laryngoscopy showed normal vocal cord mobility. Since there is no unequivocal way to demonstrate EBSLN injury and sophisticated voice assessment techniques were not available, we were unable to be certain of the cause of voice change in this patient apart from excluding RLN injury.

There were two cases of temporary hypoparathyroidism; these reversed completely and required no treatment beyond two weeks.

5. Discussion

Voice change following thyroidectomy is not uncommon. Stojadinovic et al. reported voice symptoms on 30% of patients at 1 week and 14% at 3 months postop. In 84% there was significant objective change in at least one voice parameter [10]. In other studies, early postoperative voice change was recorded in over 40% of cases [8,11]. Kaushal et al. reported voice alteration in 23% of patients having thyroidectomy [12]. We found some hoarseness, noticed by either the patient or surgeon, in 73% of patients within the first 24h. This could be due to laryngeal edema from intubation combined with manipulation from the thyroidectomy as it settled rapidly down to 11% within 1 week. This compares favourably with the Stojadinovic study [10]. Traction injury to the EBSLN is very unlikely to occur with retrograde thyroidectomy since the upper pole is drawn downward only after the LB is divided, the isthmus severed, the lobe completely mobilized and the avascular plane between the upper pole and the cricothyroid muscle developed as described in the technique above.

Apart from RLN and EBSLN injury, other factors may be related to voice change. Division of the sternothyroid and sternohyoid muscles and disturbance of laryngotracheal mobility may contribute to voice dysfunction post thyroidectomy [10,13]. We do not divide the strap muscles, even in very large goiters, for when the lobe is delivered medially, there remains considerable space posterolaterally, medial to the stretched strap muscles, to allow excellent exposure without muscle division. However some surgeons almost routinely divide these muscles; Stojadinovic et al. did it in 92% of cases and admitted that they were therefore unable to assess its impact on voice [10]. It has also been suggested that endotra-

cheal intubation alone may produce significant voice change in 5% of cases [14].

In spite of all these variables, division of strap muscles and nerve injury (RLN & EBSLN) are under direct control of the surgeon. For benign MNG, it is our view that division of the strap muscles is not necessary. Of the nerves, most authors agree that the EBSLN is damaged far more frequently than the RLN [4,8,14]. There is much argument about whether it is worth identifying the EBSLN in order to preserve it at surgery. Page et al. report that even using a nerve stimulator, the nerve was identified in only 20% of cases and concluded that searching for the nerve during thyroidectomy is not useful [15]. However, other authors believe that nerve identification and preservation is desirable in order to minimize injury [17].

In cadaveric dissections, Ozlgedik et al. describe that it is possible to identify the EBSLN as it crosses the inferior constrictor of the pharynx in 90% of cases [16]. At live surgery, Aina and Hisham reported the highest rate of EBSLN identification – 92.7% of 202 cases. They recommend identification and preservation of the EBSLN but indicated that most surgeons tend to avoid rather than expose and identify the nerve [17]. Yet, a large meta-analysis of neuro monitoring in 3064 nerves at risk showed no significant decrease in definitive injury to either the RLN or EBSLN [18].

Many authors use the Cernea classification to estimate risk to the EBSLN where in 20% of cases the nerve is reported to cross the superior thyroid vessels below the upper border of the thyroid lobe [19]. Kierner et al. found that the nerve crossed below the upper pole in 14% [20]. However, both of these were cadaveric studies in patients with normal thyroids. However, we have found that in the enlarged thyroid lobe the upper lobe extends well above the EBSLN in many cases. Because the thyroid is firmly fixed to the trachea by the LB, any enlargement cephalad to this point will result in the upper pole being driven much more cephalad than its normal anatomical position, while the nerve, fixed in its relation to the cricothyroid muscle, is left in a more caudal position – hence at even greater risk. In fact, Aina et al. noted that in large goiters greater than 100 g, the type 2b EBSLN was 51.3% [17]. We certainly agree with this finding and recognize that if the lobe is dissected in a retrograde fashion and drawn caudally by complete mobilization after dividing the LB, then all upper poles, even in very large glands, will be brought well below the cricoid and completely free from the EBSLN as shown in Fig. 6a and b. This technique could also eliminate or minimize the need for identification of the EBSLN since the nerve is far removed from the field when the entire lobe is mobilized and drawn caudally before the upper pole vessels are ligated or coagulated. We therefore recommend retrograde thyroidectomy as a safe way of preserving the EBSLN, especially in large multinodular goiters.

Conflict of interest

There is no conflicts of interest amongst the authors in publishing this case series.

Source of funding

No fund was received to published this article.

Ethical approval

Ethical approval was granted by the institutional ethics committee.

Consent

Informed consent was obtained from all patients.

Author contributions

All authors have contributed significantly in these case series. The first author have performed the surgery and rest of the authors helped in collecting data, designing, organizing to write the manuscript as well as assisted in critical analysing of the manuscript. All authors have approved the final version of this manuscript.

Registration of research studies

It is not a clinical trial.

Guarantor

The corresponding author and the first author (Professor Vijay Naraynsingh) will accept the full responsibility for the work.

Acknowledgement

The authors have nothing to acknowledge.

References

- [1] R.A. Agha, A.J. Fowler, S. Rammohan, I. Barai, D.P. Orgill, PROCESS Group, *Int. J. Surg.* 36 (Pt A) (2016) 319–323.
- [2] A. Pisanu, G. Porceddu, M. Podda, A. Cois, A. Uccheddu, Systematic review with meta-analysis of studies comparing intraoperative neuromonitoring of recurrent laryngeal nerves versus visualization alone during thyroidectomy, *J. Surg. Res.* 188 (1) (2014) 152–161 [PubMed].
- [3] L. Delbridge, Total thyroidectomy: the evolution of surgical technique, *ANZ J. Surg.* 73 (2003) 761–768, <http://dx.doi.org/10.1046/j.1445-2197.2003.02756.x>.
- [4] L. Delbridge, The 'neglected' nerve in thyroid surgery: the case for routine identification of the external nerve, *ANZ J. Surg.* 71 (4) (2001) 199.
- [5] B.J. Teitelbaum, B.L. Weng, Superior Laryngeal nerve injury from thyroid surgery, *Head Neck* 17 (January–February (1)) (1995) 36–40 (ISSN: 1043-3074).
- [6] R.C. Claudia, N. Sunao, C.H. Flavio, Identification of the External Branch of the Superior Laryngeal Nerve (EBSLN) in large goiters, *Am. J. Surg.* 164 (6) (1992) 634–639.
- [7] J. Svante, T. Lars-Erik, H. Ingrid, S. Esbjörn, S. Rune, S. Per, Partial superior laryngeal nerve (SLN) lesions before and after thyroid surgery, *World J. Surg.* 12 (1988) 522, <http://dx.doi.org/10.1007/BF01655439>.
- [8] P. Aluffi, M. Policarpo, C. Cherovac, M. Olina, R. Dosdegani, F. Pia, Post thyroidectomy superior laryngeal nerve injury, *Eur. Arch. Otorhinolaryngol.* 258 (2001) 451–454, <http://dx.doi.org/10.1007/s004050100382>.
- [9] V. Naraynsingh, S.O. Cawich, R. Maharaj, D. Dan, Retrograde thyroidectomy: a technique for visualization and preservation of the external branch of superior laryngeal nerve, *Int. J. Surg. Case Rep.* 5 (3) (2014) 122–125, <http://dx.doi.org/10.1016/j.ijscr.2014.01.001>, PMID: 24514007 PMID: PMC3955232.
- [10] A. Stojadinovic, A.R. Shaha, R.F. Orlikoff, A. Nissam, M.F. Kornak, B. Singh, J.O. Boyle, J.P. Shah, M.F. Brennan, D.H. Kraus, Prospective functional voice assessment in patients undergoing thyroid surgery, *Ann. Surg.* 236 (2002) 823–832.
- [11] N.P. Mc Ivor, D.J. Flint, J. Gillibrand, R.P. Morton, Thyroid surgery and voice-related outcomes, *Aust. N. Z. J. Surg.* 70 (March (3)) (2000) 179–183.
- [12] K. Manish, M. Anjali, K.M. Saroj, Thyroid surgery and voice-related outcomes, *ANZ J. Surg.* 71 (2001) 611, <http://dx.doi.org/10.1111/j.1445-2197.2001.2201a.x>.
- [13] K.H. Hong, Y.K. Kim, Phonatory characteristics of patients undergoing thyroidectomy without laryngeal nerve injury, *Otolaryngol. Head Neck Surg.* 117 (October (4)) (1997) 399–404.
- [14] A.E. Kark, M.W. Kissin, R. Auerbach, M. Meikle, Voice changes after thyroidectomy: role of the external laryngeal nerve, *Br. Med. J. (Clin. Res. Ed.)* 289 (1984) 1412–1415.
- [15] C. Page, M. Laude, D. Legars, P. Foulon, V. Strunski, The External Laryngeal nerve: surgical and anatomical considerations. Report of 50 total thyroidectomies, *Surg. Radiol. Anat.* 26 (June (3)) (2004) 182–185.
- [16] S. Ozlgedik, H.I. Acar, N. Apaydin, I. Tekdemir, A. Elhan, A. Comert, Surgical anatomy of the external branch of the superior laryngeal nerve, *Clin. Anat.* 20 (2007) 387–391, <http://dx.doi.org/10.1002/ca.20399>.
- [17] E.N. Aina, A.N. Hisham, External Laryngeal nerve in thyroid surgery: recognition and surgical implications, *ANZ J. Surg.* 71 (2001) 212–214.

- [18] A.I. Sanabria, A. Ramirez, L.P. Kowalski, C.E. Silver, A.R. Shaha, R.P. Owen, C. Suárez, A. Khafif, A. Rinaldo, A. Ferlito, Neuromonitoring in thyroidectomy: a meta-analysis of effectiveness from randomized controlled trials, *Eur. Arch. Otorhinolaryngol.* 270 (August (8)) (2013) 2175–2189, <http://dx.doi.org/10.1007/s00405-013-2557-2>, Epub 2013 May 17.
- [19] C.R. Cernea, A.R. Ferraz, S. Nishio, Surgical anatomy of the external branch of the superior laryngeal nerve, *Head Neck* 14 (1992) 380–383.
- [20] A.C. Kierner, M. Aigner, M. Burian, The external branch of the superior laryngeal nerve: its topographical anatomy as related to surgery of the neck, *Arch. Otolaryngol. Head Neck Surg.* 124 (March (3)) (1998) 301–303 [Medline].

Open Access

This article is published Open Access at sciendo.com. It is distributed under the [IJSCR Supplemental terms and conditions](#), which permits unrestricted non commercial use, distribution, and reproduction in any medium, provided the original authors and source are credited.