

Video Abstracts

Re-Emergent Kinetic Tremor in Parkinson's Disease

Harsh V. Gupta*

Department of Neurology, Kansas University Medical Center, Kansas City, KS, USA

Abstract

Background: This is a case of re-emergent kinetic tremor in Parkinson's Disease (PD).

Phenomenology shown: The video shows re-emergent kinetic tremor while drawing a spiral and with repeated attempts to drink water from a cup.

Educational value: The kinetic tremor described by patients with PD can be a re-emergent tremor which occurs after a few repetitive movements.

Keywords: Re-emergent, kinetic tremor, spirals, Parkinson's disease, essential tremor

Citation: Gupta HV. Re-Emergent Kinetic Tremor in Parkinson's Disease. Tremor Other Hyperkinet Mov. 2019; 9. doi: 10.7916/tohm.v0.660

*To whom correspondence should be addressed. E-mail: dr.harshgupta@gmail.com

Editor: Elan D. Louis, Yale University, USA

Received: March 6, 2019; **Accepted:** June 14, 2019; **Published:** July 5, 2019

Copyright: © 2019 Gupta. This is an open-access article distributed under the terms of the Creative Commons Attribution–Noncommercial–No Derivatives License, which permits the user to copy, distribute, and transmit the work provided that the original authors and source are credited; that no commercial use is made of the work; and that the work is not altered or transformed.

Funding: None.

Financial Disclosures: None.

Conflicts of Interest: The authors report no conflicts of interest.

Ethics Statement: This study was performed in accordance with the ethical standards detailed in the Declaration of Helsinki. All patients who appear on the video have provided written informed consent.

A 62-year-old right-handed female was seen in the clinic for a second opinion. She started to have a rest tremor in her left hand around 8 years ago. She was diagnosed with Parkinson's disease (PD), but decided not to start any treatment. Recently, she noted the appearance of other symptoms such as stiffness on the left side associated with dragging of the left foot. Her nonmotor symptoms include depression and urinary urgency. There is no family history of tremor, but the tremor improves some with alcohol. Besides holding a cup, her tremor is also bothersome while doing different activities such as painting, eating, drinking, and so on.

Her physical examination showed a rest tremor in the left upper extremity associated with slowness in the same extremity. There is a re-emergent postural tremor in the left upper extremity which has the same amplitude and frequency as the rest tremor. A re-emergent kinetic tremor is seen with spiral drawing as no tremor is seen in the initial part of the spiral, while it is seen in the later part (Figure 1). The same phenomenon of re-emergent kinetic tremor in the left hand can be demonstrated with repeated attempts to drink water from a cup (Video 1).

The phenomenon of re-emergent postural tremor in PD was described in 1999.¹ This refers to the appearance of a postural tremor after a latency once the limb assumes a horizontal posture.¹ This is in comparison to essential tremor (ET), where the postural tremor appears as soon as the limb is held in a horizontal position.¹ Occasionally, PD

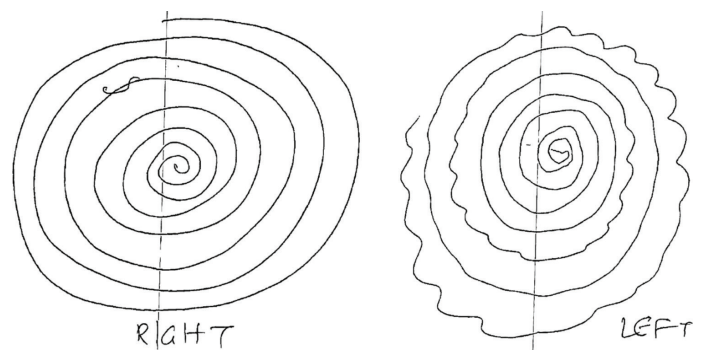
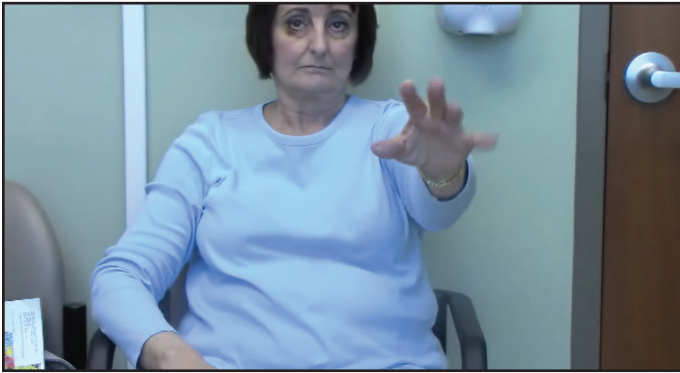

Figure 1. A Normal Spiral Drawing with the Right Hand, While There Is a Tremor in the Later Portion of the Spiral with the Left Hand Indicating a Re-emergent Kinetic Tremor. The spiral drawing with the left hand lacks the characteristic “saw-tooth” morphology seen with ET, and there is a lack of identifiable axis as well.

patients have a re-emergent postural tremor in the absence of rest tremor.¹ In daily life, a re-emergent postural tremor is a significant cause of disability because it can interfere with holding objects.¹ People with ET describe a kinetic tremor which is present while doing an activity and can interfere with several tasks such as shaving, handwriting,



Video 1. A Rest Tremor in the Left Upper Extremity Associated with Bradykinesia. There is a re-emergent postural tremor in the left upper extremity after a latency. A re-emergent kinetic tremor is seen in the left arm with repeated attempts to drink water from a cup.

pouring, and so on. This is in contrast to PD, where the tremor is present mainly at rest and minimally with action. Therefore, the tremor of PD does not interfere while doing a task such as eating or drinking, but can be present while holding an object which represents a re-emergent postural tremor. In a study published recently, it was found that kinetic and postural tremor can occur in the absence of rest tremor in PD, but

the amplitude of kinetic tremor was low and not severe enough to interfere with any activity.²

This case illustrates the phenomenon of re-emergent kinetic tremor in PD because it occurs after a latency and has a higher amplitude which can interfere with activities. The spiral drawing of this patient is different from a classic ET patient because the tremor is not severe in a direction, there is no tremor in the initial part of the spiral, and the morphology lacks “saw tooth” pattern as seen in ET spirals.³ The presence of a re-emergent kinetic tremor in PD can lead to diagnostic confusion with ET, and careful examination of the latency should be done to improve diagnostic accuracy.

References

1. Jankovic J, Schwartz KS, Ondo W. Re-emergent tremor of Parkinson's disease. *J Neurol Neurosurg Psychiatry*. 1999;67(5):646–650. doi: 10.1136/jnnp.67.5.646
2. Pasquini J, Ceravolo R, Qamhawi Z, Lee JY, Deuschl G, Brooks DJ, et al. Progression of tremor in early stages of Parkinson's disease: a clinical and neuroimaging study. *Brain*. 2018;141(3):811–821. doi: 10.1093/brain/awx376
3. Morgan S, Louis ED. Re-emergent tremor of Parkinson's disease masquerading as essential tremor. *Tremor Other Hyperkinet Mov (N Y)*. 2016;6:370. doi: 10.7916/D8NG4QDB