

# Prolonged ileus in traumatic pelvic ring injury patients who underwent arterial angio-embolization

## A retrospective study

Chan-Hee Park, MD<sup>a</sup>, Jeong-Woo Lee, MD<sup>a</sup>, Beom-Soo Kim, MD<sup>b</sup>, Myung-Rae Cho, MD<sup>c</sup>, Suk-Kyoon Song, MD<sup>c,\*</sup> 

### Abstract

Paralytic ileus occurs in up to 18% of the patients with pelvic bone fractures. The aim of this study is to determine if massive bleeding requiring arterial angio-embolization is related with the duration of ileus in patients with traumatic pelvic ring injuries. This retrospective study included 25 patients who underwent arterial angio-embolization for traumatic pelvic ring injuries. Data were collected from prospectively maintained databases of two independent hospitals. Demographic characteristics (such as age, sex, body mass index, and Charlson Comorbidity Index), cause of trauma, and severity of pelvic injuries were similar in the non-prolonged and prolonged ileus groups. As expected, the prolonged ileus group had a significantly longer duration of ileus than the non-prolonged ileus group ( $8.0 \pm 4.2$  days vs  $1.2 \pm 0.4$  days, respectively;  $P < .001$ ). The mortality rate was higher in the prolonged ileus group (20% vs 0%), but it was not significantly different ( $P = .13$ ). Interestingly, the prolonged ileus group received significantly higher amounts of packed red blood cell transfusions ( $6.1 \pm 2.1$  units vs  $3.8 \pm 2.5$  units;  $P = .02$ ). The amount of packed red blood cell transfusions was associated with a greater risk of prolonged ileus development ( $P = .03$ , odds ratio = 2.04, 95% confidence interval = 1.08–3.88). This study supports the idea that the duration of the ileus is related with the amount of bleeding caused by the traumatic pelvic ring injury. In order to prevent further complications, conservative treatments of the ileus should be considered.

**Abbreviations:** AAE = arterial angio-embolization, CI = confidence interval, OR = odd ratio, PRBC = packed red blood cells.

**Keywords:** arterial angio-embolization, bleeding, ileus, pelvic ring injury

## 1. Introduction

Traumatic pelvic ring injuries are rare and potentially lethal skeletal lesions associated with polytrauma often.<sup>[1]</sup> They are mostly caused by high-energy forces such as motor vehicle collisions (60% of cases), falls (30%), and high-speed crashes (10%).<sup>[2]</sup> Owing to massive bleeding, they are considered a major cause of death in pelvic trauma patients, with an overall mortality of approximately 5%.<sup>[2–4]</sup> The mortality rate reaches 30% when the pelvic fractures are also accompanied by hemodynamic instability,<sup>[5–7]</sup> mainly caused by bleeding at the fracture site, injury to the presacral venous plexus, and/or bleeding branches of the iliac artery.<sup>[5]</sup> Timely hemorrhage control interventions are fundamental to improve outcomes and include the use of pelvic binders, stabilization by external fixation, extraperitoneal pelvic packing, and arterial angio-embolization (AAE). AAE is considered a first-line treatment to control massive bleeding in pelvic injuries.<sup>[8,9]</sup>

Paralytic ileus is defined as a temporary inhibition of peristalsis. It results in stagnation of intestinal contents and gut dilation due to accumulation of secretions and gas. The causes can include intra-abdominal infections, metabolic disturbance, retroperitoneal or intraperitoneal hematomas, intestinal ischemia, and drugs.<sup>[10–12]</sup> Patients generally present with abdominal distension, abdominal pain, abdominal discomfort, nausea, vomiting, and constipation.<sup>[12]</sup> Postoperative ileus occurs in approximately 15% of patients who underwent abdominal surgery, and in approximately 8% of patients who underwent orthopedic surgeries that did not involve the peritoneal or retroperitoneal cavities.<sup>[10,13,14]</sup> In addition, paralytic ileus occurs in 5.5% to 18% of the patients with pelvic bone fractures.<sup>[15–17]</sup> Long-lasting ileus is associated with increased morbidity, health care cost, and length of hospital stay.<sup>[18–20]</sup> The determinants of ileus in traumatic pelvic ring injury patients are not yet fully understood. The aim of our study is to define whether bleeding in traumatic pelvic ring injury patients who underwent AAE is associated with the duration of ileus.

The authors have no conflicts of interest to disclose.

All data generated or analyzed during this study are included in this published article [and its supplementary information files].

<sup>a</sup> Department of Surgery, School of Medicine, Keimyung University and Dongsan Medical Center, Daegu, Republic of Korea, <sup>b</sup> Department of Orthopaedic Surgery, School of Medicine, Keimyung University and Dongsan Medical Center, Daegu, Republic of Korea, <sup>c</sup> Department of Orthopaedic Surgery, School of Medicine, Daegu Catholic University Hospital, Daegu, Republic of Korea.

\*Correspondence: Suk-Kyoon Song, Department of Orthopaedic Surgery, School of Medicine, Daegu Catholic University Hospital, 33, Duryugongwon-ro 17-gil, Nam-gu, Daegu, Republic of Korea (e-mail: ryansong10@naver.com).

Copyright © 2022 the Author(s). Published by Wolters Kluwer Health, Inc. This is an open-access article distributed under the terms of the Creative Commons Attribution-Non Commercial License 4.0 (CCBY-NC), where it is permissible to download, share, remix, transform, and buildup the work provided it is properly cited. The work cannot be used commercially without permission from the journal.

How to cite this article: Park C-H, Lee J-W, Kim B-S, Cho M-R, Song S-K. Prolonged ileus in traumatic pelvic ring injury patients who underwent arterial angio-embolization: A retrospective study. *Medicine* 2022;101:39(e30684).

Received: 16 December 2021 / Received in final form: 20 August 2022 / Accepted: 22 August 2022

<http://dx.doi.org/10.1097/MD.00000000000030684>

## 2. Methods

### 2.1. Ethics statements

The study protocol was approved by the institutional review boards of the Keimyung University Hospital (approval number: DSMC 2021-11-041) and the Daegu Catholic University Hospital (approval number: CR-21-190), and conducted in accordance to local ethical guidelines. The requirement for informed consent was waived, as all data were de-identified to protect patient's right to privacy.

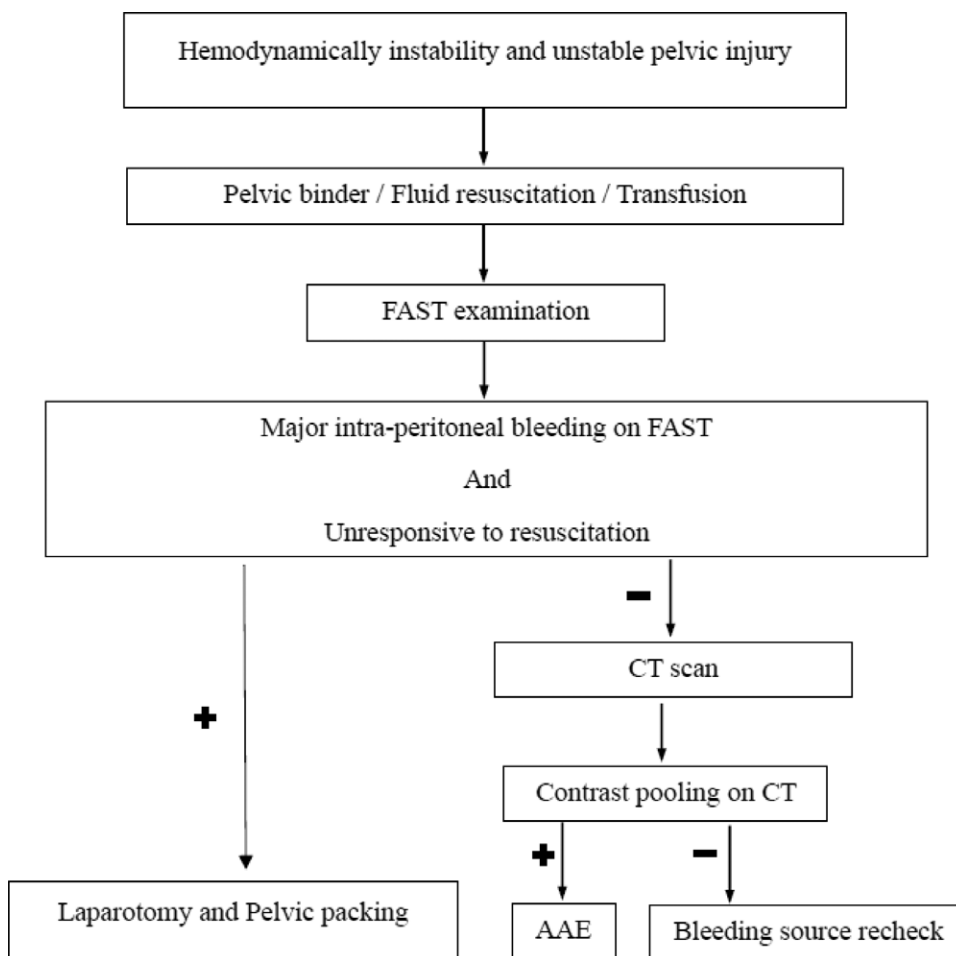
### 2.2. Study population

The study included 29 patients who underwent AAE for traumatic pelvic ring injuries with active bleeding. Fourteen patients were treated at the Keimyung University Dongsan Hospital (Daegu, Korea) and 15 patients were treated at the Daegu Catholic University Hospital (Korea) between August 2015 and August 2021. Four patients died within 3 days of traumatic pelvic ring injury and were therefore excluded. This is because we could not evaluate whether these patients had prolonged ileus.

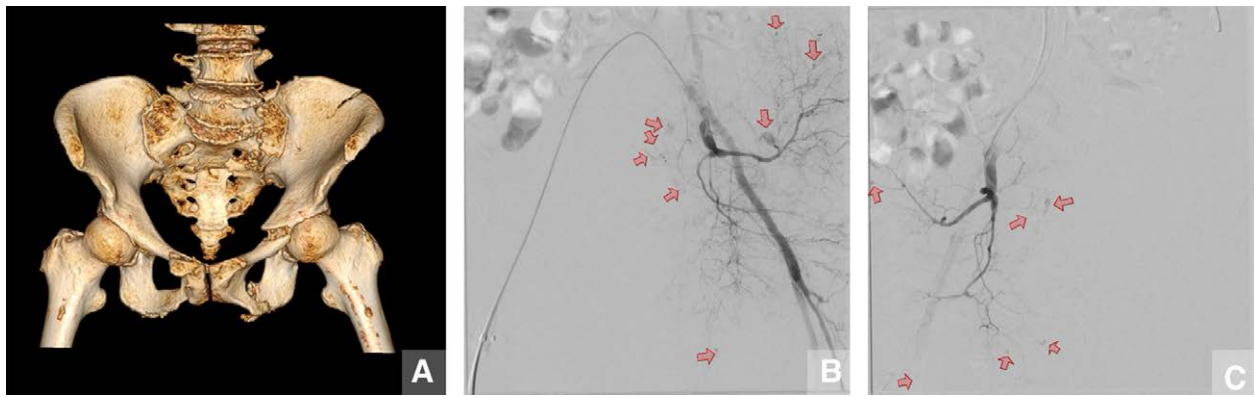
### 2.3. Treatment

The treatment algorithm for hemodynamically unstable patients with pelvic injury is shown in Figure 1. Both study sites adopted the same protocol that required the presence of a multidisciplinary team comprising a trauma surgeon, an

orthopedic surgeon, and an interventional radiologist in the emergency department. The protocol followed the recommendations of the Advanced Trauma Life Support guideline.<sup>[21,22]</sup> First, patients with unstable pelvic injuries were immediately equipped with a pelvic binder. Endotracheal intubation and mechanical ventilation were performed when necessary, based on the level of consciousness and breathing patterns of the patient. At least two large-bore venous catheters were inserted for the rapid infusion of crystalloid solution (1 L). Patients were diagnosed with hemodynamic instability if their systolic blood pressure was lower than 90 mm Hg and did not recover after giving fluids.<sup>[23]</sup> When packed red blood cell (PRBC) was prepared at the same time as fluid resuscitation, transfusion of two packs of PRBC began immediately. If the patients with pelvic trauma had massive bleeding, a 1:1:1 ratio of PRBC, fresh-frozen plasma, and platelets was transfused according to the massive transfusion protocol.<sup>[24,25]</sup> Simultaneously, a focused assessment with sonography for trauma was performed to detect life-threatening intra-peritoneal bleeding and to evaluate the need for intervention. In case the focused assessment with sonography for trauma exam showed major intra-peritoneal bleeding, and the patient was still unresponsive after resuscitation, laparotomy and pelvic packing were performed by the trauma surgery team. Alternatively, in case the vital signs were stable, a computed tomography scan was performed to identify the site of bleeding and to assess injuries in other organs. If the computed tomography scan showed pooling of contrast material, an AAE was performed by the interventional radiology team (Fig. 2).



**Figure 1.** Protocols for the acute management of hemodynamic unstable pelvic injuries at the Keimyung University Hospital and the Daegu Catholic University Hospital. AAE = arterial angio-embolization, CT = computer tomography, FAST = focused assessment with sonography for trauma.



**Figure 2.** Computed tomography 3-dimensional reconstruction of pelvic fracture and pelvic angiogram. (A) Tile C pelvic injury with straddle fracture. Pelvic ring vertical instability is due to fractures of left iliac crest, sacral ala, and L5 transverse process. (B and C) The angiograms show bleeding in several small branches of the internal iliac artery, associated with unstable vital signs. Artery embolization was performed using Gelfoam.

#### 2.4. Data collection and definitions

Data regarding patients' characteristics and clinical outcomes were collected from the prospectively maintained databases of the two institutions. Prolonged ileus was defined as a paralytic ileus lasting more than 3 days after trauma (Fig. 3).<sup>[11,26]</sup> The duration of ileus was calculated from the time of admission to the time of adequate intake of a liquid diet. Shock at admission was defined as a significant drop in blood pressure that required treatment with fluid resuscitation or vasopressors.<sup>[23]</sup> The pelvic fractures were most often classified using the Tile classification system.<sup>[27]</sup> It is a method to categorize the stability of the pelvic ring based on the fracture patterns and the mechanism of injury. Type A are stable fractures not involving the ring. Type B are rotationally unstable, but vertically stable fractures with injury to elements of the posterior arch. Type C are rotationally and vertically unstable fractures with injury to elements of the posterior arch.<sup>[28]</sup> PRBC transfusions were recorded as the number of units of PRBC transfused within 24 hours from admission. Massive transfusions are defined as transfusions that required 10 or more PRBC units within

24 hours, or transfusions that required 4 or more PRBC units within 1 hour.<sup>[24]</sup>

#### 2.5. Statistical analysis

Data were reported as percentages or as means  $\pm$  standard deviations. The clinical characteristics and outcomes of the non-prolonged ileus group and prolonged ileus group were compared using a chi-squared test or a Fisher exact test (for categorical variables), or a Student *t* test (for continuous variables). Univariate and multivariate logistic regression analyses of risk factors associated with prolonged ileus were performed; the degree of association with prolonged ileus was expressed as odds ratios (OR) with their corresponding 95% confidence intervals (CI). Differences were considered statistically significant at *P* values  $<.05$ . All analyses were performed using SPSS software (version 25.0; IBM Corp., Armonk, NY).

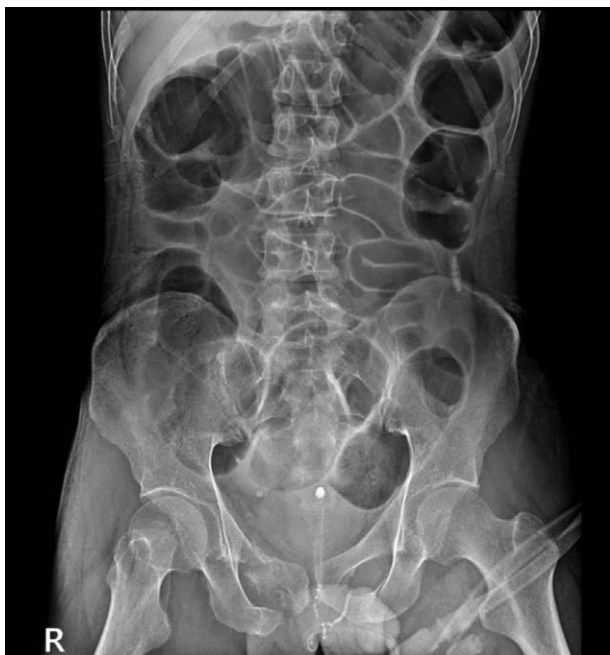### 3. Results

#### 3.1. Patient characteristics

A total of 25 patients were included in the study, 10 were in the non-prolonged ileus group and 15 in the prolonged ileus group. There were no notable differences between the two study groups in terms of demographic characteristics such as age, sex, body mass index, and Charlson Comorbidity Index. The two groups reported similar causes of trauma, mostly due to pedestrian traffic accidents (5 cases in each group). Also, 80% of patients in both groups were in shock at the time of arrival at the emergency room. There was no statistical difference between the non-prolonged and the prolonged ileus groups in the percentage of patients with traumatic abdominal injury (30.0% vs 26.7%, respectively; *P* = .86) and in the percentage of patients taking anticoagulant medication (30.0% vs 20.0%; *P* = .57). There was no significant difference between the two groups in the Tile classification (*P* = .08). A total of 20% of patients (*n* = 2) in the non-prolonged ileus group had a Tile classification type A pelvic fracture, while none were reported in the prolonged ileus group. This difference was not statistically significant (*P* = .07) (Table 1).

#### 3.2. Clinical outcomes

In the total study population, the average duration of ileus was  $5.2 \pm 4.7$  days. As expected, the average duration was longer in the prolonged ileus group ( $8.0 \pm 4.2$  days) and shorter in the non-prolonged ileus group ( $1.2 \pm 0.4$  days, *P*  $<.001$ ). The overall mortality rate was 12.0%, and there was no significant



**Figure 3.** Prolonged ileus. The paralytic ileus was due to pelvic trauma and lasted more than 3 days.

**Table 1**  
Patient characteristics.

	Total (N = 25)	Non-prolonged ileus (n = 10)	Prolonged ileus (n = 15)	P value
Age (yr)	62.3 ± 18.5	59.8 ± 17.6	64 ± 19.5	.59
Sex, N (%)				.51
Male	12 (48.0)	4 (40.0)	8 (53.3)	
Female	13 (52.0)	6 (60.0)	7 (46.7)	
BMI (kg/m <sup>2</sup> )	22.2 ± 5.8	22.3 ± 6.8	22.1 ± 5.2	.93
CCI	3.8 ± 2.9	3.6 ± 3.5	3.9 ± 2.6	.83
Cause of Injury, N (%)				.65
Pedestrian traffic accident	10 (40.0)	5 (50.0)	5 (33.3)	
Fall	6 (24.0)	1 (10.0)	5 (33.3)	
Motorcycle accident	4 (16.0)	2 (20.0)	2 (13.3)	
Car accident	3 (12.0)	1 (10.0)	2 (13.3)	
Slip down	2 (8.0)	1 (10.0)	1 (6.8)	
Shock at admission, N (%)	20 (80.0)	8 (80.0)	12 (80.0)	.99
Traumatic abdominal injury, N (%)	7 (28.7)	3 (30.0)	4 (26.7)	.86
Anticoagulant, N (%)	6 (24.0)	3 (30.0)	3 (20.0)	.57
Tile classification, N (%)				.19
A	2 (8.0)	2 (20.0)	0	.07
B	15 (60.0)	5 (50.0)	10 (66.7)	.40
C	8 (32.0)	3 (30.0)	5 (33.3)	.86

BMI = body mass index, CCI = Charlson Comorbidity Index.

difference between the two groups (0% vs 20.0%;  $P = .13$ ). On average, the prolonged ileus group required significantly more PRBC transfusions than the non-prolonged ileus group ( $6.1 \pm 2.1$  packs vs  $3.8 \pm 2.5$  packs;  $P = .02$ ), and showed a higher percentage of patients requiring massive transfusions (66.7% vs 30.0%;  $P = .07$ ) and vasopressors (53.3% vs 30.0%;  $P = .25$ ), although the differences between the two groups were not significant in these latter cases. None of the patients in the non-prolonged ileus group required ventilator care or a tracheostomy, while 8 patients (53.3%,  $P = .01$ ) required ventilator care and 6 (40.0%;  $P = .02$ ) received a tracheostomy only in the prolonged ileus group. The percentage of patients admitted to the intensive care unit was higher in the prolonged ileus group (73.3% vs 50.0%), but there was no significant difference between the two groups ( $P = .23$ ). The duration of stay in the intensive care unit was longer in the prolonged ileus group ( $28.6 \pm 22.6$  days vs  $8.8 \pm 5.5$  days;  $P = .08$ ), same as the total length of hospital stay ( $53.1 \pm 48.6$  days vs  $33.3 \pm 22.8$  days;  $P = .24$ ), but there were no statistically significant differences between the two groups (Table 2).

### 3.3. Risk factors for prolonged ileus

In the univariable analysis, the amount of PRBC transfusions was associated with risk of prolonged ileus ( $P = .03$ , OR = 1.57, 95% CI = 1.04–2.37). Further, in the multivariable logistic regression analysis, the amount of PRBC transfusions was the only variable independently associated with greater risk of prolonged ileus development ( $P = .03$ , OR = 2.04, 95% CI = 1.08–3.88) (Table 3).

## 4. Discussion

Pelvic ring injuries are associated with high mortality rates, mainly as result of massive bleeding.<sup>[5–7]</sup> Hemorrhage control is fundamental to improve the outcomes of patients with

**Table 2**  
Clinical outcomes.

	Total (N = 25)	Non-prolonged ileus (N = 10)	Prolonged ileus (N = 15)	P value
Duration of ileus (d)	5.2 ± 4.7	1.2 ± 0.4	8.0 ± 4.2	<.001
Mortality, N (%)	3 (12.0)	0	3 (20.0)	.13
PRBC transfusion	5.2 ± 2.5	3.8 ± 2.5	6.1 ± 2.1	.02
Massive transfusion, N (%)	13 (52.0)	3 (30.0)	10 (66.7)	.07
Vasopressor, N (%)	11 (44.0)	3 (30.0)	8 (53.3)	.25
Ventilator care, N (%)	8 (32.0)	0	8 (53.3)	.01
Tracheostomy, N (%)	6 (24.0)	0	6 (40.0)	.02
Admission to ICU, N (%)	16 (64.0)	5 (50.0)	11 (73.3)	.23
ICU stay (d)	22.4 ± 20.9	8.8 ± 5.5	28.6 ± 22.6	.08
Hospital stay (d)	45.2 ± 40.8	33.3 ± 22.8	53.1 ± 48.6	.24

ICU = intensive care unit, PRBC = packed red blood cell.

**Table 3**  
Multivariable logistic regression analysis for prolonged ileus in patients with traumatic pelvic bone fracture and who underwent arterial angio-embolization.

Variable	Univariable		Multivariable	
	OR (95% CI)	P value	OR (95% CI)	P value
Age (yr)	1.01 (0.97–1.06)	.57	1.06 (0.99–1.13)	.12
Sex (male)	0.58 (0.11–2.95)	.51	0.84 (0.11–6.63)	.87
BMI (kg/m <sup>2</sup> )	0.99 (0.86–1.14)	.93	1.05 (0.85–1.30)	.65
CCI	1.03 (0.78–1.37)	.82	0.84 (0.58–1.21)	.34
PRBC transfusion	1.57 (1.04–2.37)	.03	2.04 (1.08–3.88)	.03

BMI = body mass index, CCI = Charlson Comorbidity Index, CI = confidence interval, OR = odds ratio, PRBC = packed red blood cell.

hemodynamically unstable pelvic ring injuries, and immediate transfusions should be considered, if necessary. Delayed transfusions can in fact worsen the traumatic coagulopathy, which can lead to multiple organ failure, and eventually death.<sup>[29]</sup> Many studies have shown that severe pelvic ring injuries are associated with extensive bleeding, requiring more blood transfusions, and with higher death rates, especially if the posterior element of the pelvic ring is compromised.<sup>[30–33]</sup> A study by Wong et al<sup>[34]</sup> suggested that the amount of bleeding is related with the type of pelvic fracture. The Tile classification for pelvic fractures divides the fractures in three types: type A fractures are stable, type B fractures are rotationally unstable, but vertically stable, and type C fractures are rotationally and vertically unstable. According to Wong et al,<sup>[34]</sup> a high-energy Tile type C fracture causes more bleeding than a type A or B fracture, and therefore requires AAE more frequently. The severity of bleeding in type C fractures is often due to damage to the internal iliac artery. However, other studies showed no correlation between the pelvic fracture classification and bleeding, including arterial bleeding, or requirement for blood transfusions.<sup>[35–39]</sup> Likewise, our study did not show significant differences in results between amounts of transfusion according to each Tile classification. In addition, there was no significant association between the Tile classification and occurrence of prolonged ileus.

In about 85% of cases, the bleeding site in a pelvic injury is located in the venous plexus or the bone surface. Since arterial injuries and bleeding might be fatal, AAE is considered a crucial treatment to control the pelvic arterial bleeding.<sup>[8,9,40–42]</sup> Despite AAE, a complete control of bleeding may not be achieved due to the pelvic collateral circulation system.<sup>[43]</sup> Furthermore, even if the peritoneal cavity and the pelvic extraperitoneal space are

distinct compartments, anatomical studies have shown communication between the two.<sup>[44,45]</sup> Consequently, pelvic hemorrhage may transfer from the retroperitoneal pelvic area to the significantly larger abdominal cavity.<sup>[5,15]</sup> In our study, due to persistent bleeding after AAE, retroperitoneal packing or exploratory laparotomy was not performed. However, we had always considered that there might be persistent bleeding because of this anatomical structure.

Although it is not clear why ileus persists in traumatic pelvic ring injuries with retroperitoneal bleeding or hematoma, several hypotheses have been formulated.<sup>[17,18]</sup> The entire structure around the pelvis could be affected by the trauma, including the mesentery or other vascular structures connected with the small bowel, colon, or rectum. Bowel injuries or other vascular injuries can therefore affect the long-term bowel motility.<sup>[46]</sup> In addition, retroperitoneal hematoma can spread to the peritoneal surface, and interfere with the autonomic nervous system that supplies the intestinal tract. These events could cause suppression of the parasympathetic nervous system and hyperactivation of the sympathetic one, which would result in reduced motility of the bowel and persisting paralytic ileus.<sup>[47-49]</sup> Lastly, occurrence of ileus may be related to transfusion-related circulatory overload. Excess fluid accumulating in the intestinal wall can cause a decrease in the intestinal motility tract, leading to paralytic ileus.<sup>[50,51]</sup> Among these causes, the cause of prolonged ileus in the patients in our study could not be determined. One or all of the aforementioned causes might be the cause of the occurrence of prolonged ileus.

Although this study supports the idea of a connection between the amount of bleeding and prolonged ileus, it is important to highlight the limitations of this work. This study is a multicenter retrospective study conducted in two different hospitals. While the protocol remained the same, each institution had access to slightly different recording systems and facilities. Further, the small number of patients recruited may have limited the statistical power of the study. To overcome these limitations, a larger multicenter prospective study of pelvic trauma patients should be considered.

## 5. Conclusion

This study suggests that, in traumatic pelvic ring injury cases, the duration of the ileus may be related to the amount of bleeding. Severe pelvic trauma patients with massive bleeding are more at risk of prolonged ileus. Conservative management, such as appropriate nutritional support and nasogastric decompression, should be implemented in these cases to prevent further complications.

## Author contributions

**Conceptualization:** Chan-Hee Park, Suk-Kyoon Song.

**Data curation:** Chan-Hee Park, Jeong-Woo Lee, Beom-Soo Kim, Myung-Rae Cho, Suk-Kyoon Song.

**Formal analysis:** Jeong-Woo Lee, Suk-Kyoon Song.

**Supervision:** Myung-Rae Cho, Suk-Kyoon Song.

**Writing – original draft:** Chan-Hee Park, Suk-Kyoon Song.

**Writing – review & editing:** Chan-Hee Park, Beom-Soo Kim, Myung-Rae Cho, Suk-Kyoon Song.

## References

- [1] Grotz MRW, Allami MK, Harwood P, Pape HC, Krettek C, Giannoudis PV. Open pelvic fractures: epidemiology, current concepts of management and outcome. *Injury*. 2005;36:1–13.
- [2] Schmal H, Markmiller M, Mehlhorn AT, Sudkamp NP. Epidemiology and outcome of complex pelvic injury. *Acta Orthop Belg*. 2005;71:41–7.
- [3] Vaidya R, Scott AN, Tonnos F, Hudson I, Martin AJ, Sethi A. Patients with pelvic fractures from blunt trauma. What is the cause of mortality and when? *Am J Surg*. 2016;211:495–500.
- [4] Yoshihara H, Yoneoka D. Demographic epidemiology of unstable pelvic fracture in the United States from 2000 to 2009: trends and in-hospital mortality. *J Trauma Acute Care Surg*. 2014;76:380–5.
- [5] Costantini TW, Coimbra R, Holcomb JB, et al. Current management of hemorrhage from severe pelvic fractures: results of an American Association for the Surgery of Trauma multi-institutional trial. *J Trauma Acute Care Surg*. 2016;80:717–23; discussion 23–5.
- [6] Costantini TW, Coimbra R, Holcomb JB, et al. Pelvic fracture pattern predicts the need for hemorrhage control intervention—results of an AAST multi-institutional study. *J Trauma Acute Care Surg*. 2017;82:1030–8.
- [7] Papakostidis C, Giannoudis PV. Pelvic ring injuries with haemodynamic instability: efficacy of pelvic packing, a systematic review. *Injury*. 2009;40(Suppl 4):S53–61.
- [8] Lustenberger T, Wutzler S, Störmann P, Laurer H, Marzi I. The role of angio-embolization in the acute treatment concept of severe pelvic ring injuries. *Injury*. 2015;46(Suppl 4):S33–38.
- [9] Papakostidis C, Kanakaris N, Dimitriou R, Giannoudis PV. The role of arterial embolization in controlling pelvic fracture haemorrhage: a systematic review of the literature. *Eur J Radiol*. 2012;81:897–904.
- [10] Chapuis PH, Bokey L, Keshava A, et al. Risk factors for prolonged ileus after resection of colorectal cancer: an observational study of 2400 consecutive patients. *Ann Surg*. 2013;257:909–15.
- [11] Holte K, Kehlet H. Postoperative ileus: a preventable event. *Br J Surg*. 2000;87:1480–93.
- [12] Artinyan A, Nunoo-Mensah JW, Balasubramaniam S, et al. Prolonged postoperative ileus—definition, risk factors, and predictors after surgery. *World J Surg*. 2008;32:1495–500.
- [13] Fineberg SJ, Nandyala SV, Kurd MF, et al. Incidence and risk factors for postoperative ileus following anterior, posterior, and circumferential lumbar fusion. *Spine J*. 2014;14:1680–5.
- [14] Parvizi J, Han SB, Tarity TD, Pulido L, Weinstein M, Rothman RH. Postoperative ileus after total joint arthroplasty. *J Arthroplasty*. 2008;23:360–5.
- [15] Hurt AV, Ochsner JL, Schiller WR. Prolonged ileus after severe pelvic fracture. *Am J Surg*. 1983;146:755–7.
- [16] Levine JI, Crampton RS. Major abdominal injuries associated with pelvic fractures. *Surg Gynecol Obstet*. 1963;116:223–6.
- [17] Daniels AH, Ritterman SA, Rubin LE. Paralytic ileus in the orthopaedic patient. *J Am Acad Orthop Surg*. 2015;23:365–72.
- [18] Harms BA, Heise CP. Pharmacologic management of postoperative ileus: the next chapter in GI surgery. *Ann Surg*. 2007;245:364–5.
- [19] Roberts SR, Kennerly DA, Keane D, George C. Nutrition support in the intensive care unit. Adequacy, timeliness, and outcomes. *Crit Care Nurse*. 2003;23:49–57.
- [20] Viscusi ER, Gan TJ, Leslie JB, et al. Peripherally acting mu-opioid receptor antagonists and postoperative ileus: mechanisms of action and clinical applicability. *Anesth Analg*. 2009;108:1811–22.
- [21] ATLS Subcommittee; American College of Surgeons' Committee on Trauma; International ATLS Working Group. Advanced trauma life support (ATLS®): the ninth edition. *J Trauma Acute Care Surg*. 2013;74:1363–6.
- [22] Zong ZW, Bao QW, Liu HY, et al. Diagnosis and treatment of rare complications of pelvic fractures. *Chin J Traumatol*. 2016;19:199–205.
- [23] Loggers SAI, Koedam TWA, Giannakopoulos GF, Vandewalle E, Erwtaman M, Zuidema WP. Definition of hemodynamic stability in blunt trauma patients: a systematic review and assessment amongst Dutch trauma team members. *Eur J Trauma Emerg Surg*. 2017;43:823–33.
- [24] Patil V, Shetmahajan M. Massive transfusion and massive transfusion protocol. *Indian J Anaesth*. 2014;58:590–5.
- [25] Parry JA, Smith WR, Moore EE, Burlow CCC, Mauffrey C. The past, present, and future management of hemodynamic instability in patients with unstable pelvic ring injuries. *Injury*. 2021;52:2693–6.
- [26] Vather R, Trivedi S, Bissett I. Defining postoperative ileus: results of a systematic review and global survey. *J Gastrointest Surg*. 2013;17:962–72.
- [27] Tile M, Pennal GF. Pelvic disruption: principles of management. *Clin Orthop Relat Res*. 1980;56:64.
- [28] Scheyerer MJ, Osterhoff G, Wehrle S, Wanner GA, Simmen HP, Werner CM. Detection of posterior pelvic injuries in fractures of the pubic rami. *Injury*. 2012;43:1326–9.
- [29] Ohmori T, Matsumoto T, Kitamura T, et al. Scoring system to predict hemorrhage in pelvic ring fracture. *Orthop Traumatol Surg Res*. 2016;102:1023–8.

- [30] Gilliland MD, Ward RE, Barton RM, Miller PW, Duke JH. Factors affecting mortality in pelvic fractures. *J Trauma*. 1982;22:691–3.
- [31] McMurtry R, Walton D, Dickinson D, Kellam J, Tile M. Pelvic disruption in the polytraumatized patient: a management protocol. *Clin Orthop Relat Res*. 1980;22:30.
- [32] Cryer HM, Miller FB, Evers BM, Rouben LR, Seligson DL. Pelvic fracture classification: correlation with hemorrhage. *J Trauma*. 1988;28:973–80.
- [33] Looser KG, Crombie HD, Jr. Pelvic fractures: an anatomic guide to severity of injury. Review of 100 cases. *Am J Surg*. 1976;132:638–42.
- [34] Wong YC, Wang LJ, Ng CJ, Tseng IC, See LC. Mortality after successful transcatheter arterial embolization in patients with unstable pelvic fractures: rate of blood transfusion as a predictive factor. *J Trauma*. 2000;49:71–5.
- [35] Gruen GS, Leit ME, Gruen RJ, Peitzman AB. The acute management of hemodynamically unstable multiple trauma patients with pelvic ring fractures. *J Trauma* 1994;36:706–711; discussion 11–3.
- [36] Sarin EL, Moore JB, Moore EE, et al. Pelvic fracture pattern does not always predict the need for urgent embolization. *J Trauma*. 2005;58:973–7.
- [37] Tile M. Pelvic ring fractures: should they be fixed? *J Bone Joint Surg Br*. 1988;70:1–12.
- [38] Cook RE, Keating JF, Gillespie I. The role of angiography in the management of haemorrhage from major fractures of the pelvis. *J Bone Joint Surg Br*. 2002;84:178–82.
- [39] Tanizaki S, Maeda S, Matano H, Sera M, Nagai H, Ishida H. Time to pelvic embolization for hemodynamically unstable pelvic fractures may affect the survival for delays up to 60 min. *Injury*. 2014;45:738–41.
- [40] Lindahl J, Handolin L, Söderlund T, Porras M, Hirvensalo E. Angiographic embolization in the treatment of arterial pelvic hemorrhage: evaluation of prognostic mortality-related factors. *Eur J Trauma Emerg Surg*. 2013;39:57–63.
- [41] El-Haj M, Bloom A, Mosheiff R, Liebergall M, Weil YA. Outcome of angiographic embolisation for unstable pelvic ring injuries: factors predicting success. *Injury*. 2013;44:1750–5.
- [42] Durkin A, Sagi HC, Durham R, Flint L. Contemporary management of pelvic fractures. *Am J Surg*. 2006;192:211–23.
- [43] Evers BM, Cryer HM, Miller FB. Pelvic fracture hemorrhage. Priorities in management. *Arch Surg*. 1989;124:422–4.
- [44] O’Connell AM, Duddy L, Lee C, Lee MJ. CT of pelvic extraperitoneal spaces: an anatomical study in cadavers. *Clin Radiol*. 2007;62:432–8.
- [45] Aikawa H, Tanoue S, Okino Y, Tomonari K, Miyake H. Pelvic extension of retroperitoneal fluid: analysis in vivo. *AJR Am J Roentgenol*. 1998;171:671–7.
- [46] Shebrain S, Zelada J, Lipsky AM, Putnam B. Mesenteric injuries after blunt abdominal trauma: delay in diagnosis and increased morbidity. *Am Surg*. 2006;72:955–61.
- [47] Jain A, Vargas HD. Advances and challenges in the management of acute colonic pseudo-obstruction (ogilvie syndrome). *Clin Colon Rectal Surg*. 2012;25:37–45.
- [48] Carroll J, Alavi K. Pathogenesis and management of postoperative ileus. *Clin Colon Rectal Surg*. 2009;22:47–50.
- [49] Browning KN, Travagli RA. Central nervous system control of gastrointestinal motility and secretion and modulation of gastrointestinal functions. *Compr Physiol*. 2014;4:1339–68.
- [50] Thompson M, Magnuson B. Management of postoperative ileus. *Orthopedics*. 2012;35:213–7.
- [51] Luckey A, Livingston E, Taché Y. Mechanisms and treatment of postoperative ileus. *Arch Surg*. 2003;138:206–14.