

# Republication of “Primary Ankle Arthrodesis vs ORIF for Severely Comminuted Pilon Fractures: A Comparative Retrospective Study”

Foot & Ankle Orthopaedics  
2023, Vol. 8(3) 1–7  
© The Author(s) 2023  
DOI: 10.1177/24730114231193391  
journals.sagepub.com/home/fao

Colin H. Beckwitt, BS<sup>1</sup>, Spencer J. Monaco, DPM<sup>2</sup>, and Gary S. Gruen, MD<sup>3</sup>

**Commentary:** Level III, retrospective cohort study that found primary arthrodesis of the tibiotalar joint is a safe and reliable method to fix highly comminuted pilon fractures with significant cartilage impaction.

## Abstract

**Background:** The treatment for highly comminuted pilon fractures remains controversial. The goal of this retrospective cohort study was to compare functional outcomes of primary arthrodesis of the tibiotalar joint (fusion) and open reduction internal fixation (ORIF).

**Methods:** Patients who underwent primary ORIF or fusion for pilon fractures at our institution since 2000 were identified by *Current Procedural Terminology (CPT)* code. Inclusion criteria for the ORIF cohort were patients with an AO/Orthopaedic Trauma Association type C3 pilon fracture. Additional inclusion criteria for the fusion cohort were patients whose fractures were deemed non-reconstructable by the treating surgeon. Outcome assessment was determined by the Foot and Ankle Outcome Score (FAOS) and Short Form 36-item health survey (SF-36), time to radiographic union or fusion, and wound-healing complications at a minimum of 2 years after their surgery.

**Results:** Nineteen ORIF and 16 fusion patients completed the study's outcome assessments. A higher rate of nonunion was observed in patients treated by primary ORIF than primary fusion (5/19 vs 1/16). Posttraumatic arthritis was observed in 11 of 19 primary ORIF patients. Primary fusion patients exhibited increased symptoms, pain, and physical role limits but were equivalent to primary ORIF patients on all other functional metrics examined.

**Conclusions:** Primary ankle arthrodesis achieves a lower rate of nonunion and comparable functional outcomes to ORIF in patients with severely comminuted pilon fractures. The higher rate of nonunion observed in the primary ORIF group suggests that primary fusion should be considered an effective procedure for severe injuries to decrease the need for further operative intervention.

**Level of Evidence:** Therapeutic Level III, retrospective cohort.

**Keywords:** pilon fracture, arthrodesis, ORIF, plafond, AO/OTA type C3, trauma, outcome studies, retrospective cohort study

The operative management of severely comminuted tibial plafond fractures remains challenging. The most severe are classified by the AO/Orthopaedic Trauma Association (AO/OTA) as type C3 pilon fractures. These high-energy distal tibial fractures often present with substantial soft tissue injury and significant articular cartilage impaction.<sup>20</sup> In addition, these injuries commonly result in end-stage post-traumatic arthritis (PTA) or infection, prolonged return to work, significant pain, and the need for further operative

<sup>1</sup>Department of Pathology, University of Pittsburgh, School of Medicine, Pittsburgh, PA, USA

<sup>2</sup>Premier Orthopaedics, Kennett Square, PA, USA

<sup>3</sup>Department of Orthopaedic Surgery, University of Pittsburgh Medical Center, Pittsburgh, PA, USA

This article was originally published as: Beckwitt CH, Monaco SJ, Gruen GS. Primary ankle arthrodesis vs ORIF for severely comminuted pilon fractures: a comparative retrospective study. *Foot Ankle Orthop.* 2018 Aug 2;3(3):2473011418780437. doi:10.1177/2473011418780437.



intervention, including amputation.<sup>3</sup> Previous studies in patients with type B3 to C3 pilon fractures reported daily pain experienced by up to 66% of patients.<sup>25</sup>

The literature remains conflicted on the best treatment for patients with the most severe articular disruption. Some authors argue for definitive external fixation with an Ilizarov ring fixator.<sup>11</sup> However, external fixation carries a pin site infection risk between 4.5% and 71%<sup>6</sup> and can increase the rate of malunion or nonunion.<sup>22</sup> With external fixation alone, the articular reduction is extremely difficult to restore and maintain without formal open reduction internal fixation (ORIF). Staged treatment using bridging external fixation followed by definitive internal fixation presents lower infection risk than external fixation and fewer wound complications than acute ORIF.<sup>2,10,19</sup> However, even with adequate reduction, rates of nonunion and PTA can be as high as 70%<sup>28</sup> and 81%,<sup>3</sup> respectively.

Historically, ankle arthrodesis was reserved for patients failing to achieve union by ORIF.<sup>16</sup> Recently, arthrodesis using a posterior blade plate has been explored as a primary treatment in a unique subset of patients with severe articular impaction.<sup>3,28</sup> Alternatively to this method, other authors have reported on retrograde nails. Although this approach can be effective at achieving ankle fusion, this procedure sacrifices the subtalar joint.<sup>18</sup> Previously, a cohort of 20 patients who underwent primary arthrodesis for type C2 or type C3 pilon fractures was shown to exhibit functional outcomes comparable to historical controls in the literature who received primary ORIF.<sup>28</sup>

The purpose of this study is to compare primary ankle arthrodesis with patients who received primary ORIF for a subset of type C3 pilon fractures at a single institution. We hypothesize that primary ORIF will yield better functional outcomes than primary arthrodesis for highly comminuted type C3 pilon fractures due to preservation of the tibiotalar joint.

## Materials and Methods

### Patients

Approval to conduct this study was received from our institutional review board. Patient databases were obtained from our institution for patients undergoing treatment for closed (*International Classification of Diseases, Ninth Revision [ICD-9]*: 824.8) and open (*ICD-9*: 824.9) ankle fractures. Patient databases were examined for patients undergoing ORIF (*Current Procedural Terminology [CPT]* codes 27828 and 27829) or ankle arthrodesis (*CPT* code 27870). Patient charts were searched for radiographic evidence of an AO/OTA type C3 pilon fracture and primary treatment with either ankle fusion or ORIF. Inclusion criteria for the ORIF cohort were patients with an AO/OTA type C3 pilon fracture. Additional inclusion criteria

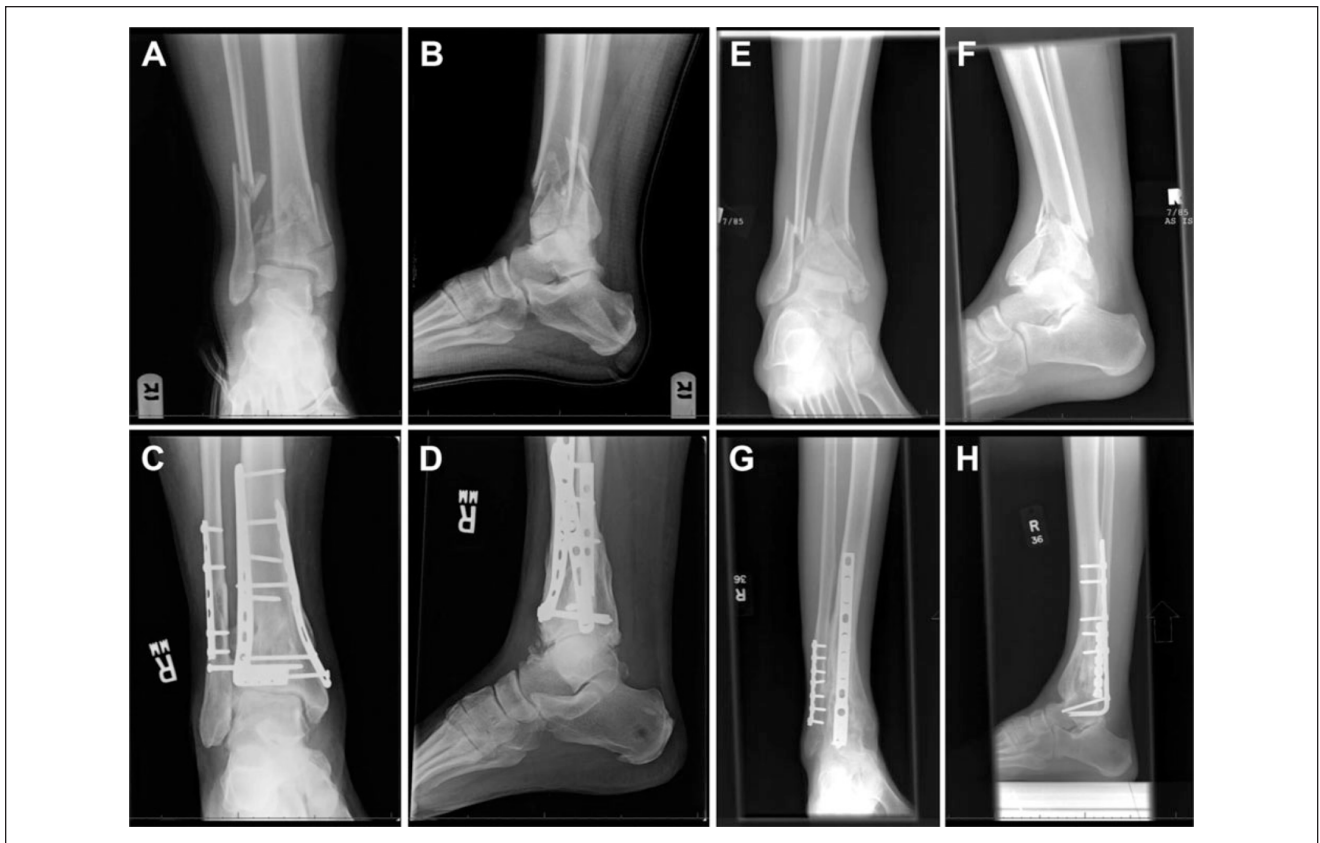for the fusion cohort were patients whose fractures were deemed non-reconstructable by the treating surgeon, which exhibited extensive comminution and marked cartilage impaction at the tibiotalar surface. Patients who underwent definitive ORIF or fusion more than 30 days after their initial injury were excluded from this study. Given primary fusion for pilon fractures is a rare indication at our institution, our study size was limited by patient eligibility. As such, our study design entailed assessing a similar number of primary ORIF patients as primary fusion patients to compare the 2 treatment modalities.

Sixteen fusion patients (11 male and 5 female) and 19 ORIF patients (13 male and 6 female), representing the primary fusion and primary ORIF cohorts, respectively, met the eligibility criteria of the study and returned completed functional outcome assessments. The average patient age was  $38.7 \pm 17.1$  years in the primary fusion cohort and  $45.2 \pm 12.9$  years in the primary ORIF cohort ( $P = .221$ ). All pilon fractures in both cohorts were classified as AO/OTA type C3. Representative radiographic images are shown for pre- and postoperative type C3 pilon fractures treated with either primary ORIF (Figure 1A-D) or fusion (Figure 1E-H). Five patients in the fusion cohort and 4 patients in the ORIF cohort had open fractures, as classified by Gustilo and Anderson,<sup>12</sup> ranging from type I to type III-B.

### Operative Treatment

Patients underwent primary ORIF or ankle fusion at the discretion of the treating surgeon. Four surgeons contributed patients to this study. Standard techniques for ORIF were used and have been extensively described in the literature.<sup>27</sup> Primary ankle fusion was performed through a posterior approach with the patient prone for anatomic reduction and joint preparation. Fixation consisted of a posterior blade plate, which was chosen over other hardware for multiple reasons. First, in contrast to other plates, the blade plate is a fixed angle device. Upon correct insertion into the talus, parallel to its axis, the tibia achieves proper alignment. Use of nonfixed angle devices cannot guarantee the correct orientation of the distal tibia and ankle, and these constructs eventually collapse. Second, in contrast to a tibiotalar nail, the blade plate facilitates primary healing, which is necessary as the limited blood flow from the surrounding soft tissues does not allow for secondary healing. In addition, the blade plate does not compromise the subtalar joint. Sagittal and coronal plane intraoperative fluoroscopy were used to judge alignment.

The tibiotalar joint was packed with posterior iliac crest autograft for all fusion patients. Five primary ORIF patients received autograft, all during secondary operative intervention for primary nonunion. Three of these 5 patients receiving autograft were supplemented with bone morphogenetic



**Figure 1.** Preoperative and follow-up radiographic evaluation. Anteroposterior (A, C, E, G) and lateral (B, D, F, H) radiographs of type C3 pilon fractures upon presentation (A, B, E, F) or after 7 years of follow-up after primary open reduction internal fixation (C, D) or 6 years of follow-up after primary fusion (G, H).

protein (BMP) when there were large osseous voids. Thirteen primary fusion patients underwent temporary external fixation. The other 3 primary fusion patients were initially splinted to allow for soft tissue swelling to diminish. Seventeen primary ORIF patients underwent temporary external fixation, whereas 2 received immediate plate fixation due to adequate soft tissue status. Plate fixation of the fibula was done in 16 primary ORIF patients. Of the remaining 3 ORIF patients, 2 did not have a fibula fracture.

### Outcome Assessment

Demographic patient data were collected from patients' charts. Collected parameters included age, sex, mechanism of injury, fracture pattern, open or closed fracture, and associated comorbidities. Operative parameters were also collected, including use of a temporary external fixator, use of bone graft, fixation of associated fibula fracture, and date of primary definitive treatment. Fracture pattern was classified according to the AO/OTA classification system. Open fractures were classified by the Gustilo-Anderson classification system.<sup>12</sup>

Definitive outcome measurements were made at a minimum of 2 years of follow-up. Parameters collected to assess postoperative recovery included time to union or ankle fusion, follow-up time, ambulation status, wound complications, presence of posttraumatic arthritis, and other operative complications. Functional outcomes were measured using 2 health surveys, the Short Form 36-item health survey (SF-36) and the Foot and Ankle Outcome Score (FAOS) survey. Follow-up time was defined as the period between the patient's completion of the SF-36 and FAOS surveys and his or her initial definitive operative procedure (ORIF or fusion). Both the SF-36 and FAOS are well-validated surveys to determine health-related quality of life. In particular, the FAOS is a useful tool for assessing outcomes in foot and ankle disorders,<sup>9</sup> albeit imperfect.<sup>14</sup> Importantly, the FAOS has been previously used as the primary outcome assessment for function in patients with type C pilon fractures treated by ORIF.<sup>8</sup>

Radiographic outcomes were determined by anteroposterior, lateral, and mortise views of the ankle made at the latest follow-up visit. In addition to evaluation by the treating surgeon, the radiographs were evaluated by an

independent radiologist to address this as a potential source of bias. Nonunion was defined as failure to achieve definitive union accompanied by absence of progressive healing on serial radiographs. Posttraumatic arthritis was determined by both clinical and radiographic evaluation.

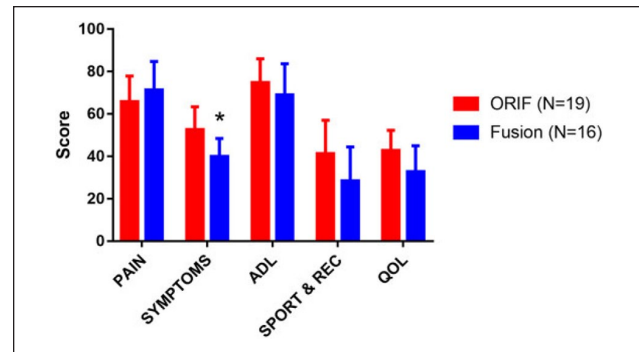
### Statistics

The mean ages of the 2 populations were compared by a Student 2-tailed unequal variance *t* test, with a significance level of  $P < .05$ . Union rates were compared with a Fisher exact test, with a significance level of  $P < .05$ . SF-36 and FAOS raw responses were converted to subscale scores on a scale of 0 to 100, with a score of 100 indicating the best possible outcome. Unanswered questions in the FAOS surveys were addressed by scaling the maximum points for a subscale with respect to the number of questions answered. Unanswered questions in the SF-36 surveys did not influence the scoring. The SF-36 subscale scores were further transformed into mental and physical component summary scores, which similarly range from 0 to 100 points. Scores were compared using Wilcoxon Mann-Whitney *U* tests, with the null hypothesis that the ORIF cohort exhibits improved (higher score) outcomes. Significance levels are indicated in the figures, and their absence denotes that no significant difference between the 2 cohorts could be detected given the number of patients available for outcome analysis. Scatterplots for pain scores obtained by SF-36 and FAOS were linearly fitted using GraphPad Prism 7 (GraphPad Software, La Jolla, CA), and the fit parameters and goodness of fit ( $R^2$ ) are reported.

## Results

### Operative Complications

Operative complications in the primary fusion cohort included 1 deep vein thrombosis (all patients received baseline anticoagulation). One patient had postoperative cellulitis that resolved upon wound care and antibiotic therapy. Operative complications in the ORIF cohort included 2 patients requiring implant removal. One patient developed severe regional pain syndrome requiring extensive medical management. Nonunion was observed in 1 of 16 patients in the fusion cohort and 5 of 19 patients in the ORIF cohort ( $P = .11$ ). One primary ORIF patient who experienced primary nonunion underwent secondary arthrodesis by application of an Ilizarov external fixator. One nonunion in the ORIF cohort was complicated by a history of diabetes. No cases of nonunion were associated with clinical signs of infection, such as elevated inflammatory markers, erythema, or draining wounds. Eleven of 19 patients in the ORIF cohort had developed posttraumatic ankle arthritis by their most recent follow-up visit. All patients in both cohorts adequately



**Figure 2.** Outcomes reported by the Foot and Ankle Outcome Score (FAOS). FAOS scores for the open reduction internal fixation (ORIF) patient cohort ( $n = 19$ ) and fusion patient cohort ( $N = 16$ ). Data are represented as the mean score, with error bars representing 95% CI. Populations were compared using Wilcoxon Mann-Whitney rank sum to determine significant differences between scores for each category. ADL, activities of daily living; QOL, quality of life; Rec, recreation. \* $P < .05$ .

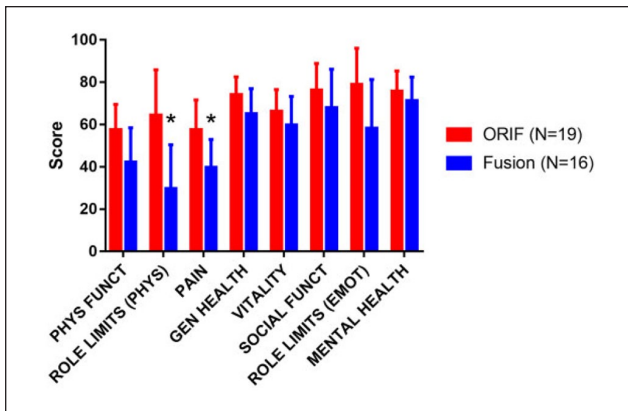
healed their operative wounds without evidence of infection or need for further operative intervention.

### Survey Completion and Time to Union

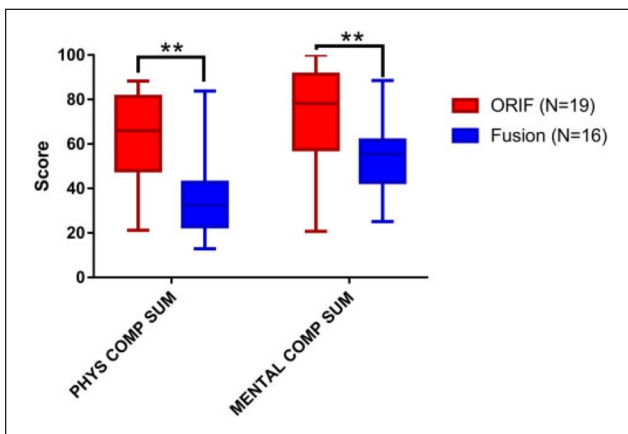
Nineteen primary ORIF patients and 16 primary fusion patients completed the SF-36 and FAOS forms. All patients had at least 2 years of follow-up since their procedure. Mean follow-up time was 5.5 years (range, 2-9 years) for the ORIF cohort and 6.9 years (range, 2-13 years) for the fusion cohort. Union was achieved from the primary procedure in 14 of 19 ORIF patients and 15 of 16 primary fusion patients. Average time to union or fusion was longer in the ORIF cohort (208 vs 132 days). Upon further analysis, 1 fusion patient and 1 ORIF patient were found to be significant outliers with regard to fusion time, defined as being greater than the third quartile by at least 1.5 times the inner-quartile range. Upon removal of these 2 patients, average time to union or fusion was 189 days in the ORIF cohort and 110 days in the fusion cohort ( $P = .007$ ). All patients were ambulatory at the most recent follow-up visit.

### FAOS and SF-36 Scores Comparable Between Primary Fusion and ORIF

FAOS and SF-36 form responses were compiled for each cohort. For FAOS, scores for the categories of pain, ankle symptoms, activities of daily living (ADL), sports and recreation (SPORT & REC), and quality of life (QOL) are reported (Figure 2). The only significant difference observed was more severe symptoms in the fusion cohort. For SF-36, scores for physical functioning, physical role limits, pain, general health, vitality, social functioning, emotional role

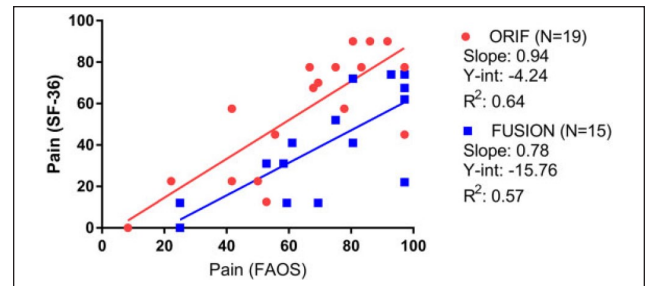


**Figure 3.** Outcomes reported by the Short Form 36-item health survey (SF-36). SF-36 scores for the open reduction internal fixation (ORIF) patient cohort ( $n = 19$ ) and fusion patient cohort ( $n = 16$ ). Data are represented as the mean score, with error bars representing 95% CI. Populations were compared using Wilcoxon Mann-Whitney rank sum to determine significant differences between scores for each category. Emot, emotional; Funct, function; Gen, general; Phys, physical.  $*P < .05$ .



**Figure 4.** Short Form 36-item health survey (SF-36) calculated summary scores. Scores for the open reduction internal fixation (ORIF) patient cohort ( $n = 19$ ) and fusion patient cohort ( $n = 16$ ) are represented by the inner-quartile range (box) and mean (line), with error bars representing the range of the data. Populations were compared using Wilcoxon Mann-Whitney rank sum to determine significant differences between scores for each category. Comp, component; Phys, physical; Sum, summary.  $**P < .01$ .

limits, and mental health are reported (Figure 3). The only 2 significant differences observed were more severe physical role limits and pain in the fusion cohort. SF-36 summary scores were generated and compared between the 2 cohorts (Figure 4). Both physical and mental component summary scores were significantly lower in the fusion cohort.



**Figure 5.** Correlation between pain scores reported by Foot and Ankle Outcome Score (FAOS) and the Short Form 36-item health survey (SF-36). Pain scores for the open reduction internal fixation (ORIF) patient cohort ( $n = 19$ ) and fusion patient cohort ( $n = 15$ ) as assessed by FAOS and SF-36 were plotted against each other. Linear regression analysis for each cohort was performed. The slope, y-intercept (Y-int), and coefficient of determination ( $R^2$ ) for each fit are reported below its respective population. The slope demonstrates the amount to which patients report similar pain on FAOS and SF-36, with a slope of 1.0 signifying equivalent pain by both surveys, a slope more than 1.0 signifying more intense pain by FAOS, and a slope less than 1.0 signifying more intense pain by SF-36.

#### Primary Fusion Patients Report More Intense Pain by SF-36 Than FAOS

Since both FAOS and SF-36 assess pain, we were interested if pain was reported similarly by both surveys. To determine this, we linearly correlated pain scores reported by FAOS and SF-36 for each treatment modality (Figure 5). One primary fusion patient did not report a pain score on the FAOS survey. Pain reported by SF-36 and FAOS was positively correlated, with  $R^2$  values of 0.64 and 0.57 for primary ORIF and fusion, respectively. While primary ORIF patients reported a similar degree of pain by both SF-36 and FAOS forms, patients who underwent primary fusion reported more intense pain by SF-36 as compared to FAOS. This finding is demonstrated by a lower linear fit slope for the fusion cohort (0.78) than the ORIF cohort (0.94), with a slope of 1.0 signifying pain was reported equally by both surveys (Figure 5).

## Discussion

Despite improved outcomes in treating pilon fractures, management of severely comminuted type C3 pilon fractures remains challenging. While fractures can safely be reduced using staged ORIF, reported functional recovery is poor.<sup>20</sup> Type C pilon fracture patients experience worse health outcomes than those with tibial plateau or pelvic fractures, acute myocardial infarction, or AIDS.<sup>21,23</sup> In addition, while mental component scores are equivalent to age-matched norms 6 months after injury, physical component scores are a standard deviation lower after 2 years.<sup>15</sup> Finally,

the incidence of PTA increases between 2 and 10 years of follow-up, suggesting evolving morbidity for this select patient population.<sup>7</sup>

Due to the high incidence of PTA and pain that result from highly comminuted pilon fractures, we sought to explore arthrodesis as the primary treatment for a very unique subset of patients with significant articular comminution and impaction. Previously, we found comparable outcomes in our primary fusion cohort and historical primary ORIF controls.<sup>28</sup> However, this comparison lacked statistical robustness (historical controls did not report variance), did not account for interinstitutional variability, and included several patients with type C2 fracture patterns, which do not present with as much articular comminution as type C3 injuries.

In contrast to our hypothesis, outcomes for primary ORIF and primary fusion were similar for many FAOS and SF-36 subscales. For the FAOS survey, we found equivalent outcomes in 4 of the 5 subscales (Figure 2). While primary fusion patients reported worse ankle symptoms, no significant difference in pain, quality of life, sports and recreation, or activities of daily living was observed. Likely, the more severe symptoms experienced by primary fusion patients can be attributed to compromised movement at the tibiotalar joint, probed by 3 of the 5 questions for this subscale.

Similarly, we saw equivalent outcomes in 6 of the 8 subscales for the SF-36 between the primary fusion and primary ORIF cohorts (Figure 3). While primary fusion patients reported more severe physical role limits and pain, all mental health, physical function, and general health subscales were equivalent between both groups. Importantly, our ORIF cohort demonstrated SF-36 scores similar to those previously reported.<sup>21</sup> Upon calculating SF-36 summary scores, both physical and mental component summary scores were significantly higher in the ORIF cohort (Figure 4). Since all primary fusion patients were deemed non-reconstructable, the baseline level of injury is likely worse for patients who undergo primary fusion compared to ORIF.

Interestingly, while pain reported by FAOS was equivalent between ORIF and fusion cohorts, pain reported by SF-36 was significantly worse in the primary fusion cohort. To determine whether patients report pain differently on the 2 surveys, we linearly correlated pain scores determined by SF-36 and FAOS (Figure 5). While ORIF patients reported pain similarly on both surveys (linear slope of 0.94), primary fusion patients reported more severe pain on the SF-36 survey (linear slope of 0.78). Pain scores are calculated from 9 question prompts in the FAOS survey, which specifically gauge pain by ankle position and movement in the past week.<sup>17</sup> In contrast, SF-36 scores are calculated from 2 questions that gauge the degree of physical pain experienced in the past 4 weeks and its interference with normal work.<sup>26</sup> Since the SF-36 questions do not assess ankle-specific pain, FAOS may be more useful to assess pain resulting from pilon fractures and their treatment.

When deciding between primary fusion and ORIF in severe pilon fractures, one must consider the patient prognostic course and the role of the vascular supply of the distal tibia in achieving union. More than half of high-energy pilon fractures present with vascular insult to the distal tibia<sup>13</sup> that is further jeopardized upon ORIF and may increase the risk of infection or nonunion.<sup>4,5</sup> In this study, we observed nonunion in 5 of 19 primary ORIF patients and 1 of 16 primary fusion patients, all of whom required further operative intervention. However, routine use of autogenous bone graft was used in all patients undergoing primary fusion. While the difference in union rate was not statistically significant with the number of patients available for analysis, these data suggest arthrodesis may yield lower rates of nonunion compared to ORIF. Our rate of nonunion for primary ORIF is similar to rates reported in the literature.<sup>1,24</sup> The current study did not assess alignment as an outcome measure.

One major strength of the present study is the use of 2 functional health surveys to determine recovery after primary fusion or ORIF. FAOS is used to determine foot- and ankle-specific capacity, whereas SF-36 is used to assess many health conditions, facilitating comparisons to other patient populations. Another strength of this study is the use of robust statistical analysis to determine differences between these 2 patient cohorts. One weakness of this study is the relatively small sample size and varied nature of the accompanying treatment to the definitive fixation method. The sample size was severely limited by the number of patients undergoing primary arthrodesis at our institution, as this is a salvage procedure. Moreover, primary arthrodesis with blade plate fixation precludes ankle arthroplasty in a select group of patients with well-aligned pilon fractures that progress to posttraumatic arthritis. Another weakness of this study, being a retrospective cohort study, is that patients were not randomized into treatment groups. Since patients undergoing primary fusion were deemed non-reconstructable, their initial prognosis may be worse than those undergoing primary ORIF. A final weakness of the study is the presence of confounding factors in our 2 populations. While these 2 measures did not achieve statistical significance, the ORIF cohort was numerically younger in age and had a higher rate of nonunion, which could affect our outcome assessments.

In summary, we suggest that primary arthrodesis of the tibiotalar joint is a safe and reliable method to fix highly comminuted pilon fractures in a unique subset of patients with significant cartilage impaction. This approach allows for rigid stabilization of the tibiotalar joint through fusion in cases of extreme articular comminution. Despite more severe injuries in patients receiving primary fusion than those in whom reconstruction could be attempted, the functional outcomes between both patient populations are similar. Moreover, as we observed more nonunions in our

ORIF cohort, primary fusion should be considered in a tailored subset of patients as definitive treatment to reduce the need for further operative management and lessen long-term morbidity.

### Acknowledgments

We thank Dana Farrell for her valuable contributions to this study.

### Declaration of Conflicting Interests

The author(s) declared no potential conflicts of interest with respect to the research, authorship, and/or publication of this article. ICMJE forms for all authors are available online.

### Funding

The author(s) received no financial support for the research, authorship, and/or publication of this article.

### References

- Bacon S, Smith WR, Morgan SJ, et al. A retrospective analysis of comminuted intra-articular fractures of the tibial plafond: open reduction and internal fixation versus external Ilizarov fixation. *Injury*. 2008;39(2):196-202.
- Barei D. Pilon fractures. In: Sethi MK, Obremskey WT, Jahangir AA, eds. *Orthopedic Traumatology: An Evidence-Based Approach*. New York, NY: Springer; 2013:323-343.
- Beaman DN, Gellman R. Fracture reduction and primary ankle arthrodesis: a reliable approach for severely comminuted tibial pilon fracture. *Clin Orthop Relat Res*. 2014;472(12):3823-3834.
- Borrelli J Jr, Prickett W, Song E, Becker D, Ricci W. Extraosseous blood supply of the tibia and the effects of different plating techniques: a human cadaveric study. *J Orthop Trauma*. 2002;16(10):691-695.
- Browner B, Jupiter J, Krettek C. *Skeletal Trauma: Basic Science, Management, and Reconstruction*. 5th ed. Philadelphia, PA: Elsevier; 2014.
- Cavusoglu AT, Er MS, Inal S, Ozsoy MH, Dincel VE, Sakaogullari A. Pin site care during circular external fixation using two different protocols. *J Orthop Trauma*. 2009;23(10):724-730.
- Chen SH, Wu PH, Lee YS. Long-term results of pilon fractures. *Arch Orthop Trauma Surg*. 2007;127(1):55-60.
- Duckworth AD, Jefferies JG, Clement ND, White TO. Type C tibial pilon fractures: short- and long-term outcome following operative intervention. *Bone Joint J*. 2016;98B(8):1106-1111.
- Golightly YM, DeVellis RF, Nelson AE, et al. Psychometric properties of the Foot and Ankle Outcome Score in a community-based study of adults with and without osteoarthritis. *Arthritis Care Res (Hoboken)*. 2014;66(3):395-403.
- He X, Hu Y, Ye P, Huang L, Zhang F, Ruan Y. The operative treatment of complex pilon fractures: a strategy of soft tissue control. *Indian J Orthop*. 2013;47(5):487-492.
- Jacob N, Amin A, Giotakis N, Narayan B, Nayagam S, Trompeter AJ. Management of high-energy tibial pilon fractures. *Strateg Trauma Limb Reconstr*. 2015;10(3):137-147.
- Kim PH, Leopold SS. Gustilo-Anderson classification. *Clin Orthop Relat Res*. 2012;470(11):3270-3274.
- LeBus GF, Collinge C. Vascular abnormalities as assessed with CT angiography in high-energy tibial plafond fractures. *J Orthop Trauma*. 2008;22(1):16-22.
- Mani SB, Do H, Vulcano E, et al. Evaluation of the foot and ankle outcome score in patients with osteoarthritis of the ankle. *Bone Joint J*. 2015;97B(5):662-667.
- Marsh JL, McKinley T, Dirschl D, et al. The sequential recovery of health status after tibial plafond fractures. *J Orthop Trauma*. 2010;24(8):499-504.
- Morgan SJ, Thordarson DB, Shepherd LE. Salvage of tibial pilon fractures using fusion of the ankle with a 90 degrees cannulated blade-plate: a preliminary report. *Foot Ankle Int*. 1999;20(6):375-378.
- Negahban H, Mazaheri M, Salavati M, et al. Reliability and validity of the Foot and Ankle Outcome Score: a validation study from Iran. *Clin Rheumatol*. 2010;29(5):479-486.
- Ochman S, Evers J, Raschke MJ, Vordemvenne T. Retrograde nail for tibiototalcaneal arthrodesis as a limb salvage procedure for open distal tibia and talus fractures with severe bone loss. *J Foot Ankle Surg*. 2012;51(5):675-679.
- Patterson MJ, Cole JD. Two-staged delayed open reduction and internal fixation of severe pilon fractures. *J Orthop Trauma*. 1999;13(2):85-91.
- Penny P, Swords M, Heisler J, Cien A, Sands A, Cole P. Ability of modern distal tibia plates to stabilize comminuted pilon fracture fragments: is dual plate fixation necessary? *Injury*. 2016;47(8):1761-1769.
- Pollak AN, McCarthy ML, Bess RS, Agel J, Swiontkowski MF. Outcomes after treatment of high-energy tibial plafond fractures. *J Bone Joint Surg Am*. 2003;85A(10):1893-1900.
- Richards JE, Magill M, Tressler MA, et al. External fixation versus ORIF for distal intra-articular tibia fractures. *Orthopedics*. 2012;35(6):e862-e867.
- Sands A, Grujic L, Byck DC, Agel J, Benirschke S, Swiontkowski MF. Clinical and functional outcomes of internal fixation of displaced pilon fractures. *Clin Orthop Relat Res*. 1998;347:131-137.
- Teeny SM, Wiss DA. Open reduction and internal fixation of tibial plafond fractures: variables contributing to poor results and complications. *Clin Orthop Relat Res*. 1993;292:108-117.
- Van Den Berg J, Monteban P, Roobroeck M, Smeets B, Nijs S, Hoekstra H. Functional outcome and general health status after treatment of AO type 43 distal tibial fractures. *Injury*. 2016;47(7):1519-1524.
- Ware JE, Snow KK, Kosinski M, Gandek B. SF-36 health survey manual and interpretation guide. 1993. [http://books.google.com/books/about/SF\\_36\\_health\\_survey.html?id=WJsgAAAAMAAJ](http://books.google.com/books/about/SF_36_health_survey.html?id=WJsgAAAAMAAJ). Accessed July 16, 2016.
- White TO, Guy P, Cooke CJ, et al. The results of early primary open reduction and internal fixation for treatment of OTA 43.C-type tibial pilon fractures: a cohort study. *J Orthop Trauma*. 2010;24(12):757-763.
- Zelle BA, Gruen GS, McMillen RL, Dahl JD. Primary arthrodesis of the tibiotalar joint in severely comminuted high-energy pilon fractures. *J Bone Joint Surg Am*. 2014;96(11):e91.