



Contents lists available at ScienceDirect

International Journal of Surgery Case Reports

journal homepage: www.casereports.com

Wide local excision for anal GIST: A case report and review of literature



Mohamed Azzaza^a, Housseem Ammar^a, Nihed Abdessayed^b, Rahul Gupta^c,
Mohamed Said Nakhli^{d,*}, Amine Chhaider^a, Nafis Abdennaceur^a, Ali Ben Ali^a

^a Department of Digestive Surgery, Hospital Sahloul, Sousse, Tunisia^b Department of Pathology, Farhat Hached Hospital, Sousse, Tunisia^c Department of HPB Surgery, CARE Hospital, Hyderabad, India^d Department of Anaesthesia, Hospital Sahloul, Sousse, 4011, Tunisia

ARTICLE INFO

Article history:

Received 11 November 2016

Received in revised form

22 November 2016

Accepted 23 November 2016

Available online 2 December 2016

Keywords:

Gastrointestinal stromal tumor

Anal canal

Abdominoperineal resection

ABSTRACT

INTRODUCTION: Gastrointestinal stromal tumors (GIST) are tumors of mesenchymal origin commonly detected in stomach and small bowel. GIST arising primarily from the anal canal is extremely rare. Due to the malignant potential, these tumors are treated with radical surgery like abdominoperineal resection. But with the advent of imatinib therapy and a better understanding of the tumor biology, some cases have been successfully treated with wide local excision.

PRESENTATION OF CASE: We describe a case of a 70-year-old lady presenting with a 2 cm mass in the anal canal. Endoanal ultrasound revealed a well-circumscribed solid nodule in the intersphincteric space. The patient was successfully treated by wide local excision and adjuvant therapy with imatinib mesylate.

DISCUSSION: Only 14 confirmed cases of primary anal GIST have been reported in the literature. It appears as a well circumscribed hypoechoic mass arising from the intersphincteric space encroaching into the lumen on endorectal ultrasound. Lymphadenopathy is absent. Anal sphincters get involved as the lesion increases in size. Treatment is often planned based on the extent of the disease, the mitotic rate, patient's general condition and willingness for a permanent colostomy.

CONCLUSION: Small lesions (<2 cm) with low mitotic rate may be successfully managed by local excision. Radical surgery should be reserved for large, aggressive tumors.

© 2016 The Authors. Published by Elsevier Ltd on behalf of IJS Publishing Group Ltd. This is an open access article under the CC BY-NC-ND license (<http://creativecommons.org/licenses/by-nc-nd/4.0/>).

1. Introduction

Gastrointestinal stromal tumor (GIST) is the most frequent gastrointestinal mesenchymal tumor [1]. The most common sites for GIST to occur are stomach, esophagus, and anorectum [2]. GIST of anorectum accounts for 5% of all cases [3]. Anal region is the primary site of origin in only 2% of all anorectal GIST cases [3]. Due to its potential for malignant behavior, most of the previously reported cases were treated by radical surgery such as abdominoperineal resection (APR) and pelvic exenteration [4–10]. But some anecdotal cases have been treated successfully by local excision [1,11,12]. Whether it is oncologically acceptable to perform local excision for anal GIST is not known. In order to gain further insight into the optimal therapeutic option, we report a case of anal GIST in

an elderly female managed successfully by local excision and adjuvant imatinib mesylate therapy and perform a brief review of the literature.

2. Case description

A 70 years old lady, a known case of atrial fibrillation taking oral anticoagulants, presented with a mass at the anal margin for 4 months. The mass was gradually increasing in size. There was no associated hematochezia, malena, bowel dysfunction or weight loss. On examination, there was an oval mass of 2 cm diameter at the anal margin, greyish white in appearance, at 7 o'clock position (Fig. 1). On digital rectal examination, the mass was firm in consistency extending up to the anal canal. The lesion was mobile with no signs of invasion of the underlying anal sphincters. Rectal mucosa appeared normal. There was no inguinal lymphadenopathy, Virchow's node, ascites or palpable abdominal mass.

On endosonography, the mass appears as a 2 cm well defined hypoechoic lesion extending upto the intersphincteric plane. The outer boundary of the tumor was regular and smooth. There was no

Abbreviations: APR, abdominoperineal resection; CT, computed tomography; ERUS, endorectal ultrasound; GIST, gastrointestinal stromal tumor.

* Corresponding author.

E-mail address: mohamedsaid.nakhli@rns.tn (M.S. Nakhli).

<http://dx.doi.org/10.1016/j.ijscr.2016.11.046>

2210-2612/© 2016 The Authors. Published by Elsevier Ltd on behalf of IJS Publishing Group Ltd. This is an open access article under the CC BY-NC-ND license (<http://creativecommons.org/licenses/by-nc-nd/4.0/>).

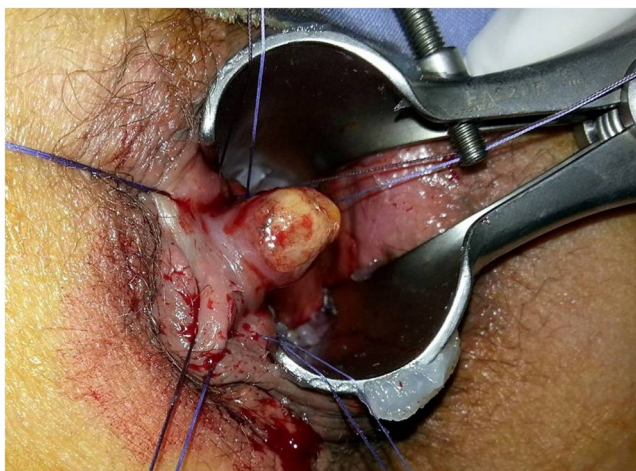

Fig. 1. Per anal examination showing the exophytic mass of 2 cm arising from the anal canal at 7'o clock position.

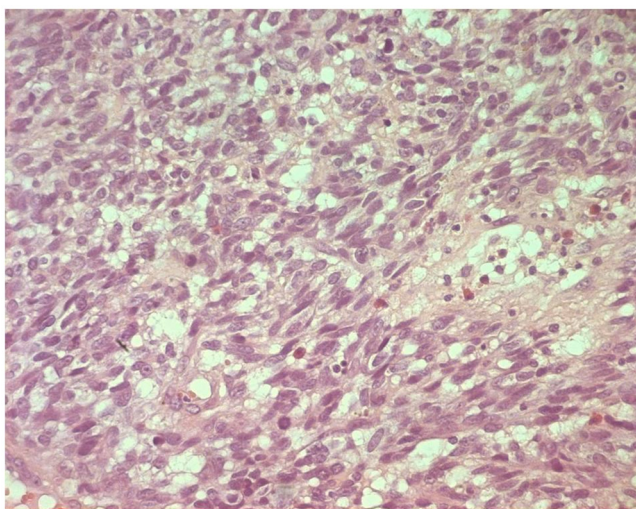


Fig. 2. Histopathological examination showing spindle shaped tumor cells arranged in diverging bundles. The cells have clear vacuoles. (H&E 200).

sign of infiltration of the external anal sphincter. The lesion seemed to be arising from the upper portion of the internal anal sphincter. No satellite lesion or lymphadenopathy was identified. The rectal wall and mesorectum were normal. Colonoscopy did not reveal any other lesion. Computed tomography (CT) of chest, abdomen, and pelvis ruled out distant lung or liver metastases. The routine tumor markers were negative.

Based on the general condition of the patient and the localized nature of the disease decision for wide local excision was planned. Patient consent was taken after explaining her risks and benefits of the procedure. Under general anesthesia, the patient was placed in the lithotomy position and wide local excision was performed including some muscle fibers of the internal anal sphincter in order to achieve clear margin. The postoperative course was uneventful.

On the cut surface, the lesion was greyish white in color and measured $2 \times 1.5 \times 2$ cm in size. On microscopic examination, the anal mucosa was widely ulcerated and lined by a fibrin-leukocyte and necrotic coating. The tumor cells were spindle shaped, arranged in bundles with many atypical cells with multiple nuclei, and frequent mitosis (30 per 10 high power field) (Fig. 2). The resection margins were free of tumor. On immunohistochemistry, the tumor

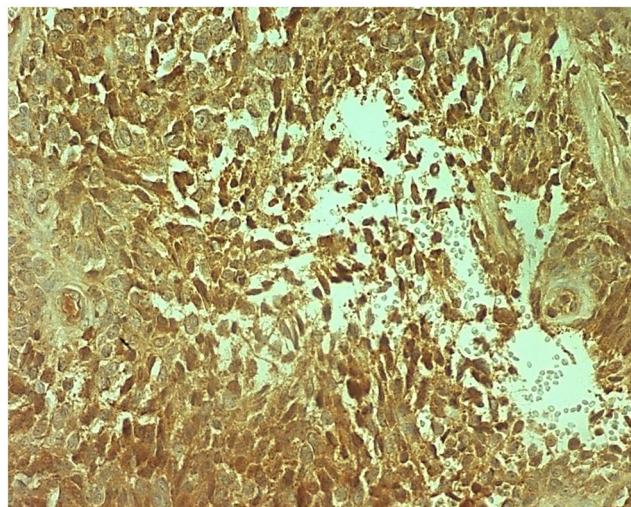


Fig. 3. Immunohistochemistry showing intense nuclear and cytoplasmic CD117 staining of tumor cells.

cells positively stained for the CD 117 (c kit) (Fig. 3). The diagnosis of high grade GIST was made. In view of the high grade tumor, a need for APR was discussed in the multidisciplinary staff meeting. But considering the old age, an absence of locoregional invasion, and R0 resection, the decision to start imatinib mesylate and maintain close surveillance was taken. Till the last follow-up at two years, there is no clinical evidence of recurrence or distant metastasis.

3. Discussion

Anal GIST is one of the rare tumors to be encountered in clinical practice. Although the exact number is not known as prior to development of CD117 immunostaining, GISTs were misinterpreted as leiomyomas and other stromal tumors, but since 2000 only 14 confirmed cases of primary anal GIST have been reported in literature (Table 1). Cases of rectal GIST involving anal canal secondarily have not been included in our review [3,13].

The most common age of presentation is sixth or seventh decade [3]. Males are more commonly affected than females (Table 1). The common symptoms are bleeding, anal pain, mass per anum [3]. Biopsy is useful for making the preoperative diagnosis in most of the cases. In the present case since the lesion was small, excisional biopsy was performed. Endorectal ultrasound (ERUS) is used for determining the depth of the lesion. Typically, GIST appears as a well circumscribed hypoechoic mass arising from the intersphincteric space encroaching into the lumen on ERUS [12]. Lymphadenopathy is absent. Anal sphincters get involved as the lesion increases in size. Alternatively, magnetic resonance imaging (MRI), CT abdomen and pelvis can be performed for staging the disease [9,12].

Due to rarity of the disease, there are no standard guidelines for the treatment of anal GIST. Among the previously published reports, wide local excision was performed in three cases while radical surgery like APR was done in seven cases (Table 1). Clinically, treatment is planned taking in to consideration the extent of the disease, tumor biology based on the mitotic rate and patient's general condition and willingness for a permanent colostomy.

Ideally, small lesions (<2 cm) with low mitotic rate can be successfully managed by local excision as seen in the present case [6]. While large, aggressive tumors require APR [8,9]. But, sometimes as the patients are often elderly and not willing for a permanent colostomy, the question of whether local excision can be considered in these patients remains to be answered.

Table 1
Clinicopathological features of anal GIST cases reported in the literature.

Sr. No.	Study [Ref. no.]	Number of patients	Age (years)	Sex	Size, location,	Treatment	Follow up (months)	Outcome
1	Tan et al. [4]	1	65	Male	3 × 3	APR	12	No recurrence
2	Lanteri et al. [11]	1	81	Male	7 × 5 cm	Local excision	30	Local recurrence
3	Gillard et al. [5]	1	70	Female	4.5 × 4 cm	APR	–	–
4	Li et al. [6]	2	73	Female	3.5 cm	APR	138	No recurrence
			67	Male	5 cm	Pelvic exentration	25	Died of liver metastases
5	Nigri et al. [1]	1	78	Male	4 × 2 cm	Local excision	12	No recurrence
					intersphincteric space			
6	Kumar et al. [7]	1	60	Male	2 × 1.5 × 1 cm	APR	–	–
7	Singhal et al. [8]	1	61	Male	>5 cm	APR + imatinib mesylate	–	–
					intersphincteric space			
8	Carvalho et al. [12]	1	73	Male	7 × 3.5 × 3 cm,	Local excision	60	No recurrence
					intersphincteric space			
9	Manimaran et al. [9]	1	69	Male	5 × 6 cm	APR	–	No recurrence
					intersphincteric space			
10	Oluymi et al. [10]	1	61	Male	5 cm	Surgery + Imatinib	–	–
11	Current case	1	70	Female	2 × 1.5 × 2 cm	Local excision + imatinib mesylate	24	No recurrence

Note: Cases of anal GIST for which the details were not available have not been listed. APR – abdominoperineal resection.

Imatinib mesylate, a tyrosine kinase inhibitor, is an integral part of multimodality treatment of GIST. It has been shown to down-stage the disease when used as neoadjuvant therapy and facilitate organ and function preserving surgeries especially in cases of rectal GIST [14]. However, it has been used only as an adjuvant therapy after curative resection for anal GIST in previous studies [8,10]. Future studies with use of imatinib as preoperative treatment for anal GIST are required to determine its potential in avoiding radical surgery.

The prognosis of GIST depends upon several factors including the location, size and mitotic rate of the tumor [15]. Due to the rarity of anal GIST, its prognosis is not known. In our review, follow up data was available for seven patients. At mean follow up of 43 months (range: 12–138), five patients are alive without disease; one patient is alive with local recurrence and one patient died due to distant metastases.

4. Conclusion

Local excision of anal GIST can be curative in appropriately selected cases. Further studies are needed to determine its role in combination with imatinib for the treatment of cases with high malignant potential.

Conflict of interest

The authors declare that they have no conflict of interest.

Informed consent

Written informed consent for the publication of this case report and all accompanying images was obtained from the patient and the patient’s family. Copies of the written consents are available for review by the Editor-in-Chief of this journal.

Funding

This study was not funded by any organization or institution.

Ethical approval

The study was approved by Ethics Committee of Hospital Sahloul.

Authors contribution

Study concept or design – MA, HA, ABA
Data collection – HA, NA, MSN
Data interpretation – MA, HA, RG
Literature review – HA, RG, NA, AC
Drafting of the paper – HA, RG, AC
Editing of the paper – MA, ABA

Registration of research studies

As this was a case report and not a clinical trial, this study does not require registration.

Guarantor

Mohamed Said Nakhli
Housseem Ammar

Acknowledgement

None.

References

- [1] G.R. Nigri, M. Dente, S. Valabrega, P. Aurello, F. D’Angelo, G. Montrone, et al., Gastrointestinal stromal tumor of the anal canal: an unusual presentation, *World J. Surg. Oncol.* 5 (2007) 20.
- [2] M. Miettinen, M. Sarlomo-Rikala, J. Lasota, Gastrointestinal stromal tumours, *Annales Chirurgiae et Gynaecologiae* 87 (1998) 278–281.
- [3] M. Miettinen, M. Furlong, M. Sarlomo-Rikala, A. Burke, L.H. Sobin, J. Lasota, Gastrointestinal stromal tumors, intramural leiomyomas, and leiomyosarcomas in the rectum and anus: a clinicopathologic, immunohistochemical, and molecular genetic study of 144 cases, *Am. J. Surg. Pathol.* 25 (2001) 1121–1133.
- [4] G.Y. Tan, C.K. Chong, K.W. Eu, P.H. Tan, Gastrointestinal stromal tumor of the anus, *Tech. Coloproctol.* 7 (2003) 169–172.
- [5] P. Gillard, C.C. Marques, P. Meunier, J. Boniver, L. De Leval, V. Gillard, GIST anale, *Acta Endosc.* 37 (2007) 63–75.
- [6] J.C. Li, S.S. Ng, A.W. Lo, J.F. Lee, R.Y. Yiu, K.L. Leung, Outcome of radical excision of anorectal gastrointestinal stromal tumors in Hong Kong Chinese patients, *Indian J. Gastroenterol.* 26 (2007) 33–35.
- [7] M. Kumar, M.M. Goel, D. Singh, Rare case of gastrointestinal stromal tumor of the anal canal, *J. Cancer Res. Ther.* 9 (2013) 736–738.
- [8] S. Singhal, A. Singhal, R. Tugnait, V. Varghese, B. Tiwari, P.K. Arora, et al., Anorectal gastrointestinal stromal tumor: a case report and literature review, *Case Rep. Gastrointest. Med.* 2013 (2013) 934875.
- [9] D. Manimaran, D.M. Khan, K. Bharathi, T.R. Raman, S. Anuradha, Gastrointestinal stromal tumor of the anal canal, *Nat. J. Lab. Med.* 4 (2015) 38–39.

- [10] A. Oluyemi, S. Keshinro, A. Jimoh, P. Oshun, Gastrointestinal stromal tumor of the anal wall in a Nigerian, *Pan Afr. Med. J.* 22 (2015) 161.
- [11] R. Lanteri, I. Aliotta, A. Racalbutto, A. Licata, Anal GIST in older old patient: a case report, *Il Giornale di chirurgia* 26 (2005) 135–137.
- [12] N. Carvalho, D. Albergaria, R. Lebre, J. Giria, V. Fernandes, H. Vidal, et al., Anal canal gastrointestinal stromal tumors: case report and literature review, *World J. Gastroenterol.* 20 (2014) 319–322.
- [13] J.A. Tworek, J.R. Goldblum, S.W. Weiss, J.K. Greenson, H.D. Appelman, Stromal tumors of the anorectum: a clinicopathologic study of 22 cases, *Am. J. Surg. Pathol.* 23 (1999) 946–954.
- [14] N. Wachter, M.A. Wörns, D.P. Dos Santos, H. Lang, T. Huber, W. Kneist, Transanal minimally invasive surgery (TAMIS) approach for large juxta-anal gastrointestinal stromal tumour, *J. Minim. Access Surg.* 12 (2016) 289–291.
- [15] Y. Yanagimoto, T. Takahashi, K. Muguruma, T. Toyokawa, H. Kusanagi, T. Omori, et al., Re-appraisal of risk classifications for primary gastrointestinal stromal tumors (GISTs) after complete resection: indications for adjuvant therapy, *Gastric Cancer* 18 (2015) 426–433.

Open Access

This article is published Open Access at [sciencedirect.com](https://www.sciencedirect.com). It is distributed under the [IJSCR Supplemental terms and conditions](#), which permits unrestricted non commercial use, distribution, and reproduction in any medium, provided the original authors and source are credited.