

Annulus Fibrosus Can Strip Hyaline Cartilage End Plate from Subchondral Bone: A Study of the Intervertebral Disk in Tension

Christian Balkovec¹ Michael A. Adams² Patricia Dolan² Stuart M. McGill¹

¹Department of Kinesiology, University of Waterloo, Waterloo, Ontario, Canada

²Centre for Comparative and Clinical Anatomy, University of Bristol, Bristol, United Kingdom

Address for correspondence Christian Balkovec, BSc, Department of Kinesiology, Burt Mathews Hall Room 3046, University of Waterloo, Waterloo, ON, Canada N2L 3G1 (e-mail: cbalkovec@uwaterloo.ca).

Global Spine J 2015;5:360–365.

Abstract

Study Design Biomechanical study on cadaveric spines.

Objective Spinal bending causes the annulus to pull vertically (axially) on the end plate, but failure mechanisms in response to this type of loading are poorly understood. Therefore, the objective of this study was to identify the weak point of the intervertebral disk in tension.

Methods Cadaveric motion segments (aged 79 to 88 years) were dissected to create midsagittal blocks of tissue, with ~10 mm of bone superior and inferior to the disk. From these blocks, 14 bone–disk–bone slices (average 4.8 mm thick) were cut in the frontal plane. Each slice was gripped by its bony ends and stretched to failure at 1 mm/s. Mode of failure was recorded using a digital camera.

Results Of the 14 slices, 10 failed by the hyaline cartilage being peeled off the subchondral bone, with the failure starting opposite the lateral annulus and proceeding medially. Two slices failed by rupturing of the trabecular bone, and a further two failed in the annulus.

Conclusions The hyaline cartilage–bone junction is the disk’s weak link in tension. These findings provide a plausible mechanism for the appearance of bone and cartilage fragments in herniated material. Stripping cartilage from the bony end plate would result in the herniated mass containing relatively stiff cartilage that does not easily resorb.

Keywords

- ▶ intervertebral disk
- ▶ tension
- ▶ herniation
- ▶ hyaline cartilage
- ▶ end plate
- ▶ subchondral bone

Introduction

The intervertebral disk is exposed to a myriad of loading conditions during everyday movement. During flexion and extension under compressive load, high bending moments could place high levels of tension on the annulus,¹ which could potentially result in the failure of the tissue. Understanding how the disk fails in tension could help to reveal the etiology of certain complex injuries in the spine.

The intervertebral disk end plate comprises a thin layer of hyaline cartilage that is bonded to an underlying layer of

perforated cortical bone.² On the disk side, the hyaline cartilage blends in with the nucleus and annulus.³ The lamellae of the outer annulus fibrosus attach themselves to the bony end plate and vertebral epiphysis by means of strong Sharpey fibers.^{4–6} More centrally, the collagen fibers of the inner annulus and nucleus coalesce to insert themselves obliquely into the cartilaginous end plate.^{6,7} In contrast, the interface between the cartilaginous end plate and the bony vertebral body is weak^{5,8} and lacks a structure to anchor it.⁹ Tensile forces acting at the annulus–end plate interface may be high enough in some cases to cause hyaline cartilage or

received
November 3, 2014
accepted after revision
January 20, 2015
published online
February 25, 2015

DOI <http://dx.doi.org/10.1055/s-0035-1546956>.
ISSN 2192-5682.

© 2015 Georg Thieme Verlag KG
Stuttgart · New York

License terms



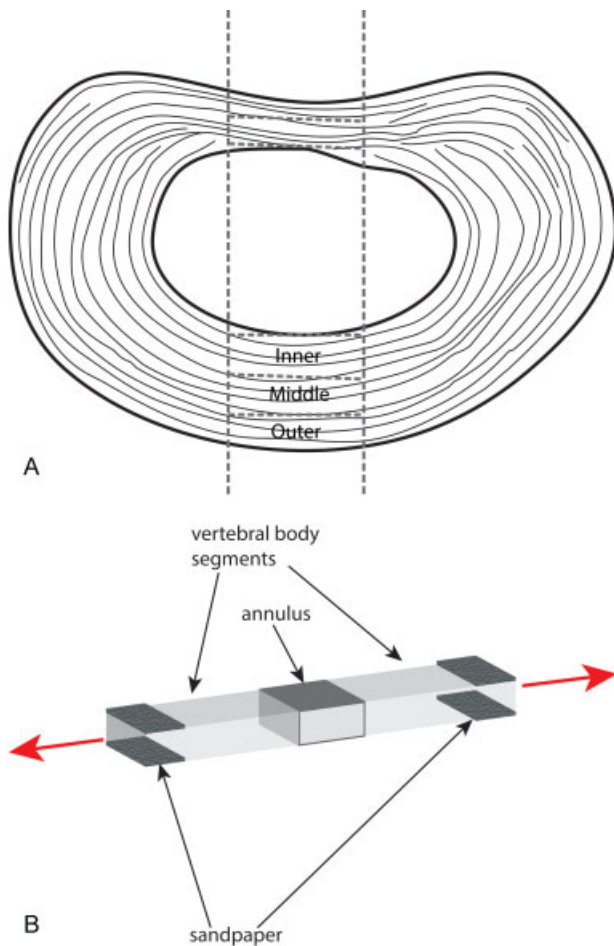


Fig. 1 Outline of method for specimen preparation. (A) Transverse view of the intervertebral disk (anterior on top) with dotted lines indicating the locations of cuts. First, two parasagittal cuts were made, followed by a series of frontal plane cuts to obtain slices for testing. (B) Specimens consisted of two regions of vertebral bone, with annulus in between. Sandpaper was fixed using cyanoacrylate adhesive to the ends of each specimen to prevent slipping while in the clamps of the materials testing machine.

bone to rupture. Identifying the weak point of the intervertebral disk in tension across a range of anterior and posterior locations could help to bolster the current understanding of

injuries that occur as a result of acute and subacute tissue overload.

If the hyaline cartilage is the weak point of the disk in tensile loading, this would leave the underlying porous bone exposed and potentially lead to a whole host of pathologic changes in the disk. Describing the anatomy of failure was therefore critical in the current investigation to provide a context for how injury occurs and to develop hypotheses concerning the etiology of discogenic back pain. The purpose of the current study was to establish the weak point of the intervertebral disk in tension.

Methods

The research was approved by the National Research Ethics Service (NRES) ethics committee, Frenchay Hospital, Bristol, United Kingdom. Thoracic spines from levels T6 to T12 were taken from four cadavers (two men, two women, age 79 to 88 years). The frozen vertebra–disk–vertebra specimens were sectioned with a fine hacksaw first in the sagittal plane to create an anterior-to-posterior midsagittal block with an average width of 12.8 mm. Coronal plane cuts were then made at the anterior and posterior annulus portions of the block to create thin slices of vertebra–disk–vertebra with an average thickness of 4.8 mm (►Fig. 1). The dissected specimens were wrapped in plastic cling wrap prior to testing to prevent dehydration but were tested immediately after a set of specimens had been dissected from the whole disk. Given the elderly spines used, some of the underlying trabecular bone was very weak or osteoporotic and would crumble during this stage. As a result, and due to the inconsistent sizing of vertebrae across individuals and segmental levels, it was not possible to obtain specimens from consistent locations across all spines. Fourteen specimens in total were obtained from the thoracic spines of the four cadavers for this investigation, with five from the posterior annulus and nine from the anterior annulus (►Table 1).

A cyanoacrylate adhesive was used to glue sandpaper to the bony ends of each specimen, so that the rough surfaces of the sandpaper could be held securely in the grips of the materials testing machine during the tensile loading.¹⁰ A

Table 1 Summary of specimen details

Spine (gender, age)	Number of slices (n)	Segmental level (n)	Tensile strength (kPa)	
			Anterior (n)	Posterior (n)
Male, 81	8	T6–T7 (3)	1,060–2,750 (2)	146 (1)
		T8–T9 (3)	438–1,840 (3)	
		T10–T11 (2)	784 (1)	858 (1)
Female, 83	2	T6–T7		143 (1)
		T8–T9	393 (1)	
Male, 88	3	T9–T10		583 (1)
		T11–T12	198–662 (2)	
Female, 79	1	T11–T12		1,728 (1)




Fig. 2 Time-series images (A–E) of a representative specimen stretched to failure. White arrows indicate the direction of pull. Failure initiates at the junction between the hyaline cartilage end plate and bone (black arrow) and spreads horizontally as the cartilage is peeled from bone.

Minimat materials testing machine (Minimat 2000, Rheometric Scientific GmbH, Bensheim, Germany) loaded the specimens in tension at a rate of 1 mm/s until failure.¹⁰ Great care was taken to ensure consistent specimen mounting in the testing apparatus. A 10-megapixel digital camera was used to capture a sequence of images that could be analyzed to determine the mode of failure. Minimat software converted force-deformation data to stress-strain data.

Results

Of the 14 specimens, 10 failed with the hyaline cartilage being peeled off the subchondral bone (→Fig. 2). Two specimens failed by the rupture of the trabecular bone near the clamps: one by the annular fibers tearing and delaminating and the other by a combination of the annular fibers tearing and partial tearing of the hyaline cartilage from the subchondral bone.

Failure at the cartilage–bone junction was typically initiated at the lateral aspects of the specimens and propagated medially. In one case, where three consecutive specimens were obtained from a block of anterior annulus, the outermost specimen required the highest amount of tensile stress to create failure, with this level of stress diminishing inward toward the nucleus region in the disk (→Fig. 3A). This same phenomenon was observed for a second pair of anterior annulus specimens (→Fig. 3B), but the opposite was observed for another pair (→Fig. 3C). The tensile stresses at failure are presented in →Table 1. Because the specimen numbers were small, individual values or ranges of values are shown.

Discussion

In the tensile tests on elderly human tissues, the site of end plate failure was usually at the junction between the hyaline

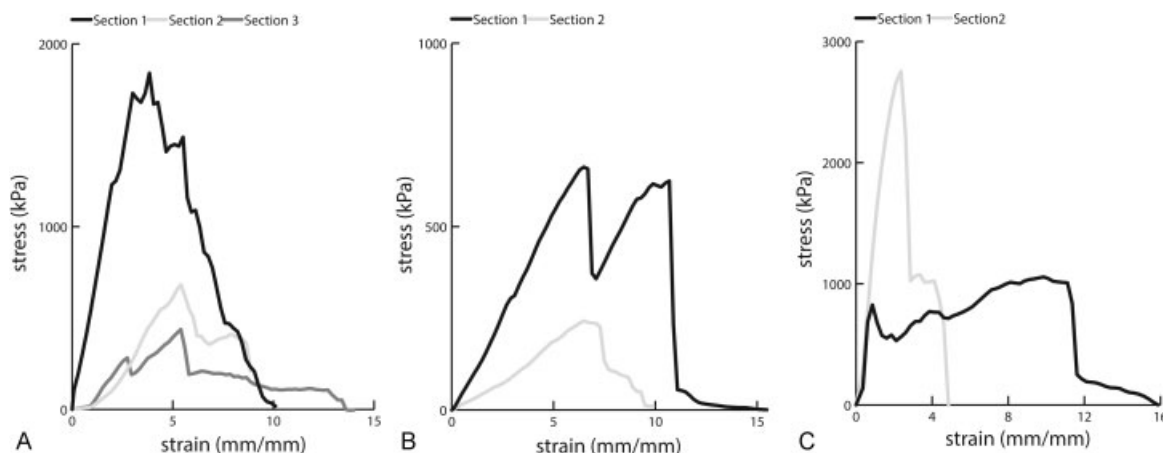


Fig. 3 Failure graphs of specimens where sequential slices were obtained. (A) The outer slice (Section 1) from the peripheral annulus required the highest tensile stress to initiate failure, and subsequent slices further in toward the nucleus (middle and inner sections, respectively) required progressively less. (B) Two-slice sample exhibiting the same phenomenon as A. The outer slice (Section 1) failed by rupture of the underlying trabecular bone. (C) In this specimen, Section 1 failed at a modest load (~1,000 kPa) but continued to resist strongly up to exceptionally high strains, as the cartilage was peeled off the underlying bone.

cartilage and subchondral bone. The tensile forces stretch the annulus vertically (axially) during spinal bending movements,¹ so these results clearly demonstrate that this is the weak point of the elderly intervertebral disk in tension.

The demonstrated mode of failure (►Fig. 2) is consistent with previous tensile studies on human tissues,^{12,13} and with bending experiments on whole motion segments.¹ Green and colleagues were able to produce the same characteristic injury on a range of young to elderly specimens, with the peripheral fibers pulling out of the matrix and the hyaline cartilage being stripped off the end plate in the inner regions where it was present.⁵ The tensile strength values (1.7 ± 0.8 MPa in the anterior annulus and 3.8 ± 1.9 MPa in the posterior annulus) were consistent with those shown in ►Table 1. The present study confirms these findings across a range of anterior-to-posterior midsagittal locations of the disk. Minor differences between the two studies are attributable to the different locations and sizes of specimens, in addition to the general heterogeneity of cadaveric specimens. Other sites of failure (such as the growth plate) may occur in different developmental stages. In addition, weakening of the trabecular bone through the alternating compressive and tensile loading could direct the mode of failure to the bony structures and create additional fracturing. This remains a question for the future.

The current observations could help to explain why disk herniations often include fragments of the hyaline cartilage and bone.^{12,14,15} The results agree with findings from Tanaka and colleagues,¹³ who found evidence of cartilaginous end plate separation in degenerated cadaveric specimens. Intervertebral disk herniation can occur under both acute^{16,17} and repetitive¹⁸⁻²¹ flexion and extension motions with varying degrees of compressive load. Unlike the annulus and nucleus tissues, the hyaline cartilage does not swell greatly in tissue fluid, even when physically disrupted.²² Consequently, fragments of the hyaline cartilage in disk herniations do not appear to lose proteoglycans or undergo cell-mediated resorption.¹⁵ In cases where bone fragments have been identified in herniated material,¹⁴ a possible origin is from the periphery of the disk where the Sharpey fibers insert directly into the vertebral body without a hyaline cartilage interface.^{13,23} Ruptures at this junction would introduce bone fragments into the extruded herniated material.

Although sequential slices across the annulus were not obtained consistently across all the specimens, the results suggest that the attachment of the hyaline cartilage to the subchondral bone is stronger closer to the periphery of the disk and weakens further inward. This is consistent with previous work showing that the outer annular fibers insert directly into the calcified end plate to create a stronger junction than that between the hyaline cartilage and bone.^{6,9,23} The sequential specimens that did not exhibit this phenomenon were two of the specimens that also exhibited abnormal results with trabecular bone rupture and annular fiber tearing rather than the common mode of failure exhibited. Structural differences that were not immediately evident at testing could have contributed to the results observed.

Annulus failure stress decreases as the specimen size decreases, probably because cutting out small specimens causes relatively more disruption to the collagen network of the annulus.²⁴ This would not have been a limiting factor in the present study, which used large (4.8 mm thick) specimens. The strength of the annular fibers appears to be derived from the connections between the collagen and its surrounding proteoglycan matrix rather than the end plate-to-end plate connections.²⁴ As the annulus acts characteristically like a chopped fiber composite,²⁵ it will remain strong in tension provided the length of the individual reinforcing fibers are sufficient. Conversely, the hyaline cartilage layer, made up of closely packed collagen fibrils,²⁶ does not seem to have the bolstering in tension through lateral connections that are exhibited by the annular fibers. The annular fibers extend through the cartilaginous end plate to insert into the calcified bone via parallel connections relative to the interface between the articular and calcified cartilage.^{6,23} However, a thicker layer of cartilaginous end plate in the midannular regions of the disk would seem to limit this anchoring ability in the subchondral bone.²⁷

Damage to the end plate produces disk decompression and height loss,²⁸ and although this is characteristic of compressive damage,²⁹ stripping of the hyaline cartilage from the subchondral bone could also act to decompress the disk. This effect would be greater in smaller disks such as the thoracic levels tested in this study.³⁰ Maintaining the hydrostatic pressure within the intervertebral disk has important implications with regard to stimulating matrix synthesis³¹ and transferring the load radially outward to the annulus fibers and vertically to the adjacent vertebral bodies.⁷ Disruption of the delicate cellular environment due to an altered stress profile can lead to the initiation of degenerative changes,³² which alter the load-bearing profile of the disk itself and predispose individuals to the risk of further mechanical damage.^{33,34}

Disruption of the cartilage end plate has also been found in whole specimens by Veres and colleagues,¹⁷ implicating flexion coupled with a highly pressurized nucleus as the mechanism of failure. Results from the present study agree with these findings; bending of the disk, applying tensile stress to it, would weaken the cartilage-bone interface further, causing it to fail under stress from the pressurized nucleus pulposus. The type of injury produced in this study has been shown to cause a significant change in the instantaneous height and internal pressurization.³⁵ Although the mechanical effects are not immediately evident, the long-term consequences of such an injury as a result of the cumulative overload could potentially have significant structural and mechanical consequences.

End plate disruption seems to be related to various instances of Modic change via fracture or herniation.³⁶ A Modic change itself can be characterized as a lesion to the end plate and bone marrow,³⁷ often with associated inflammation. Whether there is a link between the Modic changes and intervertebral disk herniations containing hyaline cartilage remains to be seen. However, it is plausible that the stripping of the hyaline cartilage from the subchondral bone of the end plate could cause or predispose the end plate to further

damage, including end plate “erosions,”³⁸ which are common at the lower lumbar levels, where they are associated with disk degeneration and back pain.³⁹ The results of the present study show that direct lesions to subchondral bone through rupture are certainly possible through mechanical means.

Limitations of this study include the small number of elderly cadaveric specimens. Nevertheless, the failure mechanism was consistent and would be unlikely to change if more specimens had been tested. Although little is known about how this failure mechanism depends on age, it was considered important to test human specimens so that the relative strengths of the disk would resemble those seen in elderly patients in life.¹⁰ If young (or animal) specimens had been used, the bone strength potentially could have increased more than the disk strength,¹⁰ and failure at the cartilage–bone junction would possibly have been even more likely than in the present experiment. Furthermore, there was a bias toward the selection of specimens that had an adequate trabecular bone quality to facilitate mounting in the tensile testing apparatus. Results from the present study would likely exclude individuals with severe osteoporosis. Further limitations include the nature with which the specimens were tested in tension. The lateral ends of the specimens were free and would increase the interlamellar shear stress experienced,¹¹ potentially enhancing the degree of the separation of the cartilage end plate from bone. Although there was a highly systematic effect of injury mechanism seen across the specimens, the same tensile stress was not needed to create failure across sequential specimens. Heterogeneity associated with cadaveric tissue testing could be a potential cause of the results seen.

Disclosures

Christian Balkovec, none
 Michael A. Adams, none
 Patricia Dolan, none
 Stuart M. McGill, none

References

- Adams MA, Green TP, Dolan P. The strength in anterior bending of lumbar intervertebral discs. *Spine (Phila Pa 1976)* 1994;19(19):2197–2203
- Adams MA, Burton K, Bogduk N, et al. *The Biomechanics of Back Pain*. 3rd ed. Edinburgh, UK: Elsevier Health Sciences; 2006
- Wade KR, Robertson PA, Broom ND. A fresh look at the nucleus-endplate region: new evidence for significant structural integration. *Eur Spine J* 2011;20(8):1225–1232
- Johnson EF, Chetty K, Moore IM, Stewart A, Jones W. The distribution and arrangement of elastic fibres in the intervertebral disc of the adult human. *J Anat* 1982;135(Pt 2):301–309
- Green TP, Adams MA, Dolan P. Tensile properties of the annulus fibrosus II. Ultimate tensile strength and fatigue life. *Eur Spine J* 1993;2(4):209–214
- Nosikova YS, Santerre JP, Grynepas M, Gibson G, Kandel RA. Characterization of the annulus fibrosus–vertebral body interface: identification of new structural features. *J Anat* 2012;221(6):577–589
- Bogduk N. *Clinical Anatomy of the Lumbar Spine and Sacrum*. 4th ed. Edinburgh, UK: Elsevier Churchill Livingstone; 2005
- Coventry MB, Ghormley RK, Kernohan JW. The intervertebral disc: its microscopic anatomy and pathology: part I: anatomy, development, and physiology. *J Bone Joint Surg* 1945;27:105–112
- Inoue H. Three-dimensional architecture of lumbar intervertebral discs. *Spine (Phila Pa 1976)* 1981;6(2):139–146
- Skrzypiec D, Tarala M, Pollintine P, Dolan P, Adams MA. When are intervertebral discs stronger than their adjacent vertebrae? *Spine (Phila Pa 1976)* 2007;32(22):2455–2461
- Iatridis JC, ap Gwynn I. Mechanisms for mechanical damage in the intervertebral disc annulus fibrosus. *J Biomech* 2004;37(8):1165–1175
- Willburger RE, Ehiosun UK, Kuhnen C, Krämer J, Schmid G. Clinical symptoms in lumbar disc herniations and their correlation to the histological composition of the extruded disc material. *Spine (Phila Pa 1976)* 2004;29(15):1655–1661
- Tanaka M, Nakahara S, Inoue H. A pathologic study of discs in the elderly. Separation between the cartilaginous endplate and the vertebral body. *Spine (Phila Pa 1976)* 1993;18(11):1456–1462
- Rajasekaran S, Bajaj N, Tubaki V, Kanna RM, Shetty AP. ISSLS Prize winner: The anatomy of failure in lumbar disc herniation: an in vivo, multimodal, prospective study of 181 subjects. *Spine (Phila Pa 1976)* 2013;38(17):1491–1500
- Lama P, Zehra U, Balkovec C, et al. Significance of cartilage endplate within herniated disc tissue. *Eur Spine J* 2014;23(9):1869–1877
- Adams MA, Hutton WC. Prolapsed intervertebral disc. A hyperflexion injury 1981 Volvo Award in Basic Science. *Spine (Phila Pa 1976)* 1982;7(3):184–191
- Veres SP, Robertson PA, Broom ND. The morphology of acute disc herniation: a clinically relevant model defining the role of flexion. *Spine (Phila Pa 1976)* 2009;34(21):2288–2296
- Adams MA, Hutton WC. Gradual disc prolapse. *Spine (Phila Pa 1976)* 1985;10(6):524–531
- Callaghan JP, McGill SM. Intervertebral disc herniation: studies on a porcine model exposed to highly repetitive flexion/extension motion with compressive force. *Clin Biomech (Bristol, Avon)* 2001;16(1):28–37
- Tampier C, Drake JD, Callaghan JP, McGill SM. Progressive disc herniation: an investigation of the mechanism using radiologic, histochemical, and microscopic dissection techniques on a porcine model. *Spine (Phila Pa 1976)* 2007;32(25):2869–2874
- Balkovec C, McGill S. Extent of nucleus pulposus migration in the annulus of porcine intervertebral discs exposed to cyclic flexion only versus cyclic flexion and extension. *Clin Biomech (Bristol, Avon)* 2012;27(8):766–770
- Summers GC, Merrill A, Sharif M, Adams MA. Swelling of articular cartilage depends on the integrity of adjacent cartilage and bone. *Biorheology* 2008;45(3–4):365–374
- Paietta RC, Burger EL, Ferguson VL. Mineralization and collagen orientation throughout aging at the vertebral endplate in the human lumbar spine. *J Struct Biol* 2013;184(2):310–320
- Adams MA, Green TP. Tensile properties of the annulus fibrosus. I. The contribution of fibre–matrix interactions to tensile stiffness and strength. *Eur Spine J* 1993;2(4):203–208
- Hukins DW, Aspden RM, Yarker YE. Fibre reinforcement and mechanical stability in articular cartilage. *Eng Med* 1984;13(3):153–156
- Inoue H, Takeda T. Three-dimensional observation of collagen framework of lumbar intervertebral discs. *Acta Orthop Scand* 1975;46(6):949–956
- Moon SM, Yoder JH, Wright AC, Smith LJ, Vresilovic EJ, Elliott DM. Evaluation of intervertebral disc cartilaginous endplate structure using magnetic resonance imaging. *Eur Spine J* 2013;22(8):1820–1828

- 28 Adams MA, Freeman BJ, Morrison HP, Nelson IW, Dolan P. Mechanical initiation of intervertebral disc degeneration. *Spine (Phila Pa 1976)* 2000;25(13):1625–1636
- 29 Brinckmann P, Biggemann M, Hilweg D. Prediction of the compressive strength of human lumbar vertebrae. *Spine (Phila Pa 1976)* 1989;14(6):606–610
- 30 Dolan P, Luo J, Pollintine P, Landham PR, Stefanakis M, Adams MA. Intervertebral disc decompression following endplate damage: implications for disc degeneration depend on spinal level and age. *Spine (Phila Pa 1976)* 2013;38(17):1473–1481
- 31 Ishihara H, McNally DS, Urban JP, Hall AC. Effects of hydrostatic pressure on matrix synthesis in different regions of the intervertebral disk. *J Appl Physiol (1985)* 1996;80(3):839–846
- 32 Bibby SR, Jones DA, Lee RB, Yu J, Urban JPG. The pathophysiology of the intervertebral disc. *Joint Bone Spine* 2001;68(6):537–542
- 33 Pollintine P, Przybyla AS, Dolan P, Adams MA. Neural arch load-bearing in old and degenerated spines. *J Biomech* 2004;37(2):197–204
- 34 Pollintine P, Dolan P, Tobias JH, Adams MA. Intervertebral disc degeneration can lead to “stress-shielding” of the anterior vertebral body: a cause of osteoporotic vertebral fracture? *Spine (Phila Pa 1976)* 2004;29(7):774–782
- 35 Michalek AJ, Iatridis JC. Height and torsional stiffness are most sensitive to annular injury in large animal intervertebral discs. *Spine J* 2012;12(5):425–432
- 36 Albert HB, Kjaer P, Jensen TS, Sorensen JS, Bendix T, Manniche C. Modic changes, possible causes and relation to low back pain. *Med Hypotheses* 2008;70(2):361–368
- 37 Kuisma M, Karppinen J, Niinimäki J, et al. A three-year follow-up of lumbar spine endplate (Modic) changes. *Spine (Phila Pa 1976)* 2006;31(15):1714–1718
- 38 Wang Y, Videman T, Battié MC. Lumbar vertebral endplate lesions: prevalence, classification, and association with age. *Spine (Phila Pa 1976)* 2012;37(17):1432–1439
- 39 Wang Y, Videman T, Battié MC. ISSLS prize winner: Lumbar vertebral endplate lesions: associations with disc degeneration and back pain history. *Spine (Phila Pa 1976)* 2012;37(17):1490–1496