

# Successful Closed Reduction of Atlantoaxial Rotatory Fixation in Children—A Retrospective Study of 30 Patients

Ping Xu, MD<sup>1</sup>, Zhiqiang Zhang, MD<sup>1</sup> , Yiming Zheng, MD<sup>1</sup> , Junrong Meng, MD<sup>1</sup>, Chuang Qian, MD<sup>1</sup>, Dong Fu, PhD<sup>1</sup>, and Dahui Wang, MD<sup>1</sup>

Global Spine Journal  
2022, Vol. 12(8) 1655–1660  
© The Author(s) 2021  
Article reuse guidelines:  
sagepub.com/journals-permissions  
DOI: 10.1177/2192568220984427  
journals.sagepub.com/home/gsj



## Abstract

**Study Design:** Retrospective cohort study.

**Objectives:** To review our treatment experience and to investigate the process of this disease.

**Methods:** Clinical data of AARF patients, who received closed reduction, was retrospectively reviewed. Patients were divided into 2 groups according to the length of delay (Group I: 1 month  $\leq$  delayed time < 3 months), Group II (delayed time < 1 months). The correlation between the length of delayed time and clinical recovery (CR), radiological recovery (RR), and total recovery time were measured. The atlantodental interval (ADI), lateral mass-dens interval (LDI) and lateral joint space (LJS) were compared at admission and final follow-up.

**Results:** 30 children (12 girls and 18 boys) with AARF had received conservative treatment. The mean age at initial treatment was 8.13-year-old, ranging from 5 to 14. The mean follow-up time was 26.93 months (range, 6–87 months). The average length of delayed time was 28.53 days (range, 2–80 days). When the LDI, LJS, and ADI differences are compared at admission and the final visit, the differences are reduced significantly on LDI and LJS. A positive correlation is observed between the length of the delay and CR time and total recovery time ( $r = 0.63$ ,  $p = 0.00$  and  $r = 0.47$ ,  $p = 0.01$ ) respectively.

**Conclusions:** Pediatric AARF patients who have a delay time < 3 months can be treated with closed reduction successfully. The longer the delayed time, the longer the traction time, but the cervical collar time is almost the same. The LDI and LJS on the anteroposterior of X-rays are convenient to estimate the progress of this condition during the treatment.

## Keywords

atlantoaxial rotatory fixation, closed reduction, halter traction, cervical collar

## Introduction

In normal individuals, the axial rotation at the craniocervical region is responsible for up to 60% of the total rotation of the neck, which serves as the main rotational pivot of the cervical spine.<sup>1</sup> However, this unique anatomic figure is also vulnerable to various dangers, including upper respiratory infections, trauma, and surgery of the head, manifested with rotational limitation, persistent painful and fixed position, known as atlantoaxial rotatory fixation (AARF).<sup>1–3</sup> It has been found mainly in children, and the typical presentation is torticollis with the head in the “cock-robin” position. Asymmetry in the atlantoaxial joint was confirmed by open-mouth anteroposterior, lateral radiograph, and computed tomography (CT).

Because the presence of torticollis is based on physical examination, no single imaging modality is mandatory to diagnose and classify AARF. Pang and Li et al<sup>4</sup> classified the AARF into 3 different groups according to the pretreatment time (acute < 1 mo, subacute = 1–3 mo, chronic > 3 mo). The initial treatment

<sup>1</sup> Department of Orthopedics, National Children’s Medical Center & Children’s Hospital of Fudan University, Shanghai, China

### Corresponding Author:

Dahui Wang, Department of Orthopedics, National Children’s Medical Center & Children’s Hospital of Fudan University, 399 Wanyuan Road, Shanghai, 201102, China.  
Email: wangdahui@fudan.edu.cn



is often nonoperative, including cervical collar, neck traction, and halo traction. For the recurrence and irreducible patients, the C1-C2 fusion is recommended.<sup>4</sup> However, surgical treatment is associated with rare but potentially catastrophic risks such as vertebral artery injury or a loss of neck motion.<sup>5,6</sup> To avoid that, some articles<sup>7-9</sup> reported good clinical outcomes with the conservative method to treat acute and subacute patients. Indeed, all patients in our center had successful treatment by closed reduction (halter traction combined with cervical collar immobilization). The purpose of this study is to review our treatment experience and to investigate the process of this disease.

## Materials and Methods

After the Ethics committee approval (CHFUE-ER-2020-198), a retrospective review was performed in all patients with the diagnosis of AARF from January 2012 to January 2019. Diagnosis of AARF was made clinically when patients had torticollis and stiffness and were confirmed using open-mouth anteroposterior, lateral radiograph, and/or CT images. Thirty patients were included and followed up at least 6 months. The clinical data of gender, age, etiology, delay time, prior treatment, and immobilization methods was recorded. The clinical outcome of range of motion (at admission and final follow-up), recurrence, and complications were collected. These children were contacted by telephone to obtain verbal informed consent from the parents for the publication of their clinical data and medical images.

Fielding classification<sup>10</sup> (grade I: rotatory fixation without anterior displacement; grade II: rotatory fixation with anterior displacement 3 to 5 mm; grade III: rotatory fixation with >5 mm anterior displacement; and grade IV: rotatory fixation with posterior displacement) was used to evaluate the severity of subluxation. Atlantodental interval (ADI) was measured using the lateral view. Lateral mass-dens interval (LDI) and lateral joint space (LJS) were measured by the open mouth anteroposterior view (Figure 1). Radiographic studies used in conjunction with clinical examination to confirm treatment success included open mouth odontoid views and CT or MRI.

Patients were separated into 2 groups according to the Pang and Li classification (Group I: subacute patients; Group II: acute patients). The maximal tolerated traction weight which is around 2-5 kg depending on the size of the patient around 10% of their body weight, and the time of traction each day was at least 23 hours. The halter traction was suspended and changed to the cervical collar when the pain was gone and ROM was recovered, which we called the clinical recovery (CR). The cervical collar immobilization time was at least 23 hours too. The collar immobilization was suspended when the symmetry of bilateral LDI was almost achieved on X-rays or CT (LDI difference was smaller than 2 mm), which we called the radiological recovery (RR). All measurements and evaluations were made by 2 observers (PX and ZQZ).

The continuous variable was analyzed by Kolmogorov-Smirnov test to assess for normality. Comparisons of 2 groups

in terms of ADI, LDI, LJS, CR, RR, and follow-up time were performed by using paired t-test. The chi-squared test was used to compare categorical variables (i.e. gender, side, recurrence, and complications). Furthermore, the difference between LDI and ADI between X-rays and CT was tested using a paired t-test. We tested the correlation between the length of delayed time and the CR time, RR time, and total recovery time by the Spearman nonparametric correlation test. The Statistical tests were considered significant at  $p < 0.05$ . All analyses were performed with the statistical software SPSS.

## Results

Thirty children (12 girls and 18 boys) with AARF had received conservative treatment. The mean age at initial treatment was 8.13-year-old, ranging from 5 to 14. The mean follow-up time was 26.93 months (range, 6-87 months). The average length of delayed time was 28.53 days (range, 2-80 days). Etiologies in this group included trauma (11), infection (3), and no obvious reasons (16). The outcomes between groups I and II were outlined in Table 1, a significant difference was only found with the average time of neck traction of 2.75 (group II) and 5.07 (group I) weeks.

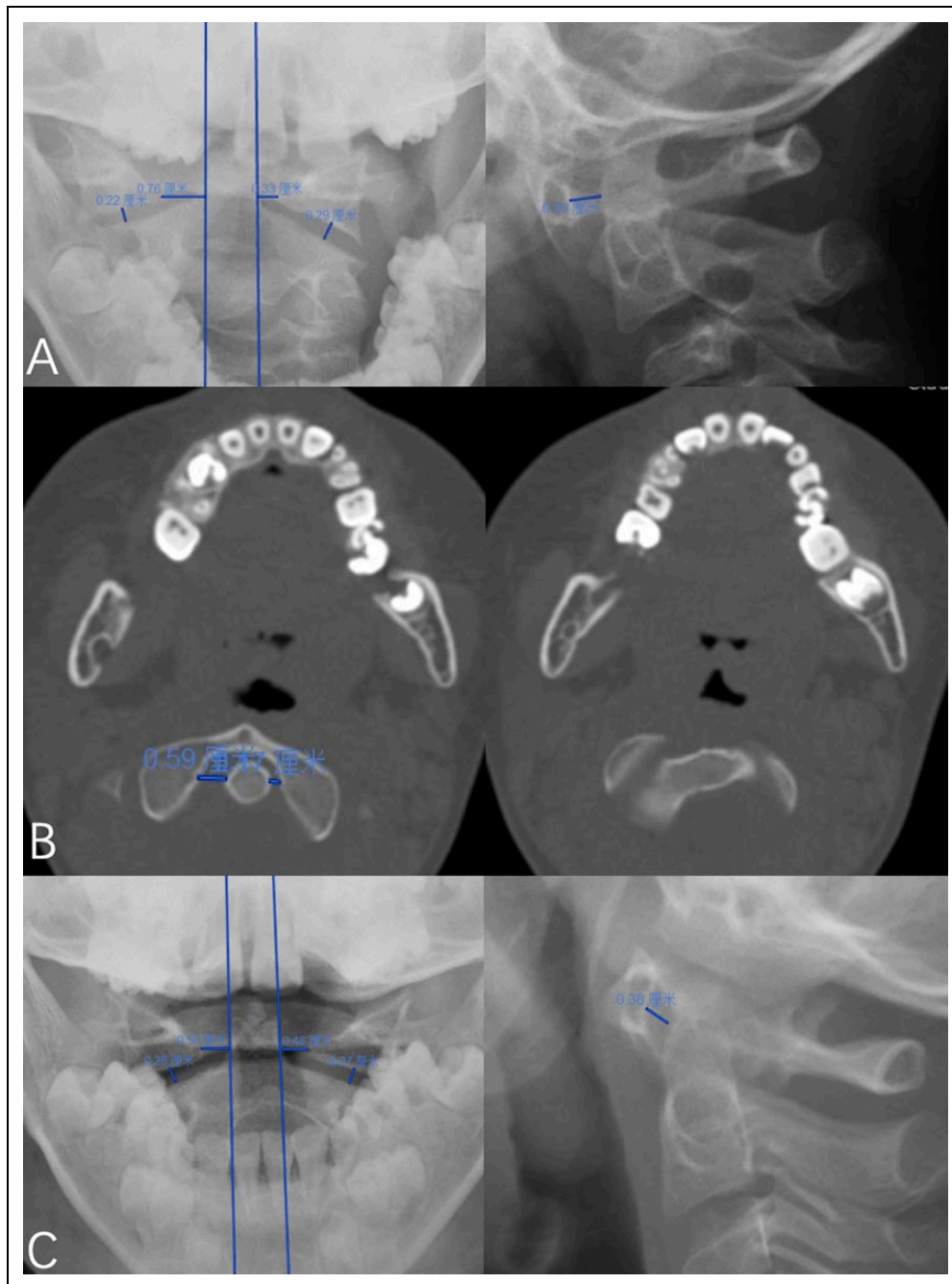
The difference between LJS, LDI, and ADI was compared pre- and post-treatment (Figure 2). The difference of LJS was changed from  $1.18 \pm 0.68$  mm to  $0.49 \pm 0.39$  mm, and the difference of LDI was changed from  $3.03 \pm 1.65$  mm to  $0.82 \pm 0.56$  mm at the final visit. The difference of ADI at admission and final follow-up was not noticed.

We also compared the difference of LDI and ADI between X-rays and CT scans, and the significant difference was seen on ADI (Table 2).

There was a positive relationship between the length of delayed time and the CR time ( $p = 0.00$ ), and between the length of delayed time and total recovery time ( $p = 0.01$ ), however, the length of delayed time and the RR time had no relationship, the average RR time was 4.37 weeks (Figure 3).

## Discussion

AARF is defined as a subluxation or dislocation of atlantoaxial joint and always develops as the consequence of trauma, upper respiratory infection, and head or neck surgeries. It's a condition that is rare but early proper management is important to achieve a successful outcome. The most used classification of AARF was termed by Fielding and Hawkins, they have characterized 4 different types of rotatory atlantoaxial subluxation according to the extent of displacement of the atlas from the axis.<sup>10</sup> Pang and Li<sup>4</sup> then defined this disorder more clearly, according to the dynamic CT, and to provide guidelines for its treatment. Many classifications and different algorithms were reported based on the different CT scanning methods.<sup>1,5,10</sup> However, Alanay et al<sup>11</sup> noted both poor reliability and poor reproducibility of dynamic CT scanning and recommended against its routine use, especially in patients presenting acutely. Based on our experience, the dynamic CT was difficult to



**Figure 1.** The clinical algorithm of AARF (Group I, Case 9). A 7-year-old boy sustained torticollis caused by trauma for 48 days, who had intermittent cervical collar immobilization 30 days. A, Open mouth anteroposterior view at admission shows the asymmetry of LDI and LJS (4.3mm and 0.7mm), the lateral view shows the ADI was 4.8mm. B, CT shows the LDI was 1.7 mm on the left side and 5.9 mm on the right side. The rotation of C1 could be seen in the second view. C, The halter traction was performed for 2 weeks and changed to collar immobilization for another 2 weeks when the clinical recovery was achieved. Open mouth anteroposterior view shows the almost symmetry of LDI and LJS (0.2 mm and 0.1 mm.), the lateral view shows the ADI was 3.8 mm.

perform routinely, which imparts some risk from ionizing radiation, especially on the young children and during the acute phase. Radiographs might be useful as the initial imaging modality, mainly to rule out obvious fracture or congenital abnormality.<sup>12</sup> Apart from that, we think that the open-mouth anteroposterior view may show displacement of the odontoid

and can be measured by LDI, LJS, and ADI on the lateral view. We noticed that the difference between X-rays and CT of LDI was not obvious, but the deference of ADI was significant. It represents that the results of LDI on the anteroposterior view can be a reliable parameter to evaluate the severity of the acute torticollis without dynamic CT. However, the ADI is not that

reliable since the head tilt may obscure the normal anatomy and landmarks of the vertebrae on the lateral radiograph, especially on the young patients.

The treatment of AARF consists of non-surgeries, including Halter traction, cervical brace and Skull calipers traction,<sup>4</sup> and surgeries, including remodeling therapy,<sup>5</sup> Halo traction and C1-2 arthrodesis.<sup>13</sup> Patients, who present within 1 month from the onset of symptoms, are routinely treated by non-surgeries. The most consistently employed measures for these patients are analgesics and a cervical collar for comfort. If the torticollis resolves quickly, no other treatment is required. Subach et al<sup>14</sup> compared the use of cervical collar alone and the traction alone, and found that reduction was achieved more rapidly and effectively with traction than the cervical collar. Like that, Pang and Li recommended that all acute and subacute (<3 months)

AARF patients should be first tried on halter traction. Our treatment strategy was based on continuous halter traction from start to CR, then changed to cervical immobilization until the RR. Surgical treatment was not required for any patients in the current study.

The length of delay was believed to be the only factor that influences the recurrence rate and the failure of closed reduction techniques.<sup>15,16</sup> In our study, we only have one recurrence case, and then treated by halter traction again, and finally had a full recovery. We noticed that the CR time in the group I was significantly longer than group II, which also represents a positive correlation between the length of delayed time and CR time ( $p = 0.00$ ). Fielding and Hawkins also concluded that delay in diagnosis related to the failure of nonoperative treatment.<sup>10</sup> Lee et al<sup>17</sup> reported 5 of the 6 pediatric patients required surgical fusion with a minimum 6-week delay in treatment. Subach et al<sup>14</sup> treated 20 patients and failed in 6 (30%) of nonoperative management. In contrast to the positive correlation of delay and CR time, the RR time was almost the same between groups, about 4.36 weeks. Mihara et al<sup>9</sup> recommended the traction continued for 2 to 3 weeks even after the deformity appeared to be corrected. Landi et al<sup>18</sup> recommended an MRI protocol to determine the length of time in the orthosis. The collars were kept intact until repeat MRI showed resolution of hyperintensity in the transverse ligament and alar ligaments. Based on the findings of our study, we believe that the cervical collar was necessary and enough to correct the residual deformity detected by the anteroposterior view of X-rays for about 4 weeks.

There were some limitations in this study. Firstly, the average age was around 8-year-old, so the physical examination

**Table 1.** Demographic Data With Reference to the Time of Delay When AARF Treatment Was Initiated.

	Group I	Group II
Age (years)	8.50 ± 2.2	7.75 ± 2.1
Gender	F:4; M:10	F:8; M:8
Side	L:6; R:8	L:10; R:6
Fielding grade	I:13; II:1	I:13; II:3
CR (weeks)*	5.07 ± 2.64	2.75 ± 1.81
RR (weeks)	4.36 ± 3.37	4.38 ± 2.82
FT (months)	28.79 ± 26.9	25.06 ± 14.1
PreLJSd (°)	1.25 ± 0.64	1.13 ± 0.74
PostLJSd (°)	0.55 ± 0.44	0.43 ± 0.36
PreLDId (°)	3.17 ± 1.8	2.89 ± 1.54
PostLDId (°)	0.78 ± 0.5	0.86 ± 0.61
PreADId (°)	3.12 ± 0.96	3.4 ± 0.89
PostADId (°)	2.66 ± 0.77	3.41 ± 1.24
Recurrence	1	0
Complications	0	0

Group I (subacute patients; 1 month ≤ delayed time < 3months), Group II (acute patients; delayed time < 1months).

CR: Clinical recovery; RR: Radiological recovery; FT: follow-up time; Pre: Pre-treatment; Post: Post-treatment; d: difference; LJS: lateral joint space; ADI: Atlantodental interval; LDI: Lateral mass-dens interval.

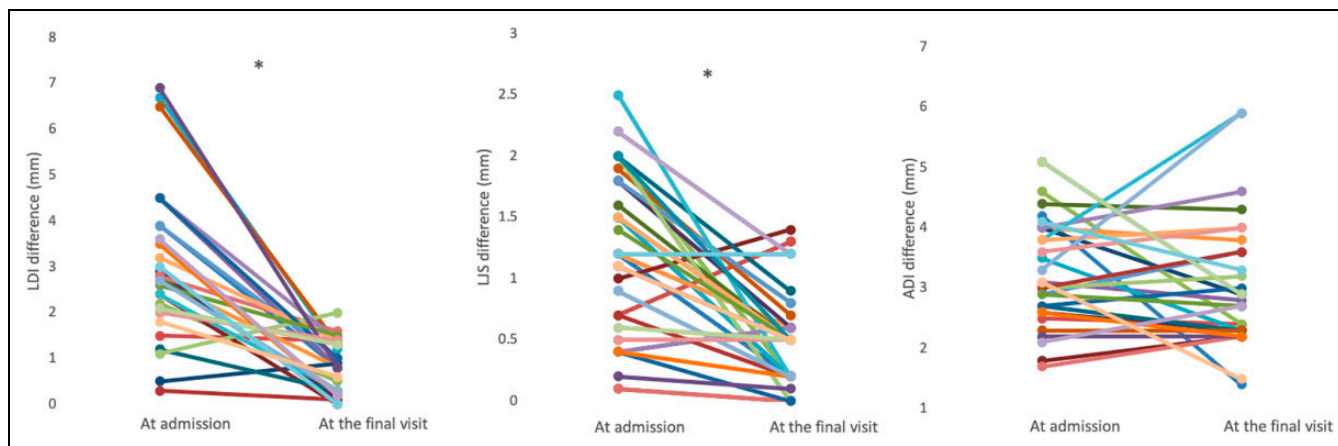
\*: significant difference.

**Table 2.** The Deference of LDI and ADI Between X-Rays and CT.

	X-rays	CT
LDId	3.02 ± 1.65	3.74 ± 1.70
ADId*	3.29 ± 0.91	2.22 ± 0.73

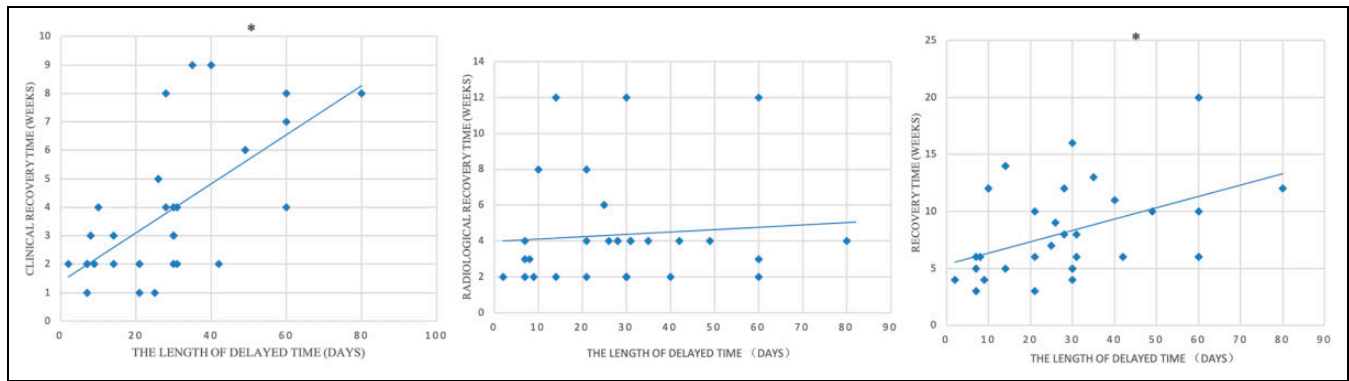
d: difference; ADI: Atlantodental interval; LDI: Lateral mass-dens interval.

\*: significant difference.



**Figure 2.** When the LDI, LJS and ADI differences are compared pre-treatment and at the final visit, the differences are reduced significantly on LDI and LJS. However, the difference of ADI is smaller. LJS: lateral joint space; ADI: Atlantodental interval; LDI: Lateral mass-dens interval  
 \*: significant difference.





**Figure 3.** Spearman correlation test between the length of delayed time and CR time, RR time and total recovery time. A positive correlation is observed between the length time and CR time and total recovery time ( $r = 0.63$ ,  $p = 0.00$  and  $r = 0.47$ ,  $p = 0.01$ ), respectively. No significant correlation is observed between the length of delayed time and RR time ( $r = 0.14$ ,  $p = 0.47$ ). The average RR time is 4.37 weeks. \*: significant difference.

and open-mouth X-rays can be performed cooperatively. As we all know, little children were difficult for the physical exam and the information taken from X-rays was limited. Secondly, all the patients were Fielding grade I or II, which may explain our success rate of conservative treatment. Thirdly, it is difficult to help predict the patients who can be treated successfully with closed techniques, based on the retrospective nature as well as variability in practice. Finally, a prospective study is warranted to eliminate the bias of selection, since some quantification of ROM, repeated CT scan was not available for all patients.

## Conclusion

Pediatric AARF patients who have a delay time  $< 3$  months can be treated with closed reduction successfully. The process of AARF consists of clinical recovery and radiological recovery, for clinical recovery, the longer the delayed time, the longer the traction time was needed, but the radiological recovery time was almost the same. The LDI and LJS on the anteroposterior of X-rays are convenient to estimate the progress of this condition during the treatment. Parents should be counseled about the need for a long process of this kind of disease and possible risk of recurrence and ultimate fusion.

## Authors' Note

Ping Xu and Zhiqiang Zhang are equal contributors. ZQZ and PX: Manuscript preparation, performed measurements, and statistical analysis. YMZ, JRM: Performed measurements, cases collection, and statistical analysis. CQ, DF: Cases collection. DHW: Study design, supervision, and validation. We declared that materials described in the manuscript, including all relevant raw data, will be freely available to any scientist wishing to use them for non-commercial purposes, without breaching participant confidentiality. This study was approved by The Ethics Committee of National Children's Medical Center & Children's Hospital of Fudan University. The IRB number: CHFU-ER-2020-198. These children were contacted by telephone to obtain verbal informed consent from the parents for the publication of their clinical data and medical images.


## Declaration of Conflicting Interests


The author(s) declared no potential conflicts of interest with respect to the research, authorship, and/or publication of this article.

## Funding

The author(s) received no financial support for the research, authorship, and/or publication of this article.

## ORCID iD

Zhiqiang Zhang, MD  <https://orcid.org/0000-0001-7698-7655>

Yiming Zheng, MD  <https://orcid.org/0000-0002-7947-2769>

## References

- Pang D, Li V. Atlantoaxial rotatory fixation: Part 1—biomechanics of normal rotation at the atlantoaxial joint in children. *Neurosurgery*. 2004;55(3):614-625. doi:10.1227/01.neu.0000134386.31806.a6
- Spiegel D, Shrestha S, Sitoula P, Rendon N, Dormans J. Atlantoaxial rotatory displacement in children. *World J Orthop*. 2017; 8(11):836-845. doi:10.5312/wjo.v8.i11.836
- Neal KM, Mohamed AS. Atlantoaxial rotatory subluxation in children. *J Am Acad Orthop Surg*. 2015;23(6):382-392. doi: 10.5435/jaaos-d-14-00115
- Pang D, Li V. Atlantoaxial rotatory fixation: Part 3—a prospective study of the clinical manifestation, diagnosis, management, and outcome of children with atlantoaxial rotatory fixation. *Neurosurgery*. 2005;57(5):954-972. doi:10.1227/01.neu.0000180052.81699.81
- Ishii K, Matsumoto M, Momoshima S, et al. Remodeling of C2 facet deformity prevents recurrent subluxation in patients with chronic atlantoaxial rotatory fixation: a novel strategy for treatment of chronic atlantoaxial rotatory fixation. *Spine*. 2011;36(4): E256-E262. doi:10.1097/BRS.0b013e3181d8bbdd
- Peng CW, Chou BT, Bendo JA, Spivak JM. Vertebral artery injury in cervical spine surgery: anatomical considerations, management, and preventive measures. *Spine J*. 2009;9(1):70-76. doi:10.1016/j.spinee.2008.03.006

7. Glotzbecker MP, Wasser AM, Hresko MT, Karlin LI, Emans JB, Hedequist DJ. Efficacy of nonfusion treatment for subacute and chronic atlanto-axial rotatory fixation in children. *J Pediatr Orthop*. 2014;34(5):490-495. doi:10.1097/bpo.0000000000000128
8. Park SW, Cho KH, Shin YS, et al. Successful reduction for a pediatric chronic atlantoaxial rotatory fixation (Grisel syndrome) with long-term halter traction: case report. *Spine*. 2005;30(15):E444-E449. doi:10.1097/01.brs.0000172226.35474.fe
9. Mihara H, Onari K, Hachiya M, Toguchi A, Yamada K. Follow-up study of conservative treatment for atlantoaxial rotatory displacement. *J Spinal Disord*. 2001;14(6):494-499. doi:10.1097/00002517-200112000-00005
10. Fielding JW, Hawkins RJ. Atlanto-axial rotatory fixation. (Fixed rotatory subluxation of the atlanto-axial joint). *J Bone Joint Surg Am*. 1977;59(1):37-44.
11. Alanay A, Hicazi A, Acaroglu E, et al. Reliability and necessity of dynamic computerized tomography in diagnosis of atlantoaxial rotatory subluxation. *J Pediatr Orthop*. 2002;22(6):763-765.
12. Samartzis D, Shen FH, Herman J, Mardjetko SM. Atlantoaxial rotatory fixation in the setting of associated congenital malformations: a modified classification system. *Spine*. 2010;35(4):E119-E127. doi:10.1097/BRS.0b013e3181c9f957
13. Wang S, Yan M, Passias PG, Wang C. Atlantoaxial rotatory fixed dislocation: report on a series of 32 pediatric cases. *Spine*. Jun 2016;41(12):E725-E732. doi:10.1097/brs.0000000000001414
14. Subach BR, McLaughlin MR, Albright AL, Pollack IF. Current management of pediatric atlantoaxial rotatory subluxation. *Spine*. 1998;23(20):2174-2179. doi:10.1097/00007632-199810150-00006
15. Martinez-Lage JF, Martinez Perez M, Fernandez Cornejo V, Poza M. Atlanto-axial rotatory subluxation in children: early management. *Acta Neurochir (Wien)*. 2001;143(12):1223-1228. doi:10.1007/s007010100018
16. Phillips WA, Hensinger RN. The management of rotatory atlanto-axial subluxation in children. *J Bone Joint Surg Am*. 1989;71(5):664-668.
17. Lee SC, Lui TN, Lee ST. Atlantoaxial rotatory subluxation in skeletally immature patients. *Br J Neurosurg*. 2002;16(2):154-157. doi:10.1080/02688690220131778
18. Landi A, Pietrantonio A, Marotta N, Mancarella C, Delfini R. Atlantoaxial rotatory dislocation (AARD) in pediatric age: MRI study on conservative treatment with Philadelphia collar—experience of nine consecutive cases. *Eur Spine J*. 2012;21(Suppl 1):S94-S99. doi:10.1007/s00586-012-2216-0