

# “Slim-Mesh” Technique for Giant Ventral Hernia

Silvio Alen Canton, MD, Claudio Pasquali, MD

## ABSTRACT

**Background and Objective:** We devised a sutureless “Slim-Mesh” technique to treat ventral hernias, including large-giant/massive ones, reduce intra- and postoperative complications, and lower operation time.

**Methods:** Between September 1, 2009 and October 31, 2020, 43 patients with large (10 – 14.9 cm)-giant (15 – 19.9 cm) and massive ( $\geq 20$  cm) ventral hernia were operated at our Department with the above technique. This was a prospective (79%)-retrospective study.

**Results:** This study comprised 22 males and 21 females. Mean age was 63 years. Large-giant and massive hernias were found intraoperatively in 37 and 6 cases respectively. Mean operation time for all hernias was 116 minutes, 104 for large-giant hernias, and 190 for massive. In 53.4% of cases, hernia-neck operative measurement was larger than preoperative size. In 25.5% of cases, laparoscopy found satellite hernias previously undetected by ultrasound- and/or computed tomography scan. A composite mesh and a non-composite mesh were used in 95% and 5% of cases respectively. For mesh fixation, titanium tacks and absorbable straps were used in 14% and 86% of cases respectively. Mean length of hospital stay was 2.3 days. Mean follow-up time was 3 years and 4 months. In our study, there were 5 early postoperative complications: 3 seromas, 1 trocar-site

hernia, and 1 case of cystitis. We found 2 late small symptomless recurrences (4.6%).

**Conclusion:** The sutureless “Slim-Mesh” technique facilitates intra-abdominal introduction, as well as the handling and fixation of giant and monster (36 × 26 cm) meshes. In our experience, “Slim-Mesh” is safe, simple, and fast, and economical even for large-giant/massive ventral hernia repair.

**Key Words:** Giant ventral hernia repair, Massive ventral hernia, Operation time, Postoperative pain, Slim-Mesh technique.

Department of Surgery, Oncology and Gastroenterology (DiSCOG), University of Padua, Padua, Italy. (Both authors)

**Acknowledgements:** The authors thank Andrew Bailey for his supervision of the English version and Carla Brighenti for her collaboration in editing the photographs.

**Disclosure:** none.

**Funding sources:** none.

**Conflict of interests:** none.

**Informed consent:** Dr. Silvio Alen Canton declares that written informed consent was obtained from the patient/s for publication of this study/report and any accompanying images.

**Address correspondence to:** Dr. Silvio Alen Canton, Department of Surgery, Oncology and Gastroenterology, University of Padua, Via Giustiniani, 2 - 35124 Padova, Padua, Italy, Phone (+39) 0498213264, Fax 0498213151, E-mail: alen@usa.com.

DOI: 10.4293/JSLS.2021.00079

© 2022 by SLS, Society of Laparoscopic & Robotic Surgeons. Published by the Society of Laparoscopic & Robotic Surgeons.

## INTRODUCTION

Ventral hernia (VH) repairs are among the most frequently performed surgical procedures<sup>1</sup> and a subset of long-standing primary or incisional hernia developed large/giant hernia sacs<sup>2</sup> following multiple repair attempts. These VH are usually described as large (L), giant (G) or huge, massive (M), or complex.<sup>2</sup>

The group L-G/M VH represents different clinical entities with numerous therapeutic possibilities, but there is no unanimous definition of what surgeons actually mean by “giant abdominal wall hernias”.<sup>3</sup> Some authors use the term G to mean all VH with wall defects greater than 30% of abdominal volume with loss of domain.<sup>4</sup> Korenkov et al. consider a VH to be L when its width or length is  $>10$  cm;<sup>5</sup> others regard a G VH as having a surface area of approximately 170 cm<sup>2</sup> (range: 100 – 225 cm<sup>2</sup>).<sup>6</sup> Chevrel proposed a classification based on the diameter of the wall defect, defining G VH as those being  $\geq 15$  cm in transverse dimension.<sup>6</sup> Recently, European Hernia Society (EHS<sup>4</sup>) classification has defined G VH as hernias larger than 10 cm with loss of domain. We considered a VH to be G or M when its diameter was 15 – 19.9 cm and  $\geq 20$  cm respectively, both without loss of domain.

In recent decades, the advent of a laparoscopic VH repair technique with transabdominal fixation sutures (LVHRTS)

has changed the management of VH, introducing a valid alternative to open surgery, with hernias being repaired with prosthetic materials<sup>6</sup> fixed by full-thickness stitches.

Despite good results in terms of the safety and low recurrence rate ensured by LVHRTS in the treatment of small (2 – 4.9 cm in diameter)/medium (5 – 9.9 cm) VH,<sup>4,5</sup> its use for L-G/M VH is still controversial.<sup>6</sup> In fact, the laparoscopic manipulation of a large/giant mesh and its first peritoneal fixation with  $\geq 4$  full-thickness stitches (often 1 every 3 – 6 cm,<sup>7</sup>) is difficult, as it involves generally long operative time, even over 240 minutes.<sup>5</sup> Since larger defects apply more stress on the fixation points of the prosthesis,<sup>7</sup> many surgeons do not consider, or even contraindicate LVHRTS, repairing L-G/M VH with open surgery only.<sup>6</sup>

The primary endpoint of our study is to evaluate our initial 11-year experience in treating 43 L-G/M VH with a novel laparoscopic technique called “Slim-Mesh” (SM),<sup>8-13</sup> focusing on operation time and intra- and postoperative complications.

## METHODS

From September 1, 2009 to October 31, 2020, 43 patients affected by large (L 10 – 14.9 cm)-giant (G 15 – 19.9 cm) and massive (M  $\geq 20$  cm without loss of domain) VH were enrolled at our Department of Surgery and managed with the SM technique.<sup>8-13</sup> The study design was prospective (79%, from September 1, 2016) and retrospective (21%); it was also descriptive and involved a single center.

All patients consented explicitly to the SM operation and the addition of their details to our registry, in accordance with the SM protocol approved by our Ethics Committee (contract no. 3902/AO/16).

The following data were obtained from clinical records: gender, age, body mass index (BMI), normal-weight (BMI 18.5 – 24.9 kg/m<sup>2</sup>), overweight (BMI 25.0 – 29.9 kg/m<sup>2</sup>), and class of obesity. Class of obesity according to the World Health Organization classification for obesity (Class I BMI 30.0 – 34.9, Class II 35.0 – 39.9, Class III 40.0 – 49.9,<sup>14</sup>) and superobesity (SO, using a common definition of SO as massive obesity with a BMI 50.0 – 59.9 kg/m<sup>2</sup>,<sup>15</sup>). Data also included American Society of Anesthesiologists (ASA) score, comorbidity, pre-operative diameter, or major axis (for oval VH) of VH-neck at physical examination, abdominal-wall ultrasound (US) and/or computed tomography (CT) -scan (small VH 2 – 4.9 cm, medium VH

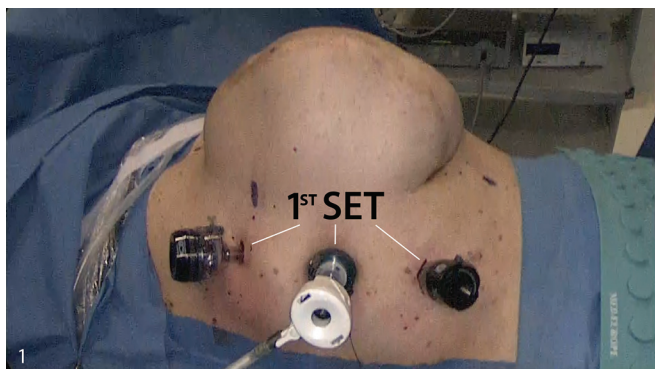
5 – 9.9 cm, and large [L] VH 10 – 14.9 cm according to Korenkov et al.’s classification and surgical treatment of incisional hernia.<sup>5</sup> We considered a VH to be G or M when its diameter was 15 – 19.9 cm or  $\geq 20$  cm respectively, both without loss of domain, when the VH was oval, we measured the major axis; type of L-G/M VH (primary, incisional, or traumatic), L-G/M VH recurrence, time of incisional hernia onset after surgery, presence of incarceration, possible emergency procedure, operative size of L-G/M VH, operation time, estimated blood loss at suction, possible conversion to open surgery, operative complications, and early postoperative complications (within 30 days after operation) e.g.. seromas, long-term, or chronic postoperative abdominal-wall pain when it lasted  $> 3$  months,<sup>16</sup> hemorrhages, bowel obstructions, infections, peritonitis, VH recurrences, port-site hernias, postoperative day of return to regular diet, length of hospital stay, reoperation, readmission to the hospital, and the follow-up with the final outcome, i.e. late complications (trocar-site hernias, recurrences, adherence syndrome). In this study, the author S.A.C. performed over 95% of cases.

The results were expressed as mean  $\pm$  standard error of the mean (SEM) standard deviation (SD) and a percentage (%). As regards the follow-up program, patients were interviewed during an outpatient visit, which included an examination at 1 and 4 weeks and 3 months postoperatively; patients underwent the same interview, including a review of abdominal-wall US results, 6 months after surgery, and then every year as per the follow-up surveillance plan.

## SM Surgical Technique

The 4 surgical phases of the SM technique have been detailed previously.<sup>8,9,11,13</sup> Briefly, the SM technique is as follows: the Hasson open technique was performed for laparoscopic access at the periphery of the abdominal wall, away from the defects and adhesions. The Hasson port was then inserted into the abdomen, which was inflated with CO<sub>2</sub> (pressure: 12 mm Hg). A 5.5-mm or 12-mm trocar was then placed under vision in the hypochondriac region and another 5.5-mm trocar at the iliac fossa (**Figures 1 and 2**). **Figure 3** shows a monster (33  $\times$  24 cm) SM before its intra-abdominal introduction, with the first set of 3 ports in a Class I Obese patient with M VH of 20  $\times$  10 cm.

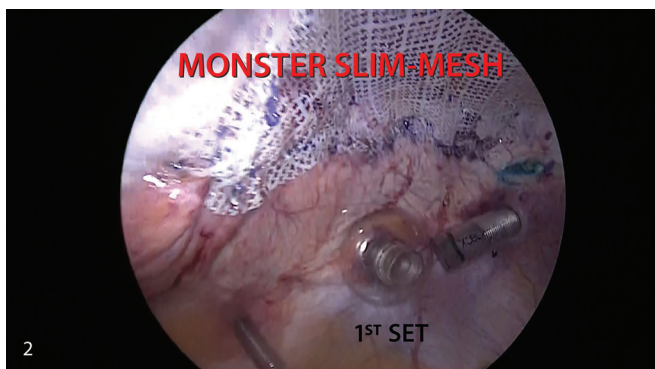For operations using a giant/massive (G/M) SM, we use from 3 to 6 ports (**Figure 4**): the first set of 3 ports are generally introduced into the abdomen, as mentioned



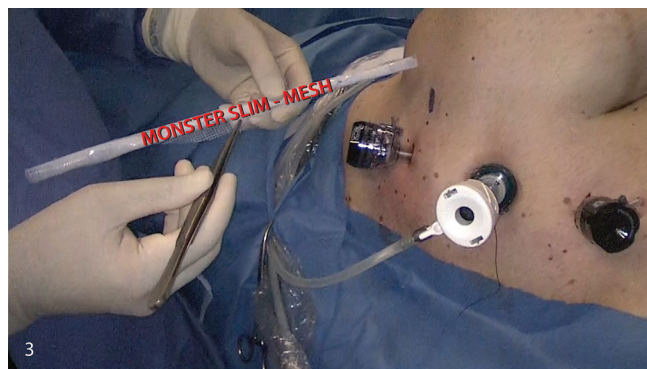
**Figure 1.** External view of the first set of 3 ports introduced into the right abdominal wall region in a class I obese patient with massive ventral hernia measuring 20 × 10 centimeters. The Hasson port is center, a 12 millimeter port is placed in the right hypochondria, and a 5.5 millimeter port at the right iliac fossa. Blue North, West, and South skin axial points are noted.

above for L SM (Figures 1-3); for a G SM and a M SM, a second set of 3 ports needs to be inserted under vision for the final SM fixation maneuvers at the contralateral region of the abdominal wall (Figures 4 and 5). The ports are several centimeters away from the first edge of the G/M SM to be fixed (Figure 6): one is a 12-mm port used to introduce the camera, and one or two are 5.5-mm trocars (Figures 4-6).

A 30-degree viewing angle camera to record HD videos was used, as were a laparoscopic grasping forceps, electric and harmonic scalpel, scissors, bipolar forceps, absorbable-straps/titanium-tacks stapler, and a mixer dissecting forceps to pull the SM's polypropylene 3-0 fixing stitches before their cutting and to unroll the SM (see SM Technique YouTube



**Figure 2.** Laparoscopic view of the first set of 3 ports from the left-hand side with the monster "Slim-Mesh" completely fixed. A part of the massive hernia defect can be viewed through the prosthesis. The Blue West peritoneal axial point is noted.

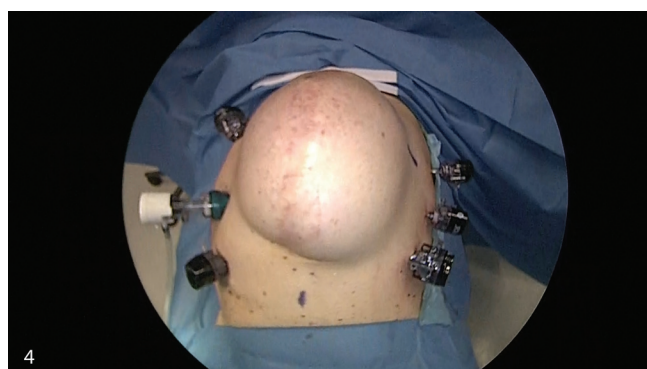

**Figure 3.** External view of the first set of 3 ports with the monster "Slim Mesh" before its intra-abdominal introduction through the 12 millimeter port in the right hypochondria.

videos).<sup>8,9,13</sup> The VH sac was not removed, and the hernia defect was not closed with interrupted sutures, according to the SM technique. Some blue peritoneal and skin tracers are shown in Figures 1–6. We mainly employed two Type III prostheses according to Amid's classification:<sup>17</sup> Proceed™ and B|Braun Omyra® (Table 1). Preferably, we employed the Ethicon SecureStrap™ Absorbable Fixation Device straps for mesh fixation (Table 1).

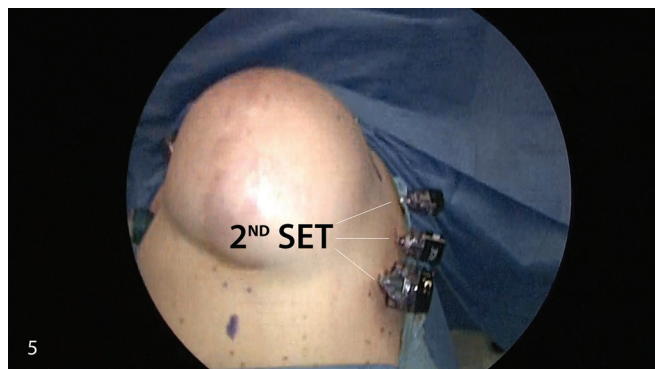
Hereunder is a crucial technical trick especially for the correct peritoneal orientation and fixation of a very large/monster (36 × 26 cm) SM.

Below are the operative steps to follow in the fourth phase: 1) visualize how to superimpose the SM's axial points (APs) onto the corresponding Peritoneal Axial Points (PAPs); 2) imagine a line between the north-south PAPs (Figure A and SM Technique YouTube videos No. 2);<sup>8,9,13</sup> carefully orientate



**Figure 4.** External view of the 6 ports. The 12 millimeter port of the second set is in the iliac fossa of the left abdominal region, along with two 5.5 millimeter ports located higher up the left-side of the abdomen. The Blue East and South skin axial points are noted.





**Figure 5.** External views of the second set of 3 ports located on the left-hand side.

the SM with two grasping forceps so that its upper edge is parallel to this line (Figure B and C); 4) superimpose the SM's first axial point (FAP) onto the first PAP and fix them (**Figure C**); 5) superimpose the SM's second AP onto the second PAP and fix; 6) superimpose the remaining two SM APs onto their corresponding PAPs and fix; 7) complete the SM fixation maneuvers.

This technical trick ensures that the SM is applied safely (**Figures 7–9**), without it crumpling and/or shifting; it also guarantees that the VH is overlapped ( $\geq 5$  cm for L-G/M VH repair) correctly with the same overlap length around the entire perimeter of the VH, according to SM technique.<sup>8,9,11,12,13</sup>

## RESULTS

In this study, a total of 43 patients with L-G/M VH underwent SM surgery at our institution over the 11 years between September 1, 2009 and October 31, 2020: 22 males and 21 females averaging  $63 \pm 2.3$  years (mean  $\pm$  SEM; range 33 – 82 years). **Table 1** summarizes the 43 VH patients' other preoperative clinical features, hernias, and operative characteristics.

The mean BMI and operation time in all 43 SM patients were  $30 \text{ kg/m}^2$  and  $116 \pm 6.9$  min. (mean  $\pm$  SEM) (range 52 – 295 min.) respectively.

We used Proceed<sup>TM</sup> and B|Braun Omyra<sup>®</sup> prostheses in 95% and 5% of cases respectively.

Repair time for 37 L-G VH cases and for 6 M VH cases was  $104 \pm 3.9$  min. (range: 52 – 155 minutes, mean  $\pm$  SEM) and  $190 \pm 32.6$  min. (range: 105 – 295 minutes, mean  $\pm$  SEM) respectively. None of the patients was converted

into laparotomy. Mean operative blood loss and complications are detailed in **Table 1**.

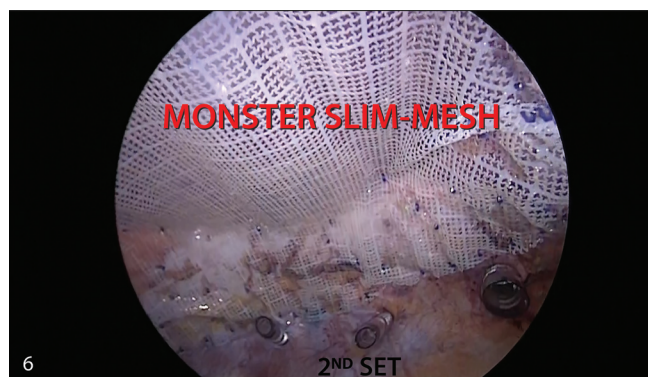There was one operative complication with transient bradycardia (30/min) in an 80-year-old man operated on for G VH. His BMI was  $27 \text{ kg/m}^2$  and he was affected by hypertension, extracranial, and intracranial vasculopathy. This complication was resolved with the administration of atropine.

A comparison between pre-operative/intraoperative VH neck-size, including the clinical characteristics of patients and VH features, is described in **Table 2**.

Fifteen cases of G VH at laparoscopy appeared small/medium at examination, US, and/or CT-scan. While 4 cases of G VH at pre-operative study proved to be wider at laparoscopy (**Table 2**). Moreover, 1 medium VH, plus 3 G VH at preoperative study, turned out to be M VH at laparoscopy (**Table 2**).

**Table 2** also details the BMI features of patients with discrepancy between pre-operative/intraoperative VH neck-size, and illustrates the cases where laparoscopy found additional abdominal-wall defects previously undetected by US and/or CT-scan.

In our study, 93% of patients resumed oral intake during the first postoperative day with a mean length of hospital stay of  $2.3 \pm 0.1$  days (mean  $\pm$  SEM). There were 3 early postoperative seromas (6.9%), which did not need surgery, 1 trocar site hernia, and 1 early case of cystitis; there were also 2 (4.6%) late small symptomless recurrences, but they did not



**Figure 6.** Laparoscopic view of the second set of 3 ports with the fixed monster “Slim Mesh” (33 × 24 centimeters). The ports are several centimeters away from the first edge to be fixed. The monster “Slim Mesh” is shown from the right-hand side with its 7 centimeter overlap, which extends from the massive ventral hernia's edges to the four peritoneal axial points. The Blue East peritoneal axial point can be noted between the two 5.5 millimeter ports above mentioned in Figure 4. A part of the massive hernia defect can be viewed through the prosthesis in this case.

**Table 1.**  
Patient and Hernia Clinical Features

Patients' Clinical Features	L (10 -14.9 cm)-G (15 - 19.9 cm) VH	M ( $\geq$ 20 cm) VH
Past medical history		
No. M/F (Total = 43)	16/21 (37)	6/0 (6)
Mean Age (years)	64	63
Mean BMI	31	29
No. ASA 3/2/1	11/26/0	2/4/0
No. D, C, Hy, AC, Cv	7/3/14/3/3	1/1/2/3/0
Social history		
No. T, A, SU	12/1/1	2/1/0
Surgical history		
No. Prior abdominal wall surgery	3	2
No. Prior VH open repair with S, Me, La	1S + 1Me, 2Me	2Me
Perioperative hernia features		
VH distribution by type (no. P/In/P+In)	17/19/1	1/5
No. In/Mean time (months) of VH onset after surgery	20/42	5/22
No. US/CT-scan/US+CT-scan	8/25/4	0/5/1
Sm/Med/L-G/M VH distribution (no.)	16/25/0	0/0/2
Operative features		
L-G/M VH distribution (no.)	37 (15 Sm/Med* + 22 L-G)	6 (1 Med* + 3L-G* + 2 M)
VH distribution by pre-intraoperative different size (no. 23, <b>Table 2</b> )	19	4
Satellite VH distribution (no. 11, <b>Table 2</b> )	8	3
Prosthesis (no. cases treated with MP/BB)	36/1	5/1
Fixation device (no. cases with TT/SS)	4/33	2/4
Mean operation time (Overall = 116 min.)	104 minutes	190 minutes
Mean BL (mL [range])	7 (0 – 38)	13 (2 – 53)
Complications (no.)	1**	0

M, male; F, female; BMI, body mass index; ASA, American Society of Anesthesiologists class; D, diabetes; C, coronary artery disease; AC, arrhythmogenic cardiomyopathy; Cv, cerebral vascular disease; Hy, hypertension; T, tobacco use; A, alcohol abuse; SU, steroid use; VH, ventral hernia; S, prior VH open repair with sutures; Me, prior VH open repair with mesh; La, laparoscopic mesh repair; S + Me, first VH open repair with sutures followed by a second operation with mesh; P, primary VH; In, incisional VH; P + In, primary VH plus incisional VH; US, abdominal-wall ultrasound; CT-scan, abdominal-wall computerized tomography; Sm, small VH at the pre-operative study (hernia neck size 2 – 4.9 cm, see **Table 2**); Med, Medium VH at the pre-operative study (hernia neck size 5 – 9.9 cm, see **Table 2**); Sm/Med\* VH, Sm/Med VH at US and/or CT-scan; L, large (hernia neck size 10 – 14.9 cm) VH; G, giant (hernia neck size 15 – 19.9 cm) VH; L-G\* VH, L-G VH at US and/or CT-scan; M, massive (hernia neck size  $\geq$  20 cm, without loss of domain) VH; MP, composite Mesh Proceed™ BB, noncomposite mesh B|BRAUN Omyra®; TT, titanium tacks (used from September 1, 2009 to September 30, 2013); SS, SecureStrap™ fixation device (used from October 1, 2013 to October 31, 2020); BL, blood loss, \*\*Cardiac Event (bradycardia).

require re-operation. We had no cases (0%) of long-term or chronic postoperative abdominal-wall pain.

In November 2020, the last follow-up for midterm results was carried out, with a minimum of one month after surgery.

Mean follow-up time was 3 years  $\pm$  5.3 months (range: 1 – 133 months, [mean  $\pm$  SEM]). A 11-year follow-up showed that two (4.6%) M VH patients each had one late postoperative complication: a small (< 2 cm) symptomless recurrence, which did not need re-operation.

**Table 2.**  
Comparison Between Pre/Operative Hernia Size

Cases	BMI/Normal or Overweight or Obesity Class or Superobesity	Type of VH/ Incarcerated VH	US VH- Neck size (cm)	CT-Scan VH Neck size (cm)	La L-G VH neck size (cm)	La M VH neck size (cm)	SVH	Difference between EX and IN VH neck size (cm)
La L-G VH								
Case 1	31/I	In/Inc	–	3	10	–	Yes	7
Case 2	31/I	P/Inc	–	3	10	–	0	7
Case 3	27/Ov	In/Inc	–	5	10	–	0	5
Case 4	23/N	P/No	–	6	10	–	0	4
Case 5	24/N	P/No	–	8	11	–	0	3
Case 6	51/SO	P/Inc	–	6	12	–	0	6
Case 7	31/I	In/Inc	–	10	12	–	Yes	2
Case 8	39/II	In/No	–	10	12	–	Yes	2
Case 9	30/I	In/Inc	–	7	13	–	Yes	6
Case 10	25/Ov	P/Inc	–	6	14	–	Yes	8
Case 11	27/Ov	In/Inc	–	12	16	–	Yes	4
Case 12	27/Ov	P/No	10	–	16	–	0	6
Case 13	35/II	P/Inc	6	–	10	–	0	4
Case 14	20/N	P/No	4	–	10	–	0	6
Case 15	27/Ov	In/Inc	–	5	11	–	0	6
Case 16	33/I	In/Inc	–	6	11	–	Yes	5
Case 17	34/I	In/Inc	–	8	14	–	0	6
Case 18	29/Ov	P/Inc	3	–	11	–	0	8
Case 19	31/I	P/Inc	–	5	10	–	Yes	5
La M VH								
Case 20	29/Ov	In/Inc	–	6	–	20	Yes	14
Case 21	29/Ov	In/Inc	–	18	–	20	Yes	2
Case 22	26/Ov	In/No	–	10	–	20	Yes	10
Case 23	30/I	In/Inc	–	14	–	21	0	7
Mean	30	–	–	–	–	–	–	6

BMI, body mass index; N, normal-weight; Ov, overweight; I, obesity Class I; II, obesity Class II; III, obesity class III; SO, super-obesity; VH, ventral hernia; P, primary hernia; In, incisional hernia; Inc, incarcerated VH; No, nonincarcerated VH; US, abdominal-wall ultrasound; CT-scan, abdominal-wall computerized tomography; La, laparoscopy; L-G, large-giant; M, massive; SVH, satellite ventral hernias; EX, external (US and/or CT-scan) VH neck size; IN, internal (operative) VH neck size.

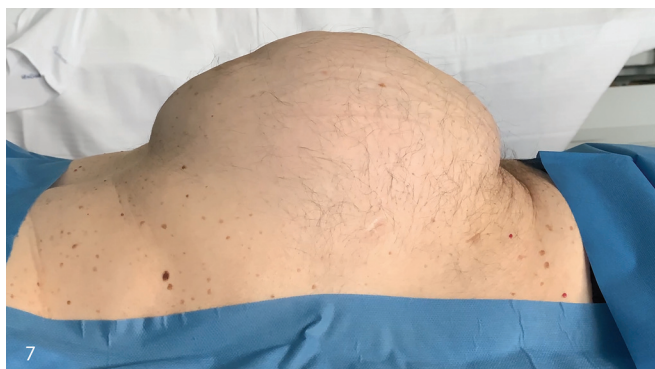
## DISCUSSION

L-G/M VH are a real handicap for patients<sup>4</sup> and require a specific therapeutic strategy that is extremely challenging for surgeons.<sup>4</sup>

There is a lack of consensus on the definition and standard treatment of L-G/M VH, as well as a shortage of data on the procedures and outcomes of these hernias, especially

from developing countries.<sup>3</sup> In fact, the choice of surgical approach (open or minimally invasive), prosthesis, and mesh-fixing method remains controversial.<sup>18</sup>

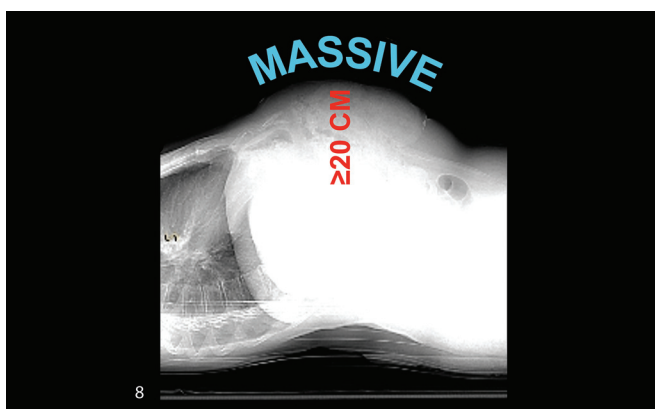
Our study of 43 patients with L-G/M VH treated with the SM procedure from September 1, 2009 to October 31, 2020 confirms the feasibility of this minimally invasive technique also for these types of VH. In fact, the SM technique enables simple intrabdominal introduction of a Giant/Monster



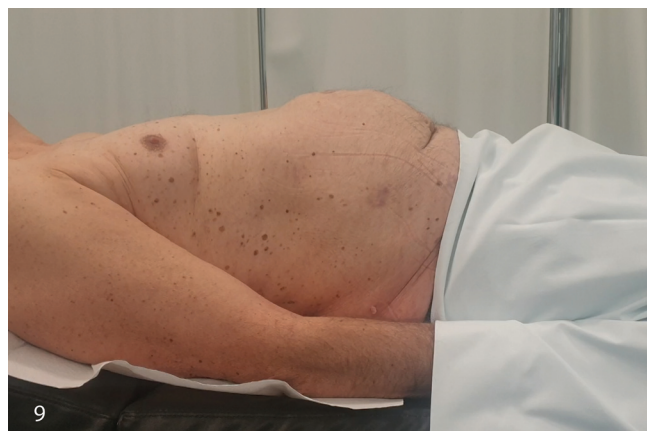**Figure 7.** Pre-operative photo of class I obese patient with massive ventral hernia while tensing his abdomen.

mesh through a 12 mm-port and fast and safe abdominal wall fixation.<sup>8-13</sup>

A total of 32.5% of our patients were overweight (BMI 25 – 29.9 kg/m<sup>2</sup>), 51.1% were obese (BMI 30 – 49.9 kg/m<sup>2</sup>), and 2.3% were superobese (BMI 50 – 59.9 kg/m<sup>2</sup>), with these three categories accounting for 85.9% of our patients; the remaining cases were normal-weight. The mean BMI of all 43 patients was 30 kg/m<sup>2</sup>. Therefore, our study suggests a correlation between high BMI and L-G/M VH. In 23 cases (53.4%, **Table 2**), hernia-neck operative measurement was larger than pre-operative size, with 17 (73.9%) of them presenting incarcerated VH (**Table 2**). This discrepancy occurs because we found laparoscopy to be more accurate than US and/or CT-scan when diagnosing VH; it was found especially in overweight-obese-superobese patients (20/23 cases [86.9%]), with mean BMI 31.1 kg/m<sup>2</sup>. Thirteen (65%) of these 20 had incisional hernias, and 11 (84.6%) of the 13 had VH incarceration, confirming the direct correlation between obesity and a major



**Figure 8.** Scout computed tomography image of the patient before “Slim Mesh” operation.



**Figure 9.** Postoperative photo of patient one year after operation while tensing his abdomen.

increase in intra-abdominal pressure, as shown in a recent study by the Heniford Group.<sup>19</sup>

In 25.5% of cases, laparoscopy found additional abdominal wall defects undetected by US and/or CT-scan (**Table 2**). As a general recommendation, a preliminary CT-scan should be carried out<sup>8,9,13</sup> on all patients undergoing L-G/M VH surgical repair. However, in a subset of patients with high ( $\geq 30$  kg/m<sup>2</sup>) BMI plus incarcerated incisional hernia, such as those above, the CT-scan may underestimate the size of the VH (**Table 2**). Therefore, we believe that laparoscopic exploration of the abdominal wall should be regarded as an important additional diagnostic examination to a preliminary CT-scan for optimal management of L-G/M VH treatment.

Respiratory distress is a common complication of laparoscopic VH repair reported in the literature.<sup>20</sup> In fact, during L-G/M VH repair, surgical pneumoperitoneum<sup>21</sup> is known to push the diaphragm into the thorax, raising pleural pressure and squeezing the lung, which could become stiffer,<sup>21</sup> particularly when operative time becomes long ( $\geq 240$  minutes<sup>22</sup>), with increased requirements for anesthetic drugs.<sup>23</sup> Prolonged CO<sub>2</sub> pneumoperitoneum<sup>20</sup> can cause significant morbidity with respiratory intra- and postoperative complications, especially in L-G/M VH patients >70 years old and/or with cardiopulmonary disease<sup>20</sup> and/or obesity.<sup>3</sup> This observation explains increased hospitalization time, early mortality (< 30 days after operation) and higher costs.<sup>24</sup>

This study demonstrated that a short mean operation time (overall, 116 minutes in our experience) and the ensuing reduced requirements for anesthetic drugs prevent early postoperative respiratory complications. Our mean operation time is lower than in Ferrari et al.’s 25 L-G/M VH



patients (205 minutes<sup>25</sup>) and Grande and al.'s 35 cases (159 minutes<sup>26</sup>); both sets of patients underwent LVHRTS.

The SM technique does not involve the plication of the abdominal-wall fascia or linea alba before the SM is fixed. In cases of L-G/M VH, the abdominal-wall fascia or linea alba (in midline hernias) is often already impaired and traumatized by previous operations,<sup>2</sup> or may be partially missing (**Figures 2 and 6**). Consequently, laparoscopic complete tension-free closure of the abdominal-wall is impossible. Moreover, laparoscopic plication of the fascia or linea alba may cause further trauma of both organs, especially in L-G/M VH patients, with increased risk of postoperative recurrence of up to 55%, as happens after open herniorrhaphy; it also leads to a bulging effect, resulting in cosmetic damage, and longer operation time.

Our postoperative seroma rate (6.9%) was probably due to the following reasons: partial but significant absence of abdominal-wall fascia and muscles, which is the hernia defect in many L-G/M VH patients, with significant reduction in damaged surgical area (**Figures 2 and 6**); the high percentage of obese-superobese patients treated, considering that the penetration of absorbable straps into their abdominal wall is reduced, thus resulting in little related damage; absence of full-thickness stitches,  $\geq 4$ , often 1 every 3 – 6 cm, and up to 20 in LVHRTS;<sup>7</sup> employment of absorbable straps whose tensile strength is reduced by 50% to the first 4 postoperative months, with reduced damage. Furthermore, we advised our operated L-G/M VH patients to use a belt for 3 – 6 months and to restrict activity.

The risk of the occurrence of other postoperative complications such as surgical site infection, wound dehiscence, seroma, mesh infection, abdominal compartment syndrome, enterocutaneous fistula, and hernia recurrence represented the main risks caused by the manipulation of a G/M mesh for L-G/M VH repair.

Under these circumstances, we have already stated<sup>8–13</sup> why we believe that the SM technique is safe. In fact, the mesh remains slim and compact, even when a G/M SM is used, thus increasing intrabdominal visibility and operating space, which is raised to the abdominal-wall front and well-clear of the organs, helping to reduce iatrogenic injuries.<sup>7,9,13,26</sup> We had no organ iatrogenic lesions, while Ferrari et al. reported 2.7% in 36 L-G/M VH patients.<sup>6</sup>

In addition, the increased intrabdominal visibility and operating space make it simpler to calculate the size of the SM overlap<sup>9,27,28</sup> during fixing maneuvers to reduce recurrence rate (4.6%). Grande documented a recurrence rate of 5.7% and a mean follow-up time of 24 months.<sup>26</sup>

In our series, the SM approach is straightforward as the SM is easy to maneuver; in fact, its elastic, tension<sup>9</sup> and adhesion forces help surgeons during all fixing maneuvers, ensuring optimal unrolling and tensioning.<sup>12</sup> We mainly employed two Type III prostheses according to Amid's classification:<sup>17</sup> Proceed<sup>TM</sup> and B|Braun Omyra<sup>®</sup>. Preferably, we fixed SM with absorbable straps, thus reducing long-term or chronic postoperative abdominal-wall pain.<sup>16</sup> The absence of full-thickness stitches for mesh fixation, as per the SM technique, also contributed to this reduction.

In addition, we consider the SM technique to be widely affordable because no expensive mesh positioning devices, such as the AccuMesh<sup>TM</sup> (Covidien<sup>29</sup>) or the Echo PS systems<sup>TM</sup> (Bard Davol<sup>29</sup>) are needed.

## CONCLUSIONS

We believe that laparoscopic repair of L-G/M VH using the sutureless SM technique has led to good outcomes (**Figures 7–9**), with operation time-saving and more acceptable rates of intraoperative and midterm postoperative complications. It is hoped that the SM approach will extend laparoscopy for L-G/M VH treatment to a larger number of patients.

## References:

1. Helgstrand F. National results after ventral hernia repair. *Dan Med J.* 2016;63(7):Pii: B5258.
2. Bikhchandani J, Fitzgibbons RJ, Jr. Repair of giant ventral hernias. *Adv Surg.* 2013;47:1–27.
3. Memon AA, Khan A, Zafar H, Murtaza G, Zaidi M. Repair of large and giant incisional hernia with onlay mesh: perspective of a tertiary care hospital of a developing country. *Int J Surg.* 2013; 11(1):41–45.
4. Passot G, Villeneuve L, Sabbagh C, et al. Fédération de Recherche en Chirurgie (FRENCH). Definition of giant ventral hernias: development of standardization through a practice survey. *Int J Surg.* 2016;28:136–140. Epub 2016 Feb.
5. Korenkov M, Paul A, Sauerland S, et al. Classification and surgical treatment of incisional hernia. Results of an experts' meeting. *Langenbecks Arch Surg.* 2001;386(1):65–73.
6. Ferrari GC, Miranda A, Sansonna F, et al. Laparoscopic management of incisional hernias  $>$  or  $=$  15 cm in diameter. *Hernia.* 2008;12(6):571–576.
7. Heniford BT, Park A, Ramshaw BJ, Voeller G. Laparoscopic repair of ventral hernias. *Ann Surg.* 2003;238(3):391–400.



8. Canton SA, Merigliano S, Pasquali C. Prosthetic mesh “slim-cigarette like” for laparoscopic repair of ventral hernias: a new technique without transabdominal fixation sutures. *Updates Surg.* 2016;68(2):199–203. <https://youtube.com/channel/UCyFjNeOTnQvRP-kZO-4BgUQ>.
9. Canton SA, Pasquali C. Laparoscopic repair of ventral/incisional hernias with the “Slim-Mesh” technique without transabdominal fixation sutures: preliminary report on short/midterm results. *Updates Surg.* 2017;69(4):479–483. <https://youtube.com/channel/UCyFjNeOTnQvRP-kZO-4BgUQ>.
10. 26th International Congress of the European Association for Endoscopic Surgery (EAES), London, United Kingdom, 30 May–1 June 2018: Poster Presentations (Online ISSN: 1432-2218. PP: 1-132. Poster 003). *Surg Endosc.* 2018.
11. 27th International Congress of the European Association for Endoscopic Surgery (EAES) Sevilla, Spain, 12–15 June 2019. *Surg Endosc.* 2019;33:485–781. Poster Presentations, Amazing Technologies, Abstract P005, and Oral Presentations, 0086–HERNIA ADHESIONS—Abdominal wall hernia).
12. 28th International Congress of the European Association for Endoscopic Surgery (EAES) Virtual Congress 23–26 June 2020. *Surg Endosc.* 2020(ABSTRACTS PRESENTATIONS. 190—HERNIA-ADHESIONS—Abdominal wall hernia).
13. Canton SA, Piotto A, Pasquali C. The impact of the “Slim-Mesh” Technique on operation time and short/midterm outcomes in 67 overweight, obese and superobese patients from a 10-year follow-up study. *J Metab Bariatr Surg.* 2020;9(2):24–32. <https://youtube.com/channel/UCyFjNeOTnQvRP-kZO-4BgUQ>.
14. Wang S, Majumdar SR, Padwal R. BMI, annual blood pressure measurements, and mortality in patients with obesity and hypertension: a retrospective cohort study. *Blood Press Monit.* 2015;20(1):32–38.
15. Slim K, Boirie Y. Superobesity and adjustable gastric banding. *J Visc Surg.* 2012;149(2):e83–e85.
16. Tsirlina VB, Colavita PD, Belyansky I, Zemlyak AY, Lincourt AE, Heniford BT. Preoperative pain is the strongest predictor of postoperative pain and diminished quality of life after ventral hernia repair. *Am Surg.* 2013;79(8):829–836.
17. Amid PK. Classification of biomaterials and their related complications in abdominal wall hernia surgery. *Hernia.* 1997;1(1):15–21.
18. Speranzini, Manlio Basilio and Deutsch, Claudio Roberto Grandes h ernias incisionais. ABCD. Arquivos Brasileiros de Cirurgia Digestiva (S o Paulo) [online]. 2010, v. 23, n. 4 [Accessed 6 January 2022], pp. 280-286. Available from: <https://doi.org/10.1590/S0102-67202010000400015>. Epub 19 Jan 2011. ISSN 2317-6326. <https://doi.org/10.1590/S0102-67202010000400015>.
19. Tsereteli Z, Pryor BA, Heniford BT, Park A, Voeller G, Ramshaw BJ. Laparoscopic ventral hernia repair (LVHR) in morbidly obese patients. *Hernia.* 2008;12(3):233–238. Epub Dec 4.
20. Cagli a P, Tracia A, Buffone A, et al. Physiopathology and clinical considerations of laparoscopic surgery in the elderly. *Int J Surg.* 2016;33(Suppl 1):S97–S102. Epub May 30.
21. Loring SH, Behazin N, Novero A, et al. Respiratory mechanical effects of surgical pneumoperitoneum in humans. *J Appl Physiol.* (1985). 2014;117(9):1074–1079. Epub Sep 11.
22. Singh S, Swarer K, Resnick K. Longer operative time is associated with increased post-operative complications in patients undergoing minimally-invasive surgery for endometrial cancer. *Gynecol Oncol.* 2017;147(3):554–557. Epub 2017 Oct 2.
23. Raftopoulos I, Vanuno D, Khorsand J, Ninos J, Kouraklis G, Lasky P. Outcome of laparoscopic ventral hernia repair in correlation with obesity, type of hernia, and hernia size. *J Laparoendosc Adv Surg Tech A.* 2002;12(6):425–429.
24. Ruscic KJ, Grabitz SD, Rudolph MI, Eikermann M. Prevention of respiratory complications of the surgical patient: actionable plan for continued process improvement. *Curr Opin Anaesthesiol.* 2017;30(3):399–408.
25. Ferrari GC, Miranda A, Di Lerna S, et al. Laparoscopic repair of incisional hernia: outcomes of 100 consecutive cases comprising 25 wall defects larger than 15 cm. *Surg Endosc.* 2008;22(5):1173–1179. Epub 2007 Dec 20.
26. Grande M, Lisi G, Campanelli M, et al. Laparoscopic treatment of giant ventral hernia: experience of 35 patients. *Surg Technol Int.* 2017;10(30):165–169. [Epub ahead of print].
27. Bittner R, Bingener-Casey J, Dietz U, et al. Guidelines for laparoscopic treatment of ventral and incisional abdominal wall hernias International Endohernia Society (IEHS)-part-1. *Surg Endosc.* 2014;28(1):2–25.
28. El-Bakary TA, Abdelaziem S, Hafiz AA, Hashish MS. Short-term outcome of “double crown” tackers mesh fixation in laparoscopic ventral hernia repair. *SS.* 2015;6(3):100–108.
29. Misiakos EP, Patapis P, Zavras N, Tzanetis P, Machairas A. Current trends in laparoscopic ventral hernia repair. *JLS.* 2015;19(3):e2015.00048.