

Original Article

Virtual autopsy to assess sacral anatomy: Conditions for a minimal invasive approach to the spinal canal through the hiatus sacralis

Andrea Bodmer, Steffen Ross¹, Andreas Raabe, Jürgen Beck, Christian T. Ulrich, Philippe Schucht

Department of Neurosurgery, Inselspital, Bern University Hospital, Freiburgstrasse, Bern, ¹Department of Radiology, Spital Männedorf, Asylstrasse, Männedorf, Switzerland

E-mail: Andrea Bodmer - andreabodmer@yahoo.com; Steffen Ross - steffen.ross@me.com; Andreas Raabe - andreas.raabe@insel.ch; Jürgen Beck - juergen.beck@insel.ch; Christian T. Ulrich - christian.ulrich@insel.ch; *Philippe Schucht - philippe.schucht@insel.ch

*Corresponding author

Received: 17 August 17 Accepted: 19 September 17 Published: 06 December 17

Abstract

Background: Despite multiple advantages of minimally invasive techniques in spinal surgery, the currently used approaches may lead to postoperative pain and spinal instability. As a natural orifice, the hiatus sacralis offers a nontransmuscular alternative entry point for endoscopic approaches. In this study, we collected data about the complex anatomical conditions of the sacral canal as a basis for the development of a sacral endoscope.

Methods: We retrospectively evaluated 192 postmortem human cadaveric specimens with computed tomography (CT). The anatomical conditions of the sacrum and lumbar spine were analyzed, including assessment of the lateral and anteroposterior diameters, measurement of the cross-sectional area of the sacral canal at the lumbosacral transition, hiatus sacralis, and the narrowest point of the sacral canal.

Results: The narrowest anteroposterior diameter was >2.3 mm in 95% of the cases; the width was >13 mm in 95% of the cases. The narrowest point was located at the hiatus in 72% of the cases. The angle of sacral kyphosis was less than 30° and less than 50° in lumbar lordosis in 95% of the cases. A length shorter than 288 mm was measured in 95% of the cases. Anatomical conditions in male and female sacra were comparable.

Conclusions: The narrow anteroposterior diameter is the key limiting feature for using the canalis sacralis as a natural entry point into the spinal canal. Sacroscopy will require endoscopes with a flattened shape, with parallel arrangement of instruments and flexibility to accommodate the varied dorsal and ventral curvatures.

Key Words: Chronic lumbar pain, endoscopy, minimally invasive surgery, sacral anatomy, sacroscopy, spinal surgery

Access this article online

Website:

www.surgicalneurologyint.com

DOI:

10.4103/sni.sni_313_17

Quick Response Code:

This is an open access article distributed under the terms of the Creative Commons Attribution-NonCommercial-ShareAlike 3.0 License, which allows others to remix, tweak, and build upon the work non-commercially, as long as the author is credited and the new creations are licensed under the identical terms.

For reprints contact: reprints@medknow.com

How to cite this article: Bodmer A, Ross S, Raabe A, Beck J, Ulrich CT, Schucht P. Virtual autopsy to assess sacral anatomy: Conditions for a minimal invasive approach to the spinal canal through the hiatus sacralis. *Surg Neurol Int* 2017;8:290.

<http://surgicalneurologyint.com/Virtual-autopsy-to-assess-sacral-anatomy:-Conditions-for-a-minimal-invasive-approach-to-the-spinal-canal-through-the-hiatus-sacralis/>

INTRODUCTION

Epiduroscopic spinal surgery as a minimally invasive procedure was first reported in the 1930s when Burman used arthroscopic equipment for the assessment of spinal pathology.^[3] The first use of small flexible fiberoptic scopes was published by Shimoji *et al.* in 1991.^[9]

In theory, minimally invasive (MIS) endoscopic techniques offer shorter operating times, short rehabilitation period, and reduced tissue trauma compared with routine open approaches.^[6,13] Despite these advantages, epidural scarring, spinal instability, and operation-induced disorders of the innervation of the back muscles are common complications, often leading to chronic and recurrent back pain.^[4,5,7,10,12] Alternatively, the hiatus sacralis, localized immediately below a thin layer of skin, offers a natural entry point and superficial, potential easier access to the spinal canal while limiting potential muscle damage. Notably, in this series, exploratory use of sacroscopy was aborted in 10% of the cases due to anatomical limitations of the hiatus sacralis.^[8] Further investigations of the anatomical conditions of the sacral canal are warranted to develop a viable endoscopic approach.

MATERIALS AND METHODS

Sacral and lumbar spinal anatomical measurements were based on computed tomography (CT) data sets from the Institute of Forensic Medicine associated. Postmortem CT was carried out as a part of the routine forensic investigation, known as “Virtual Autopsy”. This included a noninvasive autopsy performed on a human body (developed in Switzerland). We enrolled 192 cases, 18–89 years of age, in whom a CT scan of the abdomen had been performed for forensic appraisal (2009–2010) [Table 1]. Exclusion criteria are shown in Table 2. Imaging was executed in supine position on a 6-row multi-slice CT scanner (Somatom Emotion 6, Siemens Medical Solutions, Erlangen, Germany). Raw data acquisition was performed with the following settings: 130 kV; 200 mAs; collimation, 6×1 mm whole body. Image reconstruction was performed at slice thickness 1.25 mm with an increment of half the slice thickness in soft tissue, and bone-weighted reconstruction kernel. Image review, multiplanar reconstructions (MPR), and measurements were performed on a PACS-workstation (IDS/, Sectra AB). The lateral and anteroposterior (AP) diameters as well as the sectional area of the sacral canal were recorded at the lumbosacral transition, at the hiatus sacralis, and at the level of the narrowest point of the sacral canal defined by human eyes [Figures 1-4]. Length and bending of the spinal canal were measured from the upper rim of the first lumbar vertebral body down to the hiatus sacralis. Bending is described in angle degrees and was measured

Table 1: Age and sex distribution of cases included in the study

Age group (years)	Men (n)	Women (n)	Total (n)
18-35	17	4	21
36-50	24	8	32
51-65	18	9	27
>66	12	8	20
Total	71	29	100

Table 2: Criteria and number of cases excluded from the study

Criterion for exclusion	Men (n)	Women (n)	Total (n)
Poor image quality	29	21	50
Incomplete data	24	18	42
Total	53	39	92

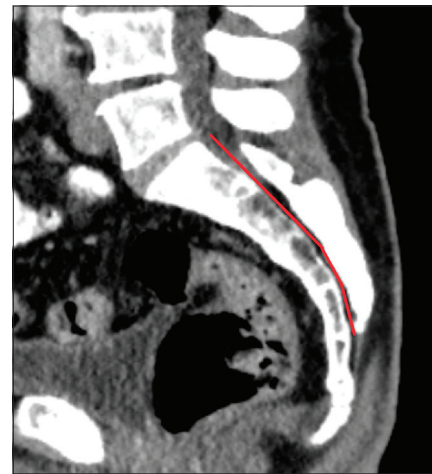

Figure 1: Sagittal view of the sacrum. Bending of the sacral and lumbar spine demand flexibility of the endoscope of at least 30° and 50° to accommodate the ventral and dorsal curvature, respectively. (Figure kindly provided by the Spital Oberengadin, Samedan)

in the center of the sacral and lumbar canal, indicated as a difference from the straight line (180°) corresponding to kyphosis and lordosis.

RESULTS

One hundred cases were included in this analysis; 71 were males and 29 were females. Details of age and sex distribution are outlined in Table 1. As shown in Table 3, the AP diameter was wider than 2.5 mm in 95% of the cases, whereupon the narrowest point was found at 5–13 mm cranial of the hiatus in 28 cases, other 72 cases showed the narrowest point at the hiatus itself.

The narrowest point of the lateral diameter was found cranial of the hiatus sacralis in 46 cases and measured more than 13 mm in 95% of the cases. The surface areas

of the sacral canal ranged 32–147 mm² and 26–159 mm² for females and males, respectively.

Regarding the angles of sacral kyphosis and lordosis see Table 4. In 11 cases, the angles were 180°, and therefore, did not show any curvature. Measurements of the length from the upper rim of the first lumbar vertebral body to the hiatus sacralis along the spinal canal varied from 210 to 305 mm; however, 97% of the cases presented with lengths <290 mm [Table 5]. None of the cases showed statistically significant differences in anatomical conditions between male and female sacra.

DISCUSSION

Measurement of the anteroposterior diameter

In an autopsy specimen study by Witte *et al.*,^[11] data from 117 sacra of cases aged 69 years and older were measured

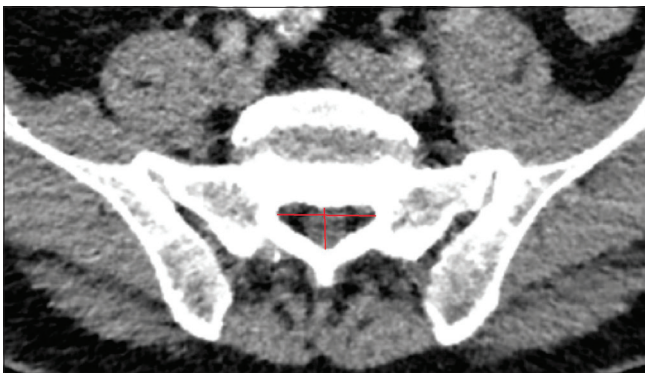

Figure 2: Axial view of the lumbosacral transition. To reach the lumbosacral transition for surgical interventions an endoscope with a minimal length of 290 mm should be developed to accommodate 95% of the patients. (Figure kindly provided by the Spital Oberengadin, Samedan)

to determine geometric coordinates. They found an average AP diameter of 5 mm at a 90-mm distance in the caudal direction of the lumbosacral transition. At this point, the minimal AP diameter was 2.45 mm. Data of the location of the absolute narrowest point in the sacral canal were not provided. In this study, we found this to be the hiatus in 72% of our cases.

Measurement of the lateral diameter

The lateral diameter in the Witte *et al.* study measured 14 mm ± 5 mm at the upper rim of S1 and 8 mm ± 5 mm at S4. The distance from the lumbosacral transition to the hiatus sacralis ranged from 85 to 155 mm. They also recorded the degrees of bending of the sacral canal up to 60°. It is yet unclear whether these findings in the geriatric population are applicable to the general population, as degenerative changes might have influenced the dimensions of the sacral canal. Moreover, materials based on autopsy specimens might contain artifacts that jeopardize the conclusions due to manipulation and dissection of the bony structures. To work more precisely and to get closer to the *in-vivo* status, our measurements were based on CT scans instead of measuring by millimeter grids.

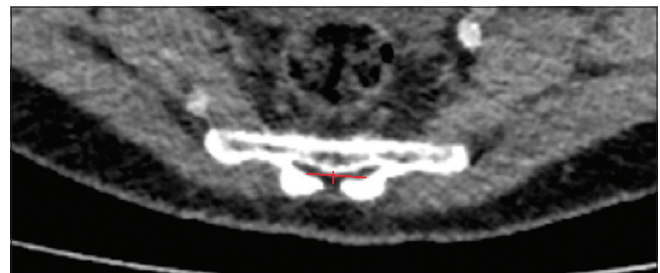


Figure 3: Axial view of the hiatus. The narrowest anteroposterior diameter of the canalis sacralis is located at the hiatus in 72% of the cases. (Figure kindly provided by the Spital Oberengadin, Samedan)

Table 3: Anteroposterior and lateral diameters; area in the sacral canal

Population [%]	ap-d [mm]		lat-d [mm]		area [mm ²]	
	Hiatus > x	Narrowest point > x	Hiatus > x	Narrowest point > x	Hiatus > x	Narrowest point > x
96-100	2.5	2	13	13	45	30
91-95	3	2.5	15	14	55	40
86-90	3	3	16	14	60	45
81-85	3	3	17	16	60	50
76-80	3.5	3.5	ns	16	65	55
71-75	3.5	3.5	ns	16	ns	60

ap-d: Antero-posterior diameter, lat-d: Lateral diameter, ns: Not specified, x: Length in millimeters

Table 4: Curvature of the lumbar and sacral canal of cases included in the study, indicated in angle degrees

Degree of bending = angle α [°]	deviation from the straight line (=180°) angle β [°]	Population [%] showing curvature <β. Lumbar lordosis	Population [%] showing curvature <β. Sacral kyphosis
130	50	94	100
140	40	70	100
150	30	<70	95
160	20	<70	67

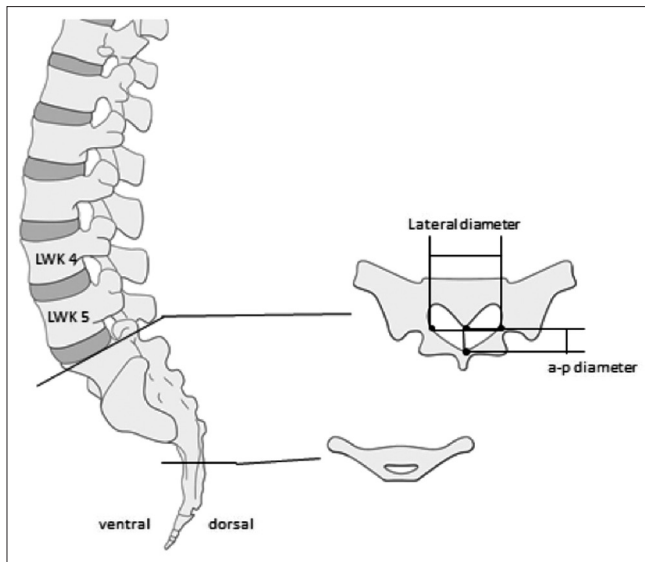


Figure 4: Measurements of the angles and diameters. The lateral and anteroposterior diameters as well as the sectional area were recorded at the lumbosacral transition, at the hiatus sacralis, and at the level of the narrowest point of the sacral canal on 100 CT-datasets

Table 5: Length of the lumbar and sacral canal in cases included in the study

Population [%] showing $x < D$	distance D Hiatus-L1 [mm]
96.8	290
92.5	280
86	270

However, our measurements were, as mentioned above, made in the supine position. As anatomy most often is position-dependent, measures of the lumbosacral angle might differ in prone position perioperatively.

Suggested use of flexible endoscope

Based on their findings, Witte *et al.* suggested the use of a flexible circular-shaped endoscope not exceeding a diameter of 4 mm. Due to their measurement and a trial of an arthroscope in five cadavers, they found that an endoscope of 4 mm would require surgical enlargement of the sacral canal to obtain access to the spinal canal in at least 20% of the patients.

Due to our findings of anatomical conditions and to accommodate 95% of the patients we suggest a flat-shaped endoscope having a vertical height of less than 2.5 mm, a width of less than 13 mm, and a minimal length of 290 mm.

Navigation issues with endoscopy

Several studies mentioned technical issues regarding navigation of the flexible but instable endoscope (2.5–3 mm diameter) through the spinal canal.^[7,8] Furthermore, mechanical operations proved to be difficult

due to the miniscule size of working tools; for example, extraction of greater tissue components was shown to be difficult.^[7]

Ruetten *et al.* also reported hemorrhages during mechanical processing, mostly due to surgical detachment of adhesions found in the dorsal epidural space of patients that had been previously operated upon.^[7]

With respect to the anatomic conditions of the sacral canal and with consideration of the issues mentioned above, we believe the optimal endoscope should have a flat shape with similarly flattened instruments. Such geometry will provide better access to the spinal canal and will improve stability of the endoscope. A flexibility of 50° in the dorsal direction and 30° in the ventral direction would lead to better guidance. If in rare cases penetration into the spinal canal is interrupted due to a narrow hiatus sacralis, a simple enlargement of the hiatus by 1–2 cm in a cauda-cranial direction could be done to overcome the resistance. The dorsomedian connective tissue band fixing the dura mater to the flaval ligaments and narrowing the epidural space in the midline^[1,2] predisposes the endoscope to be used in the ventral epidural space.

CONCLUSIONS

In conclusion, the hiatus sacralis presents a natural orifice for sacroscopy. It also offers an additional site for MIS. Our study delineates the requirement of a future sacral endoscope, as mentioned above. Further technical studies are warranted for the construction of an adequate endoscope.

Financial support and sponsorship

Nil.

Conflicts of interest

There are no conflicts of interest.

REFERENCES

- Blomberg R. The dorsomedian connective tissue band in the lumbar epidural space of humans: An anatomical study using epiduroscopy in autopsy cases. *Anesth Analg* 1986;65:747-52.
- Blomberg RG, Olsson SS. The lumbar epidural space in patients examined with epiduroscopy. *Anesth Analg* 1989;68:157-60.
- Burman MS. Myelography or the direct visualization of the spinal cord and its contents. *J Bone Joint Surg* 1931;13:695-6.
- Fritsch EW, Heisel J, Rupp S. The failed back surgery syndrome: Reasons, intraoperative findings, and long-term results: A report of 182 operative treatments. *Spine* 1996;21:626-33.
- Kotilainen E, Valtonen S. Clinical instability of the lumbar spine after microdiscectomy. *Acta Neurochir (Wien)* 1993;125:120-6.
- Ruetten S, Komp M, Merk H, Godolias G. Surgical treatment for lumbar lateral recess stenosis with the full-endoscopic interlaminar approach versus conventional microsurgical technique: A prospective, randomized, controlled study. *J Neurosurg Spine* 2009;10:476-85.
- Ruetten S, Meyer O, Godolias G. [Epiduroscopic diagnosis and treatment of epidural adhesions in chronic back pain syndrome of patients with previous

- surgical treatment: First results of 31 interventions]. *Z Für Orthop Ihre Grenzgeb* 2002;140:171-5.
8. Ruetten S, Meyer O, Godolias G. Endoscopic surgery of the lumbar epidural space (epiduroscopy): Results of therapeutic intervention in 93 patients. *Minim Invasive Neurosurg* 2003;46:1-4.
 9. Shimoji K, Fujioka H, Onodera M, Hokari T, Fukuda S, Fujiwara N, et al. Observation of spinal canal and cisternae with the newly developed small-diameter, flexible fiberscopes. *Anesthesiology* 1991;75:341-4.
 10. Sihvonen T, Herno A, Paljärvi L, Airaksinen O, Partanen J, Tapaninaho A. Local denervation atrophy of paraspinal muscles in postoperative failed back syndrome. *Spine* 1993;18:575-81.
 11. Witte H, Hellweg S, Witte B, Grifka J. [Epiduroscopy with access via the sacral canal. Some constructional equipment requirements from the anatomic and biomechanical viewpoint]. *Biomed Tech (Berl)* 1997;42:24-9.
 12. Yadav YR, Parihar V, Namdev H, Agarwal M, Bhatele PR. Endoscopic interlaminar management of lumbar disc disease. *J Neurol Surg Part Cent Eur Neurosurg* 2013;74:77-81.
 13. Yamada H, Yoshida M, Hashizume H, Minamide A, Nakagawa Y, Kawai M, et al. Efficacy of novel minimally invasive surgery using spinal microendoscope for treating extraforaminal stenosis at the lumbosacral junction. *J Spinal Disord Tech* 2012;25:268-76.