

Nocardia infection following intraocular surgery: Report of seven cases from a tertiary eye hospital

Devesh Sharma, Umang Mathur, Abha Gour, Manisha Acharya, Nidhi Gupta, Neelam Sapra

Purpose: To study the outcome of ocular nocardiosis following intraocular surgery. **Materials and Methods:** A retrospective review of medical records of all postoperative cases of culture proven *Nocardia* infection over a period of 3 years, from October 2010 to September 2013, was performed. Microbiological analysis was performed for all cases and included smears and cultures. Fortified 2% amikacin eye drops were the mainstay of treatment. Surgical intervention was performed in case of nonresponse to medical therapy or suspected endophthalmitis. **Results:** Seven cases of culture proven *Nocardia* infection were seen. All cases had been operated in a hospital surgical facility. Six followed phacoemulsification, and one followed a secondary intraocular lens implantation. Four patients were part of a cluster infection. The mean duration between the primary surgical procedure and presentation was 16.14 ± 9.82 days. Five patients had infiltrates at the site of the surgical incision. One each had endophthalmitis and panophthalmitis. Six eyes required surgical intervention. Infection was seen to resolve in four eyes. Two eyes went into phthisis, and one was eviscerated. Only two of the six eyes, where in surgical intervention was performed early, obtained a final visual acuity of 20/60. **Conclusion:** Early surgical intervention, before the involvement of the anterior chamber, may help preserve the anatomic and functional integrity of the eye.

Key words: Endophthalmitis, intraocular surgery, ocular infection, ocular nocardiosis

Nocardia is filamentous, Gram-positive, weakly acid-fast bacteria, frequently found as soil saprophytes. Ocular nocardiosis has most commonly been associated with infectious keratitis, with the reported incidence varying from 0.3% to 4.2%.^[1-3] Postoperative infections after intraocular surgical procedures caused by *Nocardia* are rare and potentially sight-threatening. Two series that studied the microbiological spectrum of endophthalmitis after intraocular surgery did not list *Nocardia* as a causative organism.^[4,5] The outcomes of *Nocardia* endophthalmitis have not been studied extensively, with only one large series on the subject, that reported a generally poor visual outcome.^[6] However, encouraging results have been noted in isolated case reports.^[7,8] The present retrospective analysis was conducted to evaluate the clinical outcomes of *Nocardia* infections after intraocular surgery.

Materials and Methods

We retrospectively reviewed the medical records of all postoperative cases of culture proven *Nocardia* infection that presented to our hospital over a period of 3 years, from October 2010 to September 2013. The parameters analyzed included predisposing factors, time between onset and presentation, presenting visual acuity, clinical examination, microbiologic data, antibiotic sensitivities of isolates, response to treatment, need for surgical intervention, time duration to surgical intervention from onset of symptoms, and the final best-corrected visual outcome.

Department of Cornea and Anterior Segment, Dr. Shroff's Charity Eye Hospital, New Delhi, India

Correspondence to: Dr. Umang Mathur, Dr. Shroff's Charity Eye Hospital, 5027, Kedarnath Road, Daryaganj, New Delhi - 110 002, India. E-mail: umang@sceh.net

Manuscript received: 29.03.17; Revision accepted: 31.03.17

Access this article online

Website:

www.ijo.in

DOI:

10.4103/ijo.IJO_564_16

Quick Response Code:



At presentation, a complete ocular and systemic history was taken. A detailed slit-lamp evaluation was performed, and characteristics of the infiltrate were recorded, including the size, depth and location, and the height of the hypopyon, if present. B-scan ultrasonography was performed in case of suspected posterior segment involvement.

The type of sample taken for microbiological analysis depended on the clinical presentation of the case—corneal scraping, anterior chamber (AC) tap, or tissue biopsy. In the initial microbiology workup, samples were smeared onto glass slides for Gram stain and 10% potassium hydroxide wet mount preparations. Acid-fast staining was performed when *Nocardia* was suspected on Gram's stain. For culture, samples were plated onto blood agar, chocolate agar, brain-heart infusion broth, and on Sabouraud's dextrose agar. Blood agar, chocolate agar, and brain-heart infusion broth were maintained at 37°C for a period of 14 days. Sabouraud's dextrose agar was incubated at 26°C for 21 days. Growth of *Nocardia* species on culture was noted as chalky white colonies. This growth was then subjected to acid-fast staining and also subcultured on Lowenstein-Jensen media, which confirmed *Nocardia*. In case the culture was suspected to have growth of *Nocardia*, the smears that were initially stained with Gram's stain were destained with acetone and subjected to acid-fast staining.

This is an open access article distributed under the terms of the Creative Commons Attribution-NonCommercial-ShareAlike 3.0 License, which allows others to remix, tweak, and build upon the work non-commercially, as long as the author is credited and the new creations are licensed under the identical terms.

For reprints contact: reprints@medknow.com

Cite this article as: Sharma D, Mathur U, Gour A, Acharya M, Gupta N, Sapra N. *Nocardia* infection following intraocular surgery: Report of seven cases from a tertiary eye hospital. Indian J Ophthalmol 2017;65:371-5.

using 1% sulfuric acid. Antibiotic sensitivities of the isolates were obtained by the disc-diffusion method.

Amikacin eye drops (2%) were the mainstay of medical therapy once the causative organism was established. Surgical intervention was performed in case of nonresponse to medical therapy, or associated endophthalmitis. Patients were followed up every 24–48 h in the first week, 2–3 times a week for the next 2 weeks, and then weekly for a month.

Results

Over a 3-year period from October 2010 to September 2013, seven patients were diagnosed with culture-positive *Nocardia* infection after intraocular surgery. The mean age was 58.71 ± 10.05 years (age range: 35–68 years). There were four male and three female patients. Three patients were diabetics under treatment. All seven patients were operated on in a hospital surgical facility. One case followed an in-house surgery while six patients were referred from elsewhere. Four patients were part of a cluster infection, having had phacoemulsification on a single day in the same operation room. However, these patients were referred to our hospital at different times, and so the severity of presentation differed. Out of the seven cases, six followed phacoemulsification with intraocular lens (IOL) implantation and one followed secondary IOL surgery for aphakia. All the infections were predominantly wound infections with intra-ocular extension, presumably due to the reuse of the surgical blades.

The time interval between the surgical procedure and presentation varied from 7 to 30 days (mean = 16.14 ± 9.82 days). One patient had undergone core vitrectomy elsewhere, for associated endophthalmitis 2 weeks before presentation. Visual acuity at presentation ranged from 20/30 to no light perception.

On clinical examination, five patients were seen to have infiltrate at the site of the surgical incision. The infiltrates appeared fluffy, dense, frequently involved the deep corneal stroma, had a yellowish tinge and had fairly well-defined margins with a limited zone of surrounding edema [Fig. 1]. In addition, frank exudation in the AC was seen in two patients, one of which had a localized exudate on the iris. One patient showed associated involvement of the vitreous cavity on B-scan

ultrasonography in the form of multiple dot and membrane echoes and was diagnosed with endophthalmitis [Fig. 2]. A diagnosis of panophthalmitis was made in one patient who had restricted ocular motility, posterior segment involvement on ultrasound, and denied light perception. One patient presented with a gradually progressive diminution of vision and scleral nodules with an associated exudative retinal detachment [Fig. 3]. In four cases, an initial clinical impression of fungal infection was made.

Samples from all seven patients were subjected to microbiological analysis [Fig. 4]. Three patients underwent early surgical intervention, within 8 days of onset of symptoms, and samples from surgery were sent for microbiological analysis. The samples included contents of evisceration sample (1), scleral biopsy (1), and corneal button (5). Direct microscopic examination with 10% acid-fast staining was performed in only four samples, and *Nocardia* could be detected in two (50%) of these on microscopy.

All the samples sent for culture grew *Nocardia*. Chalky white, tiny colonies of *Nocardia* grew on blood agar, chocolate agar, and Sabaroud's dextrose agar in 48 h in all patients. Cultures also revealed an *Aspergillus* coinfection in one patient. Antibiotic sensitivity testing was performed in all the samples. All samples were sensitive to amikacin. Antibiotic sensitivity testing could be performed in six of the seven samples. The antibiotic sensitivity report showed sensitivity to amikacin (7/7), moxifloxacin (5/7), gatifloxacin (5/7), ciprofloxacin (6/7), gentamicin (6/7), tobramycin (4/7), imipenem (4/7), and linezolid (3/7).

Six of the seven cases (85.71%) required some form of surgical intervention-evisceration (1), therapeutic penetrating keratoplasty (1) [Case 6, Fig. 5], corneal patch graft (2), core vitrectomy with corneal patch graft (1), and scleral patch graft (1) [Fig. 6]. The time duration between the onset of symptoms and surgical intervention varied from 7 to 42 days.

Infection was seen to resolve in four out of the seven patients. Surgical intervention was performed within a week of onset of symptoms in the two cases [Case 3 - Fig. 1 and Case 5 - Fig. 7]. The summary as well as outcomes of all the cases is tabulated in Table 1.

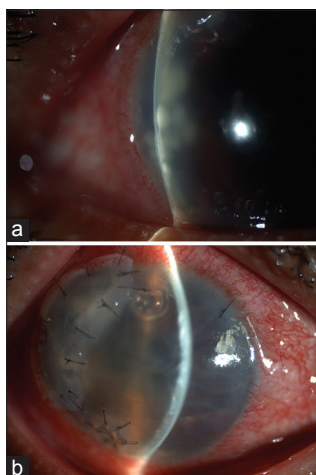


Figure 1: Deep corneal stromal infiltrates at the surgical incision sites in case 3 (a). (b) Following corneal patch grafts

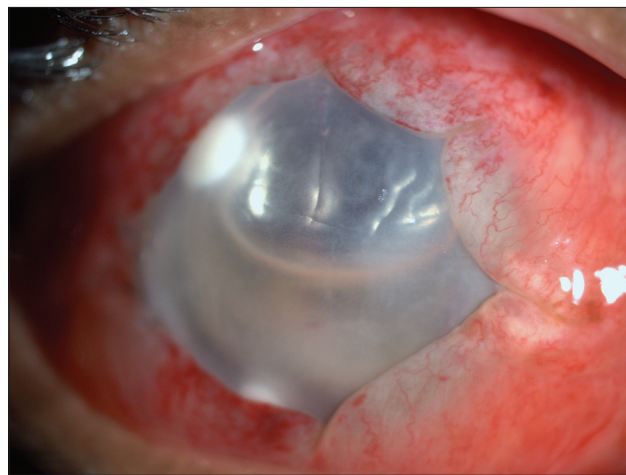


Figure 2: Exudation in the anterior chamber in case 2. B-scan ultrasonography showed involvement of the vitreous cavity

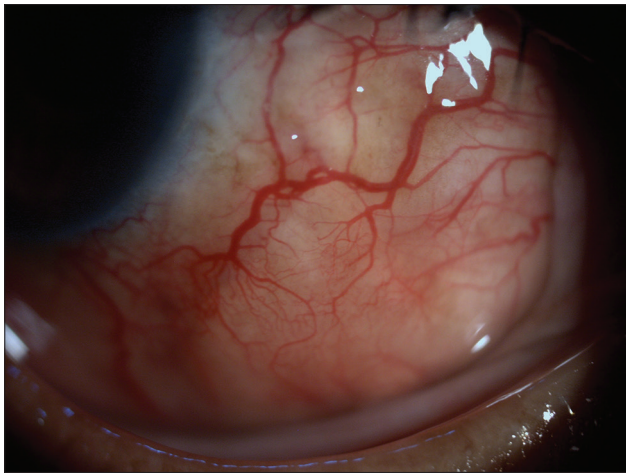


Figure 3: Multiple scleral nodules in case 7. Fundus evaluation revealed an associated exudative retinal detachment

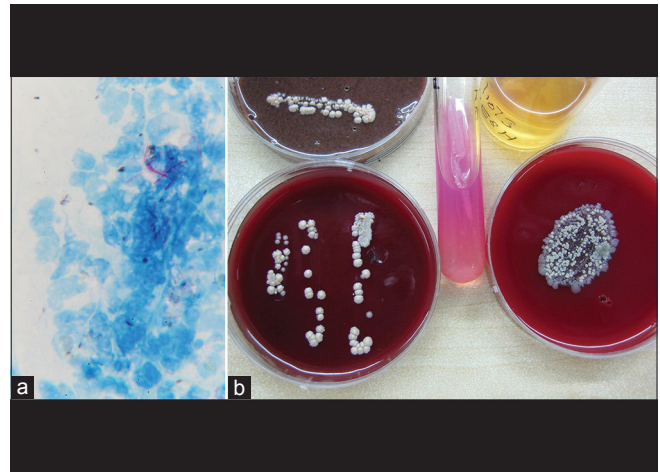


Figure 4: Smears on potassium hydroxide media revealing *Nocardia* organisms (x2) (a). *Nocardia* colonies on blood agar (b)

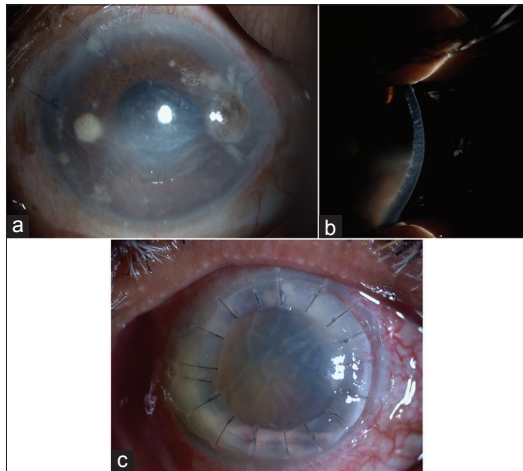


Figure 5: Multiple deep infiltrates and corneal perforation (a) in case 6. (b) Anterior chamber exudation. (c) Following therapeutic penetrating keratoplasty

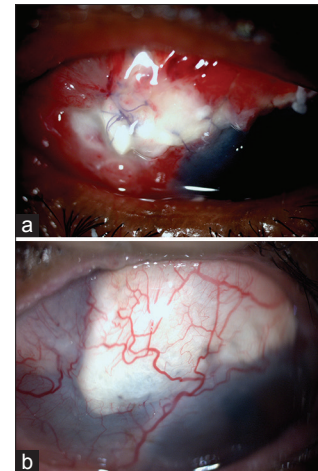


Figure 6: Scleral patch graft (a) for a scleral abscess in case 1. Three months postoperatively, the eye is quiet (b)

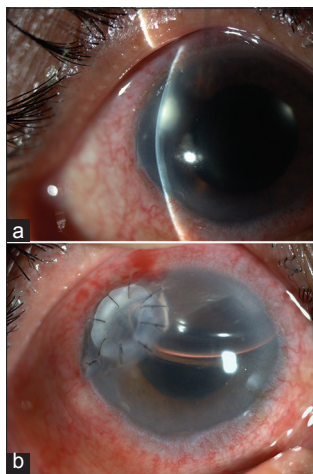


Figure 7: Endoexudate at the corneal surgical incision in case 5 (a). Following a corneal patch graft (b)

Discussion

Our case series of *Nocardia* infection following ocular surgery suggests that patients with early surgical intervention had

a better prognosis than cases that had delayed intervention. In addition, surgery performed in the absence of significant intraocular involvement, translated into better visual outcomes. This emphasizes the need for prompt microbiological diagnosis and surgical intervention for *Nocardia* infections. All cases in our study had involvement of the deep corneal stroma, with or without intraocular extension, where medical therapy may be ineffective.^[7] Corneal scraping may not be possible in most cases due to nonavailability of surface infiltration, making it difficult to initiate treatment based on microbiology findings.

Postoperative infections caused by *Nocardia* species are generally regarded as uncommon.^[4,5] However, an unusually high rate (16.8%) of postoperative infections caused by the organism has been found in South India.^[6] This may be relevant for tropical regions. In the same series, only three cases (12.5%) of infection followed phacoemulsification surgery.^[6] In addition, there were no cases that occurred as a cluster infection. Four cases in our study were part of a cluster infection. All four cases had infection at the incision site with varying severity of anterior and posterior segment involvement, depending on the time of presentation. Gokhale *et al.*^[7] have reported two cases of infection following phacoemulsification

Table 1: Demography, risk factors, clinical presentation, management, and outcomes of subjects

Serial number	Age/sex	Inciting/risk factors	Time to presentation (days)	Visual acuity	Clinical appearance	Treatment	Interval between onset of symptoms and surgical intervention (days)	Outcome	Final visual acuity
1	62/female	Cataract surgery, diabetes	30	6/36	Corneal infiltrate at side-port and scleral abscess	Scleral patch graft Cefa Tobra Nata KTZ	42	Resolved	HM
2	61/male	Cataract surgery, diabetes	21	No PL	AC and vitreous full of exudates	Evisceration	22	Eviscerated	No PL
3	60/female	Cataract surgery	7	6/18	Endoexudate at corneal section with 2 small corneal infiltrates	Patch graft Cefa Amika Cotrimoxazole	7	Resolved	6/18
4	65/female	Cataract surgery	8	PL	2 mm × 2 mm infiltrates at 7 and 10 o'clock; with endophthalmitis	Patch graft Vitrectomy Amika Moxi Cotrimoxazole	8	Phthisis	No PL
5	35/male	Cataract surgery	8	6/9	Endoexudate at corneal section	Patch graft Cefa Amika Cotrimoxazole	8	Resolved	6/12
6	68/male	Secondary IOL implant	7	FC	Small corneal infiltrate with infiltrate on iris	Amika Moxi TPK	12	Phthisis	PL
7	60/male	Cataract surgery, diabetes	30	PL	Scleral nodules; Exudative retinal detachment	Moxi (topical and oral)	N/A	Resolved	6/24

HM: Hand movements, PL: Light perception, No PL: No light perception, FC: Finger counting, Amika: 2% amikacin eye drops, Moxi: 0.5% moxifloxacin eye drops, Tobra: 1.3% tobramycin eye drops, Cefa: 5% cefazolin eye drops, TPK: Therapeutic penetrating keratoplasty, Nata: 5% natamycin eye drops, KTZ: Ketoconazole 200 mg tablets, AC: Anterior chamber, N/A: Not available

from a surgical knife that was not resterilized. Five of our seven patients (including four from the cluster infection) had surgical site infection from possibly infected surgical knives. *Nocardia* is found to be endemic in soil and dust^[9] and may infect hospital spaces.^[10] Contamination of surgical instruments and reuse with improper sterilization may lead to *Nocardia* infection. Most of the cases had their primary surgery elsewhere and were referred to us for the management of postoperative infection, and hence, we were unable to perform root cause analysis of the infection in the operative field.

Medical therapy may only be successful for superficial *Nocardia* infections.^[11] When infection is deep seated, treatment failure is likely.^[6] Poor response to medical therapy may be found even when isolates are found to be sensitive *in vitro*. Gokhale *et al.*^[7] found good outcomes with early surgical intervention. Two patients, in our study, who had deep infiltrates limited to the site of the surgical incision, without significant anterior segment involvement, also benefited from early surgery and maintained a visual acuity of at least (20/60). In addition, surgical intervention may provide opportunity to obtain material for microbiological examination in deep-seated infection.

Four of the total seven (57.14%) patients had a final visual acuity of hand motions or worse. This may be due to the advanced nature of the infection at presentation. *Nocardia* infections have generally been associated with a poor visual outcome.^[6] The absence of posterior segment involvement may not necessarily give the patient a better prognosis. It has been hypothesized that extensive involvement of the AC and ciliary body may result in hypotony and phthisis bulbi.^[6] Indeed, two patients in the present study, without a posterior segment involvement, had a poor visual outcome.

Conclusion

Nocardia infections after intraocular surgery have a guarded visual prognosis. Early surgical intervention, before the involvement of the AC, may help preserve the anatomic and functional integrity of the globe.

Acknowledgment

Authors would like to thank Mr. Lokesh Chauhan for analytical and technical assistance.

Financial support and sponsorship

Nil.

Conflicts of interest

There are no conflicts of interest.

References

1. Upadhyay MP, Karmacharya PC, Koirala S, Tuladhar NR, Bryan LE, Smolin G, et al. Epidemiologic characteristics, predisposing factors, and etiologic diagnosis of corneal ulceration in Nepal. *Am J Ophthalmol* 1991;111:92-9.
2. Garg P, Rao GN. Corneal ulcer: Diagnosis and management. *Community Eye Health* 1999;12:21-3.
3. Srinivasan M, Gonzales CA, George C, Cevallos V, Mascarenhas JM, Asokan B, et al. Epidemiology and aetiological diagnosis of corneal ulceration in Madurai, South India. *Br J Ophthalmol* 1997;81:965-71.
4. Anand AR, Therese KL, Madhavan HN. Spectrum of aetiological agents of postoperative endophthalmitis and antibiotic susceptibility of bacterial isolates. *Indian J Ophthalmol* 2000;48:123-8.
5. Bharathi MJ, Ramakrishnan R, Vasu S, Meenakshi Chirayath A, Palaniappan R. *Nocardia asteroides* keratitis in South India. *Indian J Med Microbiol* 2003;21:31-6.
6. Haripriya A, Lalitha P, Mathen M, Prajna NV, Kim R, Shukla D, et al. *Nocardia* endophthalmitis after cataract surgery: Clinicomicrobiological study. *Am J Ophthalmol* 2005;139:837-46.
7. Gokhale NS, Garg P, Rodrigues C, Haldipurkar S. *Nocardia* infection following phacoemulsification. *Indian J Ophthalmol* 2007;55:59-61.
8. Pradhan ZS, Jacob P, Korah S. Management of post-operative *Nocardia* endophthalmitis. *Indian J Med Microbiol* 2012;30:359-61.
9. Mishra SK, Damodaran VN. Observations on the natural habitats of *Cryptococcus neoformans* and *Nocardia asteroides*. *Indian J Chest Dis* 1973;15:263-71.
10. Lovett IS, Houang ET, Burge S, Turner-Warwick M, Thompson FD, Harrison AR, et al. An outbreak of *Nocardia asteroides* infection in a renal transplant unit. *Q J Med* 1981;50:123-35.
11. Sridhar MS, Gopinathan U, Garg P, Sharma S, Rao GN. Ocular *Nocardia* infections with special emphasis on the cornea. *Surv Ophthalmol* 2001;45:361-78.