Internal Medicine
The Japanese Society of Internal Medicine

doi: 10.2169/internalmedicine.5665-20
Intern Med 60: 1101-1107, 2021
http://internmed.jp

【 CASE REPORT 】

Anti-PM/Scl Antibody-positive Systemic Sclerosis Complicated by Multiple Organ Involvement

Tatsuya Shimizu[1], Chie Saito[1], Megumi Watanabe[1], Ryota Ishii[1], Tetsuya Kawamura[1], Kei Nagai[1], Akiko Fujita[1], Shuzo Kaneko[1], Hirayasu Kai[1], Naoki Morito[1], Joichi Usui[1], Masahiro Yokosawa[2], Yuya Kondo[2], Sae Inoue[3], Naoko Okiyama[3] and Kunihiro Yamagata[1]

Abstract:
A 40-year-old Japanese woman developed malignant-phase hypertension complicated by thrombotic microangiopathy, progressing to end-stage renal disease. Five years later, she was diagnosed with pulmonary arterial hypertension and interstitial pneumonia. Despite a lack of overt skin sclerosis, nucleolar staining in our indirect immunofluorescence analysis and nailfold capillaroscopy facilitated the diagnosis of anti-PM/Scl antibody-positive systemic sclerosis. We observed the persistent presence of anti-PM/Scl antibodies throughout the clinical course, suggesting that her kidney disease was scleroderma renal crisis. Anti-PM/Scl antibodies can be associated with multiple organ diseases. Careful attention to a patient's antinuclear antibody pattern and dermatological findings may help clarify the etiology of undiagnosed diseases.

Key words: anti-PM/Scl antibody, systemic sclerosis, scleroderma renal crisis, thrombotic microangiopathy

(Intern Med 60: 1101-1107, 2021)
(DOI: 10.2169/internalmedicine.5665-20)

Introduction

Systemic sclerosis (SSc) is a connective tissue disease characterized by fibrosis of the skin and internal organs, microvasculopathy, and autoantibody production. Several disease-related autoantibodies have been reported in individuals with SSc, and these autoantibodies have distinct associations with clinical and prognostic features. SSc-associated autoantibodies are generally mutually exclusive in one individual and will not change to other autoantibodies during the clinical course. It is thus important to identify SSc-associated autoantibodies in a precise assessment (1-3).

Anti-PM/Scl antibodies recognize nucleolar protein complex, whose major antigens are the 75-kDa proteins (anti-PM/Scl-75 antibody) and 100-kDa proteins (anti-PM/Scl-100 antibody) (4). In western countries, anti-PM/Scl antibodies are identified in approximately 5% of patients with SSc (5, 6), while approximately 30% of anti-PM/Scl antibody-positive patients have features of overlap syndrome related to SSc and other connective tissue diseases (7, 8). It is also reported that patients with anti-PM/Scl antibodies develop limited cutaneous SSc and have favorable prognoses because life-threatening organ complications are uncommon in this population (9).

We herein report a case of anti-PM/Scl antibody-positive SSc complicated by scleroderma renal crisis (SRC), pulmonary arterial hypertension (PAH), and interstitial pneumonia.

Case Report

A 40-year-old Japanese woman was referred to our hospital with impaired consciousness. She had experienced anorexia and edema a few days before admission, and it gradually became difficult for her to move. She had no family history of renal disease or connective tissue disease. At 30 years old, she had been diagnosed with hypertensive disorder of pregnancy. Although she did not receive continuous medical follow-up, her serum creatinine level had been 0.6 mg/dL at 32 years old. She had also been diagnosed with

[1]Department of Nephrology, Faculty of Medicine, University of Tsukuba, Japan, [2]Department of Rheumatology, Faculty of Medicine, University of Tsukuba, Japan and [3]Department of Dermatology, Faculty of Medicine, University of Tsukuba, Japan
Received: June 20, 2020; Accepted: September 12, 2020; Advance Publication by J-STAGE: November 2, 2020
Correspondence to Dr. Kunihiro Yamagata, k-yamaga@md.tsukuba.ac.jp

Table 1. Laboratory Findings at the First Admission.

Blood cell counts		**Blood chemistry**			
WBCs	24,700 /μL	TP	5.4 g/dL	Na	138 mEq/L
RBCs	351×10^4 /μL	Albumin	2.1 g/dL	K	7.0 mEq/L
Hb	10.5 g/dL	AST	137 U/L	Ca	7.5 mg/dL
MCV	94.0 fL	ALT	269 U/L	IP	15.1 mg/dL
Reticulocytes	79 ‰	LDH	1,543 U/L	CRP	4.03 mg/dL
Platelets	22.0×10^4 /μL	ALP	358 U/L	CK	380 U/L
Schistocytes	4.99 %	γGTP	38 U/L	Myoglobin	612 ng/mL
		T-Bil	1.4 mg/dL	Haptoglobin	<10 mg/dL
Coagulation		D-Bil	0.7 mg/dL	KL-6	237 U/mL
APTT	36.9 s	BUN	186.5 mg/dL	SP-D	72.8 ng/mL
PT%	45.0 %	Creatinine	14.6 mg/dL		
PT-INR	1.66	UA	20.6 mg/dL	HbA1c	<3.2 %
Fibrinogen	364.5 mg/dL				
FDP	15.0 μg/mL			Plasma renin activity	16.5 ng/mL/h
				Aldosterone	2,390 pg/mL

Immunology					
IgG	1,442 mg/dL	Anti-DNA antibody (RIA)	4 IU/mL	Direct Coombs test	negative
IgA	393 mg/dL	Anti-Sm antibody	negative		
IgM	155 mg/dL			ADAMTS13 activity	23.7 %
RF	42 IU/mL	Anti-CLβ2GPI antibody	<0.7 U/mL	ADAMTS13 Inhibitor	negative
C3	45 mg/dL	LAC	1.6 ratio		
C4	9 mg/dL			O-157 antigen	negative
CH50	27.4 U/mL	Anti-Scl 70 antibody	negative		
		Anti-centromere antibody	<5.0 Index	Cryoglobulins	negative
Antinuclear antibody	640	Anti-U1RNP antibody	negative		
	Speckled, Nucleolar			M-proteins	negative
MPO-ANCA	<1.0 U/mL	Anti-SS-A antibody	2		
PR3-ANCA	<1.0 U/mL	Anti-SS-B antibody	negative		
Anti-GBM antibody	2.2 U/mL	PA-IgG	44.6 ng/10^7 cells		

ADAMTS13: a disintegrin and metalloproteinase with thrombospondin motifs 13, ALP: alkaline phosphatase, ALT: alanine aminotransferase, ANCA: anti-neutrophil cytoplasmic antibody, APTT: activated partial thromboplastin time, AST: aspartate aminotransferase, BUN: blood urea nitrogen, CK: creatine kinase, CLβ2GPI: cardiolipin beta-2-glycoprotein I, CRP: C-reactive protein, D-Bil: direct bilirubin, FDP: fibrin/fibrinogen degradation products, GBM: glomerular basement membrane, γGTP: gamma-glutamyl transpeptidase, INR: international normalized ratio, IP: inorganic phosphate, KL-6: Krebs von den Lungen-6, LAC: lupus anticoagulant, LDH: lactate dehydrogenase, MCV: mean corpuscular volume, MPO: myeloperoxidase, PA-IgG: platelet-associated IgG, PR3: proteinase 3, PT: prothrombin time, RBC: red blood cell, RF: rheumatoid factor, RIA: radioimmunoassay, SP-D: surfactant protein D, T-Bil: total bilirubin, TP: total protein, UA: uric acid

schizophrenia, which was being stably controlled by aripiprazole.

Her blood pressure was 236/140 mmHg at admission and was reduced to 170/130 mmHg with nicardipine. She was in a state of stupor. The consciousness level indicated by the Glasgow Coma Scale (GCS) was E3V3M5. She had already progressed to anuria and showed bilateral leg edema. Notably, Raynaud's phenomenon was observed in her fingers. The laboratory analysis revealed advanced renal failure and liver dysfunction, and thrombotic microangiopathy (TMA) was indicated by elevated lactate dehydrogenase, hemolytic anemia with schistocytes, and thrombocytopenia (Table 1). A diagnosis of malignant-phase hypertension was made because the patient exhibited an altered mental status, and the fundus examination confirmed hypertensive retinopathy (Keith-Wagener grade 3). The hormonal profiles of renin and aldosterone showed that both were elevated, supporting this diagnosis.

Abdominal ultrasonography showed mildly atrophic kidneys but no hydronephrosis. It was suspected that the patient might have developed chronic kidney disease, but malignant-phase hypertension complicated by TMA caused an acute exacerbation of the kidney function. A renal biopsy was not performed because of the patient's mildly atrophic kidneys. We performed plasma exchange with fresh-frozen plasma twice during the first two days post-admission because we could not rule out thrombotic thrombocytopenic purpura. However, the patient's ADAMTS13 activity was not completely reduced at admission (>10%), and ADAMTS 13 inhibitors were not detected in the patient's serum. The patient's serum was positive for antinuclear antibody (ANA), showing speckled and nucleolar staining patterns. We considered the possibility of systemic autoimmune diseases, as she also exhibited Raynaud's phenomenon. It is often the

Table 2. Laboratory Findings at the Second Admission (Five Years Later).

Blood cell counts		**Blood chemistry**			
WBCs	6,100 /μL	TP	8.4 g/dL	Na	138 mEq/L
RBCs	388×10^4 /μL	Albumin	2.7 g/dL	K	3.9 mEq/L
Hb	10.0 g/dL	AST	29 U/L	Ca	8.1 mg/dL
MCV	85.3 fL	ALT	11 U/L	IP	4.7 mg/dL
Reticulocytes	16 ‰	LDH	265 U/L	CK	32 U/L
Platelets	11.8×10^4 /μL	ALP	275 U/L	Myoglobin	92.8 ng/mL
Schistocytes	0.7 %	γGTP	45 U/L	CRP	0.35 mg/dL
		T-Bil	0.3 mg/dL	Haptoglobin	78 mg/dL
Coagulation		BUN	25.2 mg/dL	KL-6	1,801 U/mL
APTT	38.0 s	Creatinine	2.96 mg/dL	SP-D	455 ng/mL
PT-INR	1.18			BNP	1,544.6 pg/mL

Immunology			
IgG	3,546 mg/dL	Anti-DNA antibody (RIA)	9 IU/mL
IgA	646 mg/dL	Anti-Sm antibody	negative
IgM	119 mg/dL		
RF	43 IU/mL	Anti-CLβ2GPI antibody	<0.7 U/mL
C3	78 mg/dL	LAC	1.1 ratio
C4	19 mg/dL		
CH50	58.7 U/mL	Anti-Scl 70 antibody	negative
		Anti-centromere antibody	<2.0 U/mL
Antinuclear antibody	1,280	Anti-RNA polymerase3 antibody	negative
	Speckled, Nucleolar	Anti-U1RNP antibody	negative
		Anti-SS-A antibody	16
MPO-ANCA	<1.0 U/mL	Anti-SS-B antibody	16
PR3-ANCA	1.6 U/mL	Anti-ARS antibody	negative
Anti-CCP antibody	<0.6 U/mL	M-proteins	negative

ALP: alkaline phosphatase, ALT: alanine aminotransferase, ANCA: anti-neutrophil cytoplasmic antibody, APTT: activated partial thromboplastin time, ARS: aminoacyl tRNA synthetase, AST: aspartate aminotransferase, BNP: brain natriuretic peptide, BUN: blood urea nitrogen, CCP: cyclic citrullinated peptide, CK: creatine kinase, CLβ2GPI: cardiolipin beta-2-glycoprotein I, CRP: C-reactive protein, γGTP: gamma-glutamyl transpeptidase, INR: international normalized ratio, IP: inorganic phosphate, KL-6: Krebs von den Lungen-6, LAC: lupus anticoagulant, LDH: lactate dehydrogenase, MCV: mean corpuscular volume, MPO: myeloperoxidase, PR3: proteinase 3, PT: prothrombin time, RBC: red blood cell, RF: rheumatoid factor, RIA: radioimmunoassay, SP-D: surfactant protein D, T-Bil: total bilirubin, TP: total protein

case that normal or mildly to moderately reduced ADAMTS 13 activity is associated with atypical hemolytic uremic syndrome secondary to systemic autoimmune diseases (10). The patient was thus referred to a rheumatologist for a detailed examination. However, a specific diagnosis of systemic autoimmune diseases could not be made at that time because the patient lacked the other diagnostic features, including skin sclerosis and other organ involvement. Clinically, it was more likely that the malignant-phase hypertension itself had caused the disease onset.

Plasma exchange was suspended and then discontinued, and the patient's consciousness level and laboratory findings seemed to improve in response to the decreased blood pressure. We therefore concluded that the acute kidney injury had been caused by malignant-phase hypertension and continued the antihypertensive therapies, including renin-angiotensin system inhibitors (enalapril and losartan). Although the patient's general condition gradually improved along with the recovery from TMA and liver dysfunction, her kidney function remained dialysis-dependent.

After five years on maintenance hemodialysis, the patient experienced repeated congestive heart failure and was readmitted to our hospital to undergo clinical investigations. A physical examination revealed facial telangiectasia and slight edema of her legs. She had bibasilar fine crackles and an accentuated pulmonary component of the second heart sound. She complained of muscle fatigue in her neck and shoulders but had no apparent myalgia. The laboratory findings at the second admission are shown in Table 2. Chest X-ray showed cardiomegaly and dilatation of the pulmonary arteries. Interstitial shadow was also suspected in the lower lung fields. An echocardiogram revealed enlargement of the right chambers causing flattening of the interventricular septum (Fig. 1). In addition, the tricuspid regurgitation pressure gradient had increased to 55.5 mmHg, which suggested pulmonary hypertension.

To examine the lungs and exclude the possibility of chronic thromboembolic pulmonary hypertension, we performed chest contrast-enhanced computed tomography (CT). Based on these images, we diagnosed the lung lesions as non-specific interstitial pneumonia (Fig. 1). Extensive pulmonary embolism was not detected by contrast-enhanced

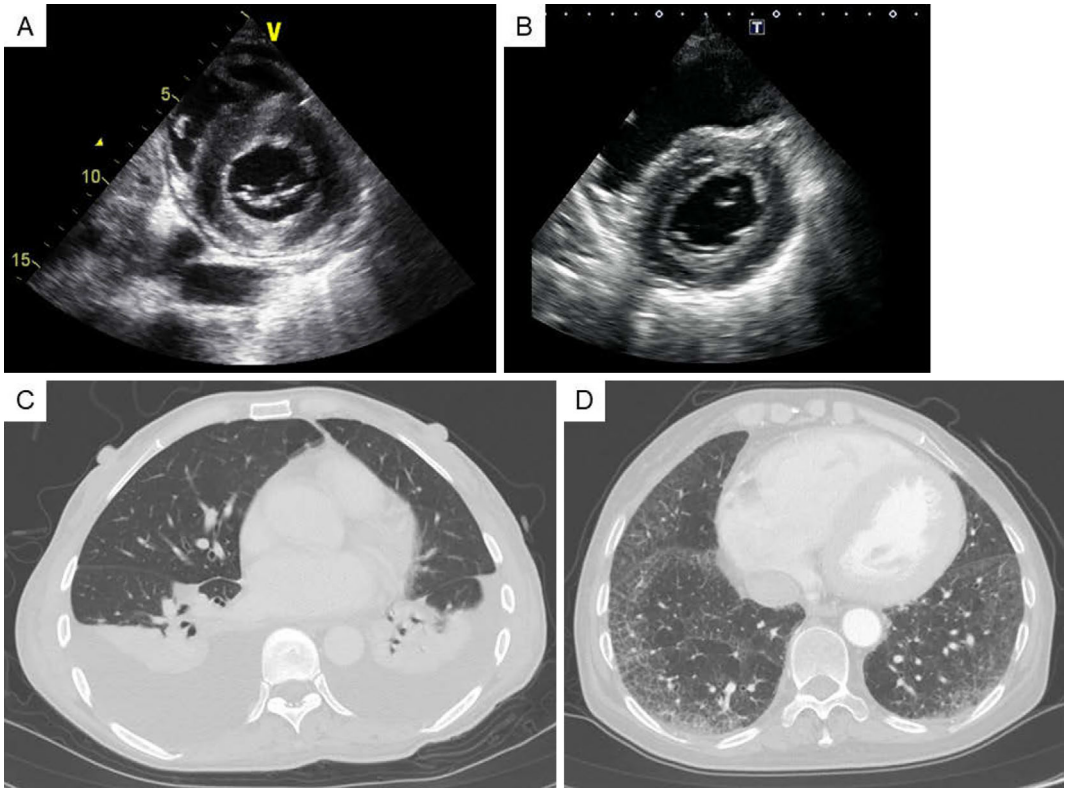

Figure 1. Parasternal short-axis views on echocardiography (A, B) and chest CT findings (C, D) over a five-year period. A: At the first admission, chronic hypertension was suspected based on the observation of left ventricular hypertrophy (interventricular septal thickness: 14 mm, posterior wall thickness: 14 mm). There was no increase in the tricuspid regurgitation pressure gradient (TRPG; 13.9 mmHg). B: Five years later, pulmonary hypertension was suggested based on the increased TRPG (55.5 mmHg). Enlargement of the right chambers and flattening of the interventricular septum were observed. C: At the first admission, bilateral pleural effusion and passive atelectasis were observed, but there was no evidence of interstitial lung diseases. D: Five years later, the patient developed bilateral ground-glass opacities and interlobular septal thickening, predominantly in the periphery of the lower lungs. There was no traction bronchiectasis or honeycombing. Enlargement of the right chambers and dilatation of the central pulmonary arteries were also observed.

CT. Subsequently, right heart catheterization was performed to examine the pulmonary hypertension. We found that the mean pulmonary arterial pressure (mPAP) and pulmonary vascular resistance (PVR) were increased to 38 mmHg (≥25) and 5.08 Wood (≥3.0), respectively. Although the patient's mildly elevated pulmonary artery wedge pressure (15 mmHg) suggested additional left-heart disease, the clear increases in the mPAP and PVR were enough to confirm the presence of PAH.

The patient's ANA result was still positive (1:1,280), and dermatologists identified sausage-like fingers as well as telangiectasias on the patient's cheeks and dorsal hands (Fig. 2). In addition to the positive ANA test and multiorgan complications, these dermatological findings prompted us to perform a further examination of the patient's nailfolds because abnormalities of the finger nailfolds can support a diagnosis of autoimmune disease. Importantly, nailfold capillaroscopy demonstrated elongation of the cuticles and twisted enlarged capillaries (Fig. 2). Although the patient did not have overt skin sclerosis, these findings are generally characteristic of SSc. We therefore suspected that she might have SSc complicated by SSc-related multiple organ involvement.

According to the 2013 American College of Rheumatology (ACR)/European League Against Rheumatism (EULAR) classification criteria for systemic sclerosis (11), telangiectasia, abnormal nailfold capillaries, PAH, interstitial lung disease, and Raynaud's phenomenon meet the SSc criteria, so our patient was considered to have SSc. Since her ANA profile showed a nucleolar pattern in the absence of major SSc-associated autoantibodies (i.e., anti-topoisomerase I antibody, anti-centromere antibody, anti-RNA polymerase III antibody and anti-U1RNP antibody), we screened SSc-associated autoantibodies using the EUROLINE Systemic Sclerosis Profile (EUROIMMUN, Luebeck, Germany), a simplified kit for line immunoblot analyses. As expected, we detected anti-PM/Scl-100, anti-PM/Scl-75, and anti-Ro52 antibodies as candidate autoantibodies.

We next performed protein immunoprecipitation assays as described (12). The results indicated the presence of anti-

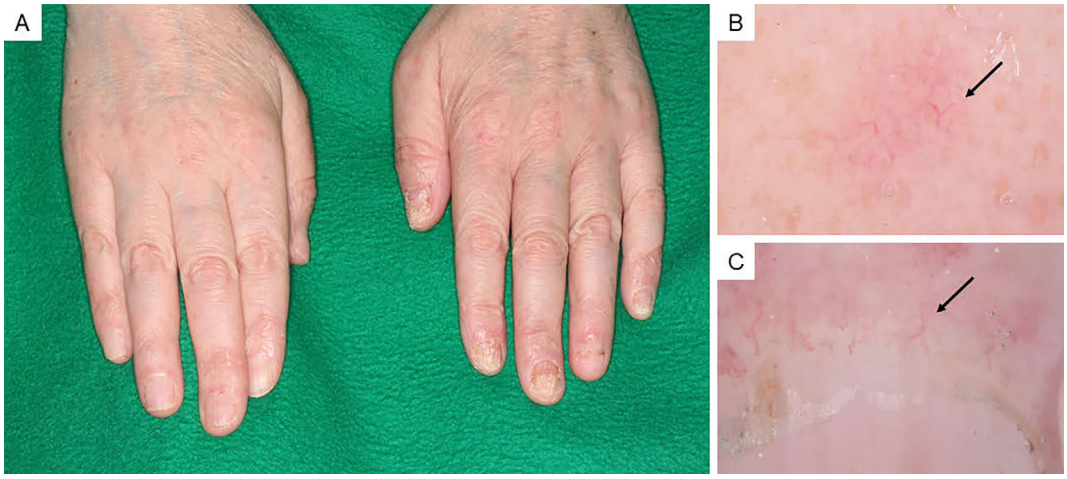

Figure 2. Dermatological findings at the second admission. A: Sausage-like fingers and telangiectasias on the dorsal hands (her left fingers were affected by tinea unguium). Note that there was no apparent skin sclerosis. B: Magnified image of telangiectasias (arrow). C: Representative capillaroscopic image of the nailfolds showing elongation of the cuticles and twisted enlarged capillary loops (arrow).

PM/Scl-100 antibodies and anti-Ro52 antibodies, although an RNA immunoprecipitation assay was not performed in this study. Intriguingly, anti-PM/Scl-100 antibodies and anti-Ro52 antibodies were also confirmed in the preserved serum at the patient's first admission, suggesting that the precedent kidney disease was SRC. A further examination of the patient's human leukocyte antigen (HLA) typing showed DRB 1*08 and DRB1*13. Collectively, we made a diagnosis of anti-PM/Scl antibody-positive SSc complicated by multiple organ diseases. We initiated medications for PAH, and the patient was transferred to a long-term-care hospital.

Discussion

We noted two important issues with this case. First, individuals with anti-PM/Scl antibodies can develop multiple organ diseases, and SRC may occur as a presenting feature of the disease. Second, careful attention to the staining pattern of the results of an indirect immunofluorescence (IIF) analysis and dermatological findings can facilitate the diagnosis of patients with autoimmune diseases (including anti-PM/Scl antibody-positive patients).

Our patient developed multiple organ involvement. Several studies have reported the clinical aspects of anti-PM/Scl antibody-positive SSc (5-8), and according to those studies, the prevalence of SRC in anti-PM/Scl antibody-positive SSc was 4%. PAH was also limited at 5-8%, whereas interstitial pneumonia was relatively prevalent (13-55%). In this light, our patient's case seems atypical and more severe than the reported cases because she had multiple organ complications. In addition, acute kidney injury complicated by TMA was the presenting feature of her case. She did not have either PAH or interstitial pneumonia at that time, and we were unable to detect any signs of the underlying autoimmune disease except the presence of ANA and Raynaud's phenomenon.

SRC without overt skin sclerosis can be the first manifestation of the disease, especially in patients with anti-RNA polymerase III antibodies (13). Furthermore, an anti-PM/Scl antibody-positive patient can reportedly develop SRC as a presenting feature as well (14). Interestingly, there was another case report of an anti-PM/Scl antibody-positive patient with interstitial pneumonia who developed SRC complicated by TMA (15). That patient only had abnormal capillaroscopic findings in the absence of apparent skin sclerosis. Our patient's case also illustrates the importance of dermatological findings, including nailfold capillaroscopy, for the early diagnosis of anti-PM/Scl antibody-positive patients. Given the findings of previous reports and our patient's clinical course, it is possible that similar anti-PM/Scl antibody-positive cases are left undiagnosed because those patients lack advanced skin sclerosis to be diagnosed as having SSc.

It is also noteworthy that both our patient and the previously reported patient (15) exhibited mild hypocomplementemia at the time of the SRC onset (Table 1). In the previous case report, the patient was successfully treated with eculizumab, an anti-C5 antibody, suggesting the possibility of effective treatment (15). Although we could not perform a detailed evaluation of our patient's TMA by a renal biopsy or a clinical investigation for atypical hemolytic uremic syndrome, we speculate that complement activation by the classical pathway may have played a role in exacerbating the renal outcome of her SRC, as described (16).

Recently, another similar case report described a patient with anti-PM/Scl-100 antibodies who developed SRC complicated by TMA (17). That patient also presented with telangiectasia and Raynaud's phenomenon in the absence of skin sclerosis. However, the patient had a recent history of the administration of systemic corticosteroid therapy, which

is a potential risk factor for SRC (18), and this might have modified the natural course of the disease. The reported patient never developed PAH or interstitial pneumonia during the follow-up period. This is different from our patient's case, in which her status progressed to a more serious condition without the use of corticosteroids. The present case also showed the onset of PAH and interstitial pneumonia, which may provide lessons concerning the follow-up of anti-PM/Scl antibody-positive cases.

One explanation for the distinct clinical features in our patient's case is the difference in genetic backgrounds. In general, the detection frequency of SSc-associated autoantibodies and their clinical presentations vary widely, depending on the patients' ethnic backgrounds. Anti-PM/Scl antibody is reportedly strongly correlated with HLA-DRB1*0301 (19) and is quite rare in the Japanese population, which has a positivity for HLA-DRB1*0301 lower than 1% (3, 20). As our patient's HLA typing showed HLA types that differed from those of the previous cases in western countries, it is possible that her genetic background affected the clinical features. Some reports have demonstrated the clinical aspects of anti-PM/Scl antibody-positive patients in Japan. For example, there were no anti-PM/Scl antibody-positive cases in a cohort of 588 Japanese SSc patients (21).

However, Muro et al. investigated the prevalence of anti-PM/Scl antibody among Japanese patients with systemic autoimmune diseases and reported that only 1.5% (9/600) of the cases were positive for anti-PM/Scl antibody (22). Approximately half of the anti-PM/Scl antibody-positive patients were considered to have undifferentiated connective tissue disease, and only one patient was diagnosed with limited cutaneous SSc. Notably, none of the anti-PM/Scl antibody-positive patients developed SRC or PAH in that study (22). Since there have been only a few reports on anti-PM/Scl antibody-positive cases in Japan, further studies are needed to elucidate their clinical features. In addition, our present patient was also positive for anti-Ro52 antibody, which was reported to correlate with interstitial pneumonia in SSc patients (23). It is also plausible that anti-Ro52 antibody is correlated with interstitial pneumonia in anti-PM/Scl antibody-positive cases.

The second lesson from our patient's case is the importance of dermatological findings in patients with suspected autoimmune diseases. One of the first signs of our patient's disease was Raynaud's phenomenon, which might have indicated SSc-related microvasculopathy. The capillaroscopic findings provided clues for the eventual diagnosis of anti-PM/Scl antibody-positive SSc. Abnormal nailfold capillaries are an established diagnostic feature of SSc (11). It is also reported that the identification of Raynaud's phenomenon and abnormal nailfold capillaries facilitates the early diagnosis of SSc before the patient develops skin sclerosis (24).

Concerning the diagnosis of SSc, we should mention that we were unable to classify our patient's case as SSc using the current Japanese national criteria (revised in 2010, issued by the Ministry of Health, Labour and Welfare, Japan), which were originally based on the 1980 ACR classification criteria (25). In those criteria, patients must have skin sclerosis to be classified as SSc. For this reason, it is sometimes difficult to diagnose cases of SSc with preceding organ involvement. Instead, we used the 2013 ACR/EULAR classification criteria, which were originally revised to enable the diagnosis of early or mild SSc cases (11). The present case emphasizes that the combination of SSc-like features, such as Raynaud's phenomenon and abnormal nailfold capillaries, may contribute to the diagnosis of early SSc cases when the 2013 ACR/EULAR criteria are used.

Given the above, we propose that it is reasonable to explore SSc-associated autoantibodies when clinicians encounter ANA-positive patients with acute kidney injury who also exhibit Raynaud's phenomenon and/or abnormal nailfold capillaries. In particular, we should be aware that some SSc-associated autoantibodies, including anti-PM/Scl antibody, show a nucleolar pattern on IIF analyses.

In conclusion, we herein report the case of an anti-PM/Scl antibody-positive Japanese patient who developed multiple organ involvement. This case suggests that patients with anti-PM/Scl antibody can develop SRC complicated by TMA as a presenting feature of the disease. Although differences in genetic backgrounds should be considered, many similar cases might be left undiagnosed. The staining patterns of ANA and capillaroscopic findings can provide clues for the accurate diagnosis. Since internal organ complications govern the prognosis of SSc patients, it is important to make an early diagnosis for anti-PM/Scl antibody-positive patients as well.

The authors state that they have no Conflict of Interest (COI).

Acknowledgement

We wish to thank Taizo Kimura, MD, PhD, for the diagnosis of PAH, Rie Kikkou and Mikie Daigo for the sample preservation, and Miwako Shobo for the identification of SSc-associated autoantibodies.

References

1. Denton CP, Khanna D. Systemic sclerosis. Lancet **390**: 1685-1699, 2017.
2. Hamaguchi Y. Autoantibodies and their clinical characteristics in systemic sclerosis. Nihon Rinsho Meneki Gakkai Kaishi (Jpn J Clin Immunol) **36**: 139-147, 2013 (in Japanese, Abstract in English).
3. Hamaguchi Y, Hasegawa M, Fujimoto M, et al. The clinical relevance of serum antinuclear antibodies in Japanese patients with systemic sclerosis. Br J Dermatol **158**: 487-495, 2008.
4. Brouwer R, Vree Egberts WT, Hengstman GJ, et al. Autoantibodies directed to novel components of the PM/Scl complex, the human exosome. Arthritis Res **4**: 134-138, 2002.
5. Hanke K, Brückner CS, Dähnrich C, et al. Antibodies against PM/Scl-75 and PM/Scl-100 are independent markers for different subsets of systemic sclerosis patients. Arthritis Res Ther **11**: R22, 2009.
6. Mierau R, Moinzadeh P, Riemekasten G, et al. Frequency of disease-associated and other nuclear autoantibodies in patients of

the German Network for Systemic Scleroderma: Correlation with characteristic clinical features. Arthritis Res Ther **13**: R172, 2011.

7. D'Aoust J, Hudson M, Tatibouet S, et al. Clinical and serologic correlates of anti-PM/Scl antibodies in systemic sclerosis: a multicenter study of 763 patients. Arthritis Rheumatol **66**: 1608-1615, 2014.

8. Koschik RW 2nd, Fertig N, Lucas MR, Domsic RT, Medsger TA Jr. Anti-PM-Scl antibody in patients with systemic sclerosis. Clin Exp Rheumatol **30**: S12-S16, 2012.

9. Marguerie C, Bunn CC, Copier J, et al. The clinical and immunogenetic features of patients with autoantibodies to the nucleolar antigen PM/Scl. Medicine (Baltimore) **71**: 327-336, 1992.

10. Sato T, Hanaoka R, Ohshima M, et al. Analyses of ADAMTS13 activity and its inhibitor in patients with thrombotic thrombocytopenic purpura secondary to connective tissue diseases: observations in a single hospital. Clin Exp Rheum **24**: 454-455, 2006.

11. van den Hoogen F, Khanna D, Fransen J, et al. 2013 classification criteria for systemic sclerosis: an American College of Rheumatology/European League against Rheumatism Collaborative Initiative. Arthritis Rheum **65**: 2737-2747, 2013.

12. Hamaguchi Y, Kuwana M, Hoshino K, et al. Clinical correlations with dermatomyositis-specific autoantibodies in adult Japanese patients with dermatomyositis: a multicenter cross-sectional study. Arch Dermatol **147**: 391-398, 2011.

13. Bhavsar SV, Carmona R. Anti-RNA polymerase III antibodies in the diagnosis of scleroderma renal crisis in the absence of skin disease. J Clin Rheumatol **20**: 379-382, 2014.

14. Zwettler U, Andrassy K, Waldherr R, Ritz E. Scleroderma renal crisis as a presenting feature in the absence of skin involvement. Am J Kidney Dis **22**: 53-56, 1993.

15. Thomas CP, Nester CM, Phan AC, Sharma M, Steele AL, Lenert PS. Eculizumab for rescue of thrombotic microangiopathy in PM-Scl antibody-positive autoimmune overlap syndrome. Clin Kidney J **8**: 698-701, 2015.

16. Batal I, Domsic RT, Shafer A, Medsger TA Jr, Kiss LP, Randhawa P, Bastacky S. Renal biopsy findings predicting outcome in scleroderma renal crisis. Hum Pathol **40**: 332-340, 2009.

17. Jacquier M, Mousson C, Rebibou JM, et al. Scleroderma renal crisis in a systemic sclerosis with anti-PM/Scl antibodies. Kidney Int Rep **4**: 1499-1502, 2019.

18. Mouthon L, Bussone G, Berezne A, et al. Scleroderma renal crisis. J Rheumatol **41**: 1040-1048, 2014.

19. Hausmanowa-Petrusewicz I, Kowalska-Oledzka E, Miller FW, et al. Clinical, serologic, and immunogenetic features in Polish patients with idiopathic inflammatory myopathies. Arthritis Rheum **40**: 1257-1266, 1997.

20. Kuwana M, Kaburaki J, Okano Y, Tojo T, Homma M. Clinical and prognostic associations based on serum antinuclear antibodies in Japanese patients with systemic sclerosis. Arthritis Rheum **37**: 75-83, 1994.

21. Kaji K, Fertig N, Medsger Jr TA, et al. Autoantibodies to RuvBL1 and RuvBL2: a novel systemic sclerosis-related antibody associated with diffuse cutaneous and skeletal muscle involvement. Arthritis Care Res (Hoboken) **66**: 575-584, 2014.

22. Muro Y, Hosono Y, Sugiura K, Ogawa Y, Mimori T, Akiyama M. Anti-PM/Scl antibodies are found in Japanese patients with various systemic autoimmune conditions besides myositis and scleroderma. Arthritis Res Ther **17**: 57, 2015.

23. Hudson M, Pope J, Mahler M, et al. Clinical significance of antibodies to Ro52/TRIM21 in systemic sclerosis. Arthritis Res Ther **14**: R50, 2012.

24. LeRoy EC, Medsger TA Jr. Criteria for the classification of early systemic sclerosis. J Rheumatol **28**: 1573-1576, 2001.

25. Subcommittee for scleroderma criteria of the American Rheumatism Association Diagnostic and Therapeutic Criteria Committee. Preliminary criteria for the classification of systemic sclerosis (scleroderma). Arthritis Rheum **23**: 581-590, 1980.

The Internal Medicine is an Open Access journal distributed under the Creative Commons Attribution-NonCommercial-NoDerivatives 4.0 International License. To view the details of this license, please visit (https://creativecommons.org/licenses/by-nc-nd/4.0/).

© 2021 The Japanese Society of Internal Medicine
Intern Med 60: 1101-1107, 2021