

Two-visit CAD/CAM milled dentures in the rehabilitation of edentulous arches: A case series

Anish Varkey John, George Abraham¹, Anumol Alias

Private Practitioner, Muvattupuzha, Kerala, ¹Department of Prosthodontics, Christian Dental College, CMC, Ludhiana, Punjab, India

Abstract

Computer-aided design-computer-aided manufacturing (CAD-CAM) has now found its place in the field of removable prosthodontics with the advent of its use in the fabrication of complete dentures. The conventional technique, by injection or compression molding using heat-polymerized resins, requires cumbersome laboratory procedures and up to five patient visits. For patients with time constraints and clinicians with a higher throughput rate, the CAD-CAM approach with a digital workflow can reduce the number of appointments and ensure speedy delivery of the prosthesis. This article describes the rehabilitation of completely edentulous arches using the Baltic Denture System (Merz Dental GmbH[®]) in just two patient visits.

Keywords: Baltic denture system, computer-aided design-computer-aided manufacturing, edentulous, rehabilitation

Address for correspondence: Dr. Anish Varkey John, Dentcare Dental Lab Pvt. Ltd., Muvattupuzha, Kochi - 686 661, Kerala, India.

E-mail: anishvjohn@yahoo.in

Received: 02nd August, 2018, **Accepted:** 12th November, 2018

INTRODUCTION

Complete removable dentures have been the mainstay of rehabilitating edentulous arches to date, though implant-supported prostheses are now gaining popularity. Prosthodontic therapy with implants may not always be feasible due to constraints and contra-indications.^[1] The introduction of computer-aided design/computer-aided manufacturing (CAD/CAM) technology in the field of removable complete denture prosthetics has now effectively reduced patient visits and decreased chairside time, thus expediting the otherwise cumbersome process.^[2] This article describes the rehabilitation of 15 patients with a CAD-CAM removable prosthesis using the Baltic Denture System (Merz Dental[®] GmbH).

CASE REPORT

This article describes the rehabilitation of 15 edentulous older adults, five females and ten males, in the age range of 61–79 years with an average of 67.7 years. Among the patients, 12 of them were previous denture wearers, who were dissatisfied with their current prosthesis. A comprehensive examination was carried out with the aid of the Prosthodontic Diagnostic Index (PDI) Complete Edentulism Checklist,^[3] based on the PDI classification system^[4] by the American College of Prosthodontists. Twelve patients were classified as PDI Class I, which represented favorable diagnostic criteria with a good prognosis. The remaining three patients presented with a greater loss of

Access this article online	
Quick Response Code:	Website: www.j-ips.org
	DOI: 10.4103/jips.jips_252_18

This is an open access journal, and articles are distributed under the terms of the Creative Commons Attribution-NonCommercial-ShareAlike 4.0 License, which allows others to remix, tweak, and build upon the work non-commercially, as long as appropriate credit is given and the new creations are licensed under the identical terms.

For reprints contact: reprints@medknow.com

How to cite this article: John AV, Abraham G, Alias A. Two-visit CAD/CAM milled dentures in the rehabilitation of edentulous arches: A case series. J Indian Prosthodont Soc 2019;19:88-92.

residual alveolar bone height (16–20 mm) and hence were classified as PDI Class II. Due to the time constraints and a favorable ridge relationship, a CAD-CAM complete denture was planned for the patients using the Baltic Denture System after obtaining informed consent from them.^[5,6]

1. The occlusal vertical dimension (OVD) was measured using conventional techniques, and an OVD reference was fabricated using a wooden tongue depressor, which was kept aside
2. The upper impression tray (BD Key®) of the appropriate size was selected and the extensions adjusted as necessitated [Figure 1a and b]
3. Four tissue stops were incorporated in the stress-bearing areas on the inner surface of the maxillary tray using a pliable putty such as thermoplastic impression material (BD Impress®), which is softened at 75–85°C and later hardens to a plastic compound at the oral temperature [Figure 2]
4. The occlusal plane analyzer (BDKEY Plane® and the BDKEY Fin®) was attached to the upper impression tray following which the occlusal plane was oriented parallel to the interpupillary line and the Camper's plane. The facial midline and anterior tooth visibility were also verified [Figure 3]
5. Once the material set, the tray was removed from the mouth, and border molding accomplished using the thermoplastic impression material (BD Impress®). The orientation of the occlusal plane was reassessed initially and following border molding, using the easily detachable plane analyzer
6. The final wash impression was then made with light-bodied polyvinyl siloxane (PVS) (Virtual® Light Body, Ivoclar Vivadent AG, Liechtenstein) [Figure 4]
7. A centric lock (BD Key® Lock) was used to secure the lower impression tray onto the upper tray, following the application of three tissue stops (two in the molar region and one in the anterior region) [Figure 5a]
8. The patient was guided into centric relation and made to close the mouth until the appropriate vertical dimension was obtained

9. Mandibular border molding and the final impression procedure, using light-bodied PVS (Virtual® Light Body (Ivoclar Vivadent AG, Liechtenstein), were then carried out. The OVD was established and reassessed intermittently during this step [Figure 5b]
10. Frontal and lateral view photographs with the lips at rest and in smile were taken to assist the dental laboratory technician with the design fabrication and tooth shade selection
11. Once the esthetics and functions were reevaluated and the patient satisfied, the impressions were sent to the dental laboratory following the standard disinfection protocols
12. In the laboratory, an extraoral scanner (D2000, 3Shape®, Denmark) was used to scan the impressions and the bite registration [Figure 6a and b]
13. A virtual three-dimensional model was obtained by importing the scanned data into the specialized software (BD Creator®). The functional borders and reference points such as the center of the ridge, the incisal papilla, and midpalatal suture were marked for aiding in aligning the teeth and even generating milling paths
14. The appropriate milling block (BD Load®) size and jaw width were selected along with the teeth. The software allows altering the vertical dimension of the scanned records by about 1.5 mm and any changes to the three-dimensional orientation of the occlusal plane could be brought about
15. The teeth setting could be rotated or moved to any position as desired, conforming to the anatomic landmarks. The denture base design with a border thickness of 2 mm (which could be increased if necessary) was generated by the CAD software, and the necessary relief was provided where desired [Figure 7]
16. The stereolithography file was then exported to the CAM software (WorkNC®, Vero India Software Pvt

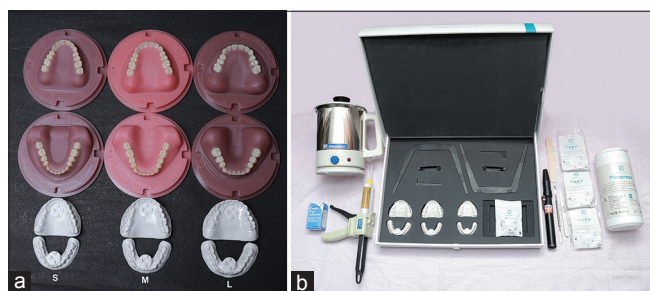

Figure 1: (a) The BD Key® Sets corresponding to the Load Blanks of various shades and sizes. (b) Armamentarium for impression making and registration of maxillomandibular relationship



Figure 2: Tissue stops incorporated in the upper key



Figure 3: Using BD Key® plane and Fin for orientation occlusal plane

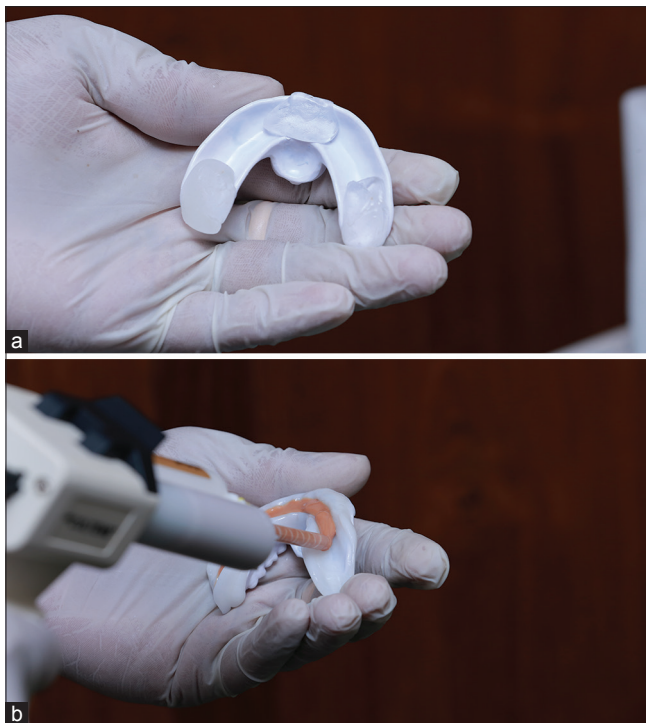


Figure 5: (a) Tissue stops incorporated in the lower key. (b) Making mandibular final impression using polyvinyl siloxane

- Ltd), and the final prosthesis was milled from the milling blank using a 5-axis milling machine (imes-icore® 350i GmbH, Germany) [Figure 8a and b]
17. Following the milling, the dentures were separated from the blank using rotary instruments, and conventional finishing and polishing were performed
 18. The dentures were inserted at the second appointment and minor occlusal adjustments were carried out [Figure 9]. Overextensions of the denture flanges, if present, were altered, and the denture was finished and polished before delivery to the patient
 19. The patients were recalled after a week and then after

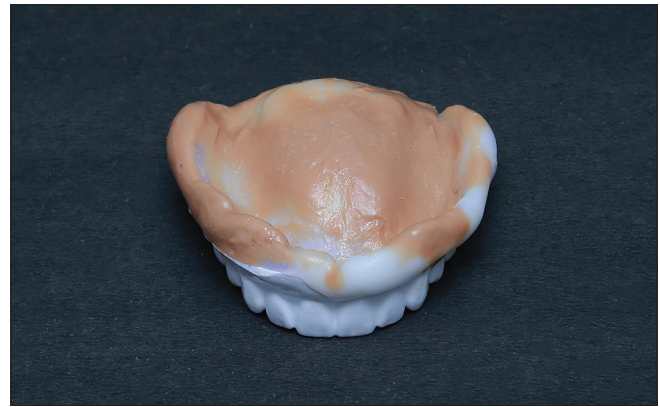


Figure 4: The maxillary final impression using polyvinyl siloxane

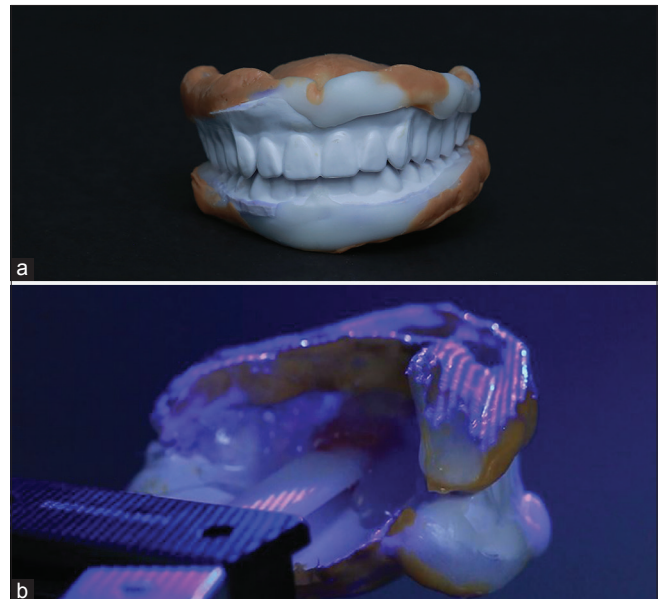

Figure 6: (a) Completed impressions with key set bite registration. (b) Extraoral scanning of the impressions and bite registration

6 weeks for evaluation. They were visibly satisfied with the new dentures and did not face any problem in function [Figure 10]. The patients are scheduled for 6 months and yearly follow-up to evaluate the functional stability of the new CAD-CAM dentures.

DISCUSSION

Compared to conventional dentures, CAD-CAM dentures have been found to have reduced resin volume and weight, which can increase patients' comfort and adaptability.^[7] These dentures release little monomer; however, it has not been found to be statistically significant when compared to longtime, water bath, heat-polymerized dentures fabricated conventionally.^[7] Studies have shown that CAD-CAM dentures fit better than that of conventional ones, which again increase patients' tolerance and acceptability.^[8,9] The intaglio

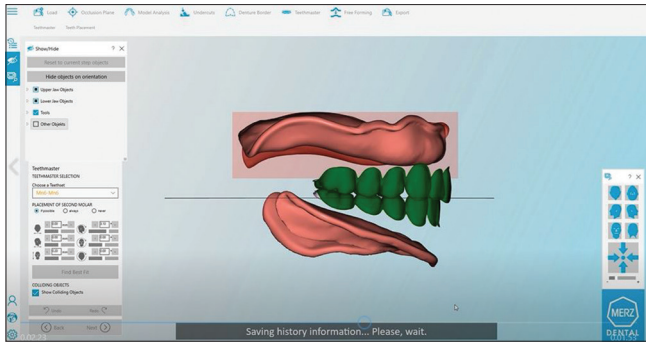


Figure 7: Computer-aided designing using specialized software

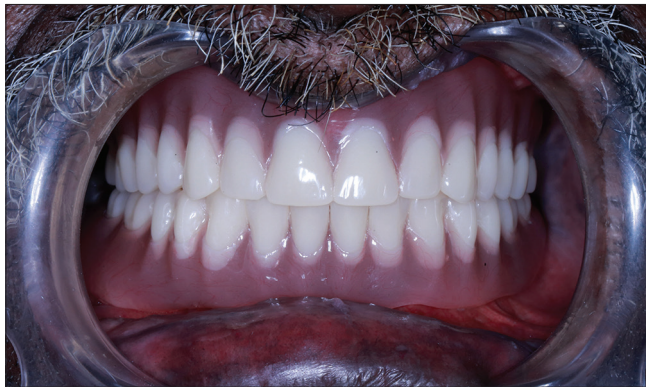
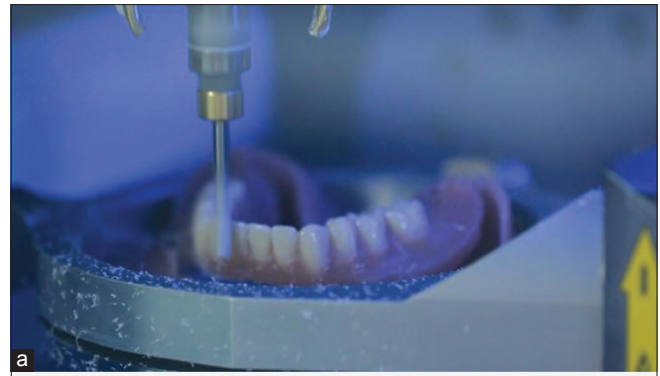
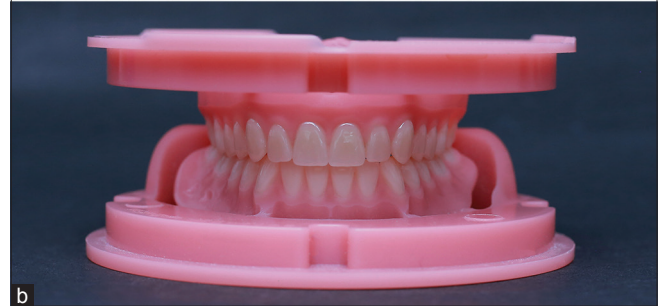Figure 9: Final prosthesis post insertion and adjustment

surface trueness of the milled CAD-CAM dentures has been found to be comparable to injection-molded and conventional techniques, which contributes to the success of the prosthesis.^[10] Polymerization shrinkage is not an issue with these dentures as they are milled from resin blanks and hence result in fewer microporosities.^[11] The absence of shrinkage also enhances the adaptation of the denture base.^[8,9] However, it has been reported that CAD/CAM denture base resins do not generally have a higher fracture tolerance than manually processed heat-polymerizing resins.^[12]

The biggest advantage of the Baltic Denture System is the reduced clinical visits, which is appealing to both the clinician (especially those with a higher throughput rate) and patients alike. The denture delivery is ensured at the second visit in comparison with other CAD-CAM systems currently available.^[7] There is no concern of debonding of denture teeth from the denture base, unlike other systems,^[7] as the teeth have already been incorporated in the milling blank in eugnathic lingualized occlusion. However, the inability to digitally customize the dentures and accurately verify centric relation is one of the drawbacks. This denture system is presently applicable only to patients with a favorable Class I maxillomandibular relationship, which is another limitation when compared



a



b

Figure 8: (a) Milling the computer-aided design/computer-aided manufacturing denture using a 5-axis milling machine. (b) Milled dentures ready for conventional finishing and polishing



Figure 10: Happy patient with his new dentures, in just two visits

with conventional techniques. However, there is a scope for extensive research, backed by long-term clinical studies in this relatively new technology, CAD-CAM dentures are here to stay!

Declaration of patient consent

The authors certify that they have obtained all the appropriate patient consent forms. In the form, the patients have given their consent for their images and other clinical information to be reported in the journal. The patients understand that their names and initials will not be published and due efforts will be made to conceal their identity, but anonymity cannot be guaranteed.

Acknowledgment

We would like to acknowledge the support of the DentCare Dental Lab Pvt. Ltd., India, which has provided the armamentarium and facilities required for the manufacture of digital dentures. We also thank to Mr. Peter Böhmert, CAD-CAM Specialist, Merz Dental GmbH, Germany, for his guidance and timely help.

Financial support and sponsorship

This research was supported by the DentCare Dental Lab Pvt. Ltd.

Conflicts of interest

There are no conflicts of interest.

REFERENCES

1. Zarb G, Hobkirk J, Eckert S, Jacob R. Prosthodontic Treatment for Edentulous Patients. 13th ed. St. Louis, Mo.: Elsevier Mosby; 2013. p. 331.
2. Bidra AS, Taylor TD, Agar JR. Computer-aided technology for fabricating complete dentures: Systematic review of historical background, current status, and future perspectives. *J Prosthet Dent* 2013;109:361-6.
3. Prosthodontics.org; 2018. Available from: https://www.prosthodontics.org/assets/1/7/Complete_Edentulism_Checklist.pdf. [Last accessed on 2018 Sep 25].
4. McGarry TJ, Nimmo A, Skiba JF, Ahlstrom RH, Smith CR, Koumjian JH, *et al.* Classification system for complete edentulism. *The American College of Prosthodontics. J Prosthodont* 1999;8:27-39.
5. Merz Dental GmbH. Innovation | Baltic Denture System. [Baltic-Denture-System.de](https://www.baltic-denture-system.de/en/); 2018. Available from: <https://www.baltic-denture-system.de/en/>. [Last accessed on 2018 Sep 25].
6. Merz Dental. Digital Dentures: Baltic Denture System from Merz Dental. [Dental-Design-Schneider.de](https://www.dental-designschneider.de/files/mydentalfamily/baltic_denture/In%20LMT%20-%20Mar17%20-%20Merz.pdf); 2017. Available from: https://www.dental-designschneider.de/files/mydentalfamily/baltic_denture/In%20LMT%20-%20Mar17%20-%20Merz.pdf. [Last accessed on 2018 Sep 25].
7. Steinmassl PA, Wiedemair V, Huck C, Klauzner F, Steinmassl O, Grunert I, *et al.* Do CAD/CAM dentures really release less monomer than conventional dentures? *Clin Oral Investig* 2017;21:1697-705.
8. Kattadiyil MT, Goodacre CJ, Baba NZ. CAD/CAM complete dentures: A review of two commercial fabrication systems. *J Calif Dent Assoc* 2013;41:407-16.
9. Goodacre BJ, Goodacre CJ, Baba NZ, Kattadiyil MT. Comparison of denture base adaptation between CAD-CAM and conventional fabrication techniques. *J Prosthet Dent* 2016;116:249-56.
10. Srinivasan M, Cantin Y, Mehl A, Gjengedal H, Müller F, Schimmel M, *et al.* CAD/CAM milled removable complete dentures: An *in vitro* evaluation of trueness. *Clin Oral Investig* 2017;21:2007-19.
11. Infante L, Yilmaz B, McGlumphy E, Finger I. Fabricating complete dentures with CAD/CAM technology. *J Prosthet Dent* 2014;111:351-5.
12. Steinmassl O, Offermanns V, Stöckl W, Dumfahrt H, Grunert I, Steinmassl PA, *et al.* *In vitro* analysis of the fracture resistance of CAD/CAM denture base resins. *Materials (Basel)* 2018;11. pii: E401.