

## CASE REPORT

# Multi-exon *COL5A1* deletion in a child with classical Ehlers–Danlos syndrome: A case report expanding the allelic spectrum and showing evidence of parental gonosomal mosaicism

Sonja Strang-Karlsson<sup>1</sup>  | Sylvia Keigwin<sup>2</sup> | Anna-Kaisa Anttonen<sup>1</sup> |  
Duncan Baker<sup>2</sup> | Kerry Bean<sup>2</sup> | Eveliina Jakkula<sup>1,3</sup>

<sup>1</sup>Department of Clinical Genetics, HUS Diagnostic Center, University of Helsinki and Helsinki University Hospital, Helsinki, Finland

<sup>2</sup>Sheffield Diagnostic Genetics Service, Sheffield Children's NHS Foundation Trust, Sheffield, UK

<sup>3</sup>Department of Medical and Clinical Genetics, University of Helsinki, Helsinki, Finland

## Correspondence

Sonja Strang-Karlsson, Department of Clinical Genetics, HUS Diagnostic Center, University of Helsinki and Helsinki University Hospital, Helsinki, Finland.

Email: [sonja.strang@helsinki.fi](mailto:sonja.strang@helsinki.fi)

## Funding information

This study was funded by state funding for university-level health research in Finland; University of Helsinki.

## Abstract

Classical Ehlers–Danlos syndrome (cEDS) is a rare inherited autosomal dominant connective tissue disorder with core clinical features including skin hyperextensibility, abnormal scarring, and generalized joint hypermobility. Classical EDS is predominantly caused by small pathogenic variants in the genes *COL5A1* and *COL5A2* and occasionally by a *COL1A1* point mutation p.(Arg312Cys), while gross deletions or duplications are uncommon. Gonosomal mosaicism is thought to be exceedingly rare with only two cases reported in the literature. We report a child with cEDS due to a rare gross deletion of exons 2–65 in the *COL5A1* gene, inherited from an unaffected mosaic father. The level of mosaicism in the father was approximately 43% in leucocyte cells and 30% in DNA extracted from skin. Our results expand the allelic spectrum of cEDS variants and suggest that parental mosaicism needs to be considered in patients with suspected cEDS, given its implication for genetic counseling.

## KEYWORDS

collagen type V, Ehlers–Danlos syndrome, germline mosaicism, gonosomal mosaicism

## 1 | INTRODUCTION

Ehlers–Danlos syndrome (EDS) refers to a group of inherited connective tissue disorders with genetic and clinical heterogeneity. The hallmarks of EDS are tissue fragility, skin hyperextensibility, and joint hypermobility. The prevailing 2017 EDS Nosology recognizes 13 subtypes based on clinical criteria and genotype.<sup>1</sup> The classical EDS

subtype (cEDS, MIM #130000, #130010) is defined by two major criteria: (1) skin hyperextensibility plus atrophic scarring and (2) generalized joint hypermobility (gJHM), as well as several minor criteria comprising easy bruising, soft and doughy skin, skin fragility, molluscoid pseudotumors, subcutaneous spheroids, hernia, complications of gJHM, epicanthal folds and a first-degree relative who meets clinical cEDS criteria. The presence of two major

This is an open access article under the terms of the [Creative Commons Attribution-NonCommercial-NoDerivs](https://creativecommons.org/licenses/by-nc-nd/4.0/) License, which permits use and distribution in any medium, provided the original work is properly cited, the use is non-commercial and no modifications or adaptations are made.

© 2022 The Authors. *Clinical Case Reports* published by John Wiley & Sons Ltd.

criteria, or major criterion number 1 and at least three minor criteria, is suggestive of cEDS. A definitive diagnosis of cEDS relies on molecular genetic verification.<sup>1</sup>

Classical EDS is an autosomal dominant disorder caused by pathogenic variants in the collagen type V genes *COL5A1* and *COL5A2*, located on 9q34.3 and 2q32.2, and encoding the respective  $\alpha 1$ - and  $\alpha 2$ -chains of collagen V.<sup>2</sup> Only rarely, cEDS is caused by the c.934C>T p.(Arg-312Cys) variant in *COL1A1*, located on 17q21.33 and encoding collagen I.<sup>3</sup> The mutational spectrum in cEDS is essentially comprised of small variants, while only a handful larger intragenic rearrangements, such as deletions or duplications of one or more exons, are described.<sup>2-4</sup>

Symoens and colleagues<sup>2</sup> reported a de novo rate of two-thirds among 93 mutation-positive cEDS patients. While parental mosaicism is described for several other heritable connective tissue disorders, parental mosaicism in cEDS has not been systematically evaluated.<sup>5,6</sup> Not until recently, the first case of parental mosaicism in cEDS was reported.<sup>7</sup>

We report a child with cEDS caused by a rare multi-exon deletion of *COL5A1*, inherited from an unaffected parent with the deletion in mosaic form.

## 2 | CASE REPORT

The patient is a 13-year-old girl born to nonconsanguineous Finnish parents without family history of cEDS. She was born preterm at gestational weeks 33+3 from an otherwise uneventful twin pregnancy. Her birthweight was 1650 g (−1.7 standard deviations [SD]), length 42, 2 cm (−0.7 SD) and head circumference 27, 6 cm (−3 SD). Apgar scores were 9/10/10 at 1, 5 and 10 min, respectively. The first observations of tissue fragility in the form of skin injury after minimal trauma was made at 1 year of age. During toddlerhood, she presented with frequent episodes of trivial trauma causing easy bruising, soft tissue swelling, skin wounds requiring suturing, and causing abnormal scarring. The forehead, chin, and shins were particularly affected. She was seen by a dermatologist due to excessive bruising. A bleeding disorder laboratory workup showed normal results. She was referred to a clinical geneticist for suspected cEDS. Wide atrophic scars on the knees, forehead and elbows, and numerous bruises on the shins, were noted. She had marked joint hypermobility (Beighton scores 9/9). Next-generation sequencing (NGS) of the *COL5A1* and *COL5A2* genes did not identify any causal variant, and a clinical diagnosis of cEDS was set.

At present, the patient is involved in several sport activities. She notices the joint hypermobility during daily activities and experience postexercise fatigue at times. She has no musculoskeletal pain complaints and feels that the

cEDS does not bother her much. She has had several knee subluxations, none of which have required medical care. She has not had a skin wound requiring stitches for a year, plausibly related to fewer physical traumas. Her echocardiogram is normal. At examination, she has atrophic scars on the forehead, chin and knees, multiple hemosiderotic scars on the shins, epicanthus, narrow face, hyperextensible skin, cutis laxa and skin wrinkling on the ankle, marked joint hypermobility (Beighton 8/9), and piezogenic papules on the heel (Figure 1).

Her father is unaffected, without abnormal scarring, tissue fragility or hyperextensible skin. He had a normal cardiac evaluation including echocardiography and no joint hypermobility at the age of 46 years (Beighton score 0).

## 3 | METHODS AND RESULTS

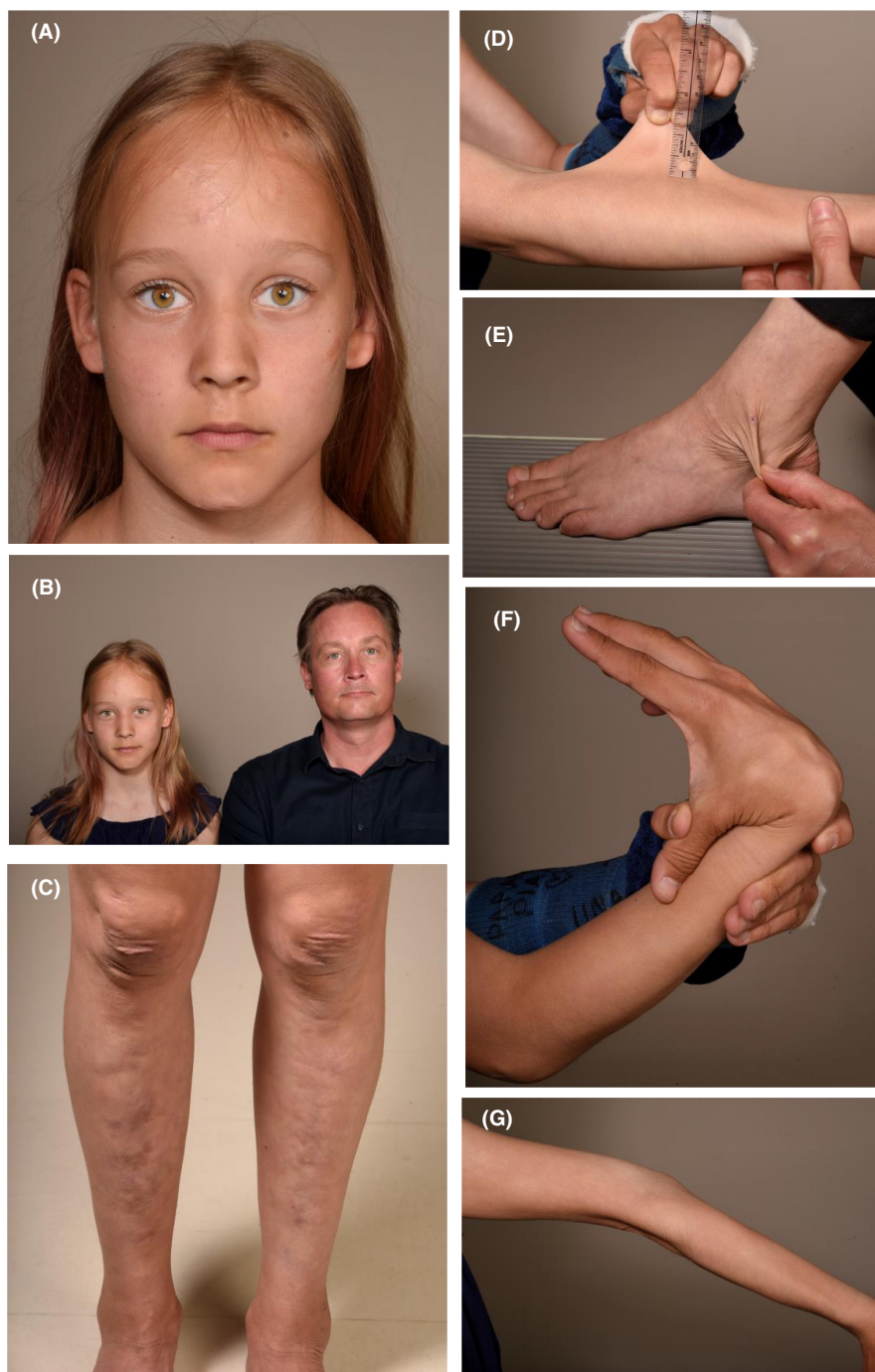
The patient and her father gave written informed consent for publication of clinical and laboratory data and photographs. All genetic analyses were performed in a diagnostic laboratory (Sheffield Diagnostic Genetics Service, UK).

The patient's initial genetic test was NGS of the *COL5A1* (NM\_000093.3) and *COL5A2* (NM\_000093.4) genes. DNA was purified from blood by standard protocol. Library preparation and target enrichment was performed using SureSelect technologies (Agilent, Santa Clara, California, USA), utilizing *in-house* custom-designed probes. Sequencing was performed on the Illumina MiSeq platform to obtain at least 30x read depth for exons and exon-intron boundaries. Reads were mapped to the GRCh37/hg19 human reference sequence using BWA (Burrows Wheeler) alignment. Variants were identified using HaplotypeCaller (Broad Institute), filtered against the *in-house* polymorphism list, and classified according to the American College of Medical Genetics (ACMG) guidelines and the Association for Clinical Genomic Science (ACGS) Best Practice Guidelines.<sup>8,9</sup> No pathogenic or likely pathogenic variant was detected on sequencing.

Due to strong clinical suspicion of cEDS, a second-tier test was undertaken at a reevaluation visit. *COL5A1* dosage analysis on DNA from blood was investigated with Multiplex Ligation-dependent Probe Amplification (MLPA), following the manufacturer's guidelines using MRC-Holland kits for *COL5A1* (P331-B1 and P332-C1, not covering exon 66). A heterozygous multi-exon deletion involving exons 2–65 was detected, NC\_000009.12 (NM\_000093.5):c.(109+1\_110–1)\_(5370+1\_?) del. As the *COL5A1* gene has 66 exons, the deletion removes almost the entire gene.

Family-member testing for the *COL5A1* deletion on DNA from blood showed that the variant was inherited

**FIGURE 1** (A) The patient presenting with atrophic scars on the forehead and chin, (B) the patient and her father, (C) hemosiderotic and atrophic scars on the knees and shins of the patient, (D, E) hyperextensible skin and (F, G) joint hypermobility in the patient.



from the father, who harbored the deletion in the mosaic state. The mother and siblings, including the patient's nonidentical twin, were noncarriers. The level of mosaicism in the father was studied using MLPA (MRC Holland, kits P331-B2 and P332-C2) and a custom-designed exon copy number detection assay using Droplet Digital PCR (Bio-Rad, Hercules, California, USA) for *COL5A1* exons 27 and 63, designed according to Bio-Rad instructions. Analysis of DNA from blood gave a result consistent with approximately 43% of cells containing the variant allele, while the corresponding

figure for DNA extracted from skin biopsy was approximately 30%.

The deletion is absent from the control population in the Genome Aggregation Database (gnomAD SVs v2.1). To our knowledge, it has not been previously published or reported in the mutation databases ClinVar, LOVD (Leiden Open Variation Database), or HGMD (Human Gene Mutation Database) professional 2021.4. It is classified as pathogenic according to the ACMG and ACGS guidelines because it is absent from control populations, the variant type is a multi-exon deletion in a gene where

loss of function is a known disease mechanism, and the diagnostic laboratory had a prior *in-house* observation of the variant in an unpublished patient.<sup>8,9</sup> We have submitted the variant to the LOVD Database (<https://www.LOVD.nl>).

## 4 | DISCUSSION

We report a child with cEDS due to a novel multi-exon deletion in the *COL5A1* gene, a mutation type rarely reported in cEDS. The deletion was inherited from a clinically unaffected mosaic father. This is, to the best of our knowledge, the third case of gonosomal (also known as somatogonadal) mosaicism in cEDS reported in the literature.

Pathogenic variants in *COL5A1* are mostly unique point mutations scattered throughout the gene. In LOVD, 487 *COL5A1* variants are reported of which only 0.8% ( $n = 4$ ) are deletions of one or more exons. Similarly, of the 168 *COL5A2* variants reported, only one (0.6%) is a gross deletion. Haploinsufficiency is an established disease mechanism in cEDS.<sup>4</sup> Interestingly, in gnomAD (SVs v2.1), no loss of function structural variants in *COL5A1* are reported. Taken together, incorporating copy number variant (CNV) analysis in the cEDS testing strategy is recommended. In this case, at the time of the patient's first genetic test, the bioinformatic pipeline for NGS data did not include any CNV detection algorithm and solely focused on sequence variant analysis. Detection of CNVs from targeted short-read NGS sequencing data, especially single exon variants or mosaic CNVs, is challenging due to issues related to the technology itself (such as short reads and GC-content bias). We speculate that gross deletions of *COL5A1* or *COL5A2* may be an underrecognized cause of cEDS and perhaps explain part of the missing heritability.<sup>4</sup>

Gonosomal mosaicism occurs in several heritable connective tissue disorders, for example Loeys-Dietz syndrome and Marfan syndrome.<sup>5,6</sup> In a study on 333 individuals with Marfan syndrome, around 5% of assumed de novo cases were caused by parental gonosomal mosaicism.<sup>7</sup> In the same study, a case with low-level parental mosaicism for a *COL5A1* variant was reported for the first time. The patient with cEDS had inherited a *COL5A1* (NM\_000093.5) c.3179G>A variant from his clinically unaffected father, who had a variant allele frequency (VAF) of 11% in blood as analyzed with deep NGS. In our study, the level of mosaicism in the patient's father was clearly higher, yet he was clinically unaffected. The second case of parental gonosomal mosaicism in cEDS was recently described in a child with cEDS due to a heterozygous *COL5A1* c.1369G>T, p.(Glu457\*) variant

inherited from her father, who had an estimated VAF of 4.8% in blood.<sup>10</sup> Common to all cases (the two previously reported ones and our patient), is that the children had typical cEDS due to a *COL5A1* mutation inherited from a mosaic father, who was clinically unaffected himself.

Our patient had numerous typical cEDS symptoms, yet her clinical presentation was not severe. This is in line with a study on 75 cEDS patients, suggesting a milder multi-system involvement in cEDS and a more favorable disease course compared to other EDS subtypes.<sup>3</sup> The young age of our patient may partly explain the nonsevere clinical presentation, as some symptoms may manifest later in life.

Parental mosaicism in cEDS has not been systematically evaluated. However, the rate of parental mosaicism in vascular EDS (vEDS, MIM 130050), caused by pathogenic variants in the *COL3A1* gene, has been studied and reported to be 2%–3%.<sup>5</sup> Parental mosaicism may be underrecognized in cEDS, which has been the case for several other conditions.<sup>11</sup> Detection of parental mosaicism is constrained by technical limitations, costs, and shortage of available tissues. The advent of more sensitive and precise methods for detecting mosaicism, such as digital droplet PCR (ddPCR), might shed light on the actual rate of parental mosaicism in cEDS.<sup>12</sup> The importance of detecting parental mosaicism was illustrated in a large trio-based exome sequencing study on developmental disorders (4293 probands), which identified parental mosaicism in 0.5% of trios, implicating a substantially increased sibling recurrence risk.<sup>13</sup> In cases with parental mosaicism, a precise recurrence risk cannot be given but may be—depending on the proportion of mutated parental germ cells—as high as 50%, which is clearly higher than for de novo cases.

In conclusion, our findings underline the importance of including CNV analysis in the cEDS testing strategy and suggest that parental gonosomal mosaicism should be considered in genetic counseling of cEDS families, given the increased recurrence risk. Future studies, utilizing the technical development of more sensitive methods for detecting mosaicism, are needed to provide a more precise estimate of the rate of gonosomal mosaicism in cEDS.

## AUTHOR CONTRIBUTIONS

Sonja Strang-Karlsson collected the data, designed the case report and wrote the first draft of the manuscript and critically revised it for intellectual content. Sylwia Keigwin drafted the manuscript, performed and interpreted the genetic analyses. Anna-Kaisa Anttonen collected data and critically revised the manuscript for intellectual content. Duncan Baker and Kerry Bean performed and interpreted the genetic analyses. Eveliina Jakkula drafted the manuscript, interpreted the data and critically revised the manuscript for intellectual content. All authors read and approved the final manuscript.



## ACKNOWLEDGMENTS

The authors gratefully acknowledge the patient and her family for allowing publication of their data. The authors (SSK, AKA, and EJ) of this publication are members of the European Reference Network on Rare Congenital Malformations and Rare Intellectual Disability ERN-ITHACA. [EU Framework Partnership Agreement ID: 3HP-HP-FPA ERN-01-2016/739516] Mark Wheeler, Anna Poptsi and James Chisholm are gratefully acknowledged for technical assistance with the laboratory work.

## FUNDING INFORMATION

This study was funded by state funding for university-level health research in Finland; University of Helsinki.

## CONFLICT OF INTEREST

The authors report no conflict of interest.

## DATA AVAILABILITY STATEMENT

Data sharing is not applicable to this article as no new data were created or analyzed in this study.

## ETHICAL APPROVAL

DNA samples analyzed were collected during routine diagnostics. Given the retrospective nature of this case report, no additional ethical approval was required.

## CONSENT

Written informed consent was obtained from the patient to publish the report in accordance with the journal's patient consent policy.

## ORCID

Sonja Strang-Karlsson  <https://orcid.org/0000-0002-8594-2077>

## REFERENCES

1. Malfait F, Francomano C, Byers P, et al. The 2017 international classification of the Ehlers-Danlos syndromes. *Am J Med Genet C Semin Med Genet.* 2017;175:8-26.
2. Symoens S, Syx D, Malfait F, et al. Comprehensive molecular analysis demonstrates type V collagen mutations in over 90% of patients with classic EDS and allows to refine diagnostic criteria. *Hum Mutat.* 2012;33:1485-1493.
3. Ritelli M, Venturini M, Cinquina V, Chiarelli N, Colombi M. Multisystemic manifestations in a cohort of 75 classical

Ehlers-Danlos syndrome patients: natural history and nosological perspectives. *Orphanet J Rare Dis.* 2020;15:197.

4. Colman M, Syx D, de Wandele I, Dhooge T, Symoens S, Malfait F. Clinical and molecular characteristics of 168 probands and 65 relatives with a clinical presentation of classical Ehlers-Danlos syndrome. *Hum Mutat.* 2021;42:1294-1306.
5. Legrand A, Devriese M, Dupuis-Girod S, et al. Frequency of de novo variants and parental mosaicism in vascular Ehlers-Danlos syndrome. *Genet Med.* 2019;21(7):1568-1575.
6. Baban A, Magliozzi M, Loeys B, et al. First evidence of maternally inherited mosaicism in TGFBR1 and subtle primary myocardial changes in Loeys-Dietz syndrome: a case report. *BMC Med Genet.* 2018;19:170.
7. Chesneau B, Plancke A, Rolland G, et al. Parental mosaicism in Marfan and Ehlers-Danlos syndrome and related disorders. *Eur J Hum Genet.* 2021;29:771-779.
8. Richards S, Aziz N, Bale S, et al. Standards and guidelines for the interpretation of sequence variants: a joint consensus recommendation of the American College of Medical Genetics and Genomics and the Association for Molecular Pathology. *Genet Med.* 2005;17:405-424.
9. Ellard S, Baple EL, Callaway A, Berry I, Forrester N, Turnbull C, Owens M, Eccles DM, Abbs S, Scott R. *ACGS Best Practice Guidelines for Variant Classification in Rare Disease.* Association for Clinical Genomic Science; 2020. <http://www.acgs.uk.com/quality/best-practice-guidelines>
10. Micale L, Foadelli T, Russo F, et al. Gonosomal mosaicism for a novel *COL5A1* pathogenic variant in classic Ehlers-Danlos syndrome. *Genes.* 2021;12:1928.
11. Campbell IM, Yuan B, Robberecht C, et al. Parental somatic mosaicism is underrecognized and influences recurrence risk of genomic disorders. *Am J Hum Genet.* 2014;95:173-182.
12. Liu Q, Karolak JA, Grochowski CM, et al. Parental somatic mosaicism for CNV deletions—a need for more sensitive and precise detection methods in clinical diagnostics settings. *Genomics.* 2020;112:2937-2941.
13. Wright CF, Prigmore E, Rajan D, et al. Clinically-relevant postzygotic mosaicism in parents and children with developmental disorders in trio exome sequencing data. *Nat Commun.* 2019;10:2985.

**How to cite this article:** Strang-Karlsson S, Keigwin S, Anttonen A-K, Baker D, Bean K, Jakkula E. Multi-exon *COL5A1* deletion in a child with classical Ehlers-Danlos syndrome: A case report expanding the allelic spectrum and showing evidence of parental gonosomal mosaicism. *Clin Case Rep.* 2022;10:e06455. doi:[10.1002/ccr3.6455](https://doi.org/10.1002/ccr3.6455)