

Graft-versus-host disease: a case report of a rare but reversible cause of constrictive pericarditis

Christopher A. Pieri ¹, Neil Roberts², John Gribben ^{2,3}, and Charlotte Manisty ^{2,4*}

¹Institute of Health Sciences, Barts and The London School of Medicine and Dentistry, West Smithfield, London EC1A 7BE, UK; ²Barts Heart Centre, Barts Health NHS Trust, West Smithfield, London EC1A 7BE, UK; ³Barts Cancer Institute, Charterhouse Square, London EC1M 6BQ, UK; and ⁴Institute of Cardiovascular Sciences, University College London, London, UK

Received 12 August 2019; first decision 11 September 2019; accepted 6 January 2020; online publish-ahead-of-print 4 March 2020

Background

Constrictive pericarditis (CP), although an uncommon cause of heart failure, requires specialist multidisciplinary input and multi-modality imaging to identify the underlying aetiology and treat potentially reversible causes.

Case summary

We report the case of a 74-year-old gentleman referred for assessment of progressive exertional dyspnoea and peripheral oedema, 30 months following treatment of acute myeloid leukaemia with high-dose chemotherapy and allogeneic stem cell transplantation. Clinical examination and cardiac imaging revealed a small pericardial effusion and pericardial thickening with constrictive physiology; however, no aetiology was identified despite diagnostic pericardiocentesis. The patient required recurrent hospital admissions for intravenous diuresis, therefore, following multidisciplinary discussions, surgical partial pericardectomy was performed. Histology suggested graft-vs.-host disease (GvHD) and post-operatively, the patient improved clinically. Following immunomodulatory therapy with ruxolitinib for both pericardial and pulmonary GvHD, his functional status improved further with no subsequent hospital admissions.

Discussion

Although pericardial disease in cancer patients is common, CP is unusual. Determining the underlying aetiology is important for subsequent management, and here, we describe the use of multi-modality imaging to diagnose a rare cause, GvHD, which responded to surgical treatment and immunomodulatory therapy.

Keywords

Constrictive pericarditis • Heart failure • Cardio-oncology • Allogeneic stem cell transplantation • Graft-vs.-host disease • Case report

Learning points

- Pericardial disease in cancer is common and may be related to the cancer itself or cancer therapy.
- Constrictive pericarditis (CP) causes characteristic abnormalities in diastolic ventricular filling, but diagnosis should also attempt to determine the underlying aetiology. Diagnosis and subsequent management require multi-modality imaging alongside multidisciplinary involvement from cardiology, cardiothoracic surgery, histopathology, and microbiology, together with the physicians treating any potential causative underlying condition.
- Graft-vs.-host disease is a rare, but potentially reversible cause of CP, amenable to surgery and appropriate immunomodulation.

* Corresponding author. Tel: +44 203 456 3081, Fax: +44 203 456 3086, Email: c.manisty@ucl.ac.uk

Handling Editor: Monika Arzanauskaite

Peer-reviewers: Hafiz Naderi, Hajnalka Vágó, and Domenico D'Amario

Compliance Editor: Anastasia Vamvakidou

Supplementary Material Editor: Ross Thomson

© The Author(s) 2020. Published by Oxford University Press on behalf of the European Society of Cardiology.

This is an Open Access article distributed under the terms of the Creative Commons Attribution Non-Commercial License (<http://creativecommons.org/licenses/by-nc/4.0/>), which permits non-commercial re-use, distribution, and reproduction in any medium, provided the original work is properly cited. For commercial re-use, please contact journals.permissions@oup.com

Introduction

Pericardial disease is common in patients with cancer—presenting either with pericarditis, pericardial effusions, pericardial masses, or pericardial constriction. It may be related to the underlying cancer diagnosis (such as with lymphoma or metastatic breast cancer-related effusions) or a complication of the administered cancer treatment. Constrictive pericarditis (CP) is characterized by pericardial fibrosis and thickening, leading to a loss in pericardial compliance, ultimately causing impaired ventricular filling.¹ Although now a relatively uncommon cause of heart failure; both diagnosis and management can be challenging, particularly in cancer patients. Detection of CP is reliant on appropriate imaging techniques.² Echocardiograms offer a functional assessment of cardiac physiology and can identify pericardial thickening, which can be characterized more elegantly using cross-sectional imaging modalities, such as magnetic resonance imaging or computed tomography. Furthermore, identifying the underlying aetiology is essential, as some causes of CP are reversible with timely medical management.³ If established, surgical pericardectomy may represent the only viable option in delivering adequate functional recovery despite its high peri-operative risk.⁴

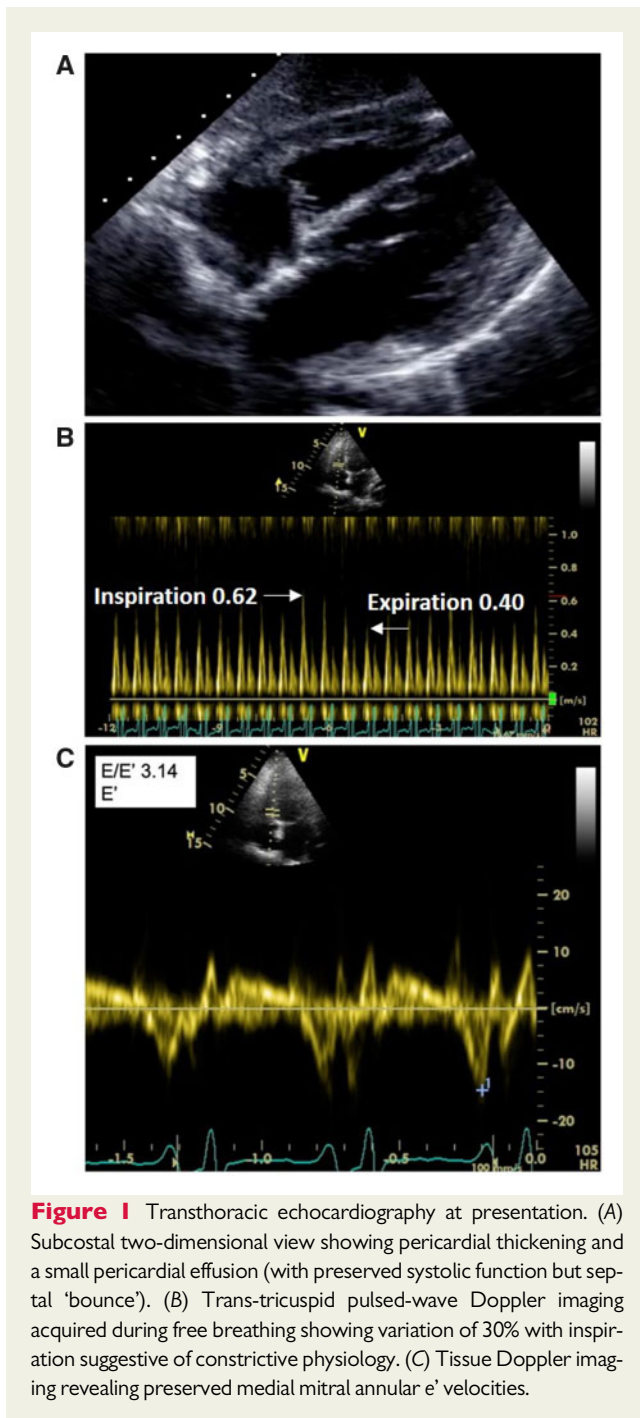
Timeline

Case presentation

A 74-year-old Caucasian man presented with significant exertional dyspnoea and peripheral oedema; progressive over a 12-month period. Of note, he had undergone allogeneic stem cell transplantation following high-dose chemotherapy (fludarabine/cyclophosphamide and methotrexate) 30 months previously for acute myeloid leukaemia. He had recovered well from this aside from an episode of skin GvHD which responded well to oral prednisolone and ciclosporin. He was known to have mild coronary artery disease (diagnosed by invasive coronary angiography), hypertension, and paroxysmal atrial fibrillation. His medication list was as follows Apixaban 5 mg twice daily, Atorvastatin 20 mg nocte, Omeprazole 20 mg daily, Ramipril 10 mg daily, Acyclovir 400 mg twice daily, Mycophenolate 500 mg twice daily, and Penicillin V 250 mg twice daily.

Clinical examination revealed a pulse of 110 b.p.m. (regular), blood pressure 98/60 mmHg, and JVP +8 cm. His oxygen saturations were 92% on room air with bilateral pleural effusions suggestive of pulmonary oedema and peripheral oedema to mid-thigh. Pericardial knock was heard, pulsus paradoxus, and Kussmaul's sign were absent. Baseline electrocardiogram demonstrated sinus tachycardia only. Chest radiography confirmed pulmonary oedema and pleural effusions. His c-reactive protein, N-terminal pro b-type natriuretic peptide, and troponin-T levels were elevated [69 mg/L (reference range < 5 mg/L), 2800 ng/L (reference range < 400 ng/L), and 26 ng/dL

Time	Events
30 months prior	Diagnosis of acute myeloid leukaemia; treated with high-dose chemotherapy and subsequent allogeneic stem cell transplantation.
26 months prior	Episode of mild skin graft-vs.-host disease (GvHD); treated with oral prednisolone and ciclosporin with rapid resolution of symptoms.
Presentation	Slowly progressive exertional dyspnoea and peripheral oedema. Clinical features in keeping with pulmonary oedema.
Transthoracic echocardiogram	Normal biventricular size and systolic function with septal 'bounce'. Pericardial thickening and small pericardial effusion with evidence of constrictive physiology and moderate bi-atrial dilatation.
Impression	Constrictive pericarditis
Treatment	Intravenous diuresis, high-dose oral steroids and diagnostic pericardiocentesis (350 mL blood-stained fluid drained—negative cytology and microbiology).
1 month post	Cardiac magnetic resonance imaging (MRI) Pericardial thickening suggestive of a constrictive/effusive pericarditis with evidence of ventricular interdependence on real-time free-breathing imaging. No myocardial late gadolinium enhancement.
1–6 months post	Multiple prolonged admissions to hospital with diuretic-refractory pleural and peripheral oedema, New York Heart Association (NYHA) Class 3–4 requiring care home admission on discharge from hospital. Multidisciplinary team decision to proceed with pericardectomy.
6 months post (surgical treatment)	Surgical partial pericardectomy—histology demonstrated presence of fibrous tissue in keeping with GvHD.
18 months post (cardiology follow-up)	Commenced on ruxolitinib 5 mg BD and continued high-dose oral diuretics. Gradual improvement in functional status to NYHA Class 1–2, living independently and recently married. Maintained on ruxolitinib on reducing diuretic doses with cardiac MRI showing only mild pericardial thickening with no ventricular interdependence.



(reference range < 14 ng/dL), respectively] but the remainder of his blood panel was unremarkable.

Transthoracic echocardiography (Figure 1A) showed normal left ventricular dimensions with preserved systolic function (left ventricular ejection fraction 57%) with no hypertrophy or regional wall motion abnormalities. The right ventricular (RV) dimensions were within normal limits with normal function. Moderate bi-atrial dilatation and pericardial thickening were noted. The inferior vena cava measured 20 mm and collapsed <50% with inspiration. The mitral inflow Doppler profile showed E:A ratio of 1.4:1. Respiratory variability was

noted in both trans-mitral (>30%) and trans-tricuspid (>40%) filling pressures on Doppler echocardiography, with preserved septal tissue Doppler E' velocities suggestive of constrictive physiology¹ (Figure 1B and C). Diagnostic pericardiocentesis drained 350 mL of blood-stained fluid, with negative cytology, immunohistochemistry, and microbiology. Computed tomography scanning of the patient's chest, abdomen, and pelvis revealed no evidence of recurrent malignancy or tuberculosis.

Cardiovascular magnetic resonance (CMR) imaging confirmed a diagnosis of effusive CP, with significant pericardial thickening, bi-atrial enlargement, and ventricular interdependence (Figure 2A and B) on real-time free breathing imaging. Tissue characterization found no evidence of myocardial oedema, focal fibrosis, or prior infarction.

The aetiology of the CP was unclear, and management focused on intravenous diuretics alongside empirical high-dose steroids. Unfortunately, he remained New York Heart Association (NYHA) Class 3–4 with diuretic resistant heart failure, requiring multiple prolonged hospital admissions.

Partial pericardectomy (with removal of the anterior pericardium adherent to the RV free and anterior wall, constrained by a boundary of the phrenic nerves) and pericardial biopsy was undertaken following multidisciplinary discussion involving cardiology, cardiothoracic surgery, and haematology, for both diagnostic and therapeutic purposes. Given the pre-operative clinical state of the patient (NYHA Class 3–4) and the presence of very thick localized adhesions a partial, not radical, approach was undertaken, with the surgical team concerned about iatrogenic damage from attempting to remove these islands of adherent pericardium, with unacceptable risk should cardiopulmonary bypass be required. Following stripping of the thickened pericardium, the anterior cardiac surface was seen to move freely intra-operatively (Figure 3). Histological analysis of stripped pericardial tissue displayed features of graft-vs.-host disease (GvHD). Consequently, ruxolitinib (JAK1/JAK2 tyrosine kinase inhibitor) was commenced as a GvHD salvage therapy alongside high-dose oral steroids.

Post-operatively the patient recovered and was discharged from hospital, with sustained clinical improvement over subsequent months. He had no further hospital admissions and his diuretic requirements reduced. At latest review, 12-month post-pericardectomy, his functional status was NYHA Class 1–2 and repeat cardiac imaging exhibited a reduction in pericardial thickness of the residual pericardium, with improved Doppler parameters and no evidence of ventricular inter-dependence by CMR imaging (Figure 2C and D).

Discussion

Constrictive pericarditis is now a relatively uncommon cause of heart failure, with diagnosis and management often problematic.¹ Diagnosis involves identification of characteristic imaging findings in conjunction with invasive haemodynamic assessment where required. Determining the underlying aetiology is more challenging, especially in the context of cancer, where the cause of pericardial disease is often multifactorial. Here, pericardial disease can either be linked directly to the cancer itself or cancer therapies (chemotherapy and radiotherapy); both can cause acute or chronic pericardial damage.⁵

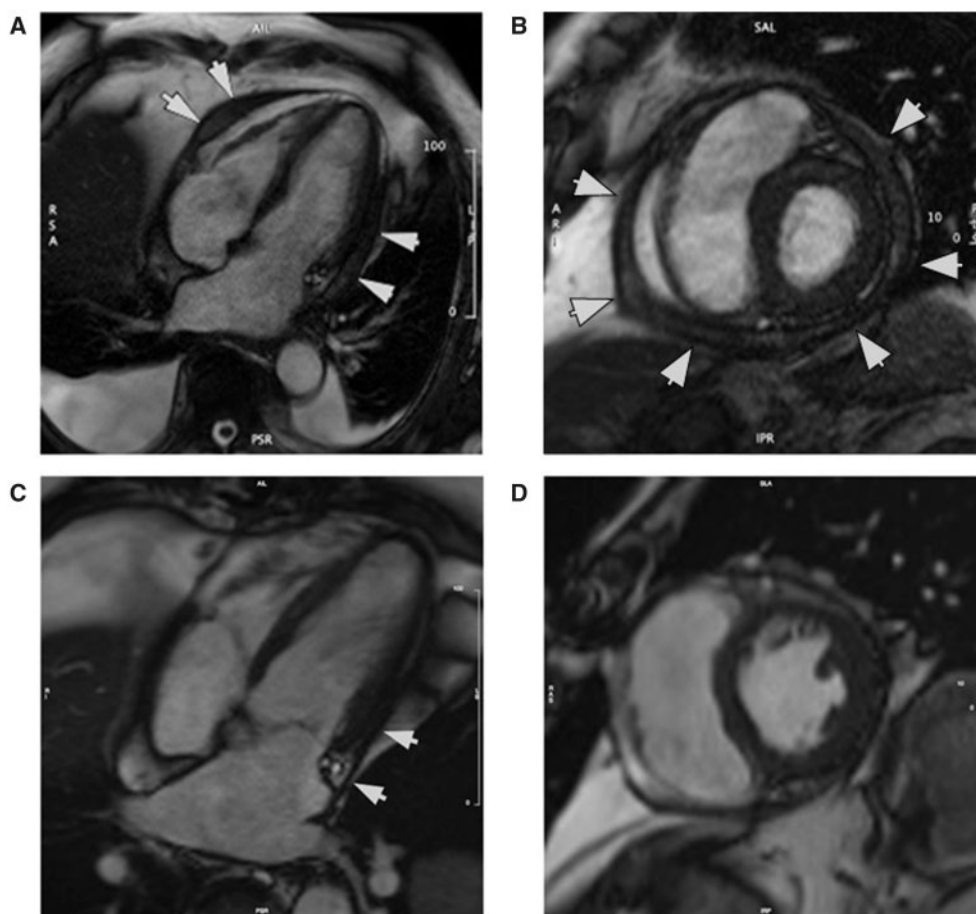


Figure 2 Cardiovascular magnetic resonance imaging. (A and B) Pre-operative cardiovascular magnetic resonance imaging—four-chamber (A) and mid-ventricular short-axis (B) views showing grossly thickened pericardium (arrowed) and bi-atrial dilatation. (C and D) Cardiovascular magnetic resonance acquired at 18-month post-surgery. Four-chamber (C) and short-axis (D) views highlighting reduction in pericardial thickening following pericardectomy and immunomodulation with ruxolitinib. Mild residual pericardial thickening can be noted remaining surrounding left ventricle lateral wall (arrowed; [Supplementary material online, Videos S1–S5](#)).

Here, we describe a rare but potentially reversible cause of CP associated with GvHD. Graft-vs.-host disease contributes a major source of morbidity and mortality in patients following allogeneic haematopoietic stem cell transplantation,⁶ with over half of allogeneic transplant recipients exhibiting clinical GvHD.⁷ It is mediated via donor T-lymphocyte responses to host tissue; while the graft-vs.-tumour effect⁸ confers beneficial effects against underlying malignancy, the immunological reaction to healthy host tissue can result in an inappropriate inflammatory response; manifesting as GvHD. Acute GvHD, occurring within the first 100 days post-haematopoietic stem cell transplantation, can be particularly severe,⁹ affecting the skin, liver and gastrointestinal tract requiring swift aggressive immunosuppression.^{8,10} Chronic GvHD has been closely compared to longstanding autoimmune connective tissue syndromes affecting multiple systems.¹¹ Cardiovascular presentations of GvHD are rare but have been described causing conduction pathway abnormalities, coronary artery disease,¹² and rarely pericarditis.^{13,14}

Importantly, ascertaining the underlying aetiology enabled a targeted management strategy combining surgery with selective inhibition of the Janus-associated tyrosine kinases (JAK1 and JAK2) to be delivered via a multidisciplinary team involving the patient's haematologist, cardiologist, and cardiothoracic surgeon. Continued systemic immunomodulation with ruxolitinib resulted in further sustained improvements to both patient morbidity and performance. This suggests an important role for timely immunosuppression in CP associated with GvHD to dampen the chronic inflammatory processes that mediate irreversible pericardial thickening.

Conclusion

This case describes a rare cause of CP, chronic GvHD that was successfully treated with a combined approach with surgical and targeted immunotherapy. This highlights the importance of multidisciplinary team involvement when managing patients with

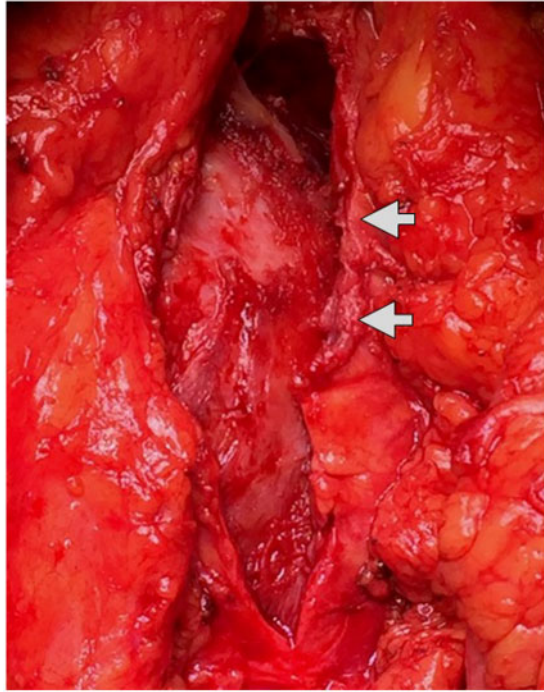


Figure 3 Intra-operative pericardectomy findings. Intra-operative image showing the thickened pericardium, especially noticeable surrounding the free wall of right ventricle (arrowed; [Supplementary material online, Video S6](#)).

cardiovascular disease following cancer treatment, and the emerging need for cardio-oncology.

Lead author biography



Chris Pieri is a clinical teaching fellow based within the Institute of Health Sciences at Barts and The London School of Medicine and Dentistry. During this posting, he has held an honorary contract with Dr Charlotte Manisty, Consultant Cardiologist, within Barts Health NHS Trust allowing him to take formative steps and experience prior to formal core cardiology training.

Supplementary material

[Supplementary material](#) is available at *European Heart Journal - Case Reports* online.

Funding

Charlotte Manisty was directly and indirectly supported by the University College London Hospitals and Barts Biomedical Research Centre.

Slide sets: A fully edited slide set detailing this case and suitable for local presentation is available online as [Supplementary data](#).

Consent: The author/s confirm that written consent for submission and publication of this case report including image(s) and associated text has been obtained from the patient in line with COPE guidance.

Conflict of interest: none declared.

References

1. Geske JB, Anavekar NS, Nishimura RA, Oh JK, Gersh BJ. Differentiation of constriction and restriction. *J Am Coll Cardiol* 2016;**68**:2329–2347.
2. Welch TD, Ling LH, Espinosa RE, Anavekar NS, Wiste HJ, Lahr BD, Schaff HV, Oh JK. Echocardiographic diagnosis of constrictive pericarditis Mayo Clinic criteria. *Circ Cardiovasc Imaging* 2014;**7**:526–534.
3. Syed FF, Schaff HV, Oh JK. Constrictive pericarditis—a curable diastolic heart failure. *Nat Rev Cardiol* 2014;**11**:530–544.
4. Schwefler M, Aschenbach R, Heidemann J, Mey C, Lapp H. Constrictive pericarditis, still a diagnostic challenge: comprehensive review of clinical management. *Eur J Cardiothorac Surg* 2009;**36**:502–510.
5. Ghosh AK, Crake T, Manisty C, Westwood M. Pericardial disease in cancer patients. *Curr Treat Options Cardiovasc Med* 2018;**20**:60.
6. Welniak LA, Blazar BR, Murphy WJ. Immunobiology of allogeneic hematopoietic stem cell transplantation. *Annu Rev Immunol* 2007;**25**:139–170.
7. MacMillan ML, Weisdorf DJ, Wagner JE, DeFor TE, Burns LJ, Ramsay NK, Davies SM, Blazar BR. Response of 443 patients to steroids as primary therapy for acute graft-versus-host disease: comparison of grading systems. *Biol Blood Marrow Transplant* 2002;**8**:387–394.
8. Ferrara JLM, Chaudhry MS. GVHD: biology matters. *Blood Adv* 2018;**2**:3411–3417.
9. Van Lint MT, Milone G, Leotta S, Uderzo C, Scimè R, Dallorso S, Locasciulli A, Guidi S, Mordini N, Sica S, Cudillo L, Fagioli F, Selleri C, Bruno B, Arcese W, Bacigalupo A. Treatment of acute graft-versus-host disease with prednisolone: significant survival advantage for day +5 responders and no advantage for non-responders receiving anti-thymocyte globulin. *Blood* 2006;**107**:4177–4181.
10. de la Rosa García E, Bologna Molina R, de Vega González T. Graft-versus-host disease, an eight case report and literature review. *Med Oral Patol Oral Cir Bucal* 2006;**11**:E486–E492.
11. Ratanatharathorn V, Ayash L, Lazarus H, Fu J, Uberti J. Chronic graft-versus-host disease: clinical manifestation and therapy. *Bone Marrow Transplant* 2001;**28**:121–129.
12. Rackley C, Schultz KR, Goldman FD, Chan KVV, Serrano A, Hulse JE, Gilman AL. Cardiac manifestations of graft-versus-host disease. *Biol Blood Marrow Transplant* 2005;**11**:773–780.
13. Silberstein L, Davies A, Kelsey S, Foran J, Murrell C, D'Cruz D, Vinnicombe S, Norton A, Cavenagh J. Myositis, polyserositis with a large pericardial effusion and constrictive pericarditis as manifestations of chronic graft-versus-host disease after non-myeloablative peripheral stem cell transplantation and subsequent donor lymphocyte infusion. *Bone Marrow Transplant* 2001;**27**:231–233.
14. Holtan SG, Spittell PC. Constrictive pericarditis due to graft-vs-host disease. *Mayo Clin Proc* 2010;**85**:e90.