

Available online at [www.sciencedirect.com](http://www.sciencedirect.com)

ScienceDirect

journal homepage: [www.elsevier.com/locate/radcr](http://www.elsevier.com/locate/radcr)

## Case Report

# Unusual presentation of testicular rhabdomyosarcoma metastases to the right ventricle papillary muscle and tricuspid valve <sup>☆</sup>

Deniz Akay Urgan, MD\*, Biraj Bista, MD, Mayil Krishnam, MD

Division of Cardiovascular and Thoracic Imaging, Department of Radiology, University of California, 101 The City Drive South, Route 140, Irvine, CA, USA

## ARTICLE INFO

## Article history:

Received 6 February 2020

Revised 20 May 2020

Accepted 21 May 2020

## Keywords:

Testicular rhabdomyosarcoma

Cardiac metastases

Papillary muscle

Tricuspid valve

CMR

## ABSTRACT

Intracardiac metastasis of the testicular cancer is very rare phenomenon. A 30-year-old-man with a history of testicular rhabdomyosarcoma and lung metastases was found to have an intracardiac filling defect in a surveillance computed tomography scan 3 years after the initial diagnosis. A cardiac magnetic resonance imaging study was performed for further evaluation and demonstrated a lobulated, heterogeneously enhancing mobile mass within the right ventricle attaching to the anterior papillary muscle. Patient underwent an open surgical resection of the cardiac mass that was confirmed metastasis of testicular rhabdomyosarcoma into the right ventricular papillary muscle and tricuspid valve. To our knowledge, this is the first report in the literature that describes metastasis to a papillary muscle and tricuspid valve from a testicular neoplasm.

© 2020 Published by Elsevier Inc. on behalf of University of Washington.

This is an open access article under the CC BY-NC-ND license.

[\(http://creativecommons.org/licenses/by-nc-nd/4.0/\)](http://creativecommons.org/licenses/by-nc-nd/4.0/)

## Introduction

Testicular tumors are the most common solid neoplasm in the male population under 45 years of age and they comprise 1%-2% of all malignant tumors in the male patients [1]. Intracardiac metastases from testicular tumors is a very rare entity with only very few case reports found in the literature [2,3]. However, none of those reports described involvement of papillary muscle. Cardiac magnetic resonance imaging (CMR) is known to be a helpful diagnostic tool for evaluation of intracardiac masses or cardiac involvement. In this report, we describe a case of testicular tumor metastases to the right ventricle with involvement of papillary muscle and tricuspid valve.

## Case report

A 30-year-old male with a history of right testicular mass and radical orchiectomy followed by chemotherapy was obtained a surveillance computed tomography (CT) scan at the 5-year follow-up that demonstrated multiple, new pulmonary parenchymal metastases (Fig. 1A) in addition to a 2.1 cm filling defect within the right ventricle (Fig. 1B). He was asymptomatic without evidence of chest pain or dyspnea.

A cardiac magnetic resonance imaging MRI was performed on a 1.5 T scanner (Avanto, Siemens Medical Solutions, Germany) for further evaluation of the right ventricular filling

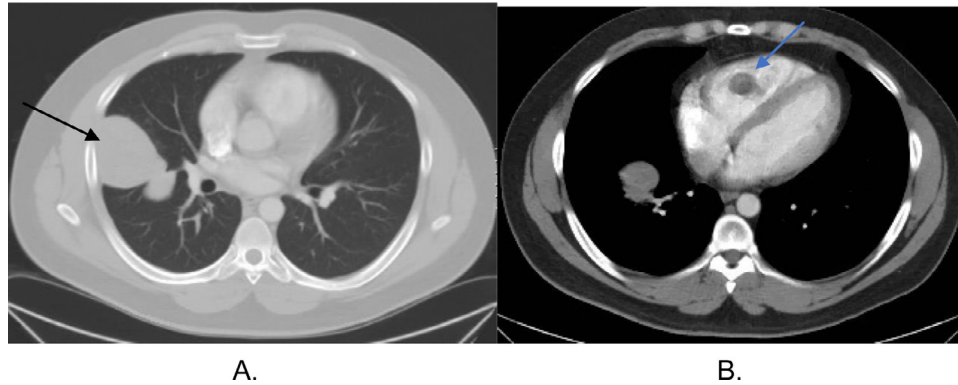
<sup>☆</sup> Declaration of Competing Interests: None.

\* Corresponding author.

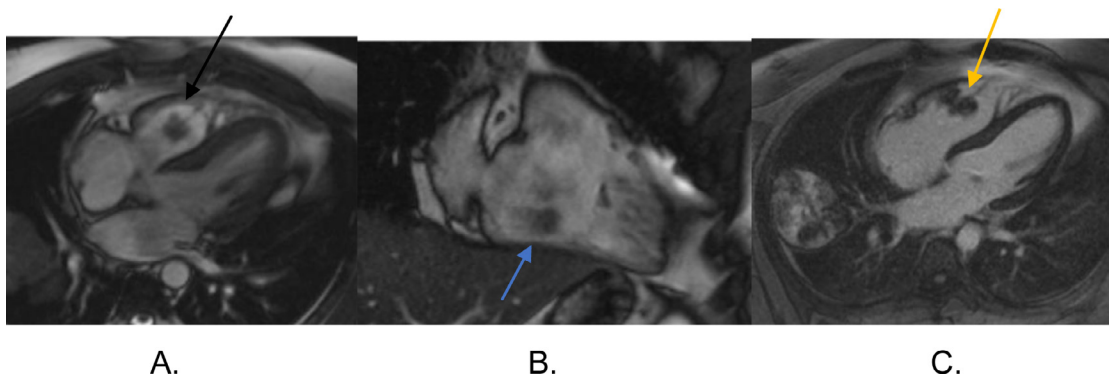
E-mail addresses: [dakayurg@hs.uci.edu](mailto:dakayurg@hs.uci.edu) (D.A. Urgan), [bbista@hs.uci.edu](mailto:bbista@hs.uci.edu) (B. Bista), [mskrishn@uci.edu](mailto:mskrishn@uci.edu) (M. Krishnam).

<https://doi.org/10.1016/j.radcr.2020.05.075>

1930-0433/© 2020 Published by Elsevier Inc. on behalf of University of Washington. This is an open access article under the CC BY-NC-ND license. (<http://creativecommons.org/licenses/by-nc-nd/4.0/>)



**Fig. 1 – (A) CT chest axial plane showing pulmonary metastatic mass in the right upper lobe (black arrow). (B) CT chest showing intracardiac filling defect within the right ventricle (blue arrow).**



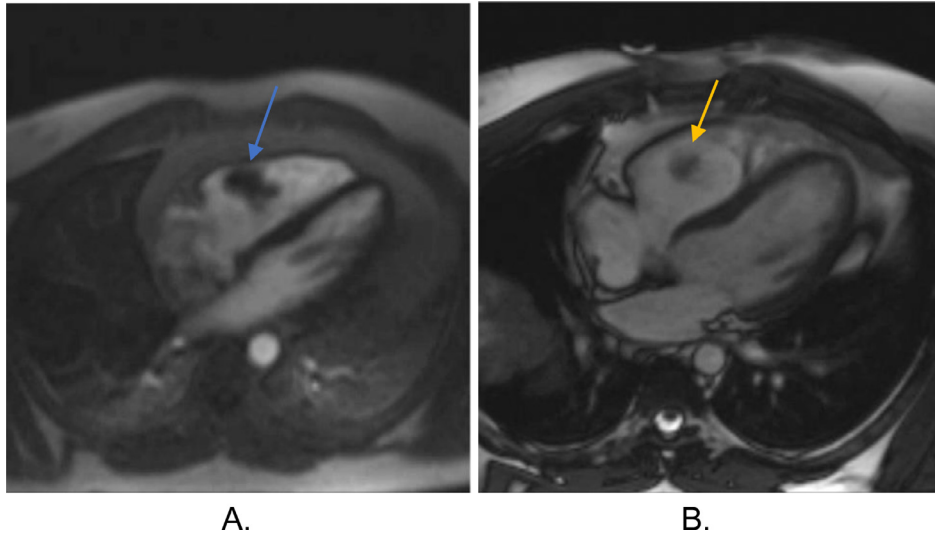
**Fig. 2 – (A) CMR Cine SSFP horizontal long axis (HLA) view showing intracardiac mass in the right ventricle (black arrow). (B) CMR Cine SSFP right ventricular outflow track (RVOT) view showing intracardiac mass in the right ventricle (blue arrow). (C) CMR delayed postcontrast PSIR image showing central heterogeneous enhancement of the right ventricular mass (yellow arrow).**

defect. Multiplanar steady state-free precession (SSFP), multiplanar cine SSFP, diffusion-weighted image (b 0, 1000), multiplanar HASTE, pre- and postcontrast T1-weighted images, first pass dynamic perfusion and delayed multiplanar Phase Sensitive Inversion Recovery (PSIR) sequences were obtained. There was a 3 cm lobulated mass within the anterior papillary muscle of the right ventricle that showed intermediate signal on both T2W image and precontrast T1W image in addition to restricted diffusion and heterogeneous patchy enhancement both on first pass dynamic perfusion and delayed postcontrast PSIR series (Figs. 2A-C and 3A). Mass was mobile on cine SSFP sequence extending to the tricuspid valve (Fig. 3B). Right ventricle was mildly dilated with trace tricuspid regurgitation. The left ventricle was in normal size with an ejection fraction of 63%. In addition, multiple enhancing metastatic pulmonary nodules and masses were seen. Based on imaging findings, right ventricular mass was favored as metastases instead of thrombus due to the presence of a heterogeneously enhanced mass in a patient with a history of testicular malignancy. The patient underwent an open surgical resection of the cardiac mass via oblique right atriotomy approach and 2 independent, mobile, bulbous masses were found to protrude through the tricuspid valve into the right atrium. Intra-

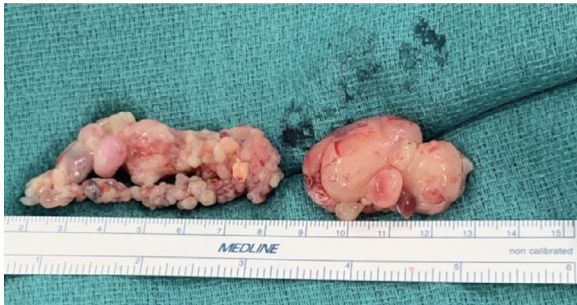operatively, these mass lesions were visualized to be attached to the anterior leaflet of the tricuspid valve and papillary muscle in the right ventricle. The mass lesions were resected completely together with the papillary muscle and were sent for pathology (Fig. 4). Histopathology and immunohistochemistry studies confirmed the mass to be metastatic embryonal rhabdomyosarcoma (Fig. 5). No germ cell tumor component was identified. Immunohistochemical stains show desmin, myogenin, and Myo-D1 positivity which were compatible with patient's metastatic embryonal rhabdomyosarcoma. Patient also underwent wedge resection of the pulmonary masses in the left upper and lower lobes.

## Discussion

Intracardiac thrombus, metastasis, myxoma, and primary malignant tumors such as angiosarcoma are the main differential diagnosis to be considered for cardiac tumors. Cardiac metastases are more common than primary cardiac tumors with a known incidence rate of 2.3%-18.3% [4-6]. Cardiac metastases are frequently seen in lung cancer, breast cancer,



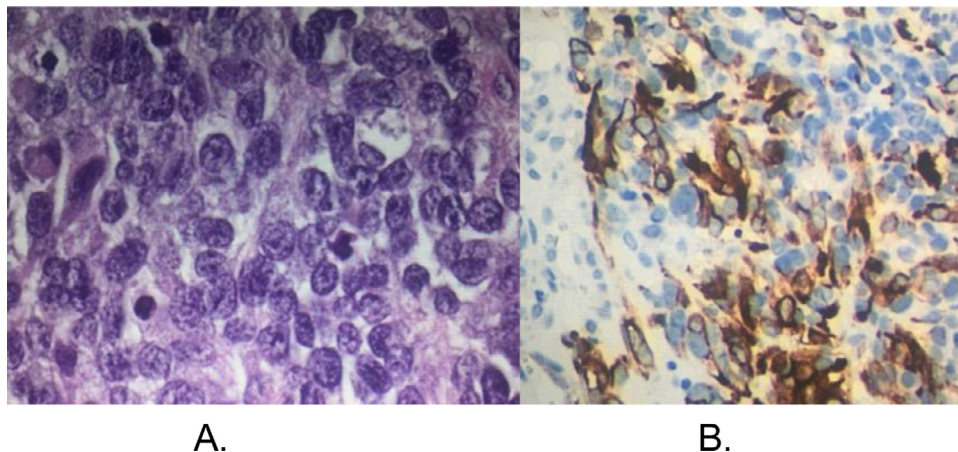
**Fig. 3 – (A) CMR dynamic perfusion series showing heterogenous enhancement of the right ventricular mass (blue arrow). (B) CMR Cine SSFP horizontal long axis (HLA) series showing mobile intracardiac mass in the right ventricle attached to the papillary muscle (yellow arrow).**



**Fig. 4 – Surgical specimen showing the 2 right ventricular masses were attached to the papillary muscle and tricuspid valve.**

malignant melanoma and lymphoma [7]. CMR is known to be invaluable in visualization and further characterization of these masses as well as evaluation of the cardiac involvement.

Rhabdomyosarcoma (RMS) is the most common type of sarcoma in children and young adults under 30 years of age [8]. The most common primary sites of RMS are the head and neck region, the genitourinary system and the extremities. An embryonal testicular RMS is rare and represents 7% of all testicular cancers. Testicular cancers usually metastasize to the paraaortic and mediastinal lymph nodes and cardiac involvement is very rare [2,3]. Right heart involvement is common than the left and this is attributed to spread of the tumor through inferior vena cava [9,10]. Metastases to the cardiac papillary muscle and tricuspid valve are yet to be described in the literature.



**Fig. 5 – Histopathologic specimen showing poorly differentiated embryonal rhabdomyosarcoma (A) with positive desmin stain (B).**

Heterogenous enhancement of a cardiac mass on first pass dynamic perfusion and delayed postcontrast series are helpful to differentiate a neoplasm from an intracardiac thrombus. Most thrombi are usually small, homogenous and immobile lesions without any contrast enhancement. Myxoma is the most common benign primary cardiac tumor and accounts 50% of the cardiac tumors [11]. It is usually seen a smooth, well-defined, pedunculated oval lesion that is hyperintense compared to normal myocardium and hypointense compared to the blood pool on CMR SSFP sequences. Cardiac lipoma is one of the intracardiac benign lesions that can easily be distinguished on CMR due to fat tissue signal characteristics. Cine SSFP and phase contrast images are also important in assessment of the cardiac wall motion abnormality and function of the heart valves.

---

## Conclusion

CMR provides a powerful tool for noninvasive morphological assessment of cardiac metastases and extension of the cardiac involvement. In our case, extremely rare papillary muscle and tricuspid valve involvement were demonstrated on CMR findings preoperatively. CMR findings will help and guide clinicians in treatment planning.

## REFERENCES

---

- [1] Fishman AD, Hoffman A, Volterra F, Frymus M, Gentilluci M. Intracaval and intracardiac metastatic nonseminomatous germ cell tumor: a rare cause of hemolytic anemia and thrombocytopenia. *Cancer Invest* 2002;20:996–1001.
- [2] Jonjev ZS, Rajić J, Majin M, Donat D. Intracardiac metastasis from germ cell testicular tumor. *Herz* 2012;37:709–11.
- [3] Bredael JJ, Vugrin D, Whitmore WF Jr. Autopsy findings in 154 patients with germ cell tumors of the testis. *Cancer* 1982;50:548–51.
- [4] Nakayama R, Yoneyama T, Takatani O, Kimura K. A study of metastatic tumors to the heart, pericardium and great vessels. *Jpn Heart J* 1966;7:227–34.
- [5] Abraham KP, Reddy V, Gattuso P. Neoplasms metastatic to the heart: review of 3314 consecutive autopsies. *Am J Cardiovasc Pathol* 1990;3:195–8.
- [6] Klatt EC, Heitz DR. Cardiac metastases. *Cancer* 1990;65:1456–9.
- [7] Stefka J, Cleveland JC, Lucia MS, Singh M. Sarcomatoid intracardiac metastasis of a testicular germ cell tumor closely resembling primary cardiac sarcoma. *Hum Pathol* 2003;34:1074–7.
- [8] Stewart LH, Lioe TF, Johnston SR. Thirty-year review of intrascrotal rhabdomyosarcoma. *Br J Urol* 1991;68:418–20.
- [9] Klatt EC, Heitz DR. Cardiac metastases. *Cancer* 1990;65:1456–9.
- [10] Taghavi F, Markar S, Williams M, Large S. Intra-cardiac metastasis from testicular non-seminoma germ cell tumour; to resect or not to resect. *Interact Cardiovasc Thorac Surg* 2010;11:843–5.
- [11] Motwani M, Kidambi A, Herzog BA, Uddin A, Greenwood JP, Plein S. MR imaging of cardiac tumors and masses: a review of methods and clinical applications. *Radiology* 2013;268:26–43. doi:10.1148/radiol.13121239.