

# A Teenage Girl With Painful Walking and a Left Foot Mass

Global Pediatric Health  
January-December 2015: 1-4  
© The Author(s) 2015  
DOI: 10.1177/2333794X15606840  
gph.sagepub.com



Shipra Gupta, MD<sup>1,2</sup>, Amrit Misra, MD<sup>1</sup>, Mahdi Alsaleem, MD<sup>1</sup>,  
and Nahed Abdel-Haq, MD<sup>1,2</sup>

## Case Report

A 12-year-old African American girl presented with a 1-year history of swelling and intermittent pain in her left foot. The swelling and pain had worsened over the past 3 weeks. She reported that prolonged walking increased the pain and swelling, while laying down led to some improvement. The patient and her mother denied trauma to the left foot. There was no history of fever, nausea, vomiting, abdominal pain, or shortness-of-breath. The rest of her review of systems was unremarkable. Her past medical history was significant for asthma, with no surgical history. The only medication she took was albuterol as needed, and she had no known medication allergies. Family history was significant for diabetes and bipolar disorder. On our physical examination, she was afebrile with stable vital signs. She had an approximately 3 × 3 × 3 cm well-circumscribed, non-tender, fluctuant mass at the dorsum of her left foot, located above the fourth and fifth metatarsals, with no overlying erythema. Her range-of-motion and strength were intact bilaterally. Laboratory work showed a white blood cell count of 7100/mm<sup>3</sup> (47% neutrophils, 42% lymphocytes, and 7% monocytes), hemoglobin 12.6 g/dL, hematocrit 37.0%, and platelets 279 000/mm<sup>3</sup>. C-reactive protein was 3.18 mg/L (normal <9.1), and erythrocyte sedimentation rate was 14 mm/h (normal 9-14). Her foot radiograph showed soft tissue swelling within the fourth and fifth intermetatarsal space, with lucencies in the diaphysis of the fourth and fifth metatarsals suggesting possible chronic osteomyelitis. Foot ultrasound showed soft tissue mass suggesting phlegmon and early abscess formation at the site of swelling. No foreign body was noted in either of the examinations. Foot magnetic resonance imaging (MRI) showed subacute/chronic osteomyelitis of the fourth and fifth metatarsals with a 3.3 × 2.4 × 3.7 cm mass consistent with inflammatory pseudotumor and a component of small abscess. There was also extensive cellulitis and myositis involving the dorsum of the midfoot and extending between the fourth and fifth metatarsals to the plantar musculature and fascia. Additionally, the MRI

showed a 2.7 cm linear foreign body in between the fourth and fifth metatarsals (Figures 1 and 2).

On further questioning, the patient recalled stepping on a toothpick approximately 1.5 years prior to her current presentation. Review of her previous medical records revealed that she had 2 previous emergency department (ED) visits as well. The first visit was shortly after she stepped on the toothpick but nothing could be felt or removed. She presented a second time to the ED 6 months prior to this presentation with swelling and pain in her foot. At that visit, bedside incision and drainage was attempted but unsuccessful. After each of these visits, patient's family was advised to follow-up in the surgery clinic for further evaluation but failed to do so.

## Hospital Course

She was initially treated with intravenous (IV) clindamycin to cover for anaerobic and gram-positive organisms including *Staphylococcus aureus*. Orthopedic Surgery was consulted and performed incision and drainage of the mass. During the debridement, the mass was noted to have separate neurovascular bundle. A toothpick fragment was removed and the mass was sent to pathology. Soft tissue sections showed abundant mixed inflammatory cells including lymphocytes, plasma cells, neutrophils, eosinophils, and histiocytes. The center of the lesion showed purulent necrosis and clusters of gram-positive beaded bacteria and sulfur granules suggestive of *Actinomyces* species. Acid-fast staining was negative. Tissue gram stain showed gram-positive beaded bacilli (Figure 3). Tissue culture grew *Actinomyces*; however, it could not be further speciated and no susceptibility testing could be performed, as the bacteria could not be subcultured. The anaerobic, fungal, and mycobacterial

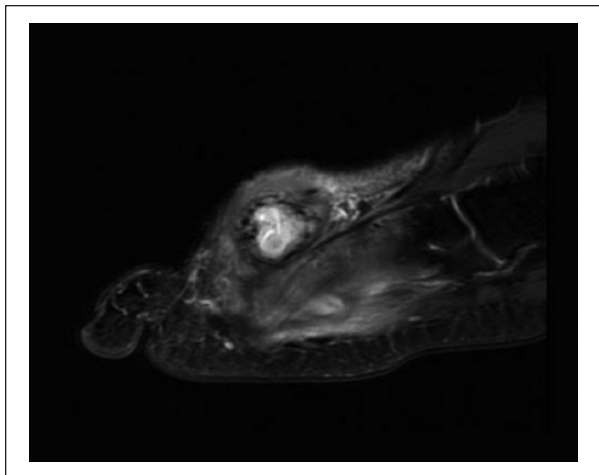
<sup>1</sup>Wayne State University, Detroit, MI, USA

<sup>2</sup>Children's Hospital of Michigan, Detroit, MI, USA

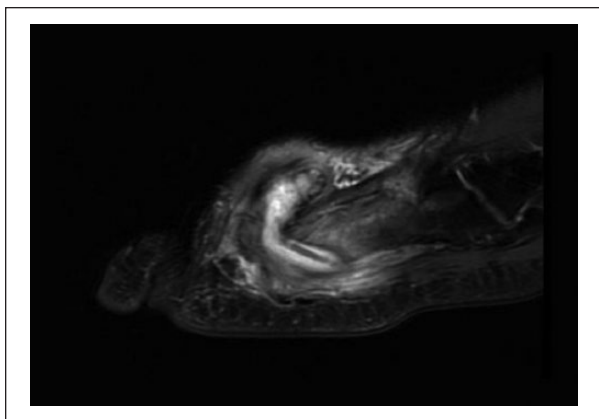
### Corresponding Author:

Nahed Abdel-Haq, Division of Infectious Diseases, Children's Hospital of Michigan, 3901 Beaubien Blvd, Detroit, MI 48201, USA.  
Email: nabdel@dmc.org

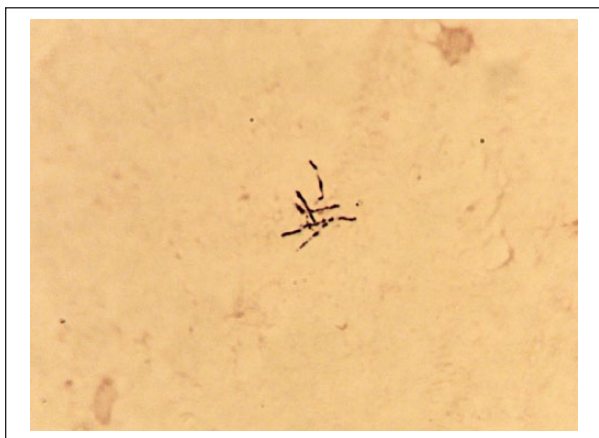




**Figure 1.** Sagittal view of the left foot MRI showing a 3.3 × 2.4 × 3.7 cm complex mass dorsal to the metatarsals.



**Figure 2.** Sagittal view of the left foot MRI showing a 2.7 cm linear foreign body between the fourth and fifth metatarsals with intense surrounding inflammatory response.



**Figure 3.** Gram stain showing gram-positive beaded bacilli.

cultures did not show any growth. She was discharged with instructions to complete a 6-week course of IV ampicillin-sulbactam, but shortly after initiation of IV therapy, she developed anaphylactic symptoms related to IV infusions. Antibiotic therapy was switched to IV meropenem, and she received that for 2 months. Patient then underwent desensitization to amoxicillin-clavulanate and completed a 6-month course of oral suppression therapy. There was complete resolution of foot swelling and tenderness.

### Final Diagnosis

Actinomycosis and osteomyelitis of the foot due to a retained toothpick

### Discussion

This is a unique case of a chronic, indolent mass following penetrating trauma and retained foreign body. Used toothpick injury can cause soft tissue infection with common oral flora and is often polymicrobial but the tissue culture in our patient grew *Actinomyces* only. Osteomyelitis of the foot following penetrating injuries with used toothpicks is most frequently caused by *Eikenella corrodens*<sup>1</sup>; only one case of osteomyelitis has been reported where both *Actinomyces odontolyticus* and *Eikenella corrodens* were isolated.<sup>2</sup>

*Actinomyces* species are part of the endogenous bacteria of the human gastrointestinal tract from the oropharynx to the bowel.<sup>3</sup> Actinomycosis occurs when the bacteria is introduced into tissues. Predisposing factors for actinomycosis include gingivitis, dental trauma or procedures, diabetes, malnutrition, immunosuppression and local tissue damage due to different causes such as trauma, radiation, or intrauterine devices.<sup>4,5</sup> Our patient developed actinomycosis due to bacterial inoculation into the soft tissues of the foot via the toothpick. Conditions that favor the proliferation of *Actinomyces* species in tissues include the duration and severity of trauma that induce microaerophilic environment as well as the synergistic effect of other bacteria.<sup>6</sup> *Actinomyces* species replicate and spread contiguously without respect for tissue planes. Patients may occasionally develop an acute inflammatory response with painful cellulitis following inoculation. However, most actinomycosis lesions progress in a slow and progressive manner to a chronic inflammatory stage characterized by formation of masses with hard walls due to extensive fibrosis.<sup>3</sup> The lack of laboratory evidence of inflammation, as demonstrated by normal white blood cell count, low C-reactive protein, and erythrocyte sedimentation rate reflects the insidious nature of actinomycotic lesions.

As the lesion matures it becomes fluctuant and may subsequently form sinus tracts. Once formed, sinus tracts tend to be chronic and have poor tendency to heal and may drain tiny yellow friable masses termed sulfur granules, which are indeed *Actinomyces* colonies mixed with neutrophils and debris. Actinomycosis is frequently polymicrobial and bacterial species such as *Eikenella corrodens*, *Fusobacterium*, *Staphylococcus*, and microaerophilic streptococci are often concomitantly isolated.<sup>3,7</sup>

Although cervicofacial bone involvement is the most common form of osteomyelitis due to *Actinomyces* species in adults and children, case reports and case series have been described of osteomyelitis involving other sites.<sup>8</sup> Bone and joint involvement may follow hematogenous spread of localized actinomycosis to distant sites.<sup>9</sup> However, most cases of *Actinomyces* osteomyelitis occur via contiguous spread of infection. Primary sternal osteomyelitis has also been reported in adults.<sup>10</sup> The most common site of osteomyelitis in children is the mandible; all had frequent recurrences of symptoms and all were diagnosed with chronic osteomyelitis.<sup>11</sup> Most patients with extrafacial bone actinomycosis have indolent clinical presentation and the clinical manifestations are similar to chronic osteomyelitis due to other bacterial causes. Involvement of the extremities may lead to mycetomas, which are localized, chronic, progressive, granulomatous, inflammatory, tumor-like lesions that may resemble tuberculosis, nocardiosis, fungal infections, or malignancies.<sup>12</sup>

Diagnosis is often made by isolation of *Actinomyces* from tissue or pus from normally sterile body sites. Clinical specimens should be preferably obtained prior to antimicrobial therapy as *Actinomyces* species are sensitive to antimicrobials. *Actinomyces* species require an anaerobic or microaerophilic environment to grow; thus, specimens should be sent to the laboratory in strict anaerobic conditions. Growth demonstrates gram-positive bacilli or branching filaments that are acid-fast stain negative. Microscopic examination of affected tissue may reveal yellow, "sulfur" granules that are considered characteristic but not pathognomonic of actinomycosis as they may also be seen in other infections such as nocardiosis or botryomycosis.<sup>13</sup> Of note, *Nocardia* may appear microscopically similar to *Actinomyces* and stains gram-positive. However, in contrast to *Actinomyces*, *Nocardia* is acid-fast stain positive or stains partially positive with stain. Molecular methods such as 16S rDNA sequencing have been used to identify *Actinomyces* in clinical specimens.<sup>14</sup>

Prolonged antibiotic therapy and surgery are the mainstay of actinomycosis treatment. Penicillin is considered the drug of choice. Treatment for actinomycosis consists of initial IV antibiotic therapy, such as IV penicillin G or ampicillin, for 2 to 6 weeks. This is followed by

a 6- to 12-month course of suppressive therapy with high-dose oral penicillin or amoxicillin.<sup>3</sup> Patients who are allergic to penicillin may be treated with clindamycin, erythromycin, or a tetracycline such as doxycycline or minocycline. Antibiotic susceptibility testing may help guide antibiotic therapy particularly in penicillin-allergic patients. Meropenem may be used during the parenteral phase of therapy in penicillin allergic patients as we treated our patient.<sup>15</sup> Antibiotics that are considered ineffective against *Actinomyces* species include oxacillin, cephalixin, ciprofloxacin, and metronidazole.

## Conclusion

Inflammatory granulomas caused by pathogens such as *Actinomyces*, *Nocardia*, and fungi can form indolent masses mimicking tumors. Patients may present with prolonged and nonspecific complaints. Actinomycosis should be considered in patients with chronic indolent foot swelling following toothpick injuries. Patients with chronic or recurrent foot swelling should get magnetic resonance imaging to evaluate for wooden foreign bodies including toothpicks as history of trauma may not be elicited.

## Author Contributions

Shipra Gupta: Substantially contributed to conception or design; drafted the manuscript; gave final approval; agrees to be accountable for all aspects of the work in ensuring that questions relating to the accuracy or integrity of any part of the work are appropriately investigated and resolved.

Amrit Misra: Substantially contributed to conception or design; contributed to acquisition, analysis, or interpretation of data; critically revised the manuscript for important intellectual content; gave final approval; and agrees to be accountable for all aspects of the work in ensuring that questions relating to the accuracy or integrity of any part of the work are appropriately investigated and resolved.

Mahdi Alsaleem: Contributed to acquisition, analysis, or interpretation of data; critically revised the manuscript for important intellectual content; gave final approval; and agrees to be accountable for all aspects of the work in ensuring that questions relating to the accuracy or integrity of any part of the work are appropriately investigated and resolved.

Nahed Abdel-Haq: Substantially contributed to conception or design; drafted the manuscript; critically revised the manuscript for important intellectual content; gave final approval; and agrees to be accountable for all aspects of the work in ensuring that questions relating to the accuracy or integrity of any part of the work are appropriately investigated and resolved.

## Declaration of Conflicting Interests

The author(s) declared no potential conflicts of interest with respect to the research, authorship, and/or publication of this article.

## Funding

The author(s) received no financial support for the research, authorship, and/or publication of this article.

## References

1. Robinson LG, Kourtis AP. Tale of a toothpick: *Eikenella corrodens* osteomyelitis. *Infection*. 2000;28:332-333.
2. Davanos E, Rahman SM, Nogid B. Treatment of *Eikenella corrodens* and *Actinomyces odontolyticus* foot abscess in a penicillin-allergic patient. *Ann Pharmacother*. 2008;42:1706-1710.
3. Smego RA Jr, Foglia G. Actinomycosis. *Clin Infect Dis*. 1998;26:1255-1261.
4. Miller M, Haddad AJ. Cervicofacial actinomycosis. *Oral Surg Oral Med Oral Pathol Oral Radiol Endod*. 1998;85:496-508.
5. Kayikcioglu F, Akif Akgul M, Haberal A, Faruk Demir O. Actinomyces infection in female genital tract. *Eur J Obstet Gynecol Reprod Biol*. 2005;118:77-80.
6. Nielsen PM, Novak A. Acute cervico-facial actinomycosis. *Int J Oral Maxillofac Surg*. 1987;16:440-444.
7. Bennhoff DF. Actinomycosis: diagnostic and therapeutic considerations and a review of 32 cases. *Laryngoscope*. 1984;94:1198-1217.
8. Valour F, Senechal A, Dupieux C, et al. Actinomycosis: etiology, clinical features, diagnosis, treatment, and management. *Infect Drug Resist*. 2014;7:183-197.
9. Brown ML, Drinkwater CJ. Hematogenous infection of total hip arthroplasty with *Actinomyces* following a noninvasive dental procedure. *Orthopedics*. 2012;35:e1086-e1089.
10. Pinilla I, Martin-Hervas C, Gil-Garay E. Primary sternal osteomyelitis caused by *Actinomyces israelii*. *South Med J*. 2006;99:96-97.
11. Robinson JL, Vaudry WL, Dobrovolsky W. Actinomycosis presenting as osteomyelitis in the pediatric population. *Pediatr Infect Dis J*. 2005;24:365-369.
12. Bonifaz A, Ibarra G, Saul A, Paredes-Solis V, Carrasco-Gerard E, Fierro-Arias L. Mycetoma in children: experience with 15 cases. *Pediatr Infect Dis J*. 2007;26:50-52.
13. de Montpreville VT, Nashashibi N, Dulmet EM. Actinomycosis and other bronchopulmonary infections with bacterial granules. *Ann Diagn Pathol*. 1999;3:67-74.
14. Hall V, Talbot PR, Stubbs SL, Duerden BI. Identification of clinical isolates of actinomyces species by amplified 16S ribosomal DNA restriction analysis. *J Clin Microbiol*. 2001;39:3555-3562.
15. Smith AJ, Hall V, Thakker B, Gemmell CG. Antimicrobial susceptibility testing of *Actinomyces* species with 12 antimicrobial agents. *J Antimicrob Chemother*. 2005;56:407-409.