

## An Isolated True Aneurysm of the Superficial Femoral Artery in a Young Woman

— A case report —

Seokkee Lee, M.D.\*, Shin Kwang Kang, M.D.\*, Hyun Kong Oh, M.D.\*, Min-Woong Kang, M.D., Ph.D.\*, Jae Hyeon Yu, M.D., Ph.D.\*, Myung Hoon Na, M.D., Ph.D.\*, Seung Pyung Lim, M.D., Ph.D.\*

A 39-year-old woman was admitted to the hospital due to a pulsatile mass on her right inner thigh that was evident for two months. She did not exhibit any risk factors of atherosclerosis, no evidence of vasculitis, or any signs of previous trauma history. Ultrasound and computed tomography revealed an adult fist-sized aneurysm on the distal superficial femoral artery. The aneurysm was resected and peripheral circulation was restored with the interposition of a saphenous vein graft. The resected aneurysm had three layers that showed atherosclerosis on histological examination.

Key words: 1. Aneurysm  
2. Saphenous vein  
3. Arteries

### CASE REPORT

A 39-year-old woman was admitted to our hospital due to the presence of a pulsatile mass on her right inner thigh. The patient complained of tightness with distension at the inner surface of her right thigh, which was developed 2 months ago and increased in size. She had no definite history of trauma on the right lower leg, diabetes mellitus, nor hypertension, and did not smoke. On admission, her arterial pressure was 120/80 mmHg and blood analysis was within the normal range. Peripheral pulsations could be palpated well at the dorsalis pedis artery and the posterior tibial artery. Ultrasound and CT (Computed tomography) showed an isolated saccular aneurysm with thrombus and calcification

measuring 6×8 cm on the right distal SFA (Superficial femoral artery). The proximal and distal walls of the aneurysm looked normal and the distal flow was preserved. The ascending aorta, aortic arch, abdominal aorta, and other major branches of the aorta were not dilated nor thickened in the CT scan (Fig. 1A). An operation was performed under general anesthesia. A medial longitudinal incision was made over the pulsatile mass closer to the great saphenous vein (GSV) above the knee. After harvesting the GSV, we entered the deep fascia and dissected the aneurysm carefully. After controlling the vessels proximal and distal to the aneurysm, the aneurysm was resected and the GSV was continuously interposed with 6-0 Prolene (Fig. 2). The wall of the aneurysm was thickened and calcified, and exhibited three layers upon

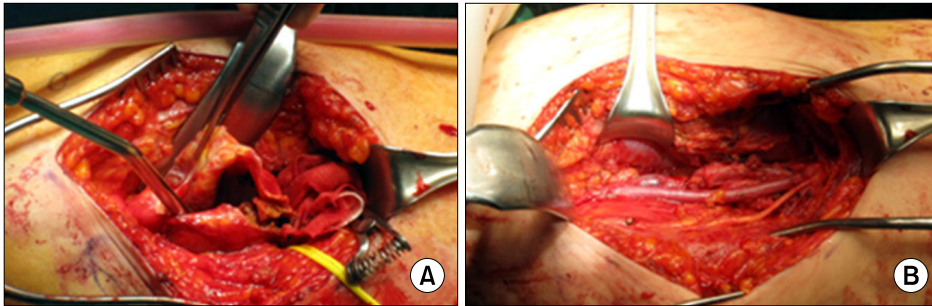
\*Department of Thoracic and Cardiovascular Surgery, Chungnam National University Hospital, College of Medicine, Chungnam National University

Received: April 11, 2011, Revised: May 9, 2011, Accepted: June 3, 2011

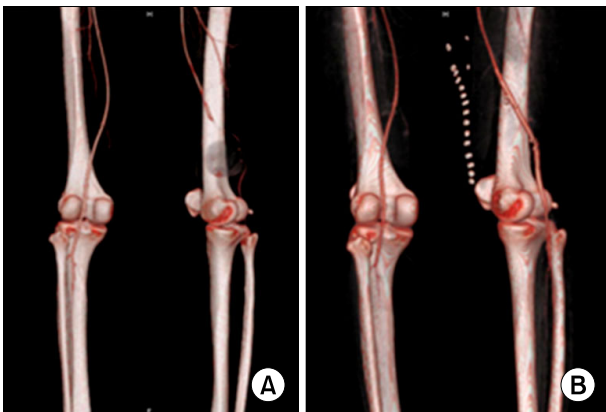
Corresponding author: Shin Kwang Kang, Department of Thoracic and Cardiovascular Surgery, Chungnam National University Hospital, College of Medicine, Chungnam National University, 282, Munhwa-ro, Jung-gu, Daejeon 301-721, Korea  
(Tel) 82-42-280-8379 (Fax) 82-42-280-7373 (E-mail) [cskkwang@cnuh.co.kr](mailto:cskkwang@cnuh.co.kr)

© The Korean Society for Thoracic and Cardiovascular Surgery. 2011. All right reserved.

© This is an open access article distributed under the terms of the Creative Commons Attribution Non-Commercial License (<http://creativecommons.org/licenses/by-nc/3.0>) which permits unrestricted non-commercial use, distribution, and reproduction in any medium, provided the original work is properly cited.



**Fig. 2.** These photographs show the calcified aneurysm of the SFA (A) and the bypassed graft (B).

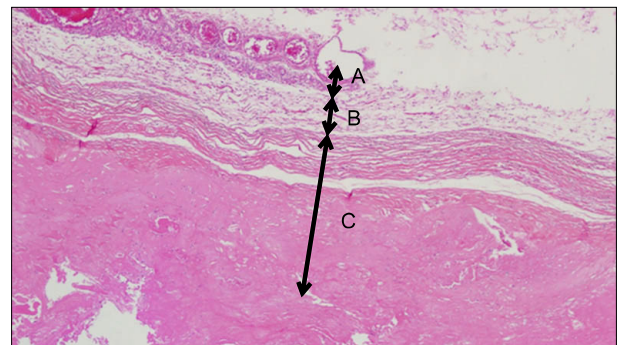


**Fig. 1.** Computed tomography showing the sacular aneurysm, measuring 6×7 cm, of the right distal SFA (A) and the vein graft bypassed postoperatively (B).

histological examination (Fig. 3). The patient had recovered uneventfully, and was discharged on the seventh day post-operatively with administration of antiplatelet agents (aspirin 100 mg and clopidogrel 75 mg daily) and a lipid-lowering agent (atorvastatin 5 mg daily). The postoperative CT showed that the aneurysm was completely resected and the graft was patent (Fig. 1B). The patency of the graft at 12 months follow-up was satisfactory.

## DISCUSSION

Isolated true aneurysms located in the SFA have rarely been reported. The etiology of true aneurysms of the SFA are atherosclerosis, mycotic infection, non-infectious autoimmune or inflammatory arteritis, and connective tissue disorders [1]. SFA aneurysms in advanced age patients with coronary, cerebral, or peripheral artery disease, and other risk factors of atherosclerosis are generally found to be athero-



**Fig. 3.** This photograph shows the resected aneurysm containing three layers of the artery (A=Adventitia; B=Muscular; C=Intima; H-E stain, ×40).

sclerotic in origin. On the other hand, SFA aneurysms that are presented together with aneurysms in the aortic arch, the abdominal aorta, the common femoral artery, the popliteal artery, or aneurysms occurring bilaterally should be suspected to be the result of systemic vascular diseases [1,2].

In 1972, Hardy and Eadie first reported an SFA aneurysm in a 70-year-old man [2]. Many studies of institutional experiences have been reported, but only a few cases have been reported of isolated true aneurysms in the SFA. In addition, these were almost always found in very elderly men [1]. The patient in the current case was a young woman without any evidence of systemic disease.

The natural history of untreated SFA aneurysms has not been clearly demonstrated. Studies of aneurysms of the SFA have shown a rupture rate of 35% to 48%, a thrombosis rate of 13% to 18%, an embolism rate of 9% to 12%, and limb salvage in 94% of cases [3,4].

The SFA is located in the deep structures of the thigh, and is not easily detected until the size is large enough for palpation or the symptoms are apparent. An acute increase in

size, ecchymosis in the thigh, and/or sudden hypotension with a fall of the hematocrit suggests leakage and rupture of the aneurysm [1].

Ultrasound is a noninvasive first line of investigation for aneurysms. CT is an accurate and effective diagnostic tool for defining the size, configuration, internal nature of the aneurysm, and the condition of adjacent vessels other than the SFA. Because of the high incidence of associated vascular problems among elderly patients, CT scans should cover the whole aorta and its major branches as well [4].

Despite there being insufficient data on the indication for surgical intervention, aneurysms of the SFA greater than 2.5 cm should be repaired surgically [1,3]. Endovascular repair is currently an alternative technique [5]. Operative approaches should take into account the general conditions of the patient, the presence of complications, and the size and configuration of the aneurysm or aneurysms. Many methods, such as excision, ligation, endo-aneurysmorrhaphy, and bypass grafting with autologous vein or prosthesis, can be applied on a case-by-case basis [1,5]. When below-knee reconstruction is

necessary, autologous vein grafting is preferable in some surgeries. Controlling the condition of the patients and life-long surveillance are mandatory for patients with aneurysms of the SFA.

## REFERENCES

1. Dimakakos PB, Tsiligiris V, Kotsis T, Papadimitriou JD. *Atherosclerotic aneurysms of the superficial femoral artery: report of two ruptured cases and review of the literature.* Vasc Med 1998;3:275-9. Review.
2. Hardy DF, Eadie DGA. *Femoral aneurysms.* Br J Surg 1972;59:614-16.
3. Attalah C, Hassan HK, Negleu P. *Superficial femoral artery aneurysm—an uncommon site of aneurysm formation.* Eur J Vasc Endovasc Surg 1995;10:502-4.
4. Criado E, Marston WA, Ligush J, Mauro MA, Keagy BA. *Endovascular repair of peripheral aneurysms, pseudoaneurysms and arteriovenous fistulas.* Ann Vasc Surg 1997;11:256-63.
5. Jarrett F, Makaroun MS, Rhee RY, Bertges DJ. *Superficial femoral artery aneurysms: an unusual entity?* J Vasc Surg 2002;36:571-4.