



¹⁸F-Fluorocholine uptake matching CT lesions in the lungs of a patient clinically cured from COVID-19 syndrome

Léa Turpin¹ · Quentin Pouliot¹ · Jules Zhang¹ · Martine Glikman² · Florie Gomez³ · Jean-Noël Talbot¹ · Françoise Montravers¹

Received: 15 April 2020 / Accepted: 7 June 2020 / Published online: 19 June 2020
© Springer-Verlag GmbH Germany, part of Springer Nature 2020

A 76-year-old man was referred to ¹⁸F-fluorocholine (FCH) PET/CT for biochemical recurrence of prostate cancer (BRPC) after prostatectomy in 2004 (initial TNM: pT2bN0). Prostate-specific antigen (PSA) serum levels had been slowly rising (from 0.1 ng/mL in 2015 to 0.31 ng/mL in 2020).

This patient presented with fever and cough 1 month before, considered as highly consistent with a COVID-19 infection by his general practitioner [1] and a positive antibody testing confirmed the infection (immunoglobulin G = 7.67, positive if > 1.4).

At the time of FCH PET-CT, he has been asymptomatic for over 1 week, and still is 2 months later.

One hour after intravenous injection of 210 MBq of FCH, no focus evocative of BRPC was found. However, bilateral pulmonary foci were discovered (SUVmax 3.9). On CT, they matched ground-glass opacities and multifocal patchy consolidative opacities involving approximately 30% of the lungs, predominating in the peripheral inferior and posterior regions: typical CT features of COVID-19 infection [1–3]. Bilateral mediastinum lymph nodes also took up FCH

(SUVmax 3.8). All these lesions were not visible on a previous FCH PET-CT performed in 2018.

COVID-19-induced lung lesions may take up ¹⁸F-fluorodeoxyglucose [4, 5] and ¹⁸F-fluorocholine as in this case. FCH was already known to reveal inflammatory conditions [6–8]. FCH uptake by mediastinum lymph nodes is frequent but this usual pattern differs from the present images.

The significance of those metabolically active lesions in a patient who clinically recovered from a COVID-19 infection is unknown: healing with a risk of lung fibrosis or subacute evolution with a risk of recurrence which did not occur within 2 months and of contamination? Male sex is associated with prolonged SARS-CoV-2 RNA shedding [9]; thus, other cases of COVID-19 imaging patterns are likely to be discovered on FCH PET/CT in the future.

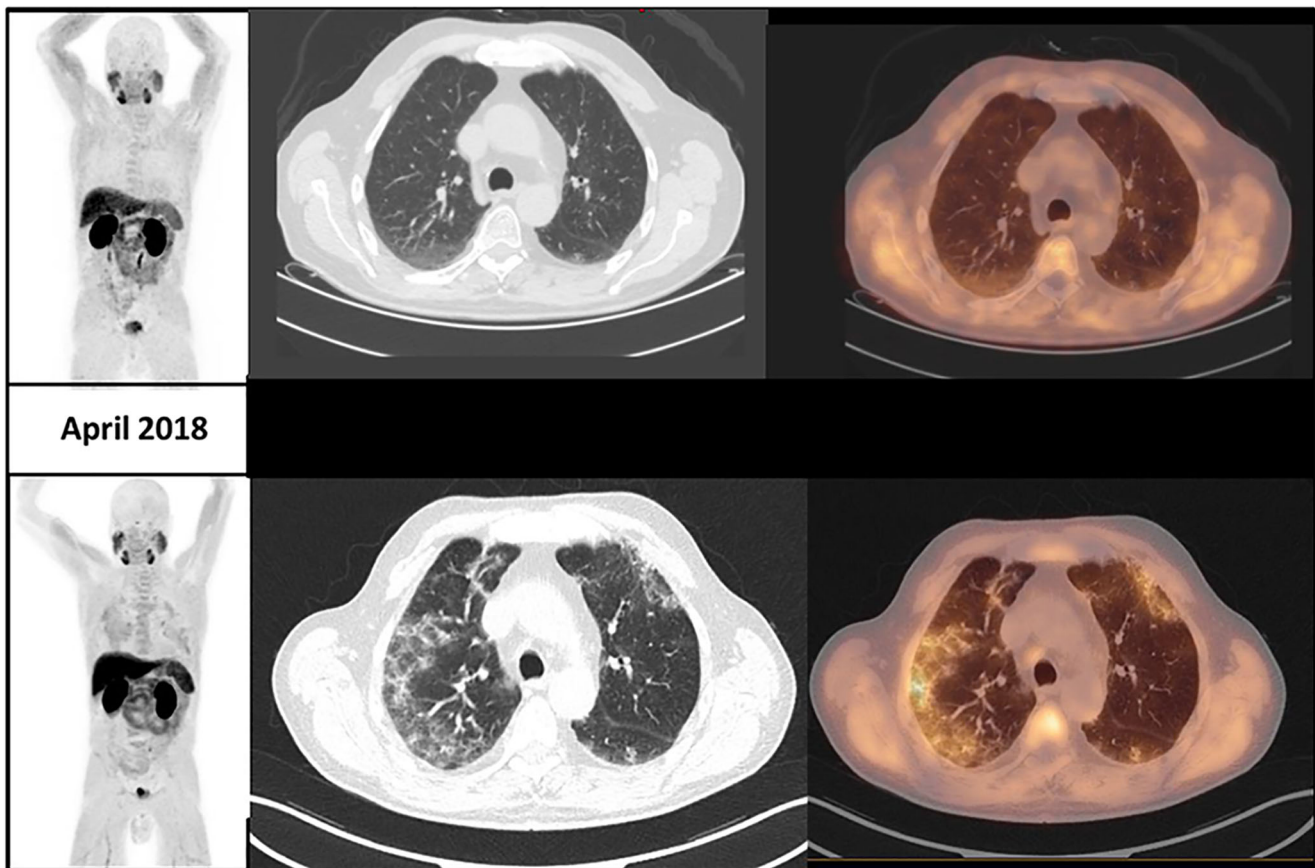
This article is part of the Topical Collection on Image of the month

✉ Léa Turpin
lea.turpin@aphp.fr

¹ Service de Médecine Nucléaire, Hôpital Tenon, AP-HP, et Sorbonne Université, Paris, France

² Cabinet de consultation de médecine générale, Pantin, France

³ Service d'urologie, Hôpital Tenon, AP-HP, et Sorbonne Université, Paris, France



April 2020

Availability of data and material Whole-body anonymized images of both PET are available for review.

Compliance with ethical standards

Conflict of interest The authors declare that they have no conflict of interest.

Ethics approval Written consent was signed by the patient for publication of his images for teaching/research purposes.

Consent to participate See above.

Consent for publication See above.

Code availability PACS of hospital Tenon

References

- Xu X, Yu C, Qu J, Zhang L, Jiang S, Huang D, et al. Imaging and clinical features of patients with 2019 novel coronavirus SARS-CoV-2. *Eur J Nucl Med Mol Imaging*. 2020;47(5):1275–80.
- Ai T, Yang Z, Hou H, Zhan C, Chen C, Lv W, et al. Correlation of chest CT and RT-PCR testing in coronavirus disease 2019 (COVID-19) in China: a report of 1014 cases. *Radiology*. 2020;200642.
- Bernheim A, Mei X, Huang M, Yang Y, Fayad ZA, Zhang N, et al. Chest CT findings in coronavirus disease-19 (COVID-19): relationship to duration of infection. *Radiology*. 2020;200463.
- Qin C, Liu F, Yen TC, Lan X. 18F-FDG PET/CT findings of COVID-19: a series of four highly suspected cases. *Eur J Nucl Med Mol Imaging*. 2020;47(5):1281–6.
- Albano D, Bertagna F, Bertolia M, Bosio G, Lucchini S, Motta F, et al. Incidental findings suggestive of covid-19 in asymptomatic patients undergoing nuclear medicine procedures in a high prevalence region. *J Nucl Med*. 2020;jnumed.120.246256. <https://doi.org/10.2967/jnumed.120.246256>.
- Wyss MT, Weber B, Honer M, Späth N, Ametamey SM, Westera G, et al. 18F-choline in experimental soft tissue infection assessed with autoradiography and high-resolution PET. *Eur J Nucl Med Mol Imaging*. 2004;31(3):312–6.
- Sarda-Mantel L, Alsac JM, Boisgard R, Hervatin F, Montravers F, Tavitian B, et al. Comparison of 18F-fluoro-deoxy-glucose, 18F-fluoro-methyl-choline, and 18F-DPA714 for positron-emission tomography imaging of leukocyte accumulation in the aortic wall of experimental abdominal aneurysms. *J Vasc Surg*. 2012;56(3):765–73.
- Kwee SA, DeGrado TR, Talbot JN, Gutman F, Coel MN. Cancer imaging with fluorine-18-labeled choline derivatives. *Semin Nucl Med*. 2007;37(6):420–8.

9. Xu K, Chen Y, Yuan J, Yi P, Ding C, Wu W, et al. Factors associated with prolonged viral RNA shedding in patients with COVID-19. *Clin Infect Dis*. 2020:ciaa351. <https://doi.org/10.1093/cid/ciaa351>.

Publisher's note Springer Nature remains neutral with regard to jurisdictional claims in published maps and institutional affiliations.