

Arthroscopic Iliac Crest Bone Graft Augmentation Using All-Suture Anchors for Shoulder Instability Caused by Glenoid Bone Loss



Tony Antonios, B.Sc., M.B.B.S., M.Sc., F.R.C.S.(Tr&Orth),
Magnus Arnander, B.Sc., M.Sc., M.B.B.S., F.R.C.S.(Tr&Orth),
Eyiemi Pearse, M.A.(Oxon), F.R.C.S.(Orth), and
Thomas Duncan Tennent, M.B.B.S., F.R.C.S.(Orth), M.Acad.Med.Ed.

Abstract: Augmentation of the anterior glenoid with bone graft is an established treatment for recurrent anterior instability due to critical glenoid bone loss. Both open and arthroscopic techniques have been described. Fixation with metal screws through an open approach is the most common technique, but the risk of metal screw-related complications remains a concern. A variety of arthroscopic techniques using suspensory fixation or suture anchors have been described in the literature. However, they all require a posterior incision to insert a targeting device or to manage sutures. We describe a technique for arthroscopic bone grafting of the anterior glenoid via a purely anterior approach with 2 linked knotless suture anchors, thereby avoiding posterior suture management and glenoid metalwork complications.

Glenoid bone loss is a major factor in recurrent shoulder dislocation.¹ Subsequently, open or arthroscopic soft-tissue repair alone is often not sufficient, and it is associated with a high risk of failure.¹ The historic literature supports anterior glenoid bone augmentation procedures if bone loss is above 25%.² However, this threshold has more recently been reduced to 15%.³

The Latarjet procedure, involving a coracoid transfer with the attached conjoint tendon, is the most commonly used technique.³ Despite this, there are several concerns with the technique: It is a nonanatomic reconstruction, the graft does not have

articular cartilage, patients can lose active internal rotation strength owing to the violation of the subscapularis, and scapular dyskinesia develops in some patients.^{3,4}

A number of alternative graft solutions have been described, including iliac crest bone graft (ICBG), distal clavicle and distal tibial fresh frozen allograft.^{3,5,6} Graft fixation is most commonly achieved with metal screws. These can be associated with significant complications such as prominence of the screw head leading to erosion of the humeral head, screw migration or breakage, and intraoperative fracture of the graft.⁷⁻⁹ Graft osteolysis is a recognized problem and can increase the likelihood of some of these complications.⁹

Arthroscopic modifications of Latarjet and ICBG procedures are well documented.^{10,11} In general, arthroscopy allows the assessment and management of coexisting shoulder pathologies and, being minimally invasive, it can allow easier rehabilitation, earlier return to work, and better cosmesis than equivalent open procedures.¹⁰ The arthroscopic Latarjet procedure is technically challenging and has a steep learning curve. As such, simpler options have been advocated, such as the arthroscopic placement of free grafts.¹⁰

Some arthroscopic techniques use metal screws, but the use of alternative means, such as suspensory suture

From the Department of Trauma and Orthopaedics, St. George's University Hospitals NHS Foundation Trust, London, England.

The authors report the following potential conflicts of interest or sources of funding: T.D.T. receives royalties for devices and techniques from Arthrex, outside the submitted work. Full ICMJE author disclosure forms are available for this article online, as [supplementary material](#).

Received June 1, 2021; accepted August 8, 2021.

Address correspondence to Tony Antonios, B.Sc., M.B.B.S., M.Sc., F.R.C.S.(Tr&Orth), Department of Trauma and Orthopaedics, St. George's University Hospitals NHS Foundation Trust, Blackshaw Road, London SW17 0QT, England. E-mail: tantonios@doctors.org.uk

© 2021 by the Arthroscopy Association of North America. Published by Elsevier. This is an open access article under the CC BY-NC-ND license (<http://creativecommons.org/licenses/by-nc-nd/4.0/>).

2212-6287/21824

<https://doi.org/10.1016/j.eats.2021.08.014>

button fixation, suture anchors, suture tape cerclage, and bioabsorbable screws, has been described in the literature.^{6,11-17} These alternatives avoid the complications associated with metal screws; however, they all require both anterior and posterior approaches, and the posterior approach is used for the insertion of instruments, transglenoid drilling, suture management, and knot tying.^{6,11-17}

In this article, we describe an arthroscopic graft fixation technique using knotless all-suture anchors via a purely anterior approach without the need for posterior suture management. The aim is to restore shoulder stability through anatomic reconstruction of anterior glenoid defects through the precise placement and fixation of the graft. Furthermore, the fixation technique allows strong durable graft compression while avoiding all the complications associated with metal screws.

Surgical Technique

Indications and Preoperative Preparation

This surgical technique is indicated for patients with recurrent shoulder dislocation with anterior glenoid bone loss of at least 15%. All patients undergo 3-dimensional computed tomography with digital subtraction of the humeral head and comparison with the contralateral glenoid to determine the degree of glenoid bone loss.

Patient Positioning

Standard general anesthesia supplemented with an interscalene block and intravenous antibiotics is administered. The surgical procedure is performed with the patient in the beach-chair position. Examination under anesthesia is carried out to confirm the direction and degree of instability. Standard routine preparation and draping of the shoulder are carried out.

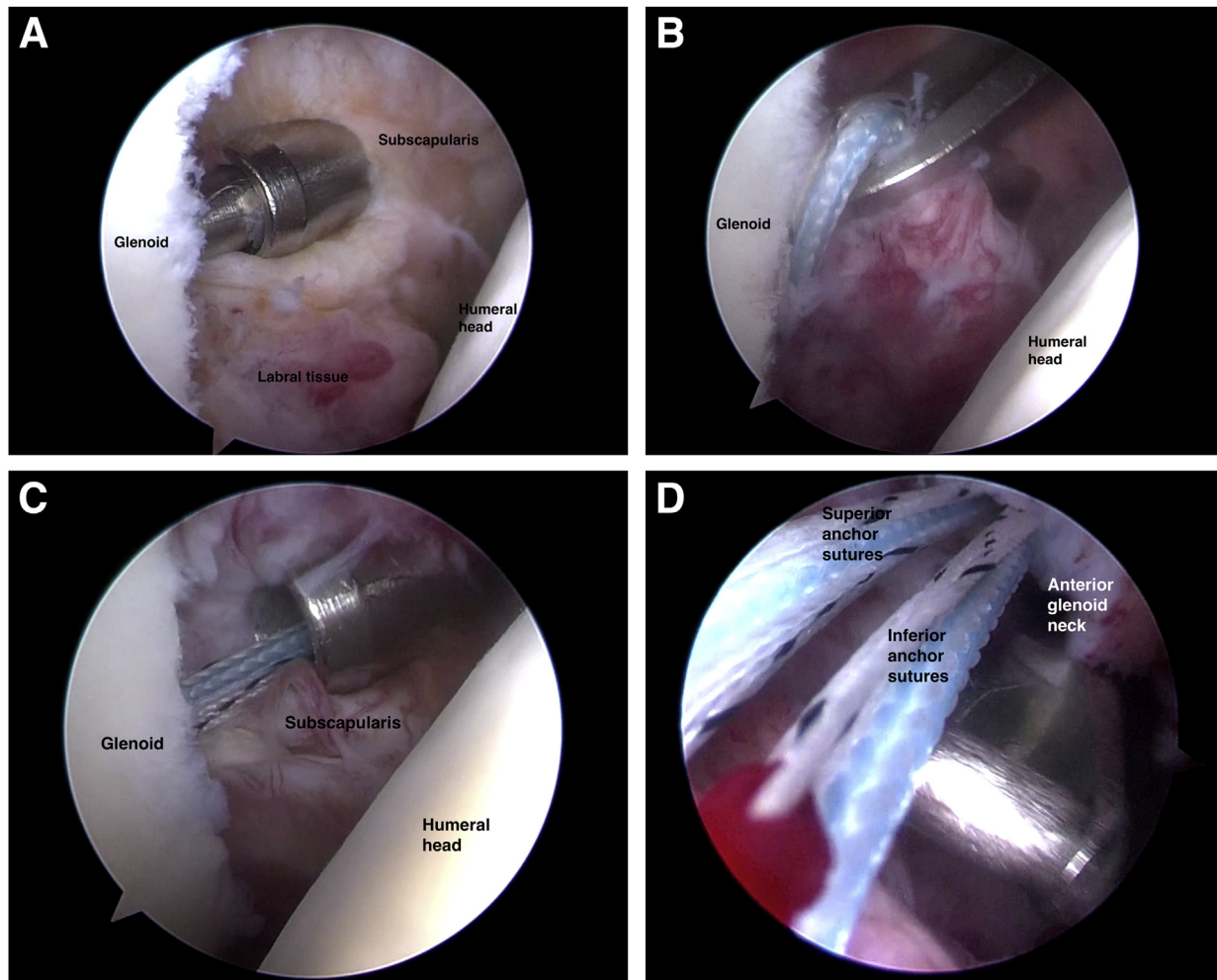


Fig 1. Key arthroscopic steps of graft augmentation for glenoid bone loss using all-suture anchor fixation technique. (A) Percutaneous superior anchor insertion through subscapularis. (B) Retrieval of sutures through superior accessory portal. (C) Insertion of inferior anchor. (D) Retrieval of all sutures through rotator interval. (E) Parachuting of bone graft down sutures. (F) Supplementary knot tying. (G) Inferior labral anchor. (H) Superior labral anchor.

Shoulder Arthroscopy and Glenoid Preparation

Video 1 illustrates the process in a stepwise manner, and Fig 1 illustrates the key arthroscopic steps for the procedure. By use of the posterior viewing portal, a diagnostic arthroscopy is carried out to confirm the diagnosis. An anterior working portal is established in the rotator interval. The anterior labrum is elevated to expose the glenoid neck and subscapularis. The glenoid neck is then prepared to a flat bleeding surface with a Power Rasp (Arthrex, Naples, FL). The adequacy of glenoid surface preparation is confirmed by viewing from the anterior portal.

A freeze-dried iliac crest bone allograft¹⁸ is cut and contoured to the shape of the anterior glenoid using an oscillating saw. By use of a 2.6-mm FiberTak drill (Arthrex), 2 drill holes directed toward the cut cancellous surface are made in the graft with a minimum bridge of 5 mm between them.

Anterior Glenoid Anchor Positioning

By use of Arthrex Percutaneous SutureTak instrumentation, a 19-gauge spinal needle is passed through the subscapularis to determine the optimum entry point and the direction for the anchors. A wire is railroaded through the spinal needle and the instrumentation used to dilate up the tract to create a trans-subscapularis portal. A 6-mm reusable crystal cannula obturator (Arthrex) is passed over the dilator to be used as a drill guide. The 2.6-mm FiberTak drill is passed from the neck of the glenoid to the posterior cortex, parallel to and approximately 5 mm below the chondral surface. The drill guide is kept in situ, and a 2.6-mm Knotless FiberTak anchor (Arthrex) is passed through to engage in the far cortex.

The position and adequacy of anchor deployment can be checked by viewing from the anterior portal. With the drill guide being kept in the joint, the sutures are

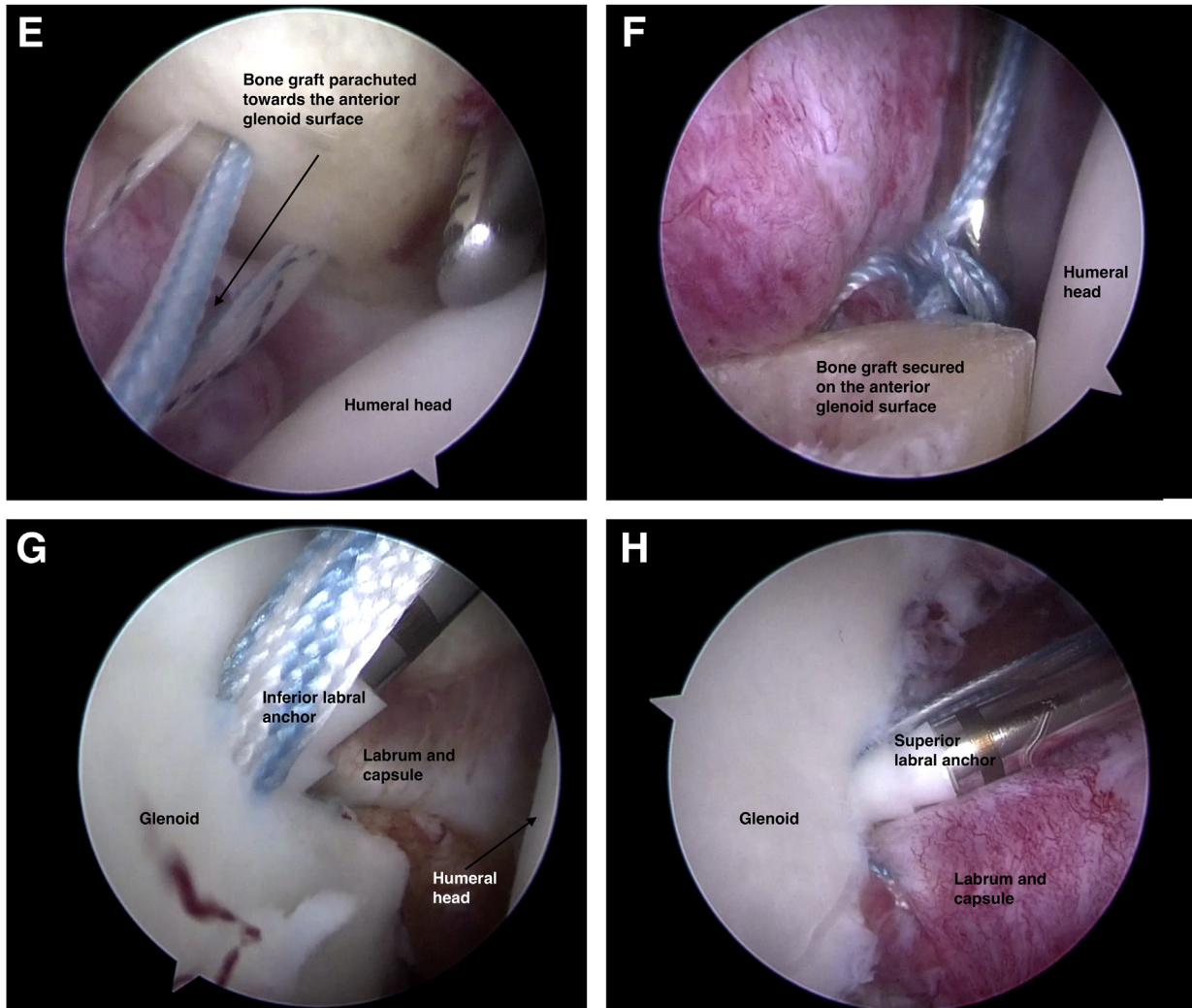


Fig 1. (continued).

retrieved through a superior accessory portal in the rotator interval. The drill guide is then repositioned, and the process is repeated to place a second anchor in the inferior glenoid neck. Again, the suture limbs are retrieved through the superior accessory portal.

The anterior portal is enlarged in preparation for graft passage. The sutures from both anchors are retrieved together through this portal. Care should be taken to ensure that each set of sutures remains separate and no soft-tissue bridges are formed.

Graft Passage and Stabilization

The superior sutures are passed through the superior drill hole in the graft, and the inferior sutures are passed through the inferior drill hole (Fig 2). The free end of the white-blue repair suture of the superior anchor is fed through the loop of the white-black shuttle suture of the inferior anchor. The free end of the inferior white-black shuttle suture is then pulled to shuttle the white-blue repair suture into the inferior knotless anchor mechanism, but they are not tightened completely until the second repair suture is shuttled.

The process is repeated with the white-blue repair suture of the inferior anchor and the loop of the white-black shuttle suture of the superior anchor. Care should be taken to ensure that all sutures remain separate and the process is carried out as close to the patient's body as possible to ensure that an adequate length of the suture is maintained between the anchors and the graft (Fig 3).

The graft is introduced into the shoulder by "parachuting" it down the suture limbs until it is flush with the glenoid neck. The white-blue repair sutures are tensioned sequentially, securing the graft onto the anterior glenoid neck (Fig 4). A knot pusher placed down the suture and pushing against the graft can be used to increase the tension. The tails of the 2 repair sutures can then be tied together for added security. Any overhanging portions of the graft can be removed with the Power Rasp.

Labral Repair

The labrum and capsule are repaired to the glenoid face over the graft using 2.9-mm PushLock anchors (Arthrex) at the 5-, 3-, and 2-o'clock positions.

Rehabilitation Protocol

Postoperatively, the shoulder is immobilized in a sling for 3 weeks. For the subsequent 3 weeks, range of motion is restricted to neutral external rotation and 90° of forward flexion. Full active shoulder movement is commenced after 6 weeks. Contact sports are started 6 months after surgery.

Discussion

Over the past decade, arthroscopic techniques have evolved and gained popularity. The arthroscopic Latarjet procedure was initially enthusiastically received.¹⁹ Because of the steep learning curve and associated complications, its popularity has waned. Its decline has prompted interest in alternative grafts, and

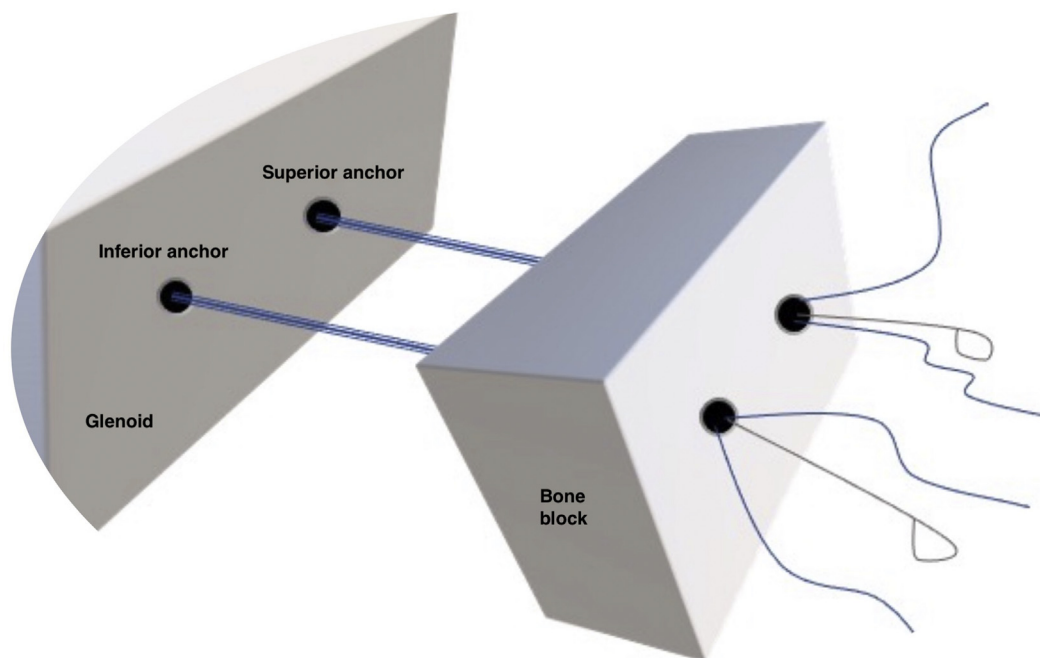


Fig 2. The superior and inferior anchors in the glenoid are shown, with their sutures passed through the drill holes in the graft.

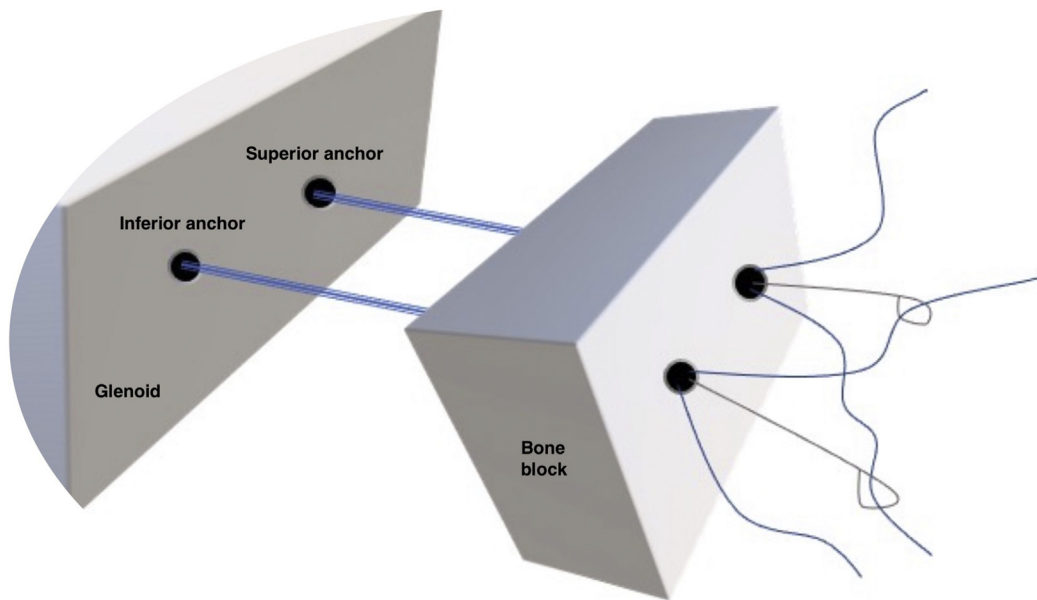


Fig 3. The repair suture of each anchor is passed through the shuttle suture of the other anchor.

likewise, complications associated with metal screws have generated interest in alternative fixation techniques.

The popularity of iliac crest autograft has increased. A recent randomized controlled trial comparing open Latarjet versus open ICBG procedures showed similar successful long-term outcomes.³ Similar to the coracoid, the ICBG has no chondral surface and harvest-site morbidity remains an issue, albeit uncommon. Fresh frozen allografts, such as distal tibial plafond graft,

which has the advantage of having articular cartilage, have been used, but compared with autograft, the cost remains very high and the bone incorporation rate is lower.⁶ Freeze-dried allografts are an option; although they can be brittle, they cost significantly less than fresh allografts.

For graft fixation, 2 metal screws have been used traditionally but have a reported complication rate of 6.5%, with a high rate of revision surgery.⁷ Other fixation methods have been developed to address these

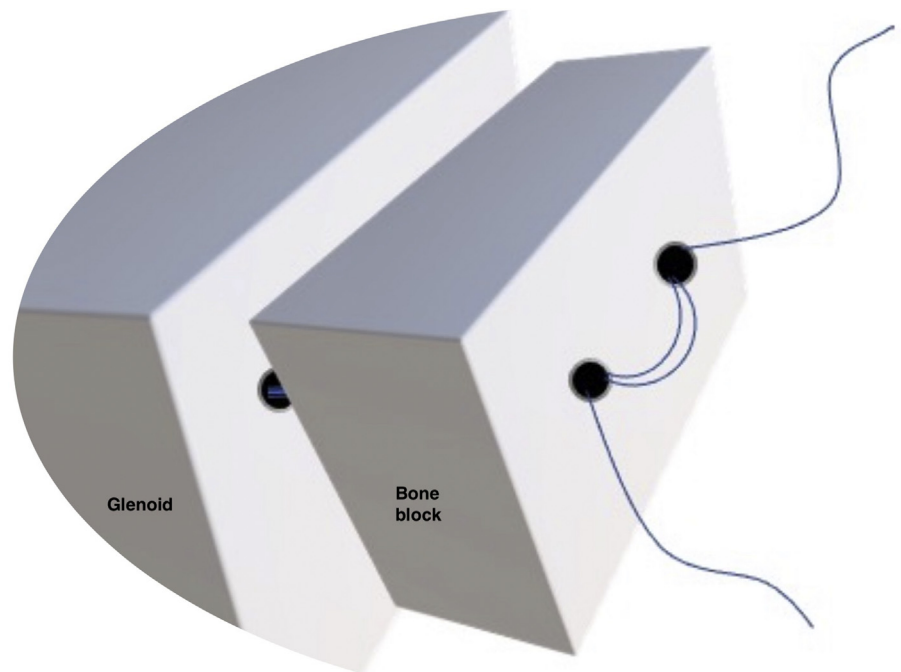


Fig 4. Reduction of the graft into the glenoid bed after suture tensioning.

Table 1. Summary of Advantages, Disadvantage, and Pearls of All-Suture Anchor Technique for Shoulder Instability

Advantages
Easy application of FiberTak suture anchor directly through subscapularis with minimal violation of tendon (only drill bit and sleeve through muscle fibers)
Solid fixation and tightening on graft directly
2 Points of fixation of graft to anterior glenoid, ensuring rotational stability
All-anterior approach, removing need for complex jigs and posterior-anterior glenoid drilling
Avoidance of all complications associated with metalwork
Disadvantages
Possible morbidity associated with autograft and allograft
Learning curve associated with arthroscopy
Drilling for PushLock anchors used to fix labrum could interfere with knotless anchor mechanism
Pearls
Ensure good exposure, allowing adequate anterior glenoid bone preparation of a flat surface for the graft.
Only enlarge the anterior portal when ready to deliver the graft.
Take care to manage the sutures meticulously.
Position the graft into the desired area before final tensioning.
Take care to tension both working sutures together.

issues. Bioabsorbable screws have been used in the arthroscopic Latarjet technique but have shown unacceptably high rates of graft osteolysis.¹² Several arthroscopic fixation techniques have been described. Taverna et al.¹⁰ and Xu et al.¹⁵ published ICBG fixation techniques using EndoButton devices (Smith & Nephew Endoscopy, Andover, MA). Kalogrianitis and Tsouparopoulos¹¹ used the Arthrex TightRope suspensory suture button system for ICBG fixation, whereas Hassebrock et al.⁶ used this system for distal tibial allograft fixation. Finally, Hachem et al.^{16,17} utilised Arthrex SutureTape cerclage technique on ICBG and in Latarjet.

All of these techniques require a separate posterior incision for suture tensioning or knot tying on the posterior glenoid neck, which may be obscured by soft tissue. Inadequate clearance of the posterior soft tissues can potentially introduce slack in the sutures and jeopardize the potential for bony union. Recently, Jeong et al.²⁰ published an ICBG fixation technique using a single all-suture anchor. Although technically easier, this technique relies on only 1 soft giant knot for fixation, with potential weaker force applied across the graft, reducing graft rotational stability.

This article introduces an arthroscopic graft augmentation technique using 2 soft-tissue knotless suture anchors. We believe this technique has several advantages, including that it is technically easy and cost-effective (Table 1). The risk of damage to the subscapularis is minimal. The 2-point fixation ensures correct graft placement with rotational stability.

There are a few limitations to our technique. Arthroscopic bone block augmentation is generally a

more technically challenging than the open procedure. Both ICBG or allograft have some associated morbidity, which remains a concern.^{3,14} The lack of chondral surface may be an issue when compared with distal tibial allograft. The FiberTak anchor is primarily designed to be used in cancellous bone in the humeral head for rotator cuff repair; its pullout strength when applied to cortical bone is significant.²¹ In conclusion, the described technique enables anatomic reconstruction in cases of anterior glenoid bone loss using a simple all-anterior technique with all-suture anchors.

References

1. Provencher MT, Bhatia S, Ghodadra NS, et al. Recurrent shoulder instability: Current concepts for evaluation and management of glenoid bone loss. *J Bone Joint Surg Am* 2010;92:133-151 (suppl).
2. Burkhart SS, De Beer JF. Traumatic glenohumeral bone defects and their relationship to failure of arthroscopic Bankart repairs: Significance of the inverted-pear glenoid and the humeral engaging Hill-Sachs lesion. *Arthroscopy* 2000;16:677-694.
3. Moroder P, Schulz E, Wierer G, et al. Neer Award 2019: Latarjet procedure vs. iliac crest bone graft transfer for treatment of anterior shoulder instability with glenoid bone loss: A prospective randomized trial. *J Shoulder Elbow Surg* 2019;28:1298-1307.
4. Carbone S, Moroder P, Runer A, Resch H, Gumina S, Hertel R. Scapular dyskinesia after Latarjet procedure. *J Shoulder Elbow Surg* 2016;25:422-427.
5. Warner JJP, Gill TJ, O'Hollerhan JD, Pathare N, Millett PJ. Anatomical glenoid reconstruction for recurrent anterior glenohumeral instability with glenoid deficiency using an autogenous tricortical iliac crest bone graft. *Am J Sports Med* 2006;34:205-212.
6. Hassebrock JD, Starkweather JR, Tokish JM. Arthroscopic technique for bone augmentation with suture button fixation for anterior shoulder instability. *Arthrosc Tech* 2020;9:e97-e102.
7. Butt U, Charalambous CP. Complications associated with open coracoid transfer procedures for shoulder instability. *J Shoulder Elbow Surg* 2012;21:1110-1119.
8. Griesser MJ, Harris JD, McCoy BW, et al. Complications and re-operations after Bristow-Latarjet shoulder stabilization: A systematic review. *J Shoulder Elbow Surg* 2013;22:286-292.
9. Ranalletta M, Rossi LA, Bertona A, Tanoira I, Maignon GD, Bongiovanni SL. Modified Latarjet procedure without capsulolabral repair for the treatment of failed previous operative stabilizations in athletes. *Arthroscopy* 2018;34:1421-1427.
10. Taverna E, Golanò P, Pascale V, Battistella F. An arthroscopic bone graft procedure for treating anterior-inferior glenohumeral instability. *Knee Surg Sports Traumatol Arthrosc* 2008;16:872-875.
11. Kalogrianitis S, Tsouparopoulos V. Arthroscopic iliac crest bone block for reconstruction of the glenoid: A fixation technique using an adjustable-length loop cortical

- suspensory fixation device. *Arthrosc Tech* 2016;5:e1197-e1202.
12. Balestro JC, Young A, Maccioni C, Walch G. Graft osteolysis and recurrent instability after the Latarjet procedure performed with bioabsorbable screw fixation. *J Shoulder Elbow Surg* 2015;24:711-718.
 13. Boileau P, Gendre P, Baba M, et al. A guided surgical approach and novel fixation method for arthroscopic Latarjet. *J Shoulder Elbow Surg* 2016;25:78-89.
 14. Ettore T, Henri U, Laura B, Guido G. Arthroscopically assisted Latarjet procedure: A new surgical approach for accurate coracoid graft placement and compression. *Int J Shoulder Surg* 2013;7:120-123.
 15. Xu J, Liu H, Lu W, et al. Modified arthroscopic Latarjet procedure: Suture-button fixation achieves excellent remodeling at 3-year follow-up. *Am J Sports Med* 2020;48:39-47.
 16. Hachem AI, Del Carmen M, Verdalet I, Rius J. Arthroscopic bone block cerclage: A fixation method for glenoid bone loss reconstruction without metal implants. *Arthrosc Tech* 2019;8:e1591-e1597.
 17. Hachem A-I, Rondanelli SR, Rius X, Barco R. Latarjet cerclage: The all-arthroscopic metal-free fixation. *Arthrosc Tech* 2021;10:e437-e450.
 18. NHS Blood and Transplant. Tissue and Eye Services. Shaped bone. <https://www.nhsbt.nhs.uk/tissue-and-eye-services/products/bone/shaped-bone/>. Accessed March 4, 2021.
 19. Wong SE, Friedman LGM, Garrigues GE. Arthroscopic Latarjet: Indications, techniques, and results. *Arthroscopy* 2020;36:2044-2046.
 20. Jeong JY, Yoo YS, Kim T. Arthroscopic iliac bone block augmentation for glenoid reconstruction: Transglenoid fixation technique using an all-suture anchor. *Arthrosc Tech* 2020;9:e351-e356.
 21. Otto A, DiCosmo AM, Baldino JB, et al. Biomechanical evaluation of proximal hamstring repair: All-suture anchor versus titanium suture anchor. *Orthop J Sport Med* 2020;8:2325967119892925.