

A case of metastasis of small cell lung cancer to the parotid gland: a case report and literature review

Journal of International Medical Research

2019, Vol. 47(11) 5824–5830

© The Author(s) 2019

Article reuse guidelines:

sagepub.com/journals-permissions

DOI: 10.1177/0300060519865645

journals.sagepub.com/home/imr



Yu Cui¹ , Xiang-Yan Cui¹, Yu Wu¹,
Wan-Zhong Yin^{1,*} and Zhan-Peng Zhu^{2,*}

Abstract

Small cell lung cancer metastasizing to the parotid gland is very rare and only a few cases have been reported. A 64-year-old man presented with a painless mass and peripheral facial paralysis. Neck ultrasound identified a solid mass in the right parotid gland with enlargement of the lymph nodes in the gland and the right submandibular lymph nodes. Lung computed tomography imaging demonstrated abnormalities in the upper and middle lobes of the right lung and intermediate bronchus, with obstructive pneumonia, as well as enlargement of the right hilar and mediastinal lymph nodes. Postoperative histopathological analysis identified small cell carcinoma in the right parotid gland with involvement of the right neck lymph nodes (one of eight). Bronchoscopy was performed and immunohistochemical analysis of the specimen demonstrated possible metastasis of small cell lung cancer to the parotid gland. From postoperative day 15, the patient started to undergo six cycles of an adjuvant chemotherapy regimen. No complications of the chemotherapy regimen were observed after three cycles. Treatment and follow-up are ongoing.

Keywords

Parotid gland tumour, small cell cancer, lung cancer, metastasis

Date received: 5 March 2019; accepted: 3 July 2019

*These authors contributed equally to this study.

Corresponding author:

Wan-Zhong Yin, Department of Otolaryngology, Head and Neck Surgery, First Hospital of Jilin University, 71 Xinmin Street, Chaoyang District, Changchun, Jilin 130021, China.

Email: yinwanzhong88@hotmail.com

¹Department of Otolaryngology, Head and Neck Surgery, First Hospital of Jilin University, Changchun, Jilin Province, China

²Department of Neurosurgery, First Hospital of Jilin University, Changchun, Jilin Province, China



Introduction

Primary parotid tumours in adults are mostly benign pleomorphic adenomas.¹ Malignant lesions are uncommon, but include predominantly mucoepidermoid carcinomas, adenocystic carcinomas and malignant mixed carcinoma.² Small cell carcinoma histology of parotid tumours is rarely seen, accounting for only 1.7% of parotid gland tumours,¹ with only a few cases so far reported.^{1,3-7} This current report presents a rare case of small cell parotid gland cancer metastasized from the lung that was diagnosed in a 64-year-old man. Furthermore, the report describes the examination and treatment plan; and provides a literature review of the current standard of care.

Case report

In October 2018, a 64-year-old man presented at the Department of Otolaryngology, Head and Neck Surgery, First Hospital of Jilin University, Changchun, Jilin Province, China with a painless mass below the right ear and complained of peripheral facial paralysis for a month. A physical examination found a 2.0 × 2.0 cm mass, with poor mobility,

in the right parotid region. The accompanied peripheral facial paralysis on the right side was classified as House-Brackmann Grade III. Neck ultrasound identified a solid mass in the right parotid gland with enlargement of the lymph nodes in the gland and the right submandibular lymph nodes. Lung computed tomography (CT; Figure 1) demonstrated abnormalities in the upper and middle lobes of the right lung and intermediate bronchus, with obstructive pneumonia, as well as enlargement of the right hilar and mediastinal lymph nodes. The patient showed no symptoms of coughing, expectoration or haemoptysis.

The patient insisted on confirming the malignancy of the solid mass in the right parotid gland but refused to undergo pre-operative needle biopsy. Intraoperative pathology confirmed a malignant tumour with metastatic potential. Thus, the right parotid gland and facial nerve were resected and selective neck dissection performed. Postoperative histopathological analysis demonstrated small cell carcinoma in the right parotid gland (Figure 2a) with involvement of the right neck lymph nodes (one of eight). Bronchoscopy was performed and the pathological results were small cell carcinoma (Figure 2b).

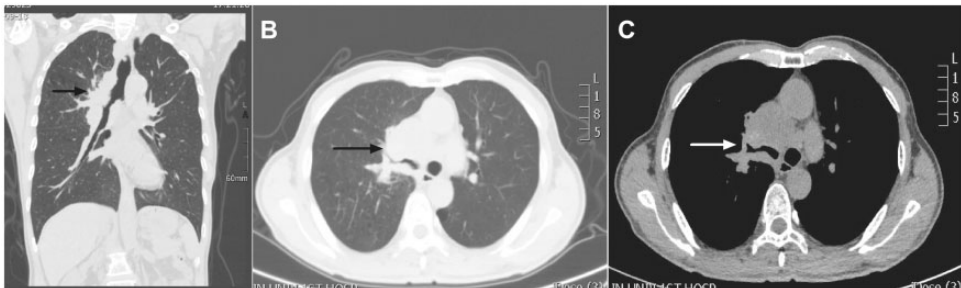


Figure 1. Coronal (a), lung window (b) and mediastinal window (c) computed tomography images of a 64-year-old man who presented with a painless mass below the right ear and complained of peripheral facial paralysis for a month. The images show abnormalities in the upper and middle lobes of the right lung and intermediate bronchus and obstructive pneumonia. Enlargement of the right hilar and mediastinal lymph nodes, indicated by black and white arrows, is also visible.

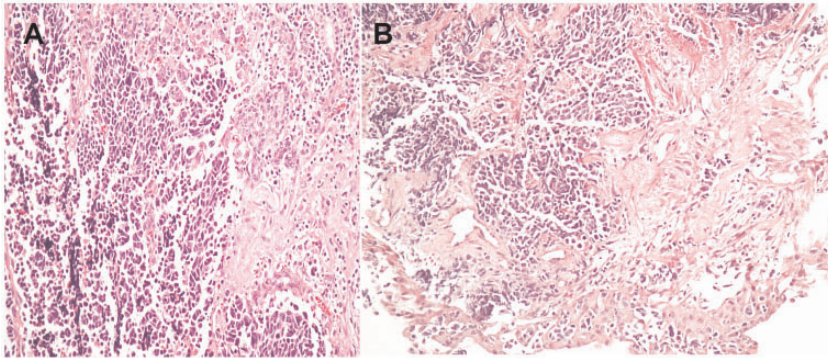


Figure 2. Histology of the parotid gland and bronchoscopic biopsy specimen from a 64-year-old man who presented with a painless mass below the right ear and complained of peripheral facial paralysis for a month. Haematoxylin and eosin staining was performed on sections from the parotid gland (a) and the bronchoscopic biopsy specimen (b). The results identified an invasive small cell carcinoma. Magnification $\times 200$. The colour version of this figure is available at: <http://imr.sagepub.com>.

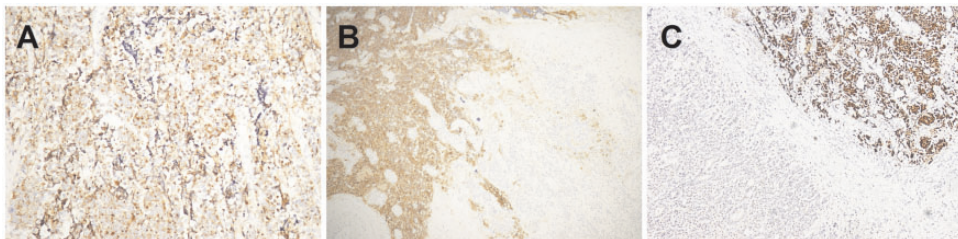


Figure 3. Immunohistochemical analysis of the parotid gland from a 64-year-old man who presented with a painless mass below the right ear and complained of peripheral facial paralysis for a month demonstrated positive staining of chromaffin granule protein A (a; magnification $\times 200$), synapsin (b; magnification $\times 100$) and thyroid transcription factor-1 (c; magnification $\times 200$). The colour version of this figure is available at: <http://imr.sagepub.com>.

Immunohistochemical analysis of the post-operative pathological specimen indicated positive staining for pan-cytokeratin, CD56, chromaffin granule protein A, synapsin (Syn) and thyroid transcription factor-1 (TTF-1) (Figure 3), partial positive staining of Ki-67 and cytokeratin 7, and negative staining for CD99, cytokeratin 5/6 and common leukocyte antigen (LCA). Immunohistochemical analysis of the bronchoscopy pathological specimen demonstrated positivity of pan-cytokeratin, CD56, Syn, TTF-1, partial positivity of Ki-67, but no staining of P40,

cytokeratin 20, cytokeratin 5/6, vimentin and LCA, suggesting possible metastasis of small cell lung cancer to the parotid gland. Positron emission tomography (PET)/CT identified a hypermetabolic lesion in the right upper and middle lobes of lung and intermediate bronchus (Figure 4), suggesting possible central lung cancer with distal obstruction and inflammation. Multiple lymph nodes were involved, and localized peritoneal thickening with hypermetabolism was observed under the right lobe of the liver, suggesting possible liver metastasis. Although hyperplasia, calcification and a

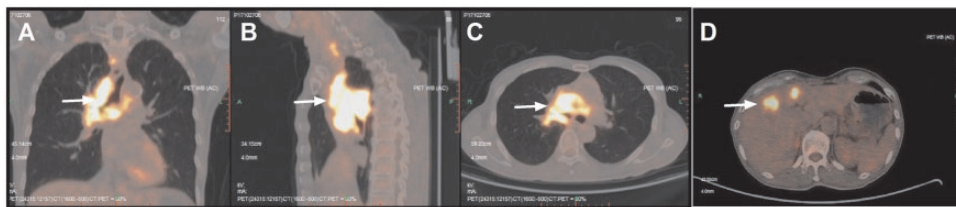


Figure 4. Coronal (a), sagittal (b) and axial (c) positron emission tomography/computed tomography images of a 64-year-old man who presented with a painless mass below the right ear and complained of peripheral facial paralysis for a month showing a hypermetabolic lesion in the right upper and middle lobes and intermediate bronchus, with features of central lung cancer (white arrow). Localized thickening and hypermetabolism under the right lobe of liver (d, white arrow) suggests possible liver metastasis.

hypermetabolic area were observed in the prostate under PET/CT, analysis of prostate-specific antigen in the serum and magnetic resonance imaging (MRI) showed no lesion.

The patient recovered well after the surgery and was scored 1 on the Eastern Cooperative Oncology Group performance scale. From postoperative day 15, the patient started to undergo six cycles of adjuvant chemotherapy with a combination of cisplatin + etoposide: days 1–3, 75 mg/m² cisplatin intravenously + 100 mg/m² etoposide intravenously; day 4, 100 mg/m² etoposide intravenously; day 5, 50 mg/m² etoposide intravenously; and the cycle was repeated every 20 days. Supportive therapy was also provided. No complications of the chemotherapy were observed after three cycles, treatment and follow-up are ongoing. Ethical approval was not required for this case report. The patient provided written informed consent for the publication of their data.

Discussion

Small cell carcinoma accounts for 15% of malignant tumours originated from the bronchus and 25% of all lung cancer.¹ It is usually associated with a high degree of malignancy and is frequently accompanied by paraneoplastic syndromes.⁸ The highly vascularized microenvironment in the lung

facilitates cancer cell extravasation thereby making possible distant metastases, which are commonly seen in the mediastinum, supraclavicular lymph nodes, liver, bone, adrenal gland and brain.^{1,9} Small cell carcinomas in the parotid glands rarely originate locally,¹⁰ and are more often metastatic tumours from other organs such as the lung.¹¹ Distant metastasis to the parotid gland is a very rare clinical event. To the best of our knowledge, only six cases have been reported (Table 1).^{1,3–7} Previous observations in cases with metastatic lung small cell carcinoma to parotid glands have shown that these patients rarely live longer than 10 months,^{1,7} the median survival of small cell lung cancer patients,¹ suggesting a poor prognosis for these patients.

Comprehensive physical examination, imaging and histopathology are required in the diagnosis. Although solid masses with poor mobility but high growth rate are usually associated with a high degree of malignancy, the decisive diagnosis relies on needle and excisional biopsies. It is also of importance to perform chest X-rays, CT and ultrasound to identify the primary lesion. In addition, metastasis of small cell lung cancer, which is predominantly through haematogenous dissemination,¹² to the parotid gland suggests an advanced stage of lung cancer, so whole body PET/CT is necessary to track remote metastasis.

Table 1. Previous case reports of metastasis of small cell lung cancer to the parotid gland.^{1,3-7}

Case	Author	Sex	Age, years	Nerve palsy	Examination & primary lesions	Other examinations	Other systemic metastases	Treatment	Survival
1	Ulubas et al. ¹	M	59	No	Thoracic CT; right main bronchus	Bronchoscopy, bone scintigraphy	Bone metastases	Chemotherapy and supportive therapy	Died 10 months after the diagnosis
2	Boeger et al. ³	M	54	No	Chest X-rays and CT; left lung	Bronchoscopy	No	Total parotidectomy with facial nerve preservation	Not mentioned
3	Borg ⁴	M	72	No	CT; left apical lung	Bronchoscopy	No	Radiotherapy	Alive 3 years later without evidence of disease recurrence
4	Hisa and Tatemoto ⁵	M	61	No	CT; right main bronchus	Bronchoscopy	Brain metastases	Left superficial parotidectomy and right superficial parotidectomy, chemotherapy	Died 17 months after the diagnosis
5	Shalowitz et al. ⁶	M	54	Left side facial weakness	Chest X-rays and CT; pleural surface of the left lower lung	Bronchoscopy	No	Chemotherapy and radiotherapy	Living at the time of the report
6	Shi et al. ⁷	M	61	No	Chest X-rays and CT; right upper lobe	Bronchoscopy	No	Partial parotidectomy and facial nerve dissection, chemotherapy and radiotherapy	Not mentioned

CT, computed tomography.

The treatment of metastatic parotid tumour is a matter of debate. In our view, total or partial parotidectomy with consideration for neck dissection, followed by postoperative chemotherapy should be included in the treatment regimen, because small cell lung cancer is sensitive to chemotherapy.¹³ If facial paralysis occurs, the facial nerve loses its reserved value. Before surgery, the current patient was advised to undergo facial nerve graft at the same time, but the patient refused. Follow-up showed that the patient did not undergo any kind of secondary facial reconstruction. A previous case report suggested that neck dissection may be unnecessary because the metastasis is more likely to be caused by haematogenous dissemination.⁷ In contrast, in our opinion, selective neck dissection can minimize the risk of recurrence and metastasis to some extent. In this current case, a total parotidectomy with facial nerve resection was undertaken, with selective neck dissection, followed by adjuvant chemotherapy. Chemotherapy combining cisplatin and etoposide was undertaken in this current case study, considering the sensitivity of small cell lung cancer to these drugs.¹³ No obvious complication was observed after three cycles of treatment and no disease progression has been observed during follow-up.

In conclusion, metastasis of small cell lung cancer to the parotid gland is rare and associated with poor clinical outcomes. Physical examination, diagnostic imaging, such as chest X-ray, CT and MRI, and histopathological analyses are required for a definitive diagnosis. Currently, it is mainly managed by surgery and chemotherapy, but the long-term efficacy remains to be characterized.

Acknowledgements

The authors would like to thank Medjaden Bioscience Limited for editing and proofreading the article. The authors also thank Xin-Mei Liu

for their contribution during the process of manuscript revision.

Authors' contributions

Yu Cui, Xiang-Yan Cui and Yu Wu collaborated in the conception and design of the study. Yu Cui, Xiang-Yan Cui and Yu Wu acquired the data. Yu Cui, Zhan-Peng Zhu and Wan-Zhong Yin performed the data analysis and interpretation. All authors were involved in writing the manuscript. All authors read and approved the final manuscript.

Declaration of conflicting interest

The authors declare that there are no conflicts of interest.

Funding

This research received no specific grant from any funding agency in the public, commercial, or not-for-profit sectors.

ORCID iD

Yu Cui  <https://orcid.org/0000-0001-9107-3579>

References

1. Ulubas B, Ozcan C and Polat A. Small cell lung cancer diagnosed with metastasis in parotid gland. *J Craniofac Surg* 2010; 21: 781–783.
2. Ozcan C, Talas D and Görür K. Parotid gland mucoepidermoid carcinoma associated with myasthenia gravis. *J Craniofac Surg* 2007; 18: 1055–1058.
3. Boeger D, Hocke T and Esser D. The interesting case – case no. 68. Metastasis of a small-cell bronchial carcinoma to the parotid gland. *Laryngorhinootologie* 2005; 84: 117–120 [Article in German, English abstract].
4. Borg MF. Parotid gland as an initial site of metastasis. *Australas Radiol* 2004; 48: 88–92.
5. Hisa Y and Tatemoto K. Bilateral parotid gland metastases as the initial manifestation of a small cell carcinoma of the lung. *Am J Otolaryngol* 1998; 19: 140–143.
6. Shalowitz JI, Cassidy C and Anders CB. Parotid metastasis of small cell carcinoma

- of the lung causing facial nerve paralysis. *J Oral Maxillofac Surg* 1988; 46: 404–406.
7. Shi S, Fang QG, Liu FY, et al. Parotid gland metastasis of lung cancer: a case report. *World J Surg Oncol* 2014; 12: 119.
 8. Shi S, Fang QG, Liu FY, et al. Parotid gland metastasis of lung cancer: a case report. *World J Surg Oncol* 2014; 12: 119.
 9. Sher T, Dy GK and Adjei AA Small cell lung cancer. *Mayo Clin Proc* 2008; 83: 355–367.
 10. Scher RL, Feldman PS and Levine PA. Small-cell carcinoma of the parotid gland with neuroendocrine features. *Arch Otolaryngol Head Neck Surg* 1988; 114: 319–321.
 11. Cantera JM and Hernandez AV. Bilateral parotid gland metastasis as the initial presentation of a small cell lung carcinoma. *J Oral Maxillofac Surg* 1989; 47: 1199–1201.
 12. Heidemann F, Schildt A, Schmid K, et al. Selectins mediate small cell lung cancer systemic metastasis. *PLoS One* 2014; 9: e92327.
 13. Kalemkerian GP, Akerley W, Bogner P, et al. Small cell lung cancer. *J Natl Compr Canc Netw* 2013; 11: 78–98.