

Contents lists available at [ScienceDirect](http://www.sciencedirect.com)

International Journal of Surgery Case Reports

journal homepage: www.casereports.com

Biosynthetic graft failure to replace infected infrainguinal bypass as developing infection due to *Morganella morganii* leading to disruption of the anastomosis. Case report



Gladiol Zenunaj*, Claudio Spataro, Luca Traina, Vincenzo Gasbarro

Unit of Vascular and Endovascular Surgery, University Hospital of Ferrara, Italy

ARTICLE INFO

Article history:

Received 2 September 2017

Accepted 3 November 2017

Available online 12 November 2017

Keywords:

Infrainguinal bypass

Graft infection

Biosynthetic material

Graft occlusion

Negative pressure medication

Morganella morganii

ABSTRACT

INTRODUCTION: Biosynthetic prosthesis has become the trend to carry out arterial reconstruction in infected sites since considered to be resistant to infection. Late graft occlusion is the only complication reported in literature so far. We report a case of biosynthetic graft infection which led to early detachment of the femoral anastomosis of a femoral-popliteal above-knee bypass.

MATERIAL: A 76-year-old man developed groin infection 3 months later after performing an ePTFE femoral-popliteal above-knee bypass for critical limb ischemia. He was re-admitted for groin infection involving the vascular structures. Explantation of the existing bypass and its replacement with a biosynthetic graft (omniflow II) was performed. Detachment of the proximal anastomosis occurred 6 days later leading to groin haematoma. Consequently, retroperitoneal access was performed for clamping the external iliac artery so as to control haemorrhage followed by explantation of the biosynthetic graft. An external iliac-popliteal above-knee bypass was tailored in order to save the limb and it was performed using a transobturator approach avoiding the infected site. In both cases bacterial cultures resulted positive for *Morganella morganii*. The groin wound was treated separately with negative pressure medication healing definitively within 20 days and after 3-month follow-up the bypass was still patent.

CONCLUSION: This is the first report of biosynthetic graft infection used for infrainguinal reconstruction leading to haemorrhage due to anastomosis disruption. Using an extra-anatomical access for providing blood inflow to the leg avoiding the infected site and treating safely the groin wound with VAC therapy revealed to be a valid approach.

© 2017 The Authors. Published by Elsevier Ltd on behalf of IJS Publishing Group Ltd. This is an open access article under the CC BY-NC-ND license (<http://creativecommons.org/licenses/by-nc-nd/4.0/>).

1. Introduction

Traditionally the treatment of infrainguinal bypass infection consists in its explantation followed by performing a new one using an autologous graft [1]. In absence of autologous material, a biosynthetic conduit can be used since considered to be more resistant to infections [2]. New generation of biosynthetic grafts for infrainguinal reconstruction are reported to be a satisfying choice without noticing any case of their infection and the only complication reported so far is their occlusion. We report a case of a biosynthetic graft (Omniflow II) infection which led to detachment of the femoral anastomosis of an above-knee femoral-popliteal bypass leading to groin haematoma. Consequently, given the recurrence of graft infections with a compromised groin surgical site and

underneath haematoma, alternative ways are required to warrant firstly patient's survival and secondarily limb salvage.

The work in this case has been reported in line with the SCARE criteria [3].

2. Case description

A 76-year-old man was admitted for critical limb ischemia (Rutherford Grade II, Category 5) and presented few comorbidities such as hypertension, dyslipidemia and diabetes type 2 non-insulin treated. Initially, a femoral popliteal above knee bypass using an ePTFE graft was performed and 3 months later he was readmitted for graft occlusion associated to groin infection with little dehiscence of the inguinal surgical scar. The existing bypass was explanted and replaced with a biosynthetic one. After initial empiric antibiotic therapy it was set up a specific antibiogram-based treatment and the bacterial specie isolated consisted of *Morganella morganii*. Within 6 days swelling of the groin occurred and CT scan documented a detachment of the proximal anastomosis (Fig. 1). A retroperitoneal access was carried out to control the

* Corresponding author at: Unit of Vascular and Endovascular Surgery, University Hospital of Ferrara, Via Aldo Moro 8, 44120 Ferrara, Italy.

E-mail addresses: gladiol.4@hotmail.com (G. Zenunaj), cspataro86@gmail.com (C. Spataro), trainaluca@yahoo.it (L. Traina), gsv@unife.it (V. Gasbarro).

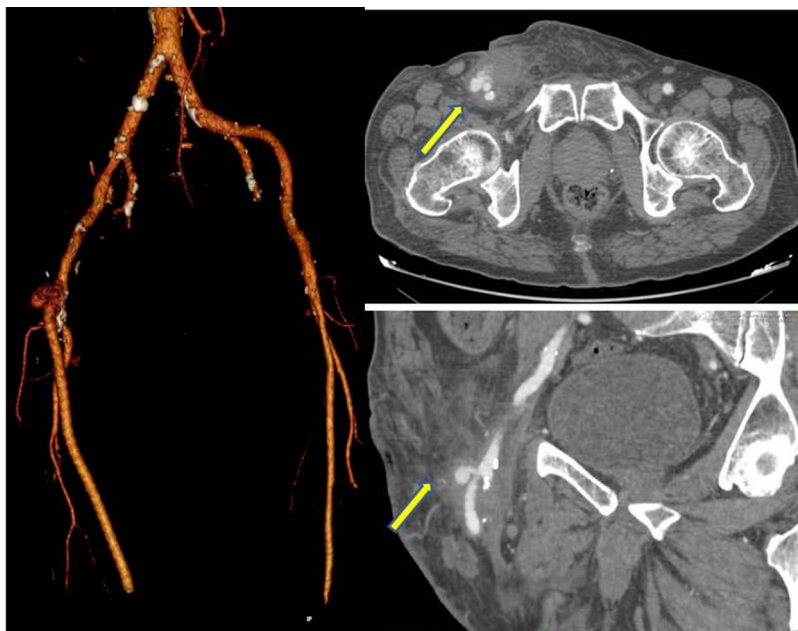


Fig. 1. Disrupture of the femoral anastomosis (common femoral artery – biosynthetic graft) with groin haematoma (yellow arrow).

inflow, clamping the external iliac artery. Then, it was tailored an external iliac to popliteal ePTFE bypass using a transobturator approach (Fig. 2). The biosynthetic graft examination revealed to be positive for *Morganella Morganii* resistant to beta-lactam antibiotics. The groin wound was treated with vacuum-assisted wound closure (VAC) therapy. No early infection or other complications occurred and after a 3-month follow up the graft was patent. The groin was definitively healed after 20 days without developing dehiscence.

3. Discussion

Traditionally infection of an infrainguinal bypass consists in its explantation and then performing a new one using an autologous graft [1]. The best approach for infected prosthetic graft is demonstrated to be its explantation in contrast to the autologous ones where the attempt to preserve them is well accepted. This, because of the assumption that even in an infected surgical site an autologous graft hardly will get infected and consequently preferred for reconstructions [4]. However, in absence of an autologous graft a biosynthetic conduit can be used since more resistant to infection with good results reported in literature [5]. For the new generation biosynthetic (Omniglow II) grafts the only complication reported so far is their occlusion with an average primary patency of 67.6% at one year and 61.5% at two years [2,5,6]. However the graft occlusion is not the only complication which may occur. Infection of the surgical site might lead to early disruption of the anastomosis developing haematoma or late pseudoaneurysm. The most bacterial species drawn from infected sites and reported consist of *Staphylococcus aureus*, *Enterococcus*, *Pseudomonas aeruginosa*, *Klebsiella pneumoniae*, *Escherichia coli* [5,6]. In the literature we did not find any quoting for *Morganella morganii* which is a gram-negative bacteria basically belonging to the intestinal flora and usually responsible of nosocomial infections in immunocompromised patients [7]. Our impression is that in an immunocompromised patient like the our one this bacteria developed a sort of superinfection which might have weakened both the arterial and biosynthetic wall leading to disruption of the anastomosis. The point that only *Morganella morganii* was found colonizing the graft it presumes that it could be alone the cause of this complication but on the other hand consist-

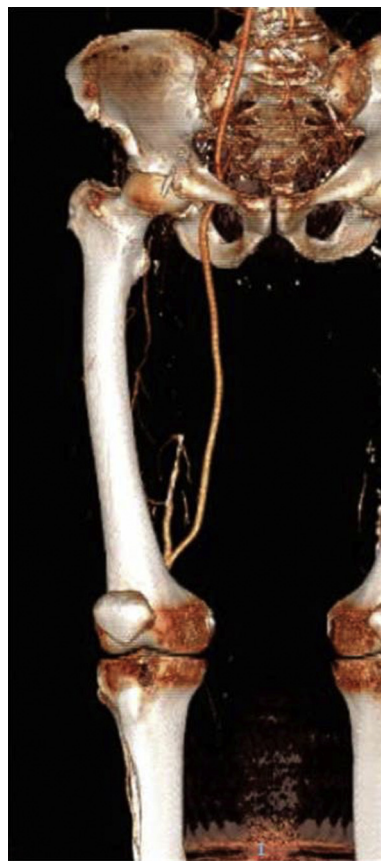

Fig. 2. Iliac-above-knee popliteal bypass through a transobturator approach.

ing of only one case we cannot claim a major affinity of this bacteria for biosynthetic materials.

Transobturator approach has been as an alternative to provide blood supply to the lower limb where femoral vessels have become inaccessible because of a compromised groin in various situations such as infection, tissue neoplastic infiltration or tenacious scar due

to multiple groin interventions [8,9]. This is considered an extra anatomical bypass and there are not substantial data to determine its long term effectiveness and durability since in literature are described only a few cases and with a short follow-up. In our case this approach revealed to be useful because in one hand it enabled to provide an inflow avoiding the infected site given the recurrence of infection of two different grafts used for reconstruction which makes meaningless the use of other materials at the same surgical site. I would have been better using at this point an allogeneic graft to carry out the new bypass but they are not promptly available in an emergency situation. In such a difficult situation avoiding the infected site performing an extra- anatomical bypass for the revascularization enabled us to focus safety on the treatment of the infected groin performing tissue debridement and applying a VAC therapy [10].

4. Conclusion

This is the first report of biosynthetic graft infection used for infrainguinal reconstruction leading to haemorrhage due to anastomosis disruption. Using an extra-anatomical access in order to provide blood inflow to the leg avoiding the infected site and treating safely the groin wound with VAC therapy revealed to be a valid approach.

Conflicts of interest

None.

Sources of funding

No funding has been received for this work.

Ethical approval

This case report did not involve any research activity. Ethical approval from institutional committee was not required.

Consent

Written informed consent was obtained from the patient for publication of this case report and accompanying images. A copy of the written consent is available if required.

Author contribution

GZ: bibliography collection, conceiving and writing of the report.

LT: patient's data collection, co-writing and manuscript's preparation.

CS: patient's data collection, bibliography collection, images' selection.

VG: report's supervision and coordination.

Registration of research studies

Not applicable.

Guarantor

GZ.

References

- [1] F.A. Herrera, S. Kohanzadeh, Y. Nasser, et al., Management of vascular graft infections with soft tissue flap coverage: improving limb salvage rates—a Veterans Affairs experience, *Am. Surg.* 75 (2009) 877–881.
- [2] G. Wiltberger, I. Matia, M. Schmelzle, F. Krenzien, H.M. Hau, B. Freitas, S. Jonas, P.T. Fellmer, Mid- and long-term results after replacement of infected peripheral vascular prosthetic grafts with biosynthetic collagen prosthesis, *J. Cardiovasc. Surg. (Torino)* 55 (October (5)) (2014) 693–698.
- [3] R.A. Agha, A.J. Fowler, A. Saetta, I. Barai, S. Rajmohan, D.P. Orgill, The SCARE Group, The SCARE statement: consensus-based surgical case report guidelines, *Int. J. Surg.* 34 (2016) 180–186.
- [4] G.S. Treiman, S. Copland, A.E. Yellin, P.F. Lawrence, R.M. McNamara, R.L. Treiman, Wound infections involving infrainguinal autogenous vein grafts: a current evaluation of factors determining successful graft preservation, *J. Vasc. Surg.* 33 (May (5)) (2001) 948–954.
- [5] P.T. Fellmer, G. Wiltberger, H.M. Tautenhahn, I. Matia, F. Krenzien, S. Jonas, Early results after peripheral vascular replacement with biosynthetic collagen prosthesis in cases of graft infection, *Zentralbl Chir.* 139 (October (5)) (2014) 546–551 [Article in German].
- [6] I. Töpel, T. Stigler, I. Ayx, T. Betz, C. Uhl, M. Steinbauer, Biosynthetic grafts to replace infected prosthetic vascular bypasses: a single-center experience, *Surg. Infect. (Larchmt)* 18 (February/March (2)) (2017) 202–205.
- [7] H. Liu, J. Zhu, Q. Hu, X. Rao, *Morganella morganii*, a non-negligent opportunistic pathogen, *Int. J. Infect. Dis.* 50 (September) (2016) 10–17.
- [8] U. Ferreira, L.O. Reis, L.Y. Ikari, W. da Silva Jr, W.E. Matheus, F. Denardi, R.M. Stopiglia, F.H. Menezes, Extra-anatomical transobturator bypass graft for femoral artery involvement by metastatic carcinoma of the penis: report of five patients, *World J. Urol.* 26 (October (5)) (2008) 487–491.
- [9] J.M. Millis, S.S. Ahn, Transobturator aorto-profunda femoral artery bypass using the direct medial thigh approach, *Ann. Vasc. Surg.* 7 (July (4)) (1993) 384–390.
- [10] S.I. Acosta, C. Monsen, Outcome after VAC[®] therapy for infected bypass grafts in the lower limb, *Eur. J. Vasc. Endovasc. Surg.* 44 (September (3)) (2012) 294–299.

Open Access

This article is published Open Access at [sciencedirect.com](https://www.sciencedirect.com). It is distributed under the [IJSCR Supplemental terms and conditions](#), which permits unrestricted non commercial use, distribution, and reproduction in any medium, provided the original authors and source are credited.