

## Post-menopausal presentation of yolk sac germ cell tumour



V.L. Parker<sup>a,\*</sup>, P. Sanderson<sup>a</sup>, V. Naik<sup>b</sup>, C. Quincey<sup>b</sup>, K. Farag<sup>a</sup>

<sup>a</sup> Department of Obstetrics and Gynaecology, Barnsley Hospital, UK

<sup>b</sup> Department of Pathology, Barnsley Hospital, UK

### ARTICLE INFO

#### Article history:

Received 23 September 2014

Accepted 8 November 2014

Available online 15 November 2014

#### Keywords:

Yolk sac  
Tumour  
Germ cell  
Ovarian  
Post-menopause

### Introduction

#### Case

A 60 year-old female was referred to Gynaecology clinic with abdominal distention and a palpable abdominal mass extending above the umbilicus. She was para two (normal deliveries), and post-menopausal for 10 years with no subsequent bleeding per vagina. She followed routine cervical screening smears, had never taken hormone replacement therapy (HRT), and was a non-smoker. She had no past medical history or family history of gynaecological or breast malignancy. Tumour markers were taken; CEA = 75.3 µg/L, CA199 = 81 kU/L, CA125 = 194 kU/L, and a CT abdomen and pelvis arranged querying bowel or ovarian primary given the raised tumour markers. Post-operative tumour markers included alpha feto-protein (AFP) = 11,677 kU/L and beta human chorionic gonadotrophin (hCG) = 8 mIU/L.

CT scan revealed a large midline mass (23 × 11.5 × 18.5 cm) predominantly cystic, with poorly defined walls, compressing and indistinguishable from the large bowel near the caecum and sigmoid colon, with bilateral hydronephrosis and hydroureter. The mass was deemed likely ovarian (bilateral) in origin with no significant lymphadenopathy, omental or extra-pelvic disease. However, given the raised CA199, CEA and the radiological appearances of a mass inseparable from the large bowel, the patient underwent US guided

biopsy to confirm the site of origin. The biopsy was reported as poorly differentiated adenocarcinoma. Immunostains were positive for CDX2, CK20, CA125, and CK7 and negative for ER. Based on the clinical picture and immunostains the pelvic tumour was diagnosed as colonic in origin.

One month after initial imaging, the patient underwent attempted debulking surgery involving right hemi-colectomy, resection of the terminal ileum and caecum with ileostomy and mucus fistula formation. The tumour was densely adherent to the right anterior abdominal wall, mesentery of the small bowel, sigmoid colon, caecum and bladder. The proximal colon was dilated, indicating partial obstruction secondary to tumour, requiring a right hemicolectomy. Tumour was resected from the small bowel and the right anterior abdominal wall and bladder, being removed in piecemeal fragments.

Intra-operatively, superficial and deep hepatic nodules were palpable hence maximal debulking was not deemed appropriate given the extent of disease spread. The uterus, right or left ovary could not be separately identified from the tumour bulk, and the pelvis was inaccessible due to the large mass (20 cm size). Therefore the procedure was completed and further extra-colonic resection was not performed.

#### Pathology

The pelvic tumour was extensively sampled and morphology showed a necrotic, heterogeneous tumour with solid, reticular and glandular pattern. There were goblet cells present in keeping with intestinal differentiation. The tumour showed Schiller Duval bodies, on the basis of which an AFP immunostain was performed, which was strongly and diffusely positive (Fig. 1). This confirmed the diagnosis of a yolk sac tumour. The tumour was positive for AE1/3, focally for CA125, CDX2, beta hCG, and very focally positive for CK7 and CK20. The tumour was negative for p53, WT1, CD10 and CD56. There was no endometrioid or serous carcinoma component present in the tumour. Compressed ovarian stroma was identified thereby confirming an ovarian origin (Fig. 2).

The right hemi-colectomy specimen showed tumour cells with a similar morphology to the pelvic tumour, which infiltrated into the mesenteric fat, mucosa of the ileum, base of the appendix and caecum. The overlying mucosa was intact. Lymph nodes showed no evidence of tumour metastases.

Based on morphology and immunohistochemistry, the final diagnosis was classified as primary ovarian yolk sac tumour (malignant germ cell tumour) with focal intestinal differentiation.

\* Corresponding author at: Department of Obstetrics and Gynaecology, Barnsley Hospital NHS Foundation Trust, Gawber Road, Barnsley, South Yorkshire S75 2EP, UK.  
E-mail address: [victoria.beckett@cantab.net](mailto:victoria.beckett@cantab.net) (V.L. Parker).

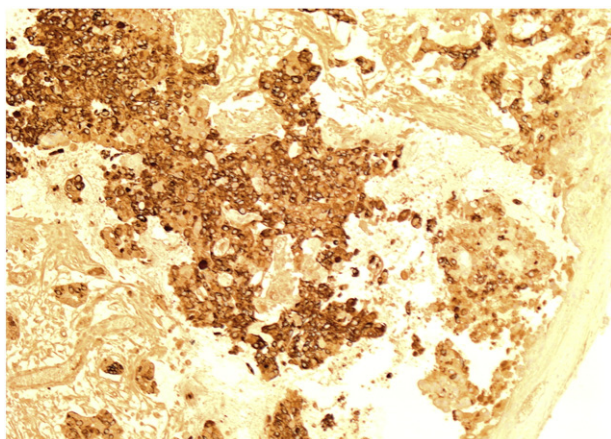


Fig. 1. Yolk sac tumour 40×: AFP immunostain stain positive.

### Outcome

Post-surgical CT imaging 17 days post-operatively revealed pelvic recurrence, peritoneal thickening, liver metastases and small bowel obstruction. The disease was deemed rapidly progressive. A long line was inserted and total parental nutrition (TPN) commenced. Due to the presence of hepatic metastases, the patient was initially commenced on 2 cycles of EP chemotherapy (etoposide and cisplatin) before switching to POMB–ACE (POMB: methotrexate, vincristine, cisplatin, bleomycin; ACE: acinomycin, cyclophosphamide, etoposide) used for high risk germ cell tumours. EP induction allows chemotherapy to be delivered to patients who would otherwise develop major toxicity if they received full dose POMB first line. Following EP therapy, the patient had a marked clinical response and a dramatic reduction in AFP and beta hCG tumour markers. She remains under Oncology follow-up.

### Discussion

Ovarian germ cell tumours (OGCT) are rare, accounting for 2–5% of ovarian malignancies with an annual incidence of 1:100,000 and

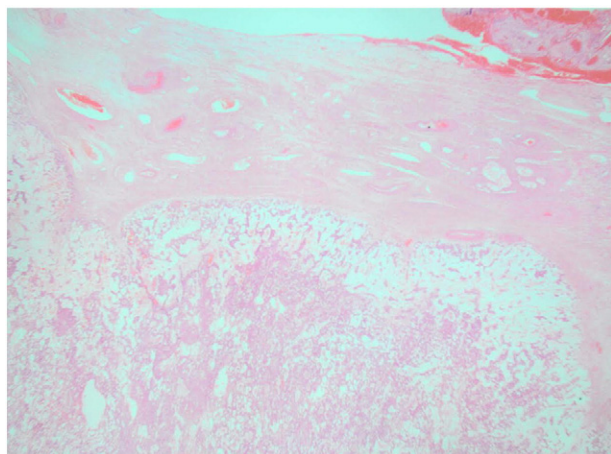


Fig. 2. Yolk sac tumour, 12.5×: Haematoxylin and eosin stain showing compressed ovarian stroma.

typically occur in young women (median age 19 years) (Bailey and Church, 2005). Yolk sac (endodermal sinus) tumours are highly malignant non-dysgerminomas and the second commonest (20–25%) subtype of ovarian germ cell tumours (Bailey and Church, 2005; Kammerer-Doak et al., 1996). They characteristically present with a rapidly enlarging abdominal mass causing abdominal distention and pain, with raised AFP levels produced by the yolk sac cells. OGCTs are highly sensitive to combination chemotherapy, yet were historically associated with a poor prognosis and can prove fatal without prompt treatment. Most are unilateral and have subclinical metastases at presentation, with the tumour spreading locally throughout the peritoneum in preference to haematogenously. Survival rates of stages I–II yolk sac tumours are 60–100%, falling to 50–75% with stages II–IV disease. 40% yolk sac tumours display mixed histology with dysgerminoma subtypes (eg: teratoma) (Bailey and Church, 2005).

Germ cell tumours in post-menopausal patients are extremely rare, with very few case reports in the literature (Kammerer-Doak et al., 1996; Rutgers et al., 1987; Nogales et al., 1996; Horiuchi et al., 1998; Mazur et al., 1988; Arai et al., 1999; Brown and Green, 1976; Kinoshita, 1990; Ferracini et al., 1979; Lopez et al., 2003; Oh et al., 2001; Pliskow, 1993; Lange et al., 2012; Filiz et al., 2003; Roma and Przybycin, 2014; Meguro and Yasuda, 2013), thereby explaining the initial diagnostic uncertainty in this case report regarding tumour type. Primary debulking surgery may not have been performed if pre-operative histology had revealed yolk sac characteristics.

To our knowledge, there are 20 published reports of ovarian endodermal yolk sac tumours in post-menopausal patients ranging between 53 and 86 years at presentation (Table 1) (Kammerer-Doak et al., 1996; Rutgers et al., 1987; Nogales et al., 1996; Horiuchi et al., 1998; Mazur et al., 1988; Arai et al., 1999; Brown and Green, 1976; Kinoshita, 1990; Ferracini et al., 1979; Lopez et al., 2003; Oh et al., 2001; Pliskow, 1993; Lange et al., 2012; Filiz et al., 2003; Roma and Przybycin, 2014; Meguro and Yasuda, 2013). Most (Oh et al., 2001) cases involved mixed yolk sac tumours with embryonal, endometrioid carcinoma, cystadenoma/cystadenofibroma or cystadenocarcinoma subtypes, the oldest case being 82 years of age (Kammerer-Doak et al., 1996; Rutgers et al., 1987; Nogales et al., 1996; Horiuchi et al., 1998; Mazur et al., 1988; Arai et al., 1999; Lopez et al., 2003; Roma and Przybycin, 2014; Meguro and Yasuda, 2013). The remainder involved pure yolk sac tumour histology with the oldest reported patient being 86 years of age (Brown and Green, 1976; Kinoshita, 1990; Ferracini et al., 1979; Oh et al., 2001; Pliskow, 1993; Lange et al., 2012; Filiz et al., 2003; Roma and Przybycin, 2014). There is little knowledge concerning the development, treatment and outcome of post-menopausal yolk sac tumours. It is postulated that their pathogenesis differs from that in young adults, arising from a transformation or neometaplasia/retro-differentiation process from surface epithelial cells rather than from yolk cells alone (Lopez et al., 2003; Lange et al., 2012; Roma and Przybycin, 2014). This theory is supported by isolated reports of these tumours originating from endometriotic deposits or endometrioid carcinomas (Kammerer-Doak et al., 1996; Rutgers et al., 1987; Nogales et al., 1996; Horiuchi et al., 1998).

Endodermal yolk sac tumours are indeed rare in post-menopausal patients, but a rapidly enlarging pelvic–abdominal mass accompanied by raised AFP levels should alert clinicians and prompt appropriate management.

### Conflict of interest statement

None.

### Ethics approval

Patient consent obtained.

**Table 1**

Summary of published case reports (1976–2012) regarding endometrial yolk sac tumours, including age at presentation, pathology and treatment.

Number	Paper	Age at presentation (years)	Histology	Endometriosis	Treatment	Chemotherapy	Outcome
1	Kammerer-Doak D et al. 1996	53	Mixed: EST + embryonal carcinoma	No	TAH,BSO, omentectomy, appendectomy, pelvic and para-aortic lymph node sampling	BEP – bleomycin, etoposide, cisplatin (3 cycles)	Disease free at 5 years
2	Rutgers et al. 1986	50	Mixed: EST + endometrioid carcinoma	Yes	TAH,BSO, omentectomy, peritoneal washings	5 cycles Vincristine/dactinomycin/cyclophosphamide pre-operatively and cisplatin/vinblastine post operatively	Deceased from disease (DOD)
3	Nogales et al. 1996	64	Mixed: EST + endometrioid carcinoma	No	TAH,BSO	Vincristine/dactinomycin/cyclophosphamide (3 cycles)	Recurrence at 8 months, deceased at 14 months
4	Nogales et al. 1996	71	Mixed: EST + endometrioid carcinoma	Yes	TAH,BSO	Cisplatin based (6 cycles)	Disease free at 12 months
5	Nogales et al. 1996	71	Mixed: EST + endometrioid carcinoma	No	TAH,BSO	Cisplatin based (1 cycle)	DOD at 3 months
6	Nogales et al. 1996	73	Mixed: EST + carcinosarcoma	No	LSO, omentum, appendix and uterine biopsy	None	DOD at 5 months
7	Horiuchi et al. 1998	53	Mixed: EST + endometrioid carcinoma	No	TAH,BSO, omentectomy, pelvic lymph node biopsy	Vinblastine/peplomycin/cisplatin/actinomycin D/cyclophosphamide (6 cycles)	DOD at 6 months
8	Aria et al. 1999	71	Mixed: mucinous cystadenocarcinoma-YST	No	TAH,BSO	Cisplatin and etoposide	DOD at 6 months
9	Mazur et al. 1988	82	Mixed: mucinous cystadenofibroma-YST	No	TAH,BSO, omentectomy	None	Disease free at 2 years
10	Lopez et al. 2003	51	Mixed: EC-YST, mucinous cystadenoma	Yes	TAH,BSO, omentectomy	Cisplatin/etoposide/bleomycin (3 cycles)	DOD at 10 months
11	Lange et al. 2012	86	Pure: EST	No	TAH,BSO, omentectomy, peritoneal stripping	BEP – bleomycin, etoposide, cisplatin (4 cycles)	Not documented
12	Ferracini R et al. 1989	63	Pure: EST	No	TAH, partial removal of mass.	None	DOD 2 days post operatively
13	Brown J et al. 1976	57	Pure: EST	No	TAH,BSO, omentectomy	None	DOD at 3 months
14	Kinoshita K et al., 1990	62	Pure: EST	No	TAH,BSO, omentectomy	Cisplatin, vinblastin, peplomycin (5 cycles)	Not documented
15	Oh C et al. 2001	75	Pure: EST	No	TAH,BSO, sigmoid colectomy, omentectomy, pelvic lymph node biopsy	Etoposide and cisplatin (3 cycles)	DOD at 4 months
16	Pliskow S et al. 1993	54	Pure: EST	No	TAH,BSO, omentectomy	Bleomycin, etoposide, cisplatin (3 cycles)	Disease free at 2 years
17	Filiz G et al. 2003	76	Pure: EST	No	TAH, BSO, omentectomy, pelvic and para-aortic lymph node sampling	Bleomycin, Etoposide and Cisplatin (4 cycles)	DOD at 6 months
18	Meguro S et al. 2013	58	Mixed: AFP producing adenocarcinoma with adenofibroma showing germ cell differentiation	No	TAH,BSO, omentectomy	Carboplatin and docetaxel (6 cycles)	Disease free at 12 months
19	Roma A et al. 2014	61	Mixed: papillary serous high grade carcinoma with minor components of endometrioid carcinoma and YST.	No	TAH,BSO and staging biopsies	Intraperitoneal chemotherapy (6 cycles)	Persistent/recurrent disease at 6 months
20	Roma A et al. 2015	70	Pure: EST	Yes	TAH,BSO and staging biopsies	6 cycles	Recurrence at 7 months

## References

- Arai, T., Kitayama, Y., Koda, K., 1999. Ovarian mucinous cystadenocarcinoma with yolk sac tumor in a 71 year old woman. *Int. J. Gynecol. Pathol.* 18, 277–280.
- Bailey, J., Church, D., 2005. Management of germ cell tumours of the ovary. *Rev. Gynaecol. Pract.* 5, 201–206.
- Brown, J.R., Green, J.D., 1976. Yolk sac carcinoma. *South. Med. J.* 69, 728.
- Ferracini, R., Gardini, G., Lanzanova, G., Lorenzini, P., 1979. Endodermal sinus tumor in a 63-year-old female. *Pathologica* 71, 885–887.
- Filiz, G., Ozuysal, S., Bilgin, T., 2003. Ovarian endodermal sinus tumor in a 76-year-old woman. *J. Obstet. Gynaecol. Res.* 29 (5), 309–311.
- Horiuchi, A., Ryosuke, O., Kuniaki, N., et al., 1998. Ovarian yolk sac tumor with endometrioid carcinoma arising from endometriosis in a postmenopausal woman, with special reference to expression of alpha-fetoprotein, sex steroid receptors and p53. *Gynecol. Oncol.* 70, 295–299.
- Kammerer-Doak, D., Baurick, K., Black, W., Barbo, D.O., Smith, H., 1996. Endodermal sinus tumor and embryonal carcinoma of the ovary in a 53-year-old woman. *Gynecol. Oncol.* 63, 133–137.
- Kinoshita, K., 1990. A 62 year old woman with endodermal sinus tumor of the ovary. *Am. J. Obstet. Gynecol.* 162, 760–762.
- Lange, S., Livasy, C., Tait, D., 2012. Endodermal sinus tumor of the ovary in an 86 year old woman. *Gynecol. Oncol. Rep.* 2, 65–66.
- Lopez, J.M., Malpica, A., Deavers, M.T., Ayala, A.G., 2003. Ovarian yolk sac tumor associated with endometrioid carcinoma and mucinous cystadenoma of the ovary. *Ann. Diagn. Pathol.* 7 (5), 300–305.
- Mazur, M., Talbot Jr., W., Talerman, A., 1988. Endodermal sinus tumor and mucinous cystadenofibroma of the ovary. *Cancer* 62, 2011–2015.
- Meguro, S., Yasuda, M., 2013.  $\alpha$ -Fetoprotein-producing ovarian tumor in a postmenopausal woman with germ cell differentiation. *Ann. Diagn. Pathol.* 17 (1), 140–144.
- Nogales, F., Bergeron, C., Carvia, R., et al., 1996. Ovarian endometrioid tumors with yolk sac tumor component, an unusual form of ovarian neoplasm: analysis of six cases. *Am. J. Surg. Pathol.* 20, 1056–1066.
- Oh, C., Kendler, A., Hernandez, E., 2001. Ovarian endodermal sinus tumor in a postmenopausal woman. *Gynecol. Oncol.* 82, 392–394.
- Pliskow, S., 1993. Endodermal sinus tumor of the ovary: review of 10 cases. *South. Med. J.* 86, 187–189.
- Roma, A.A., Przybycin, C.G., 2014. Yolk sac tumor in postmenopausal patients: pure or associated with adenocarcinoma, a rare phenomenon[In Process Citation] *Int. J. Gynecol. Pathol.* 33 (5), 477–482.
- Rutgers, J.L., Young, R.H., Scully, R.E., 1987. Ovarian yolk sac tumor arising from an endometrioid carcinoma. *Hum. Pathol.* 18, 1296–1299.