



Since January 2020 Elsevier has created a COVID-19 resource centre with free information in English and Mandarin on the novel coronavirus COVID-19. The COVID-19 resource centre is hosted on Elsevier Connect, the company's public news and information website.

Elsevier hereby grants permission to make all its COVID-19-related research that is available on the COVID-19 resource centre - including this research content - immediately available in PubMed Central and other publicly funded repositories, such as the WHO COVID database with rights for unrestricted research re-use and analyses in any form or by any means with acknowledgement of the original source. These permissions are granted for free by Elsevier for as long as the COVID-19 resource centre remains active.

Conflict of interest

We have no conflicts of interest.

Ethics statement/confirmation of patients' permission

Not required.

Reference

1. Fink S. 'We're in Disaster Mode': Courage Inside a Brooklyn Hospital Confronting Coronavirus. March 26, 2020. *NY Times*. Available here: <https://www.nytimes.com/2020/03/26/nyregion/coronavirus-brooklyn-hospital.html>. (Accessed March 27 2020).
2. Wayne State University School of Medicine. COVID-19 claims member of Class of 2018 Chris Firlit. April 7, 2020. Available here: <https://today.wayne.edu/medicine/news/2020/04/07/covid-19-claims-member-of-class-of-2018-chris-firlit-36783> (Accessed April 21, 2020).

N.P. Saggese*

V.A. Cardo

*Department of Oral and Maxillofacial Surgery,
1 Brookdale Plaza, Brookdale Hospital Medical Center,
Brooklyn, NY, 11212*

*Corresponding author at: Department of Oral and Maxillofacial Surgery, Brookdale Hospital Medical Center, 1 Brookdale Plaza, Brooklyn, NY 11231. Tel.: +1 718 240-6282; Fax: +1 718 240-6682
E-mail address: npsaggese@gmail.com
(N.P. Saggese)

Re: Toward a consensus view in the management of acute facial injuries during the COVID-19 pandemic

Sir,

We commend Holmes et al for their recent article regarding the management of facial trauma during the COVID-19 pandemic.¹ They addressed the issue of teamwork among medical professionals to deliver safe care to patients. In this letter, we aim to highlight how public institutions and private practitioners can collaborate to manage patients with facial injuries during the pandemic.

Due to the high infectivity of SARS-CoV-2 and the number of asymptomatic carriers who are acting as transmitters, most governments have enacted containment measures to limit the spread of this disease. These measures have substantially modified our daily clinical practice in oral and maxillofacial surgery (OMFS) and they require us to focus on patients in medical and surgical emergency situations. Furthermore, human and technical resources have been real-

located to intensive care (ICU) and medical units treating patients with COVID-19, thereby changing current hospital practices and reducing resources for more commonplace operating theatre activities (described as scenario B, by Holmes et al).¹

Emergencies that involve life-threatening conditions (such as haemorrhage or obstruction of the upper respiratory tract) need to be treated without delay in reference medical centres, irrespective of their public or private status.² Facial injuries can be managed differently, depending on their severity. While life-threatening cases and patients with multiple injuries require multidisciplinary management in a trauma centre,³ others can be managed by case-by-case assessment of the complexity of the fractures, and possible referral to a private practitioner. We devised an algorithm based on the need for preoperative or postoperative monitoring in ICU (Fig. 1). We have considered that most closed fractures (such as those in groups 2 and 3 according to Holmes et al)¹ can be managed by private practitioners if the patients do not require monitoring in ICU. We have also devised a degraded procedure involving the use of tracheostomy for complex situations with no possibility of extubation.

In all cases, surgical practices should be adapted to take into account new priorities stemming from the COVID-19 pandemic: operations should be shortened to reduce anaesthetic drug use, aerosolisation should be avoided whenever possible, and all surgeons and staff should wear full protective equipment to limit transmission of the virus, as every patient is potentially an asymptomatic carrier of SARS-CoV-2.^{4,5}

We are aware that this strategy cannot constitute a guideline, since it reflects only the situation in the sixth-largest French city, which comprises one public university hospital and a large number of private OMFS. However, it does reflect the importance of the partnership between public and private professionals in providing safe and quality care to our patients.

Ethics statement/confirmation of patients' permission

Not required.

Conflict of interest

We have no conflicts of interest.

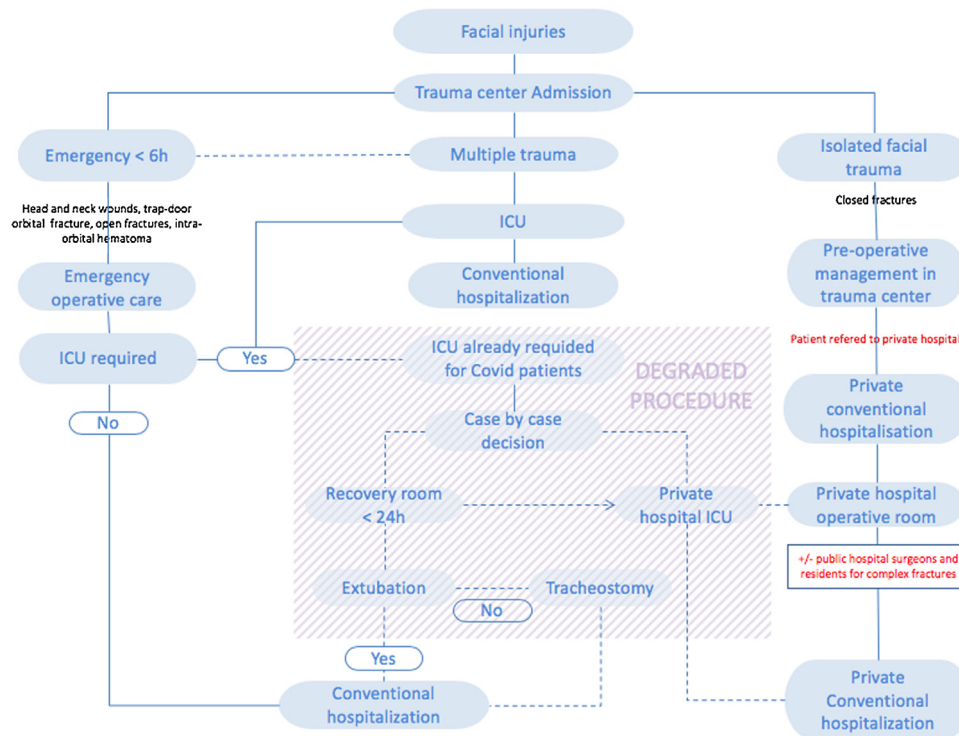


Fig. 1. Algorithm for the management of facial trauma during the COVID-19 pandemic. ICU: intensive care unit.

Reference

- Holmes S, Bhatti N, Bhandari R, et al. Toward a consensus view in the management of acute facial injuries during the Covid-19 pandemic. *Br J Oral Maxillofac Surg* available from URL: [https://www.bjoms.com/article/S0266-4356\(20\)30128-5/abstract](https://www.bjoms.com/article/S0266-4356(20)30128-5/abstract) (last accessed 1 May 2020).
- Yang Y, Soh HY, Cai ZG, et al. Experience of diagnosing and managing patients in oral maxillofacial surgery during the prevention and control period of the new coronavirus pneumonia. *Chin J Dent Res* 2020;23:57–62.
- Choi J, Lorenz HP, Spain DA. Review of facial trauma management. *J Trauma Acute Care Surg* 2020;88:e124–30.
- Zimmermann M, Nkenke E. Approaches to the management of patients in oral and maxillofacial surgery during COVID-19 pandemic. *J Craniomaxillofac Surg* 2020, <http://dx.doi.org/10.1016/j.jcms.2020.03.011>.
- French Society of Stomatology, Maxillo-Facial Surgery, Oral Surgery (SFSCMFCO). Practitioners specialized in oral health and coronavirus disease 2019: Professional guidelines from the French society of stomatology, maxillofacial surgery and oral surgery, to form a common front against the infectious risk. *J Stomatol Oral Maxillofac Surg* 2020;121:155–8.

H. Bertin ^{a,b,*}

^a Service de Chirurgie Maxillo-faciale et Stomatologie, CHU de Nantes, 1 Place Alexis Ricordeau, 44093 Nantes Cedex 1, France

^b Laboratoire des Sarcomes Osseux et Remodelage des Tissus Calcifiés (PhyOs, UMR 1238), Faculté de Médecine, 1 rue Gaston Veil, 44035 Nantes cedex, France
C. Koudougou

Chirurgie Maxillo-faciale et Stomatologie, Hôpital Privé du Confluent, 2-4 rue Eric Tabarly, 44277 Nantes cedex 2, France

F. Marion

Chirurgie Maxillo-faciale et Stomatologie, Clinique Bretéché, 3 rue de la Beraudière, 44000 Nantes, France
P. Corre ^{a,b}

^a Service de Chirurgie Maxillo-faciale et Stomatologie, CHU de Nantes, 1 Place Alexis Ricordeau, 44093 Nantes Cedex 1, France

^b Laboratoire D'Ingénierie Ostéo-Articulaire et Dentaire (LIOAD), Faculté de Chirurgie Dentaire, 1 Place Alexis Ricordeau, 44042 Nantes, France

R. Deransy

Service D'anesthésie et Réanimation, CHU de Nantes, 1 Place Alexis Ricordeau, 44093 Nantes Cedex 1, France

* Corresponding author at: Service de Chirurgie Maxillo-faciale et Stomatologie, CHU de Nantes, 1 Place Alexis Ricordeau, 44093 Nantes Cedex 1, France. Tel.: +33 (0)2 40 08 36 79, Fax: +33 (0)2 40 08 36 68.

E-mail addresses: helios.bertin@chu-nantes.fr (H. Bertin), dr.koudougou@groupeconfluent.fr (C. Koudougou), dr.marionfrancois@gmail.com (F. Marion), pierre.corre@chu-nantes.fr (P. Corre), romain.deransy@chu-nantes.fr (R. Deransy)