

## Oncology

# Metastasectomy for rectal wall seeding of prostate adenocarcinoma after transrectal prostate biopsy

E Matthew DiLizia<sup>a,\*\*</sup>, Michael Ahdoot<sup>b</sup>, Michael Daneshvar<sup>b</sup>, Patrick T. Gomella<sup>b</sup>, Nitin K. Yerram<sup>b</sup>, Peter A. Pinto<sup>b,\*</sup>

<sup>a</sup> Department of Urology, MedStar Georgetown University Hospital, Washington, DC, USA

<sup>b</sup> Urologic Oncology Branch, National Cancer Institute, National Institutes of Health, Bethesda, MD, USA



## ARTICLE INFO

## Keywords:

Prostate biopsy  
Seeding  
Needle track  
Transrectal prostate biopsy

## ABSTRACT

Definitive treatment for local prostate cancer recurrence remains controversial. Early recurrences are often from positive surgical margins or nodal metastases, however other explanations should be considered. We present a case of a 79 year-old male with localized prostate cancer and early biochemical persistence after margin-negative robotic-assisted radical prostatectomy. Workup demonstrated a 0.9 cm rectal mass without nodal or distant metastasis, and biopsy revealed prostate adenocarcinoma. A subsequent transanal excision was performed. Post-operatively, his PSA dropped to 0.02 ng/mL. We present a rare case of prostate adenocarcinoma seeding after transrectal prostate biopsy and a review of the literature.

## 1. Introduction

Biochemical recurrence after prostatectomy remains a common clinical finding which often reflexively results in treatment with systematic therapies. Biochemical recurrence or persistence can represent a multitude of clinical scenarios. Among these is the rare occurrence of needle-track seeding during ultrasound-guided prostate biopsy.

Transrectal ultrasound-guided prostate biopsy remains the most common method of diagnosing prostate cancer.<sup>1</sup> Reports of needle track seeding during prostate biopsy are exceedingly rare with approximately 40 reported in the literature.<sup>2</sup> Interestingly, seeding may be historically more common with a transperineal approach than a transrectal approach (77.5% vs. 22.5% of reported cases).<sup>2</sup>

PSA elevation after treatment for clinically localized prostate cancer is typically due to local recurrence, or less commonly, regional or distant metastases. Local recurrences following positive surgical margins are routinely treated with salvage radiation while distant metastases are often treated with systemic therapy. Surgical management of regional recurrence remains controversial. This case report describes a patient with localized prostate cancer who underwent robotic-assisted radical prostatectomy (RARP) with negative margins and had early biochemical persistence from a prostate adenocarcinoma implant in the rectum.

## 1.1. Case presentation

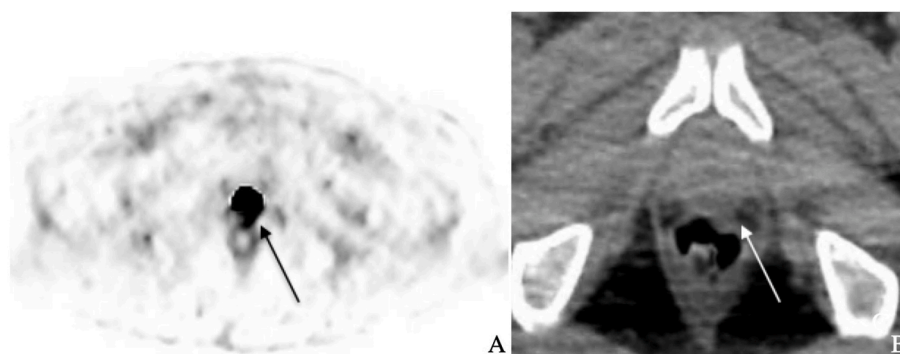
A 79 year-old man with history of hyperlipidemia and osteoarthritis on active surveillance for localized prostate cancer presented for annual surveillance MRI and PSA. On MRI fusion transrectal prostate biopsy one year prior he had Gleason grade group (GG) 3 disease, but elected to defer treatment. He remained asymptomatic with no weight loss or bone pain. His physical exam, including prostate exam, was unremarkable. Over the 11 month follow up period his PSA increased from 4.99 to 6.20 ng/mL (PSA velocity: 1.1 ng/mL/yr) and his MRI showed interval growth of a known left apical peripheral zone PIRADS-4 lesion from 1.0 to 1.2 cm. Given the change in imaging findings, a repeat MRI-fusion targeted and systematic transrectal prostate biopsy was performed with an 18-gauge spring-loaded core biopsy needle. This demonstrated GG4 prostate adenocarcinoma in one standard left-sided core and four left-sided lesion-targeted cores out of 25 total cores. Given his now high-risk prostate cancer, metastatic workup was performed with CT and bone scan that were both negative.

The patient was offered observation or surgery and elected to undergo RARP despite his advanced age. His final pathology demonstrated pT2a/N0 GG4 prostate adenocarcinoma with 7 uninvolved nodes, negative margins, and no lymphovascular invasion (LVI) or extra-prostatic extension (EPE). His post-operative PSA was 0.54 ng/mL but

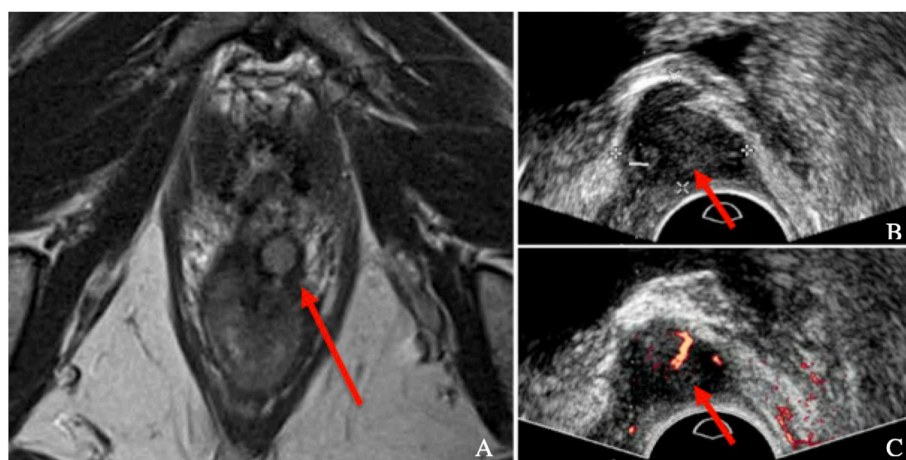
\* Corresponding author. MD National Institutes of Health Building 10, Hatfield CRC Room 2W-5940 Bethesda 20892, MD, USA.

\*\* Corresponding author.

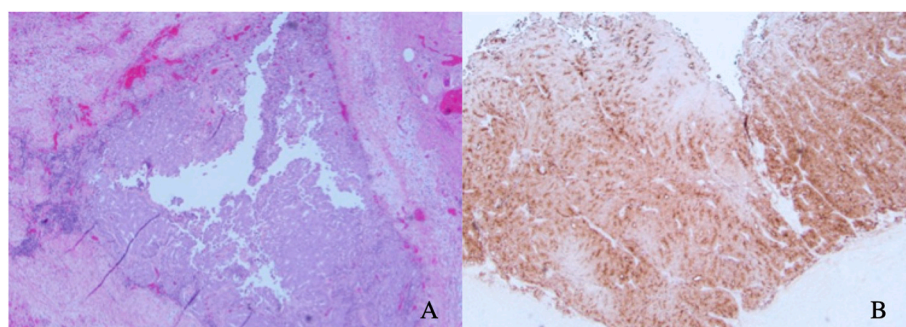
E-mail addresses: [e.m.dilizia@medstar.net](mailto:e.m.dilizia@medstar.net) (E.M. DiLizia), [pintop@mail.nih.gov](mailto:pintop@mail.nih.gov) (P.A. Pinto).



**Fig. 1.** Post prostatectomy  $^{18}\text{F}$ DCFPyl PSMA PET (A) and corresponding CT (B) demonstrating small positive focus ( $\text{SUV}_{\text{max}}$ : 5.8) at left anterior perirectal region, consistent with known location of the soft tissue lesion (arrow). No other PET-avid lesions were detected in the pelvis, regional lymph nodes, or axial skeleton.



**Fig. 2.** Post-prostatectomy pelvic MR and ultrasound imaging. T2 sequence coronal images from MRI pelvis obtained after detection of biochemical recurrence showing 0.9 cm soft tissue lesion at the left anterior peri-rectal region with no nodal disease evident (A). Ultrasound images obtained during transrectal ultrasound-guided lesion biopsy demonstrating lesion (B) and hypervascularity with Doppler imaging (C).



**Fig. 3.** Histologic images of excised rectal nodule. Metastatic prostate cancer was identified within the muscularis propria of the rectum (H&E 200x) (A). Tumor cells stained positive for IHC staining with PSA (IHC 200x) (B).

increased to 2.26 ng/mL in approximately 4 months with a PSA doubling-time of 1.9 months. He remained asymptomatic without any weight loss, bone pain, or pelvic pain. Physical exam was notable for a 1 cm palpable but non-obstructing rectal nodule on DRE. Metastatic workup with bone scan, and prostate-specific membrane antigen (PSMA) PET using  $^{18}\text{F}$ DCFPyl showed no distant or nodal metastases, however a PSMA-PET avid 0.9 cm nodule was seen in the left perirectal space (Fig. 1). This lesion was further characterized on MRI and transrectal ultrasound (Fig. 2). Biopsy of the lesion demonstrated poorly differentiated prostate adenocarcinoma in two of two cores, staining strongly positive for PSA. The patient underwent transanal en bloc

excision of the nodule with primary closure of rectal wall using interrupted sutures. Final tumor pathology demonstrated PSA staining, adenocarcinoma consistent with metastatic prostate cancer involving the muscularis propria (Fig. 3), and sites of tumor nearing the inked margin representing either focal positive margin or artifact. Post-operative PSA values at 4 and 7 months declined to 0.02 ng/mL and 0.03 ng/mL respectively.

## 2. Discussion

Transrectal prostate biopsy is the current standard for diagnosing

prostate cancer, with over 1 million performed annually in the US.<sup>1</sup> Needle track seeding after prostate biopsy is a rare complication as only 40 confirmed cases previously reported, with only 9 occurring after transrectal prostate biopsy.<sup>2</sup> Seeding after transperineal prostate biopsy typically presents as a subcutaneous perineal nodule. Alternatively, seeding following transrectal biopsy is often discovered as a nodule on digital rectal exam or during a work up for a post treatment PSA elevation. Evidence of seeding can present within one month and up to 14 years after biopsy. Most nodules are small, though some have been reported up to 4–5 cm<sup>3</sup>. Most cases of post-biopsy prostate cancer seeding have been treated with local excision or radiation.

Several proposed risk factors for seeding include tumor size, grade, biopsy needle type, and biopsy technique, though these remain to be definitively proven.<sup>4</sup> The presence of needle track seeding is thought to portend a worse clinical prognosis, though this finding is mainly observational.<sup>2</sup> It appears that the risk of seeding is higher with the transperineal approach, though these results are confounded by other variables such as needle type, biopsy quantity, tumor histology, and era in which the biopsy was performed. In addition, trans-perineal nodules are usually more clinically apparent than rectal nodules and this finding may influence a reporting bias. In our case, the seeded lesion was discovered during workup for persistent PSA elevation post-prostatectomy.

Given the recent advantages of ultrasensitive PSA and improved imaging capabilities for detecting biochemical recurrence in prostate cancer, it is possible that more future cases of local recurrence from prostate biopsy seeding may be detected. While CT and bone scintigraphy have limited sensitivity for detecting sites of biochemical recurrence at lower PSA levels, PSMA PET has shown increased accuracy and sensitivity for detecting biochemical recurrence, especially at lower PSA levels.<sup>5</sup> Localizing sites of biochemical recurrence, especially in the case of needle track seeding, may lead to earlier detection and more focused therapy. The use of restaging imaging, including PSMA PET in our case, highlights its ability to accurately identify a site of biochemical persistence and to enable treatment of a solitary lesion before metastases develop.

### 3. Conclusion

This case provides an example of surgical management of a local prostate cancer implant. This rare report of needle track seeding of prostate cancer in the rectal wall underscores the importance of restaging and re-imaging patients with biochemical recurrence of prostate cancer. This patient was successfully treated with local excision and was likely spared the potential morbidity of salvage therapy.

### Author statement

E Matthew DiLizia: Writing- Original and final draft preparation, Visualization. Michael Ahdoot: Conceptualization, Writing- Original and final draft preparation. Michael Daneshvar: Writing- Final draft preparation, reviewing and editing. Patrick T. Gomella: Project administration, Writing- Reviewing and editing. Nitin K. Yerram: Project administration, Writing- Reviewing and editing. Peter, Peter A. Pinto: Supervision, Project administration, Writing- Reviewing and editing.

### Declaration of competing interest

The authors declare that they have no known competing financial interests or personal relationships that could have appeared to influence the work reported in this paper.

### References

1. Loeb S, Vellekoop A, Ahmed H. Systematic review of complications of prostate biopsy. *Eur Urol.* 2013;64:876–892.
2. Volanis D, Neal D, Warren A, Gnanapragasam V. Incidence of needle-tract seeding following prostate biopsy for suspected cancer: a review of the literature. *BJU Int.* 2015;115(5).
3. Burkholder G, Kaufman J. Local implantation of carcinoma of the prostate with percutaneous needle biopsy. *J Urol.* 1966;95:801–804.
4. Moul J, Miles B, Skoog S, McLeod D. Risk factors for perineal seeding of prostate cancer after needle biopsy. *J Urol.* 1989;142(1):86–88.
5. Grubmuller B, Baltzer P, D'Andrea D. 68Ga-PSMA 11 ligand PET imaging in patients with biochemical recurrence after radical prostatectomy – diagnostic performance and impact on therapeutic decision-making. *Eur J Nucl Med Mol Imag.* 2018;45: 235–242.