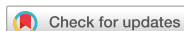

## Review Article



# Epithelial ovarian cancer: a review of preoperative imaging features indicating suboptimal surgery

Soo Young Jeong ,<sup>1</sup> Tae-Joong Kim ,<sup>1</sup> Byung Kwan Park <sup>2</sup>

<sup>1</sup>Department of Obstetrics & Gynecology, Samsung Medical Center, Sungkyunkwan University School of Medicine, Seoul, Korea

<sup>2</sup>Department of Radiology, Samsung Medical Center, Sungkyunkwan University School of Medicine, Seoul, Korea



Received: Feb 14, 2020

Revised: Mar 5, 2020

Accepted: Mar 8, 2020

### Correspondence to

Byung Kwan Park

Department of Radiology, Samsung Medical Center, Sungkyunkwan University School of Medicine, 81 Irwon-ro, Gangnam-gu, Seoul 06351, Korea.

E-mail: rapark@skku.edu  
1436park@gmail.com

Copyright © 2020. Asian Society of Gynecologic Oncology, Korean Society of Gynecologic Oncology

This is an Open Access article distributed under the terms of the Creative Commons Attribution Non-Commercial License (<https://creativecommons.org/licenses/by-nc/4.0/>) which permits unrestricted non-commercial use, distribution, and reproduction in any medium, provided the original work is properly cited.

### ORCID iDs

Soo Young Jeong   
<https://orcid.org/0000-0001-8789-901X>  
Tae-Joong Kim   
<https://orcid.org/0000-0002-9693-9164>  
Byung Kwan Park   
<https://orcid.org/0000-0002-4114-8859>

### Conflict of Interest

No potential conflict of interest relevant to this article was reported.

### Author Contributions

Conceptualization: P.B.K.; Writing - original draft: J.S.Y., K.T.J., P.B.K.; Writing - review & editing: J.S.Y., K.T.J., P.B.K.

## ABSTRACT

Epithelial ovarian cancer has been traditionally treated with cytoreductive surgery and chemotherapy. Optimal surgery is the key to improving the prognosis, and, thus, preoperative imaging should be carefully assessed to determine if the involvement of gastrointestinal, vascular, or thoracic surgeons is necessary to achieve this. Consequently, gynecologists should be able to recognize which imaging features suggest optimal or suboptimal resection. The aim of this review was to present the preoperative imaging features indicating suboptimal resection of epithelial ovarian cancer.

**Keywords:** Epithelial Ovarian Cancer; Multidetector Computed Tomography; Magnetic Resonance Imaging

## INTRODUCTION

Epithelial ovarian cancer is the second most common gynecologic cancer in the USA and has the highest mortality rate [1]. This tumor is frequently detected in advanced stages because the patients are asymptomatic in the early stage [2-5]. Accordingly, tumor prognosis depends on the use of cytoreductive surgery and chemotherapy [6,7]. To achieve optimal cytoreductive surgery, it is crucial for gynecologists to assess and recognize preoperative imaging features [8] so that they can identify not only metastasis but also adhesion or invasion, which could influence optimal resection. The recent development of imaging modalities enables gynecologists to easily understand anatomical and functional information for the detection and determination of the extent of the tumor [9-11].

If gynecologists cannot recognize the imaging features suggesting incomplete resection preoperatively, they end up doing nothing but keeping the patient's abdomen open until gastrointestinal surgeons, vascular surgeons, or urologists come to intervene. Therefore, identifying tumor adhesion or invasion is crucial so that they can know which other surgeons will be involved in the procedure. However, most radiologic reports that illustrate imaging features of ovarian cancer mainly focus on the differential diagnoses [12-16], and very few reports illustrate computed tomography (CT) or magnetic resonance imaging (MRI) features suggesting incomplete resection.

The aim of this review was to present preoperative imaging features that indicates suboptimal resection of epithelial ovarian cancer.

## IMAGING FEATURES INDICATIVE OF INCOMPLETE RESECTION

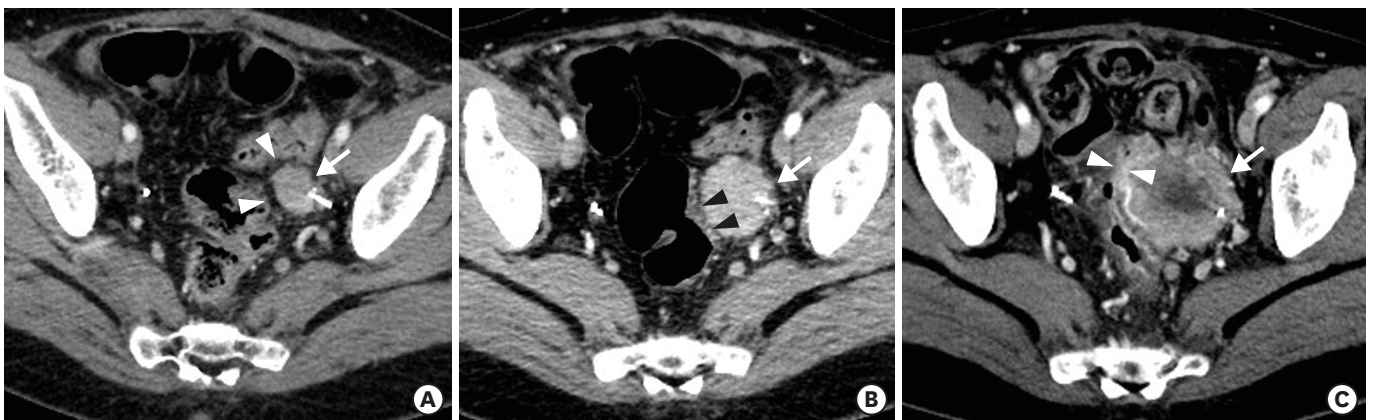### 1. Bowel adhesion or invasion

The obliteration of a fat layer between a tumor and the bowel is a common imaging finding that suggests adhesion (**Fig. 1**). Fat tissue is hypoattenuating on a CT scan and is hyperintense on T1- and T2-weighted images. Previous surgical treatment, radiation therapy, and pelvic inflammation frequently obliterate the fat plane between the tumor and the bowel.

Radiation therapy or post-surgical inflammation may increase the attenuation of fat tissue, suggesting that it becomes hard due to the accumulation of inflammatory cells, such as neutrophils, lymphocytes, and fibroblasts. Accordingly, adhesion may exist even if the fat plane is not obliterated between the tumor and the bowel. Radiologists may frequently miss this imaging feature because the tissue plane still remains between the bowel and the tumor.

A disruption of the bowel layers is a direct sign of tumor invasion (**Fig. 1**). International Federation of Gynecology and Obstetrics staging only accepts bowel invasion in cases where mucosa involvement is identified by endoscopy. However, although serosa or muscular layers are invaded, an ovarian tumor may not be entirely removed. Thus, gastrointestinal surgeons should be involved to achieve optimal resection and to avoid bowel perforation. Some investigators have reported that deeper bowel wall invasion is not associated with a worse surgical outcome if all tumors are clearly removed and that serosa or muscular involvement is not significantly different from mucosa involvement [17-19]. Other studies have reported that mucosal invasion provides poorer prognosis or disease-free survival than invasion into other layers [20,21].

A tumor projecting into the bowel lumen on CT images or MRI indicates mucosa involvement, and this is the most significant finding to diagnose bowel invasion. In cases



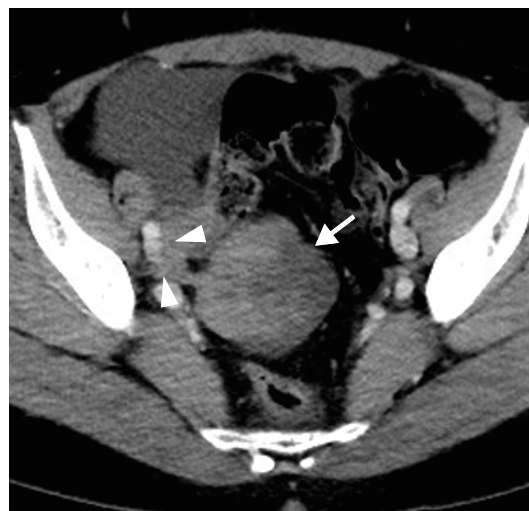**Fig. 1.** Bowel adhesion and invasion in a 58-year-old woman. (A) Contrast-enhanced axial CT image shows recurrent ovarian cancer (arrow) in the sigmoid mesocolon. Arrowheads indicate a preserved fat plane between the tumor and the sigmoid colon. (B) A contrast-enhanced axial CT image taken 3 months later shows the fat plane (arrowheads) obliterated or hyperattenuating, suggesting tumor adhesion to the bowel. An arrow indicates the recurrent ovarian tumor. (C) A contrast-enhanced axial CT image taken 3 months later shows the tumor invading the muscular layer (arrowheads) of the sigmoid colon. An arrow indicates the recurrent ovarian tumor. CT, computed tomography.

of mucosal involvement on CT images or MRI, an endoscopy is definitely unnecessary in patients who have gastrointestinal bleeding, such as hematemesis, melena, or hematochezia.

An ovarian tumor that obstructs the bowel loop is also suggestive of bowel invasion. In most cases, tumors surround bowel loops circumferentially. However, it should be kept in mind that bowel obstruction may also be caused by many kinds of benign conditions, such as adhesion, ischemia, infarct, or inflammation.

## 2. Vascular adhesion or invasion

Obliteration of a fat layer is also a common imaging finding suggesting vascular adhesion. In these cases, a hypoattenuating or hyperintense fat layer on CT imaging or MRI is not observed between the tumor and the vessels. Previous histories of lymph node dissection, radiation therapy, and retroperitoneal fibrosis increase the likelihood of vascular adhesion. Because radiation therapy decreases the thickness of the fat layer or increases fat attenuation, ovarian tumors frequently stick to the vessels. Moreover, a progressed tumor becomes rock hard after metastatic lymph nodes are irradiated. For this reason, even vascular surgeons experience difficulty in peeling out a recurrent tumor following radiation therapy. A large tumor makes a fat layer very thin, giving the appearance of vascular adhesion or invasion. Extraluminal encasement or abutment of the major vessels is one of the patterns that suggest vascular invasion [22]. Disruption or thickening of a pelvic peritoneal layer helps to diagnose vascular adhesion or invasion (**Fig. 2**). Normal pelvic peritoneal layer is difficult to see on CT. However, it becomes thick by seeding cancers and then easily visible on CT images. Moreover, vessel distortion or collapse and tumor encasement are good signs suggestive of vascular invasion (**Fig. 2**) [22,23]. Tumor-to-vessel angle is also an important factor to determine whether there is vascular invasion. Generally, more than 180° indicates vascular invasion, but we need to concern another factors such as surgeon skill, tumor hardness, inflammatory change, contact length, and so on.



**Fig. 2.** Vascular invasion in a 48-year-woman. Contrast-enhanced axial CT image showing metastatic cancer (arrow) in the pelvic cavity. The smaller tumor (arrowheads) is encasing the right external iliac vessels, suggesting vascular invasion. A laterally-pointed arrowhead also indicates that peritoneum becomes thick by cancer spread. CT, computed tomography.

The presence of tumor thrombi is the most significant finding indicating venous invasion [24,25], and enhancement is the key finding to differentiate between malignant and benign thrombi. Malignant thrombi tend to enhance well, whereas benign thrombi do not. Circumferential encasement or vascular collapse also indicate vascular invasion.

### 3. Bladder adhesion or invasion

It is not uncommon for seeding ovarian tumors to invade the urinary bladder, which has a relatively thick muscle layer. When bladder layers are obliterated by adjacent tumors, bladder invasion is strongly suggested (**Fig. 3**). Disruption of the normal bladder wall architecture is a characteristic sign of bladder invasion [26], and, thus, endoscopy is unnecessary because the urothelium is intact. Therefore, preoperative CT or MRI is important to avoid bladder injury during the surgery. Muscular layer is best depicted on T2-weighted images and shows intermediate signal intensity. Accordingly, obliterated or thin muscle layer is one of imaging features suggesting suboptimal resection.

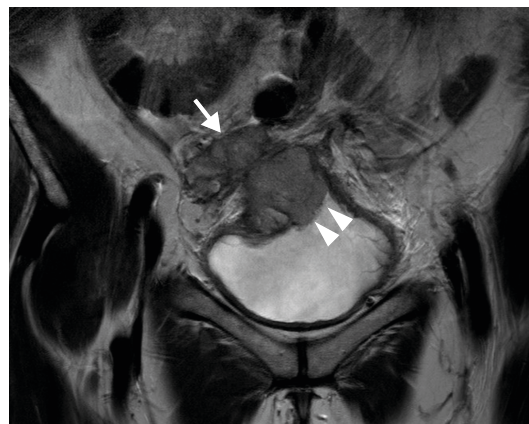Preservation of the normal fat plane between the tumor and bladder excludes stage IVA cancer [27]. Appropriate preparation is important since this anatomic plane is difficult to assess in patients with an overdistended bladder. The presence of bladder mucosa edema does not indicate mucosal involvement [28-31].

When a focal mass projects into the bladder lumen, it is a definite sign of bladder invasion. This situation does not require an endoscopy to confirm the bladder invasion, especially in patients who have hematuria.

MRI is superior to CT in assessing bladder invasion because of high soft-tissue contrast. T2-weighted imaging is the best MRI sequence to delineate bladder wall architecture, and the axial or sagittal planes are good to detect bladder invasion.

### 4. Diffuse thickening of the small bowel

Serosal deposits are difficult to detect on CT or MRI, particularly if bowel distention is inadequate. However, diffuse serosal infiltration, focal nodules, segmental mural thickening, and a well-defined mass are imaging features indicating the involvement of both the



**Fig. 3.** Bladder invasion in a 48-year-old woman. T2-weighted coronal MRI showing a seeding cancer (arrow) invading the bladder dome in which the low signal intensity (arrowheads) of the wall is disrupted. MRI, magnetic resonance imaging.

serosa and the adjacent mesentery [32]. Bowel obstruction is a final sign of carcinomatous involvement and precludes optimal debulking [33,34]. Therefore, it is one of the indications for neoadjuvant chemotherapy [35].

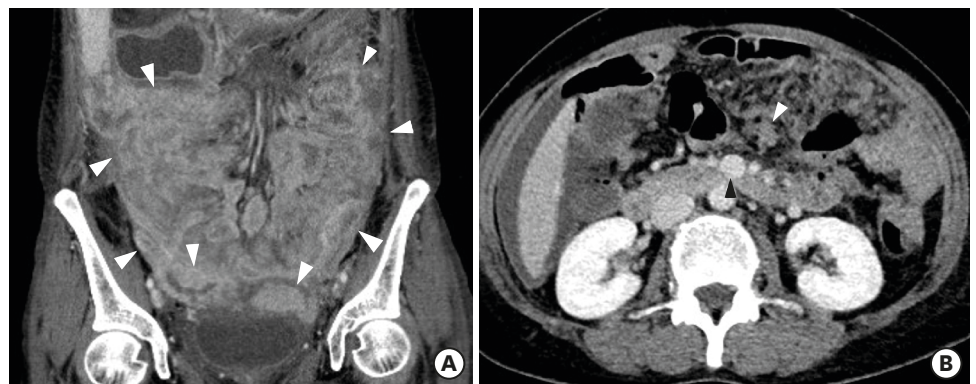
Ovarian cancer may seed along the small bowel wall, making it diffusely thick (Fig. 4). A segmental involvement can be treated with resection and anastomosis by gastrointestinal surgeons, but surgical correction of long or multifocal involvement is impossible. Extensive small bowel resections lead to a high risk of postoperative functional complications [36]. Great care should be taken not to miss this finding because bowel wall thickening is frequently undetected when it is equivocal. The obliteration of the serosa line and a thick wall is the most frequent finding suggestive of diffuse thickening of the small bowel.

MRI is reported to be superior to CT in assessing small bowel or mesenteric involvement because of superior soft-tissue contrast [37]. However, active peristalsis may result in motion artifacts in the MRI, making CT superior to MRI in patients with active peristalsis. CT or MRI frequently underestimates bowel or mesenteric involvement compared with surgical exploration [38].

Three imaging planes according to axial, coronal, and sagittal dimensions should be carefully evaluated to reduce misinterpretation errors resulting from false negative or positive findings. Multi-detector CT scans are now more available and can provide three imaging planes with data set obtained from a single-phase CT scan. Therefore, gynecologists need to ask radiologists to make sagittal and coronal reformat images on every CT scan.

### 5. Poorly-accessible tumor locations

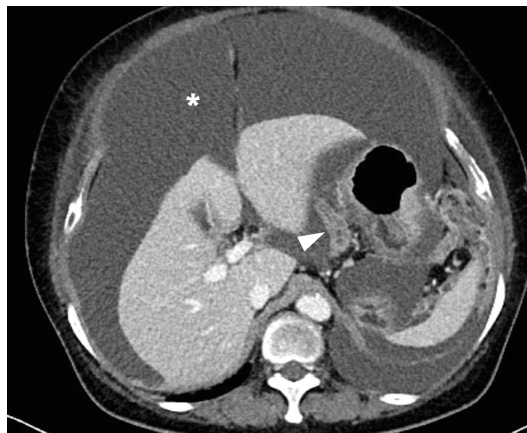
Recent studies have reported that a threshold diameter of 1 cm is most commonly used for acceptable residual disease because it is well correlated with good prognosis and long-term survival [39,40]. If a lesion diameter of <1 cm remains, it is considered acceptable residual disease, defined as optimal cytoreduction. Some surgeons routinely perform aggressive resections of metastatic ovarian cancer in the liver, spleen, and bowel [36,39,41]. Others have reported that this approach is associated with high morbidity, delayed chemotherapy, and poor life quality [42]. Reportedly, neoadjuvant chemotherapy and debulking surgery are not inferior to debulking surgery and adjuvant chemotherapy in terms of disease-free survival



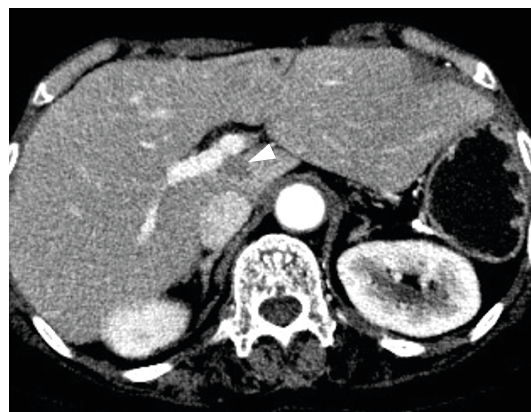**Fig. 4.** Diffuse small bowel thickening in a 55-year-old woman. (A) Contrast-enhanced coronal CT image shows multiple seeding tumors along the small bowel loops, in which the walls are diffusely thick (arrowheads). (B) Contrast-enhanced axial CT image shows a seeding cancer (white arrowhead) adjacent the superior mesenteric vein (black arrowhead). CT, computed tomography.

[43-46]. However, this debate is still ongoing, and preoperative selection is important in advanced ovarian cancer with a substantial tumor burden. As a result, preoperative imaging provides gynecologists with useful features to determine what is and is not resectable [47].

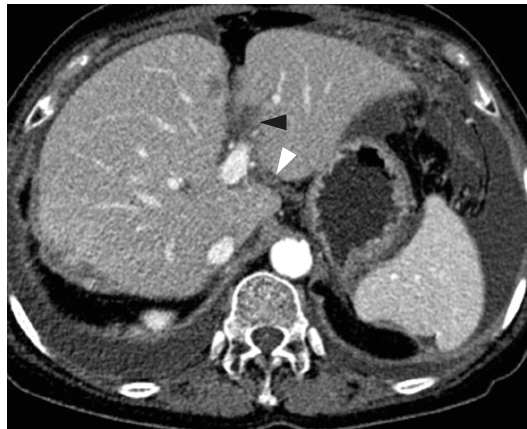Poorly-accessible tumor locations are mainly determined by surgical skill and experience. Therefore, there are no clearly established surgical criteria for indicating inoperable disease and no generally accepted consensus of optimal cytoreduction. Many papers have reported tumor locations such as the mediastinum, lesser sac (**Fig. 5**), mesentery root (**Fig. 4**), pleura, porta hepatis (**Fig. 6**), and fissure for ligamentum venosum or ligamentum teres (**Fig. 7**) [32,47-49]. If ovarian tumors metastasize to these locations, it is difficult for gynecologists alone to perform optimal cytoreductive surgery, and thoracic or general surgery is necessary to determine that the tumors have been completely resected. Therefore, preoperatively assessing CT imaging or MRI is crucial to formulate a surgical plan with other surgeons.



**Fig. 5.** Lesser sac metastasis in a 62-year-old woman. Contrast-enhanced axial CT image shows a metastatic cancer (arrowhead) in the lesser sac. A large amount of ascites (asterisk) is seen in the upper abdomen. CT, computed tomography.



**Fig. 6.** Porta hepatis metastasis in a 61-year-old woman. Contrast-enhanced axial CT image shows a metastatic cancer (arrowhead) in the porta hepatis. The tumor is invading the caudate lobe of the liver. Because it was not surgically correctable, it was treated with percutaneous radiofrequency ablation. CT, computed tomography.



**Fig. 7.** Liver fissure metastases in a 66-year-old woman. Contrast-enhanced axial CT image shows two metastatic cancers in the major liver fissures. Black and white arrowheads indicates cancer foci in the fissures for ligamentum teres and venosum, respectively. CT, computed tomography.

## CONCLUSION

In patients with epithelial ovarian cancer, preoperative imaging examinations can provide important radiologic features to show tumor adhesion or invasion to critical organs and poorly-accessible tumor locations in which there is a high risk of suboptimal debulking. Therefore, careful evaluation of imaging features is a key to determine whether or not the involvement of other surgeons is necessary to achieve optimal resection. Furthermore, due to improvements and new developments in imaging tools and software, radiologists need to report any imaging features that indicate suboptimal resection.

## REFERENCES

1. Siegel RL, Miller KD, Jemal A. Cancer statistics, 2018. *CA Cancer J Clin* 2018;68:7-30.  
[PUBMED](#) | [CROSSREF](#)
2. Holschneider CH, Berek JS. Ovarian cancer: epidemiology, biology, and prognostic factors. *Semin Surg Oncol* 2000;19:3-10.  
[PUBMED](#) | [CROSSREF](#)
3. Tognon G, Carnazza M, Ragnoli M, Calza S, Ferrari F, Gambino A, et al. Prognostic factors in early-stage ovarian cancer. *Ecancermedicalscience* 2013;7:325.  
[PUBMED](#) | [CROSSREF](#)
4. van der Burg ME, van Lent M, Buyse M, Kobierska A, Colombo N, Favalli G, et al. The effect of debulking surgery after induction chemotherapy on the prognosis in advanced epithelial ovarian cancer. *N Engl J Med* 1995;332:629-34.  
[PUBMED](#) | [CROSSREF](#)
5. Leffers N, Gooden MJ, de Jong RA, Hoogbeem BN, ten Hoor KA, Hollema H, et al. Prognostic significance of tumor-infiltrating T-lymphocytes in primary and metastatic lesions of advanced stage ovarian cancer. *Cancer Immunol Immunother* 2009;58:449-59.  
[PUBMED](#) | [CROSSREF](#)
6. Hoskins WJ, Bundy BN, Thigpen JT, Omura GA. The influence of cytoreductive surgery on recurrence-free interval and survival in small-volume stage III epithelial ovarian cancer: a Gynecologic Oncology Group study. *Gynecol Oncol* 1992;47:159-66.  
[PUBMED](#) | [CROSSREF](#)
7. Sioulas VD, Schiavone MB, Kadouri D, Zivanovic O, Roche KL, O'Cearbhaill R, et al. Optimal primary management of bulky stage IIIC ovarian, fallopian tube and peritoneal carcinoma: are the only options

- complete gross resection at primary debulking surgery or neoadjuvant chemotherapy? *Gynecol Oncol* 2017;145:15-20.  
[PUBMED](#) | [CROSSREF](#)
8. Forstner R, Meissnitzer M, Cunha TM. Update on imaging of ovarian cancer. *Curr Radiol Rep* 2016;4:31.  
[PUBMED](#) | [CROSSREF](#)
  9. Azaïs H, Uzan C, Canlorbe G, Thomassin-Naggara I. Which preoperative imaging for nodal status assessment in ovarian cancer? *J Gynecol Obstet Hum Reprod* 2020;49:101726.  
[PUBMED](#) | [CROSSREF](#)
  10. Roze JF, Veldhuis WB, Hoogendam JP, Verheijen RHM, Scholten R, Zweemer RP. Prognostic value of radiological recurrence patterns in ovarian cancer. *Gynecol Oncol* 2020;157:606-12.  
[PUBMED](#) | [CROSSREF](#)
  11. Stein EB, Hansen JM, Maturen KE. Fertility-sparing approaches in gynecologic oncology: role of imaging in treatment planning. *Radiol Clin North Am* 2020;58:401-12.  
[PUBMED](#) | [CROSSREF](#)
  12. Jung SE, Lee JM, Rha SE, Byun JY, Jung JI, Hahn ST. CT and MR imaging of ovarian tumors with emphasis on differential diagnosis. *Radiographics* 2002;22:1305-25.  
[PUBMED](#) | [CROSSREF](#)
  13. Jeong YY, Outwater EK, Kang HK. Imaging evaluation of ovarian masses. *Radiographics* 2000;20:1445-70.  
[PUBMED](#) | [CROSSREF](#)
  14. Laing FC, Allison SJ. US of the ovary and adnexa: to worry or not to worry? *Radiographics* 2012;32:1621-39.  
[PUBMED](#) | [CROSSREF](#)
  15. Marko J, Marko KI, Pachigolla SL, Crothers BA, Mattu R, Wolfman DJ. Mucinous neoplasms of the ovary: radiologic-pathologic correlation. *Radiographics* 2019;39:982-97.  
[PUBMED](#) | [CROSSREF](#)
  16. Wagner BJ, Buck JL, Seidman JD, McCabe KM. From the archives of the AFIP. Ovarian epithelial neoplasms: radiologic-pathologic correlation. *Radiographics* 1994;14:1351-74.  
[PUBMED](#) | [CROSSREF](#)
  17. Mert I, Kumar A, Torres D, Huang Y, McGree ME, Weaver AL, et al. Should mucosal bowel invasion in ovarian cancer be assigned to FIGO stage IV disease? *Gynecol Oncol* 2019;153:238-41.  
[PUBMED](#) | [CROSSREF](#)
  18. Kim M, Suh DH, Park JY, Paik ES, Lee S, Eoh KJ, et al. Survival impact of low anterior resection in patients with epithelial ovarian cancer grossly confined to the pelvic cavity: a Korean multicenter study. *J Gynecol Oncol* 2018;29:e60.  
[PUBMED](#) | [CROSSREF](#)
  19. Kumar A, Torres D, McGree M, Weaver A, Cliby W. Depth of bowel invasion in ovarian cancer is not associated with worse outcomes. *Gynecol Oncol* 2019;154:e20-1.  
[CROSSREF](#)
  20. Di Giorgio A, Cardi M, Biacchi D, Sibio S, Accarpio F, Ciardi A, et al. Depth of colorectal-wall invasion and lymph-node involvement as major outcome factors influencing surgical strategy in patients with advanced and recurrent ovarian cancer with diffuse peritoneal metastases. *World J Surg Oncol* 2013;11:64.  
[PUBMED](#) | [CROSSREF](#)
  21. Park JY, Seo SS, Kang S, Lee KB, Lim SY, Choi HS, et al. The benefits of low anterior en bloc resection as part of cytoreductive surgery for advanced primary and recurrent epithelial ovarian cancer patients outweigh morbidity concerns. *Gynecol Oncol* 2006;103:977-84.  
[PUBMED](#) | [CROSSREF](#)
  22. Xu MS, Li J, Wiseman SM. Major vessel invasion by thyroid cancer: a comprehensive review. *Expert Rev Anticancer Ther* 2019;19:191-203.  
[PUBMED](#) | [CROSSREF](#)
  23. Forstner R. Radiological staging of ovarian cancer: imaging findings and contribution of CT and MRI. *Eur Radiol* 2007;17:3223-35.  
[PUBMED](#) | [CROSSREF](#)
  24. Oka S, Shinohara S, Kuwata T, Takenaka M, Chikaishi Y, Hirai A, et al. The major thoracic vascular invasion of lung cancer. *Ann Med Surg (Lond)* 2017;20:13-8.  
[PUBMED](#) | [CROSSREF](#)
  25. Tomimaru Y, Ishikawa O, Ohigashi H, Eguchi H, Yamada T, Sasaki Y, et al. Intraductal papillary-mucinous carcinoma of the pancreas with tumor thrombus in the portal vein: a report of two cases. *Hepatogastroenterology* 2007;54:1585-8.  
[PUBMED](#)



26. Baughman WC, Corteville JE, Shah RR. Placenta accreta: spectrum of US and MR imaging findings. *Radiographics* 2008;28:1905-16.  
[PUBMED](#) | [CROSSREF](#)
27. Otero-García MM, Mesa-Álvarez A, Nikolic O, Blanco-Lobato P, Basta-Nikolic M, de Llano-Ortega RM, et al. Role of MRI in staging and follow-up of endometrial and cervical cancer: pitfalls and mimickers. *Insights Imaging* 2019;10:19.  
[PUBMED](#) | [CROSSREF](#)
28. Sala E, Rockall AG, Freeman SJ, Mitchell DG, Reinhold C. The added role of MR imaging in treatment stratification of patients with gynecologic malignancies: what the radiologist needs to know. *Radiology* 2013;266:717-40.  
[PUBMED](#) | [CROSSREF](#)
29. Nougaret S, Lakhman Y, Vargas HA, Colombo PE, Fujii S, Reinhold C, et al. From staging to prognostication: achievements and challenges of MR imaging in the assessment of endometrial cancer. *Magn Reson Imaging Clin N Am* 2017;25:611-33.  
[PUBMED](#) | [CROSSREF](#)
30. Nougaret S, Horta M, Sala E, Lakhman Y, Thomassin-Naggara I, Kido A, et al. Endometrial cancer MRI staging: updated guidelines of the European Society of Urogenital Radiology. *Eur Radiol* 2019;29:792-805.  
[PUBMED](#) | [CROSSREF](#)
31. Meissnitzer M, Forstner R. MRI of endometrium cancer - how we do it. *Cancer Imaging* 2016;16:11.  
[PUBMED](#) | [CROSSREF](#)
32. Nougaret S, Addley HC, Colombo PE, Fujii S, Al Sharif SS, Tirumani SH, et al. Ovarian carcinomatosis: how the radiologist can help plan the surgical approach. *Radiographics* 2012;32:1775-800.  
[PUBMED](#) | [CROSSREF](#)
33. Dvoretzky PM, Richards KA, Angel C, Rabinowitz L, Beecham JB, Bonfiglio TA. Survival time, causes of death, and tumor/treatment-related morbidity in 100 women with ovarian cancer. *Hum Pathol* 1988;19:1273-9.  
[PUBMED](#) | [CROSSREF](#)
34. Dvoretzky PM, Richards KA, Angel C, Rabinowitz L, Stoler MH, Beecham JB, et al. Distribution of disease at autopsy in 100 women with ovarian cancer. *Hum Pathol* 1988;19:57-63.  
[PUBMED](#) | [CROSSREF](#)
35. Bogani G, Tagliabue E, Signorelli M, Ditto A, Martinelli F, Chiappa V, et al. A score system for complete cytoreduction in selected recurrent ovarian cancer patients undergoing secondary cytoreductive surgery: predictors- and nomogram-based analyses. *J Gynecol Oncol* 2018;29:e40.  
[PUBMED](#) | [CROSSREF](#)
36. Colombo PE, Mourregot A, Fabbro M, Gutowski M, Saint-Aubert B, Quenet F, et al. Aggressive surgical strategies in advanced ovarian cancer: a monocentric study of 203 stage IIIC and IV patients. *Eur J Surg Oncol* 2009;35:135-43.  
[PUBMED](#) | [CROSSREF](#)
37. Low RN, Semelka RC, Worawattanakul S, Alzate GD. Extrahepatic abdominal imaging in patients with malignancy: comparison of MR imaging and helical CT in 164 patients. *J Magn Reson Imaging* 2000;12:269-77.  
[PUBMED](#) | [CROSSREF](#)
38. Dromain C, Leboulloux S, Auperin A, Goere D, Malka D, Lumbroso J, et al. Staging of peritoneal carcinomatosis: enhanced CT vs. PET/CT. *Abdom Imaging* 2008;33:87-93.  
[PUBMED](#) | [CROSSREF](#)
39. Aletti GD, Dowdy SC, Gostout BS, Jones MB, Stanhope CR, Wilson TO, et al. Aggressive surgical effort and improved survival in advanced-stage ovarian cancer. *Obstet Gynecol* 2006;107:77-85.  
[PUBMED](#) | [CROSSREF](#)
40. Armstrong DK, Bundy B, Wenzel L, Huang HQ, Baergen R, Lele S, et al. Intraperitoneal cisplatin and paclitaxel in ovarian cancer. *N Engl J Med* 2006;354:34-43.  
[PUBMED](#) | [CROSSREF](#)
41. Aletti GD, Podratz KC, Moriarty JP, Cliby WA, Long KH. Aggressive and complex surgery for advanced ovarian cancer: an economic analysis. *Gynecol Oncol* 2009;112:16-21.  
[PUBMED](#) | [CROSSREF](#)
42. Morice P, Dubernard G, Rey A, Atallah D, Pautier P, Pomel C, et al. Results of interval debulking surgery compared with primary debulking surgery in advanced stage ovarian cancer. *J Am Coll Surg* 2003;197:955-63.  
[PUBMED](#) | [CROSSREF](#)
43. Rustin GJ, van der Burg ME, Griffin CL, Guthrie D, Lamont A, Jayson GC, et al. Early versus delayed treatment of relapsed ovarian cancer (MRC OV05/EORTC 55955): a randomised trial. *Lancet* 2010;376:1155-63.  
[PUBMED](#) | [CROSSREF](#)

44. Vergote I, Tropé CG, Amant F, Kristensen GB, Ehlen T, Johnson N, et al. Neoadjuvant chemotherapy or primary surgery in stage IIIC or IV ovarian cancer. *N Engl J Med* 2010;363:943-53.  
[PUBMED](#) | [CROSSREF](#)
45. Vergote IB, De Wever I, Decloedt J, Tjalma W, Van Gramberen M, van Dam P. Neoadjuvant chemotherapy versus primary debulking surgery in advanced ovarian cancer. *Semin Oncol* 2000;27:31-6.  
[PUBMED](#)
46. Vergote I, Amant F, Kristensen G, Ehlen T, Reed NS, Casado A. Primary surgery or neoadjuvant chemotherapy followed by interval debulking surgery in advanced ovarian cancer. *Eur J Cancer* 2011;47 Suppl 3:S88-92.  
[PUBMED](#) | [CROSSREF](#)
47. Qayyum A, Coakley FV, Westphalen AC, Hricak H, Okuno WT, Powell B. Role of CT and MR imaging in predicting optimal cytoreduction of newly diagnosed primary epithelial ovarian cancer. *Gynecol Oncol* 2005;96:301-6.  
[PUBMED](#) | [CROSSREF](#)
48. Lenhard SM, Burges A, Johnson TR, Kirschenhofer A, Bruns C, Linke R, et al. Predictive value of PET-CT imaging versus AGO-scoring in patients planned for cytoreductive surgery in recurrent ovarian cancer. *Eur J Obstet Gynecol Reprod Biol* 2008;140:263-8.  
[PUBMED](#) | [CROSSREF](#)
49. Rema P, John ER, Samabasivan S, Prahladan A, George P, Ranjith JS, et al. Evaluation of computed tomography scan and CA 125 response in predicting operability in advanced ovarian cancer and assessing survival outcome in interval cytoreductive surgery. *Indian J Surg Oncol* 2019;10:426-34.  
[PUBMED](#) | [CROSSREF](#)