

^{99m}Tc -besilesomab (Scintimun®) in peripheral osteomyelitis: comparison with ^{99m}Tc -labelled white blood cells

Wolf S. Richter · Velimir Ivancevic · Johannes Meller · Otto Lang ·
Dominique Le Guludec · István Szilvazi · Holger Amthauer · Florence Chossat ·
Amel Dahmane · Carsten Schwenke · Alberto Signore

Received: 23 August 2010 / Accepted: 4 January 2011 / Published online: 15 February 2011

© The Author(s) 2011. This article is published with open access at Springerlink.com

Abstract

Purpose The diagnosis of osteomyelitis is a challenge for diagnostic imaging. Nuclear medicine procedures including white blood cell imaging have been successfully used for the identification of bone infections. This multinational, phase III clinical study in 22 European centres was undertaken to compare anti-granulocyte imaging using the murine IgG antibody besilesomab (Scintimun®) with ^{99m}Tc -labelled white blood cells in patients with peripheral osteomyelitis.

Methods A total of 119 patients with suspected osteomyelitis of the peripheral skeleton received ^{99m}Tc -besilesomab

and ^{99m}Tc -hexamethylpropyleneamine oxime (HMPAO)-labelled white blood cells (WBCs) in random order 2–4 days apart. Planar images were acquired at 4 and 24 h after injection. All scintigraphic images were interpreted in an off-site blinded read by three experienced physicians specialized in nuclear medicine, followed by a fourth blinded reader for adjudication. In addition, clinical follow-up information was collected and a final diagnosis was provided by the investigators and an independent truth panel. Safety data including levels of human anti-mouse antibodies (HAMA) and vital signs were recorded.

W. S. Richter
Pharmtrace klinische Entwicklung GmbH,
Alt-Moabit 59-61,
10555 Berlin, Germany

W. S. Richter · H. Amthauer
Clinics for Radiology and Nuclear Medicine,
University Clinics Magdeburg,
Leipziger Strasse 44,
39120 Magdeburg, Germany

V. Ivancevic
Nuclear Medicine Celle,
Siemensplatz 4,
29223 Celle, Germany

J. Meller
Department of Nuclear Medicine,
University Medicine (UMG) Göttingen,
Robert-Koch-Str. 40,
37075 Göttingen, Germany

O. Lang
Department of Nuclear Medicine, Charles University,
3rd Medical Faculty, UH Kralovske Vinohrady,
Šrobarova 50,
100 34 Prague, Czech Republic

D. Le Guludec
CHU Bichat-Claude Bernard, Service de Médecine Nucléaire,
46 rue Henri Huchard,
75877 Paris Cedex 18, France

I. Szilvazi
Department of Nuclear Medicine,
Országos Gyógyintézeti Központ,
Szabolcs u. 33,
1135 Budapest, Hungary

F. Chossat · A. Dahmane
IBA/CIS bio international,
BP 32,
91192 Gif sur Yvette Cedex, France

C. Schwenke
SCOSSIS,
Zeltinger Strasse 58 G,
13465 Berlin, Germany

A. Signore (✉)
Nuclear Medicine Unit, “Sapienza” University of Rome,
2nd Faculty of Medicine,
Ospedale S. Andrea, Via di Grottarossa 1035,
00189 Rome, Italy
e-mail: alberto.signore@uniroma1.it

Results The agreement in diagnosis across all three readers between Scintimun® and ^{99m}Tc -HMPAO-labelled WBCs was 0.83 (lower limit of the 95% confidence interval 0.8). Using the final diagnosis of the local investigator as a reference, Scintimun® had higher sensitivity than ^{99m}Tc -HMPAO-labelled WBCs (74.8 vs 59.0%) at slightly lower specificity (71.8 vs 79.5%, respectively). All parameters related to patient safety (laboratory data, vital signs) did not provide evidence of an elevated risk associated with the use of Scintimun® except for two cases of transient hypotension. HAMA were detected in 16 of 116 patients after scan (13.8%).

Conclusion Scintimun® imaging is accurate, efficacious and safe in the diagnosis of peripheral bone infections and provides comparable information to ^{99m}Tc -HMPAO-labelled WBCs.

Keywords Osteomyelitis · Scintimun® · WBC · Imaging · Nuclear medicine

Introduction

The diagnosis of osteomyelitis is a challenge for physicians and diagnostic imaging because of a substantial heterogeneity in its possible clinical presentations. Diagnosis is usually based on a combination of clinical, laboratory and imaging findings. Whereas clinical and laboratory data provide general evidence of an inflammatory process, diagnostic imaging is typically used to detect and document osteomyelitic changes in specific bones or joints.

There is not one single optimal imaging method for patients with suspected osteomyelitis. Instead, the most appropriate imaging modality has to be selected on the basis of the individual strengths and limitations of each imaging approach and depends also on patient-specific factors such as disease history, comorbidity and the location of the suspected disease process. The imaging modalities most widely used in suspected osteomyelitis include X-ray, conventional bone scintigraphy, CT and MRI. While conventional X-ray may show characteristic changes in *later* osteomyelitis, *early* diagnosis is frequently missed, particularly when the inflammatory process is limited to the medullary space of the bone as, e.g. in early haematogenous osteomyelitis [1]. In addition, X-ray diagnosis is considered to be neither sensitive nor specific in the case of suspected prosthetic joint infection [2].

CT may provide useful high-definition images, particularly for peripheral osteomyelitis, whereas MRI has emerged as a promising method for its superior soft tissue contrast and the high anatomical resolution. Limitations of CT and MRI are related to the presence of artefacts in patients after joint replacement and to difficulties regarding the differentiation

between osteomyelitis and other diseases with similar symptoms, e.g. the differentiation between diabetic foot and Charcot neuropathic osteoarthropathy [3–5].

Conventional bone scintigraphy almost always identifies osteomyelitic lesions but is also positive in a wide variety of non-osteomyelitic conditions and, therefore, suffers from a limited specificity. Imaging of white blood cells (WBCs) with scintigraphic methods is used as an adjunct tool to distinguish between infection and sterile inflammation and other disorders in areas that are abnormal on bone scans. The combination of conventional bone scanning and WBC scintigraphy has proven to be a clinically useful approach in patients with suspected osteomyelitis [6].

Different scintigraphic methods are available for WBC imaging. In vitro labelling of WBCs with ^{111}In or ^{99m}Tc is regarded as the gold standard; however, this approach is cumbersome as it requires in vitro separation of WBCs, their radioactive labelling and re-injection of the labelled WBCs into the patient [7–9]. In vitro labelling of WBCs is also associated with infection risks for personnel and patients and a high radiation burden to technicians in charge of the labelling [6]. The recent availability of a closed system device for WBC labelling¹ has greatly reduced these problems, but in vivo labelling of WBCs still represents an attractive alternative to direct in vitro labelling, particularly because it reduces preparation time. The first approach regarding in vivo labelling was the murine IgG1k antibody BW 250/183 (^{99m}Tc -besilesomab, Scintimun®) which recognizes the nonspecific cross-reacting antigen 95 (NCA-95; also referred to as CD66b and CEACAM8) in the cytoplasm and on the cell membranes of granulocytes and granulocyte precursor cells. Radiolabelled besilesomab has been used since 1992 in Switzerland, Hungary, the Czech Republic and Sweden on the basis of local marketing approvals and in Germany (on the basis of individual prescription). Since 1992, an estimated 100,000 patients have been diagnosed with Scintimun® in these countries. In January 2010, Scintimun® was granted a marketing authorization for all European countries by the European Medicines Agency (EMA) for determining the location of infection in peripheral bone in adults with suspected osteomyelitis.

This article reports the results of the recent phase III clinical trial comparing Scintimun® with ^{99m}Tc -hexamethylpropyleneamine oxime (HMPAO)-labelled WBCs in peripheral osteomyelitis. The trial was conducted with the primary aim of evaluating diagnostic concordance between the two techniques and as secondary aims to evaluate the sensitivity, specificity and image quality of Scintimun® and ^{99m}Tc -HMPAO-labelled WBCs in acute and chronic peripheral osteomyelitis.

¹ <http://www.leukokit.com/home.htm>

Materials and methods

Study design

This study was a randomized, open-label, intraindividual comparison, multicentre phase III clinical trial with 22 study centres in Europe (see [Annex](#) for a listing of all study centres). Patients with suspected or documented osteomyelitis were assigned to receive two scintigraphic examinations in random order: one scintigraphy with ^{99m}Tc -besilesomab (Scintimun®) and one scintigraphy with ^{99m}Tc -HMPAO-labelled WBCs. The minimum acceptable interval between the two examinations was 2 days, and the maximum acceptable interval was 4 days.

Study procedures included planar scintigraphic imaging at 4 and 24 h after injection of each radiopharmaceutical, the documentation of vital signs and adverse events, the determination of serum levels of human anti-mouse antibodies (HAMA), and the determination of laboratory values [complete blood count including differential blood count, alanine aminotransferase (ALT), aspartate aminotransferase (AST), gamma-glutamyltranspeptidase (GT), alkaline phosphatase, total bilirubin, conjugated bilirubin, creatinine, non-fasting glucose, chloride, potassium, sodium, total protein, albumin, alkaline reserve, urea, calcium, C-reactive protein (CRP) including the coagulation profile (prothrombin time and activated partial thromboplastin time)]. The primary efficacy variable was the agreement rate of Scintimun® and ^{99m}Tc -HMPAO-labelled WBCs with regard to the diagnosis of infection or sterile inflammation, based on the evaluation of three blinded and independent readers in a central image analysis. Secondary efficacy variables included image quality and sensitivity/specificity/accuracy of the reader's diagnoses using the final assessment of the local investigator as the reference. The final assessment of the investigator was obtained at 1 month after scintigraphic imaging and took into account all available clinical information including data on follow-up and the results of all imaging procedures.

In addition, an independent truth panel reviewed the medical history and the clinical findings of the patients and gave a final assessment on the presence of infection or sterile inflammation and the affected body regions. The truth panel was provided with all relevant clinical information, the results of all diagnostic imaging procedures related to infection (except information about the results of imaging with Scintimun® and ^{99m}Tc -HMPAO-labelled WBCs) and information about the further follow-up of the patients up to 12 months after scintigraphy (where available). The truth panel was composed of three physicians (one nuclear medicine specialist, one radiologist and one orthopaedist). All decisions of the truth panel were derived by consensus. Based on the assessment of the truth

panel, the sensitivity, specificity and accuracy of Scintimun® and ^{99m}Tc -HMPAO-labelled WBCs were calculated as an additional secondary analysis.

The protocol was reviewed and approved by the local and/or central independent Ethics Committees and the responsible regulatory authorities of each study centre. The study was conducted in accordance with all local legal and regulatory requirements, the ethical principles that have their origin in the Declaration of Helsinki, and the International Conference on Harmonisation (ICH) guideline E6 (Good Clinical Practice). Patients were only included in the study after having provided informed consent in writing.

Patients

Male or female patients aged 18 or older could be recruited, provided they presented with suspected or documented osteomyelitis (acute, subacute, chronic) of the peripheral skeleton. Patients with loosening of joint prosthesis and patients with diabetic foot were accepted for the study. All patients had to present with at least one of the following signs or symptoms: localized pain, non-healing skin ulceration, fever above 37.8°C for at least 3 days, leukocyte count in excess of the upper normal limit, erythrocyte sedimentation rate in excess of the upper normal limit, radiographic findings suggestive of osteomyelitis, or positive blood or wound cultures.

Patients were not allowed to enter the study if they were pregnant or breast-feeding, had a history of allergy to mouse proteins, had a history of idiosyncratic reactions to any drug, had a positive HAMA test prior to first study radiopharmaceutical administration, suffered from hereditary fructose intolerance, had suffered from a severe disease or had undergone surgery (except for orthopaedic reasons) within 4 weeks prior to first study radiopharmaceutical administration, or had a leukocyte count below $4 \times 10^9/\text{l}$. Further exclusion criteria included the use of non-steroidal anti-inflammatory drugs and corticosteroids within 3 days prior to first study radiopharmaceutical administration as well as the intake of cancer chemotherapy, immunosuppressive drugs, and immunomodulators within 4 weeks prior to study entry. Patients were not allowed to participate in another study within 1 month prior to screening. No other nuclear medicine diagnostic procedure was accepted within 2 days prior to first study radiopharmaceutical administration.

Scintimun® and ^{99m}Tc -HMPAO-labelled WBCs

Scintimun® (IBA/CIS bio international, Saclay, France) was supplied as a kit containing two types of vials (vial 1 and vial 2). Reconstitution and quality control of the final solution were done according to the procedure described in the Summary of Product Characteristics (SmPC). The radio-

activity dose of Scintimun® was 700–900 MBq (19–24 mCi) per injection (patient) as proposed by the respective guideline of the German Society of Nuclear Medicine. Radiochemical purity (RCP) of Scintimun® was checked prior to injection in all but two patients of the per protocol (PP) population. RCP was above 95% in 116 patients and RCP was below 95% in 1 patient (91.9%). The mean RCP was 97.7%, standard deviation 1.7%, and the median 97.8%.

Ex vivo labelling of WBCs with ^{99m}Tc was performed using Ceretec™ (GE Healthcare, Buc, France). Preparation, labelling and quality control of ^{99m}Tc -HMPAO-labelled WBCs had to follow the procedures described in the SmPC of Ceretec™. Individual trial sites were allowed to deviate from these procedures if validated procedures for WBC labelling were in place at that site for routine diagnostic studies. The radioactivity dose of ^{99m}Tc -HMPAO-labelled WBCs was 250–400 MBq (7–11 mCi) per injection (patient). Labelling efficiency (LE) was assessed in 117 patients of the PP population (2 patients with missing values); the mean value of LE was 61.1% (standard deviation 15.5%, median 61.5%). According to the recent guidelines of the European Association of Nuclear Medicine (EANM) for labelling of leukocytes with ^{99m}Tc -HMPAO, LE is expected to be between 40 and 80% [7].

Scintigraphy

Planar scintigraphic images including anterior and posterior views of the affected body regions (ipsilateral and contralateral) were acquired at 4 and 24 h after each radiotracer administration. Whole-body acquisitions were accepted. The investigator was free to acquire additional views (e.g. lateral views) or to perform single photon emission computed tomography (SPECT). SPECT/CT was never performed. During all acquisitions with both tracers, imaging had to follow the same procedures and the same views were to be obtained. All planar images available were processed for the central blinded read.

A large field of view gamma camera equipped with low-energy high-resolution collimator had to be used. If count rates were low on 24-h images, centres were free to use a low-energy all-purpose (LEAP) collimator for late imaging. For both tracers and all time points, images were to be acquired with either a minimum of 800 kcounts per view or an acquisition time of 15 min. The pulse height analyser of the gamma camera had to be centred at 140 keV with an energy window of 15–20%. Patients had to be studied with the same camera/computer system during Scintimun® and ^{99m}Tc -HMPAO-labelled WBC studies. All images were subjected to a quality assurance procedure at the blinded read core lab to assure consistent quality standards.

Laboratory assessments and safety parameters

Laboratory assessments were obtained before and 24 h after injection of each tracer and included serum chemistry, haematology, inflammation parameters and coagulation profile. A final laboratory assessment was obtained after 1 month. The presence of HAMA in serum was assessed at screening and at days 30 and 90 after Scintimun® scintigraphy using the commercial HAMA-ELISA kit from medac (Hamburg, Germany). Vital signs (blood pressure and heart rate) were assessed before and after each injection (at 5 min, 4 h and 24 h); adverse events were recorded from the first tracer injection until 1 month after injection.

Central (blinded) image analysis

The blinded image analysis was performed in three sessions. During the first session, all patients were shown once to each of three blinded readers. Readers saw either the Scintimun® images or the ^{99m}Tc -HMPAO-labelled WBC images (4- and 24-h images). The readers had to identify areas of infection/inflammation by drawing appropriate regions of interest (ROIs). Furthermore, readers had to assess body segments contralateral to each identified infectious or sterile inflammatory lesion. These contralateral body sides were expected to be normal (unaffected by infection or inflammation) and were required for the calculation of the agreement rate in normal regions and for the calculation of specificity. Further assessments included the level of diagnostic confidence, image quality and the final diagnosis.

The second session was conducted in the same way as the first session; however, the second available image set had to be assessed by the reader (e.g. if Scintimun® images were presented during the first session, ^{99m}Tc -HMPAO-labelled WBC images were presented during the second session). The time interval between reading sessions 1 and 2 was at least 3 weeks to avoid information carryover.

During the third session, a fourth blinded reader evaluated all image pairs (Scintimun® and ^{99m}Tc -HMPAO-labelled WBCs) of each patient with the ROIs drawn by the three blinded readers. The fourth reader had to decide if, for each reader, the sites identified by ROIs on Scintimun® and ^{99m}Tc -HMPAO-labelled WBC images represented the identical area of infection or inflammation. In the same way, this fourth reader had to assess the contralateral body side for identity of assessments.

All blinded readers were certified in nuclear medicine and had experience in scintigraphy of infection or inflammation. The readers were independent and did not participate in the clinical part of the study. During their assessments, all readers were blinded with regard to all

clinical information; the first three readers were also blinded with regard to the tracer.

Statistics

Analyses were performed in the all subjects examined (ASE) population for safety and in the PP population for efficacy. The ASE population consisted of all randomized patients who received at least one of the two study treatments. The PP population consisted of all patients who completed all study procedures including imaging with ^{99m}Tc -HMPAO-labelled WBCs and Scintimun® without major protocol violations. The agreement rate was analysed using a modified adjusted χ^2 test to cover clustered data and multiple measurements per cluster [8]. The limit of clinical relevance was set to 0.7, and agreement between both methods was concluded when the 95% confidence interval (CI) for the agreement rate was positioned above 0.7. For further analyses of efficacy, summary statistics, frequency counts and CIs were computed, as appropriate.

The primary efficacy variable was the agreement rate between Scintimun® and ^{99m}Tc -HMPAO-labelled WBCs calculated as an average across the results of the three blinded readers. For each reader, the agreement rate was calculated after adjudication by the fourth reader taking into consideration all sites identified as affected by infection or sterile inflammation together with the respective segments on the contralateral body side (which were expected to be unaffected by infection or inflammation): (number of agreed affected sites + number of agreed not affected sites) / (total number of all affected and not affected sites)

Continuous data were compared between treatment groups by t test, and categorical data by χ^2 tests. The image quality was compared between the treatment groups by multivariate regression analysis based on generalized estimation equations taking into account the multiple measurements of each image by the three readers. Independence was used as working correlation matrix with a cumulative logit function as link function. Statistical significance was concluded with two-sided p values below 0.05. All calculations were performed with SAS 9.2 (SAS Institute, Cary, NC, USA).

Results

A total of 141 patients were screened for the study. Of these, 121 received both study radiopharmaceuticals, 2 patients received Scintimun® only, 7 patients dropped out before any study radiopharmaceutical administration and 11 patients were screening failures. The ASE population for safety consisted of 123 patients who received at least one of the two study radiopharmaceuticals: 61 in the treatment

sequence “Scintimun® first” and 62 patients in the treatment sequence “ ^{99m}Tc -HMPAO-labelled WBCs first”.

The PP population for efficacy consisted of 120 patients who received both study radiopharmaceuticals and completed all required study procedures including scintigraphic imaging without major protocol violations: 59 patients in the treatment sequence Scintimun® first and 61 patients in the sequence ^{99m}Tc -HMPAO-labelled WBCs first. One patient from the PP population was excluded from the analyses of agreement rates because he was not assessed by one of the three blinded readers. All results reported here refer to 119 patients of the PP population who were assessed by all blinded readers. Details about these 119 patients are summarized in Table 1.

The primary efficacy variable of the study was the agreement rate between Scintimun® and ^{99m}Tc -HMPAO-labelled WBCs after adjudication by the fourth reader. The agreement rate across all readers was 0.83 with a lower limit of the 95% CI at 0.8. The lower limit of the 95% CI was clearly above the predefined level of 0.7 ($p < 0.0001$) and, therefore, the primary objective of study AG-PH3 was met and a clinically relevant and statistically significant agreement between Scintimun® and ^{99m}Tc -HMPAO-labelled WBCs demonstrated. Results for the agreement rate by reader are summarized in Table 2.

In a secondary analysis, the sensitivity and specificity of both tracers were calculated using the final diagnosis of the local investigator at the 1-month follow-up as the reference. For this assessment, the local investigator had to make use of all available clinical information (including Scintimun® and ^{99m}Tc -HMPAO-labelled WBC imaging). The investigator assessment was compared with the results of the blinded read in a patient-based manner, i.e. patients were regarded as positive if at least one lesion was identified in the blinded read (irrespective of the location of the lesion) or negative if no lesion was identified in the blinded read. At the 1-month follow-up, the local investigator rated 73 patients as suffering from infection or sterile inflammation, while 39 were rated as normal. Seven patients were excluded from this analysis because the final assessment of the local investigator was missing. Using the final diagnosis of the local investigator as the reference, Scintimun® had higher sensitivity than ^{99m}Tc -HMPAO-labelled WBCs (74.8 vs 59.0%) and slightly lower specificity (71.8 vs 79.5%) (see Table 3 for detailed results).

An additional patient-based analysis was performed using a truth panel assessment as the reference. The truth panel was provided with all relevant clinical data including 12 months of follow-up information (where available). Information about the results of imaging with Scintimun® and ^{99m}Tc -HMPAO-labelled WBCs was not provided to the truth panel. The truth panel was able to establish a final diagnosis in 74 patients: 41 patients were assessed as

Table 1 Details of 119 patients of the PP population

	Scintimun® first	WBCs first	<i>p</i> value ^a
Total number	59	60	
Men	38 (64%)	35 (58%)	0.4963
Age ^b	62 ± 13	61 ± 16	0.7140
Height ^b	170 ± 10	169 ± 13	0.5120
Weight ^b	84 ± 15	81 ± 18	0.3477
Clinical symptoms			
Localized pain	10 (17%)	7 (12%)	0.4103
Non-healing skin ulceration	39 (66%)	47 (78%)	0.1362
Fever >37.8°C for at least 3 days	57 (97%)	57 (95%)	0.6616
Other clinical symptoms	44 (75%)	50 (83%)	0.2410
Biological signs of infection ^c	28 (47%)	21 (35%)	0.1674
Imaging findings suggestive of infection ^d	28 (47%)	33 (55%)	0.4105
Loosening of joint prosthesis	29 (49%)	33 (55%)	0.5232
Diabetic foot	13 (22%)	12 (20%)	0.7854

^a *p* values of comparisons of groups, *t* test for continuous data, χ^2 test for categorical data

^b Arithmetic mean ± 1 standard deviation

^c Leukocyte count or erythrocyte sedimentation rate above upper limit of normal, or positive blood or wound cultures

^d Imaging includes X-ray, CT, MRI, bone scan and other procedures (but does not include Scintimun® and labelled WBCs)

positive (suffering from infection or sterile inflammation) and 33 were assessed as negative. Also from this analysis, Scintimun® showed higher sensitivity than ^{99m}Tc-HMPAO-labelled WBCs (75.6 vs 62.6%) and slightly lower specificity (68.7 vs 75.8%, respectively).

Microbiological cultures were obtained in 17 patients of the PP population. Of these 17 patients, 7 had infection as proven by a positive microbiological culture. With Scintimun®, all three blinded readers correctly identified six of these patients and missed one (sensitivity across readers 85.7%). With ^{99m}Tc-HMPAO-labelled WBCs, two readers correctly identified four positive patients and one reader correctly identified three positive patients (sensitivity across readers 61.9%).

This phase III study was primarily designed to assess the agreement between Scintimun® and ^{99m}Tc-HMPAO-labelled WBCs regarding infection or inflammation without distinction between those two conditions. In clinical practice, however, a differentiation between infection and sterile inflammation is required because of the different ensuing therapeutic consequences. To address this aspect, an analysis was performed in the subgroup of patients in whom the local investigator was able to make a distinction between sterile inflammation and infection on the basis of the 1-month follow-up. This assessment of the local investigator at 1 month was compared to his assessment obtained directly after each of the two imaging procedures. In total, 34 patients were classified by the local investigator as having an infection and 31 as

having a sterile inflammation. The image interpretation criteria for infection were based on the increase of activity in suspected areas or the increase of size showing uptake with time, by comparing images at 4 and 24 h (Figs. 1 and 2). In this subgroup, Scintimun® had a sensitivity of 47% for correct identification of infection, a specificity of 77% and an overall accuracy of 62%. The respective values for ^{99m}Tc-HMPAO-labelled WBCs were 44% for sensitivity, 87% for specificity and 65% for overall accuracy. The difference between the two radiopharmaceuticals was statistically not significant.

Acute vs chronic infection or inflammation

In 95 patients clinical symptoms started earlier than 6 weeks before inclusion into the study. These patients were classified as suffering from “chronic” disease [9]. In the remaining 24 patients, the onset of clinical symptoms was within 6 weeks before inclusion and these patients were classified as suffering from “acute” disease. The agreement rate between Scintimun® and ^{99m}Tc-HMPAO-labelled WBCs after adjudication by the fourth reader was 0.79 in the chronic group and 0.80 in the acute group. Taking the final diagnosis of the investigator as the reference, Scintimun® exhibited a significantly higher sensitivity than ^{99m}Tc-HMPAO-labelled WBCs in patients with chronic disease. Further details of this analysis are summarized in Table 4.

Table 2 Agreement rate by reader between Scintimun® and ^{99m}Tc-HMPAO-labelled WBCs

	Agreement rate	Standard error	Lower limit of the 95% CI
Reader 1	0.81	0.02	0.76
Reader 2	0.84	0.02	0.79
Reader 3	0.85	0.02	0.80
Across all 3 readers	0.83	0.01	0.80

Table 3 Sensitivity and specificity of Scintimun® and ^{99m}Tc -HMPAO-labelled WBCs using the final diagnosis of the local investigator at the 1-month follow-up as the reference

	Scintimun®		^{99m}Tc -HMPAO-labelled WBCs	
	Sensitivity	95% CI	Sensitivity	95% CI
Reader 1	0.770	0.674; 0.867	0.703	0.598; 0.808
Reader 2	0.757	0.658; 0.855	0.514	0.399; 0.628
Reader 3	0.716	0.613; 0.820	0.554	0.440; 0.668
Across readers	0.748	0.666; 0.829	0.590	0.497; 0.683
	Specificity		Specificity	
	Specificity	95% CI	Specificity	95% CI
Reader 1	0.641	0.575; 0.861	0.667	0.517; 0.817
Reader 2	0.795	0.667; 0.923	0.897	0.801; 0.994
Reader 3	0.718	0.575; 0.861	0.821	0.699; 0.943
Across readers	0.718	0.594; 0.842	0.795	0.703; 0.887

Image quality

During the blinded read, each reader also had to assess the quality of images on a 4-point scale as poor, moderate, good or excellent. The results are summarized in Table 5. The cumulated frequency of good and excellent images was

267 (75%) for Scintimun® and 199 (56%) for ^{99m}Tc -HMPAO-labelled WBCs. The difference in image quality between both tracers was significant (χ^2 test based on a multinomial regression, $p < 0.0001$), although different amounts of radioactivity were injected for the two types of scans.

Fig. 1 A 40-year-old patient presenting with pain in the area of the left tibia. His history included a motorcycle accident almost 4 years earlier with severe trauma of the left body side. WBC imaging was performed to rule out osteomyelitis. The Scintimun® study showed increased uptake in the upper inner part of the left tibia consistent with material infection. The labelled WBC study showed low uptake at 4 h but rather normal images at 22 h. At surgery 4 months after imaging no evidence of infection was found. The truth panel rated this patient as abnormal (suffering from infection or inflammation)

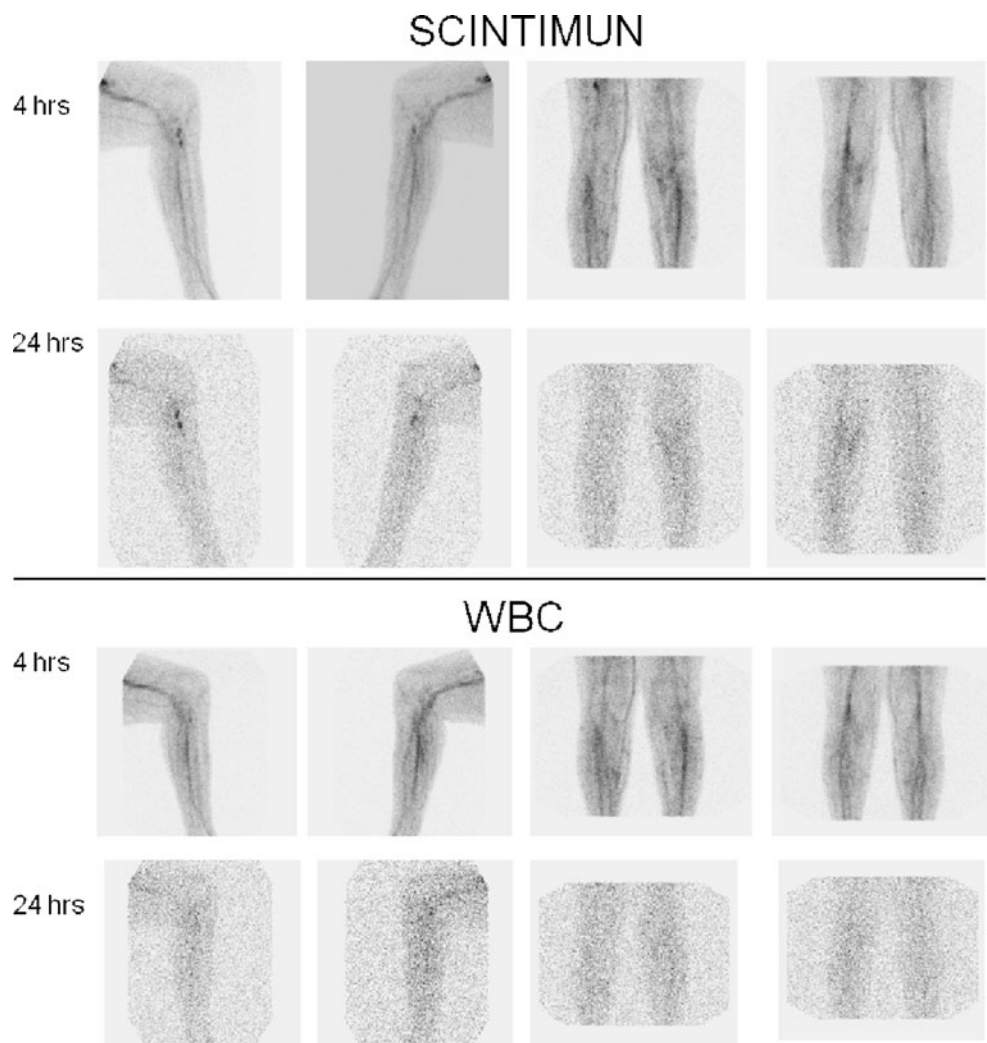


Fig. 2 A 60-year-old diabetic patient admitted for non-healing defect with fistula of the second toe of the right foot with redness and swelling but without fever. Based on the initial clinical examination, osteomyelitis in the right foot was suspected and the patient was admitted to the hospital. Laboratory examinations revealed an elevated CRP; blood leukocytes were normal. Multiresistant *Staphylococcus aureus* was cultivated from the bone biopsy; control cultivation 4 months after antibiotic therapy was negative. Scintimun® and ^{99m}Tc -HMPAO-labelled WBC studies show a lesion of focal increasing uptake of radioactivity with time at the second toe. The uptake at the level of the left metatarsus decreasing with time was detected only by Scintimun® and can be interpreted as sterile inflammation (Charcot osteoarthropathy)

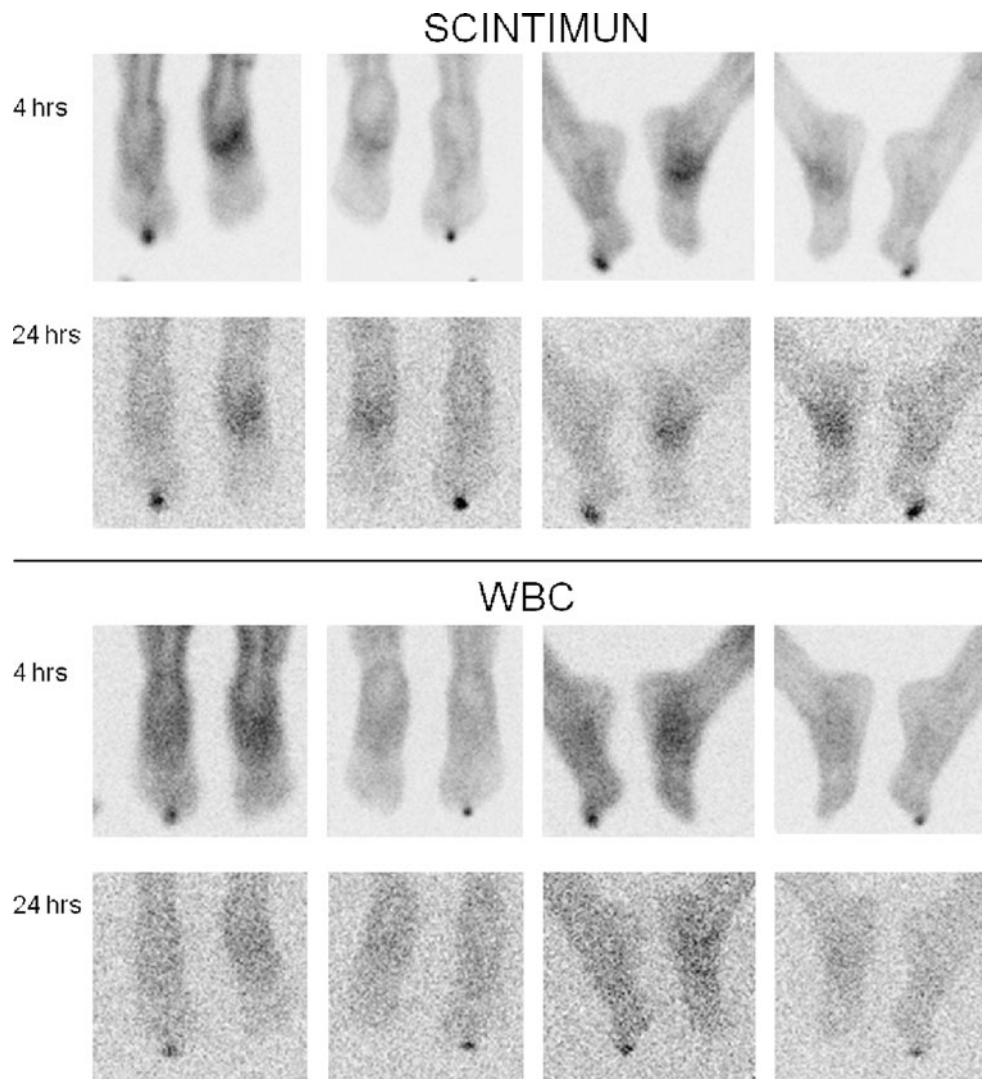


Table 4 Sensitivity and specificity of Scintimun® and ^{99m}Tc -HMPAO-labelled WBCs separately for patients with chronic and acute infection or inflammation

	No. of patients ^a	Scintimun®	^{99m}Tc -HMPAO-labelled WBCs
Sensitivity			
Chronic	60	0.733 (0.638; 0.829)	0.544* (0.440; 0.649)
Acute	13	0.846 ^c	0.821 ^c
Specificity			
Chronic	28	0.726 (0.587; 0.865)	0.774** (0.652; 0.895)
Acute	11	0.697 ^b	0.848 ^b

95% CI shown in parentheses

* $p < 0.05$ vs. Scintimun®; ** $p = \text{n.s.}$ vs Scintimun®

^a Total number of patients with final diagnosis of the investigator is 112 (73 patients positive for infection/inflammation and 39 patients negative for infection /inflammation; 7 patients without final diagnosis by the investigator)

^b CI and significance level not calculated because of low cluster size

Table 5 Image quality as assessed by the three readers

Image quality	Scintimun®	^{99m} Tc-HMPAO-labelled WBCs
Excellent	40 (11%)	13 (4%)
Good	227 (64%)	186 (52%)
Moderate	71 (20%)	110 (31%)
Poor	13 (4%)	41 (11%)
Not evaluable	6 (2%)	7 (2%)
Total no. of assessments	357 (100%) ^a	357 (100%)

^a Total number of assessments is 357: 119 patients assessed by 3 readers

Adverse events

Amongst the 123 patients of the ASE population who received at least one of the two study radiopharmaceuticals, 24 patients (19%) reported a total of 31 adverse events. Of these 31 adverse events, 14 (45%) were related to infectious or inflammatory disease and 2 (6%) were assessed as possibly or probably related to Scintimun® and concerned 2 cases of mild and transient hypotension. Only one patient experienced a serious adverse event during study participation. This patient suffered from necrosis at the level of the metatarsus and was hospitalized for transmetatarsal amputation after completion of scintigraphic imaging. His health condition deteriorated during hospitalization, a gastroscopy revealed haemorrhage of a duodenal ulcer and he finally died from cardiopulmonary failure. This serious adverse event was assessed by the investigator as unrelated to study radiopharmaceuticals.

Laboratory assessments, vital signs and HAMA

Assessment of laboratory parameters was comparable between the two study groups (Scintimun® first and ^{99m}Tc-HMPAO-labelled WBCs first). The majority of abnormal laboratory values was already abnormal before the first injection of study radiopharmaceutical and was related to the inflammatory process. Mean values did not change from baseline after administration of Scintimun® or ^{99m}Tc-HMPAO-labelled WBCs. No effect of Scintimun® or ^{99m}Tc-HMPAO-labelled WBCs on vital signs was detected except in three patients in whom blood pressure decreased after injection of Scintimun®. Two of these cases of hypotension were assessed as possibly or probably related to Scintimun®.

Blood samples for HAMA were collected at screening and twice after injection of Scintimun® (at 1 month and at 3 months). Four patients presented with HAMA levels above 40 µg/l at screening and were not allowed to enter the study (screening failures). Seven patients had no HAMA assessment during follow-up. Consequently, 116 patients had at least one HAMA assessment after administration of Scintimun®. Only 16 of 116 patients (13.8%) became positive with HAMA levels >40 µg/l after Scintimun® administration.

Discussion

The results of this phase III trial show that Scintimun® imaging is accurate, efficacious and safe in diagnosing infection of the peripheral skeleton and provides comparable information to ^{99m}Tc-HMPAO-labelled WBCs. In this study, Scintimun® was more sensitive than ^{99m}Tc-HMPAO-labelled WBCs in patients with microbiologically proven infection of the bone and in patients with chronic osteomyelitis.

The basis of the Scintimun® mechanism of action is its nanomolar affinity to the NCA-95 (CEACAM8, CD66b) antigen, which is found on granulocytes and mature bone marrow cells of the granulocytic lineage [10, 11]. These cells are present in major amounts in inflammatory and infectious lesions and are also found in the haematopoietic bone marrow. The typical uptake pattern of Scintimun® in humans, therefore, includes focal uptake at sites of infection or inflammation as well as a staining of the haematopoietic bone marrow.

Since its introduction into clinical practice in a limited number of European countries almost 20 years ago, the specific accumulation of Scintimun® at sites of infection or inflammation has been studied in various clinical indications. The majority of these studies have been conducted in patients with osteomyelitis. Other indications include endocarditis [12, 13], inflammatory bowel disease [14–17], lung infection [18], the detection of perioperative septic foci [19] and fever of unknown origin [20–22].

The most important clinical indication for Scintimun® imaging is osteomyelitis [23]. In this context, osteomyelitic lesions of the peripheral skeleton and of the central skeleton have to be considered separately. In the peripheral skeleton, osteomyelitic foci are characterized by an increased uptake of Scintimun®. In the central skeleton the typical finding of osteomyelitis is a focally decreased uptake (cold spot) which is based on the displacement of normal bone marrow by the inflammatory process. The finding of a cold spot in the haematopoietic bone marrow of the central skeleton is not specific for osteomyelitis but can also be caused by other processes (e.g. metastases, haemangioma). Inherently, therefore, a reduced specificity of Scintimun® has to be

expected in the central skeleton as has already been reported for ^{99m}Tc -HMPAO-labelled WBCs. This consideration is confirmed by data from Guhlmann et al. who studied 36 patients with suspected chronic osteomyelitis of the peripheral skeleton and 15 patients with suspected chronic osteomyelitis of the central skeleton by combined Scintimun® and conventional bone scintigraphy [24]. Sensitivity was comparable in the central and peripheral skeleton (85 vs 91%, respectively), while specificity was lower in the central skeleton (60 central vs 85% peripheral).

In peripheral osteomyelitis, the results of published studies show that Scintimun® has high sensitivity and specificity. Typically, reported values of sensitivity and specificity in osteomyelitis range between 70 and 90% [18, 24–28]. Reuland et al. [28] studied Scintimun® in 106 patients with suspected peripheral bone infection after surgery. The final diagnosis was obtained by microbiological culture and clinical follow-up information. Sensitivity was highest in the lower leg (100%), followed by thigh (85%), knee (70%) and hip (69%). Specificity ranged between 83 (knee) and 100% (lower leg). The high sensitivity of Scintimun® has been confirmed by Peltier et al. [18] in a small series of eight patients with suspected peripheral osteomyelitis who underwent bone biopsy for final confirmation of disease. All eight patients with osteomyelitis were correctly identified (sensitivity 100%).

Only very limited data are available about an intra-individual comparison of Scintimun® against alternative scintigraphic procedures for imaging of WBCs. This comparison is required to ultimately assess the diagnostic value of Scintimun® against competing methods. This study was primarily designed to provide data about the comparison of Scintimun® with the accepted gold standard for imaging of infection (^{99m}Tc -HMPAO-labelled WBCs).

The results of this trial show that Scintimun® and ^{99m}Tc -HMPAO-labelled WBCs provide comparable clinical information in osteomyelitis. This is the first larger series of patients studied intraindividually with both methods and allows for the first time a direct comparison between Scintimun® and ^{99m}Tc -HMPAO-labelled WBCs.

It is important to mention again that it was not the primary aim of this study to evaluate sensitivity and specificity of the two radiopharmaceuticals. Nevertheless, sensitivity and specificity were calculated for comparative reasons. For the calculation of sensitivity and specificity, a truth panel decision was used as a surrogate for the true gold standard (bone biopsy showing granulocytic accumulation). The resulting values of sensitivity and specificity were slightly lower for both radiopharmaceuticals in this trial than the respective values in the published literature. The reason for the lower values is most probably explained by the very strict and controlled environment of the blinded image evaluation that was used in this trial. All blinded

readers were completely unaware of any clinical information related to the patients. The lack of complementary information represents an artificial situation with limited clinical relevance. It is assumed that imaging with Scintimun® and ^{99m}Tc -HMPAO-labelled WBCs in a clinical environment will have a greater contribution to medical decision-making than implied by the sensitivity and specificity values obtained in this trial. This assumption is in line with results from an earlier phase III trial in 775 patients where Scintimun® was rated by the investigator to supply additional information which was not provided by other diagnostic methods in 31.5% of patients, to assure or confirm a diagnosis already suspected by other diagnostic methods in another 35.7% of patients, and positively influenced the treatment strategy in 35% of patients [29].

Besides providing overall evidence for the good agreement between Scintimun® and ^{99m}Tc -HMPAO-labelled WBCs, this study also points towards specific differences between the two tracers. A subanalysis of patients with acute and chronic osteomyelitis shows that Scintimun® detects chronic osteomyelitis with higher sensitivity than ^{99m}Tc -HMPAO-labelled WBCs. The high sensitivity of Scintimun® in this trial in chronic osteomyelitis is in line with comparable values from the literature. Kaim et al. [25] studied 24 patients with chronic post-traumatic osteomyelitis and reported a sensitivity of 84% and a specificity of 72% of combined Scintimun® imaging and conventional bone scintigraphy. Slightly lower values were published by Boubaker et al. [30] for patients with subacute or chronic infection of hip prosthesis. Their study involved 57 patients and yielded a sensitivity of 67% and a specificity of 75% using microbiological examinations and clinical follow-up as the reference.

The higher sensitivity of Scintimun® compared to ^{99m}Tc -HMPAO-labelled WBCs in chronic osteomyelitis can be explained by two factors: the first factor is related to the higher image quality of Scintimun® which allows discrete increases of tracer uptake to be detected more easily. Chronic osteomyelitis is frequently characterized by a lower disease activity and a lower level of granulocytic accumulation than acute osteomyelitis. A slightly increased uptake in chronic lesions is probably detected more easily in high-quality images. The second factor is related to the presumed uptake mechanism of Scintimun® in osteomyelitic lesions. Uptake of Scintimun® is supposed to involve two components which occur in parallel: (1) targeting of NCA-95 on circulating granulocytes in the bloodstream with subsequent migration of Scintimun®-labelled granulocytes to the inflammatory lesion and (2) transport of free Scintimun® with the bloodstream to sites of infection with subsequent sequestration to the extravascular space due to an increased capillary permeability, followed by specific binding to granulocytes which are present in the extravascular space. The latter mechanism is suggested to be more

important in the clinical situation. Ex vivo labelled WBCs, in contrast to Scintimun®, accumulate in osteomyelitic lesions only on the basis of the first mechanism (migration of labelled cells into the lesion). It is conceivable that the second mechanism (sequestration of the free Scintimun® antibody to sites of infection or inflammation with subsequent binding to granulocytes) contributes to a relevant degree to the accumulation of Scintimun® in chronic lesions. This difference in uptake mechanism may also explain the higher sensitivity of Scintimun® in patients with microbiologically confirmed osteomyelitis.

For clinical purposes, the differentiation between infection and sterile inflammation is of particular relevance for therapy decisions. In clinical practice, an increase in uptake or size over time is typically interpreted as infection, whereas a decrease in uptake or size is assumed to represent sterile inflammation or bone marrow activity. In this study, Scintimun® and ^{99m}Tc-HMPAO-labelled WBCs could be compared with regard to their ability to differentiate infection from sterile inflammation in a subgroup of 65 patients. In these patients, the local investigator was able to obtain a final diagnosis on the basis of follow-up information. In these 65 patients, Scintimun® and ^{99m}Tc-HMPAO-labelled WBCs were equally effective in differentiating between infection and sterile inflammation.

Finally, this study provides the first systematic data about the development of HAMA after injection of Scintimun®. Of 116 patients, 16 developed HAMA after Scintimun® injection and may have a potential risk of hypersensitivity at re-exposure. According to the SmPC² of Scintimun®, determination of HAMA levels is requested before injection of Scintimun® and re-administration to HAMA-positive patients is contraindicated.

With the exception of two cases of mild and transient hypotension, no other parameters related to patient safety (laboratory data, vital signs) provided evidence of an elevated risk associated with the use of Scintimun®. This is in line with the available safety profile which is based on some 100,000 injections and does not identify specific safety risks.

Besides Scintimun® and labelled WBCs, other nuclear medicine methods have also been used for the diagnosis of osteomyelitis. The murine Fab' fragment sulesomab targets NCA-90 (CEACAM6, CD66c) on granulocytes and has shown to be of value in osteomyelitis. However, affinity to granulocytes is lower than the respective values of Scintimun® [31]. Recently, ¹⁸F-fluorodeoxyglucose (FDG) in conjunction with positron emission tomography (PET) has

been used for infection or inflammation imaging. Available results are promising; however, the increased uptake of ¹⁸F-FDG is due to an increased glucose metabolism and in this regard unspecific for infection or inflammation.

In summary, Scintimun® is a promising, efficacious and safe tool for diagnosis of osteomyelitis in the peripheral skeleton.

Conflicts of interest Wolf S. Richter is the managing director of Pharmtrace, a CRO that provides contract research services to IBA/CIS bio international (marketing authorization holder of Scintimun®), Carsten Schwenke provides statistical services to IBA/CIS bio international, Florence Chossat and Amel Dahmane are employees of IBA/CIS bio international. All other authors do not have a conflict of interest.

Open Access This article is distributed under the terms of the Creative Commons Attribution Noncommercial License which permits any noncommercial use, distribution, and reproduction in any medium, provided the original author(s) and source are credited.

Annex: participating sites and principal investigators

Prof. Michèle Allard (CHU Pellegrin, Bordeaux, France); Prof. Dr. H. Amthauer (Charité, Berlin, Germany); Dr. Magdolna Bakos (Békés Megyei Képviselettestület, Pándy Kálmán Kórház, Gyula, Hungary); Prof. Hatem Boulahdour (CHRU Jean Minjoz, Besançon, France); Prof. László Galuska (Debreceni Egyetem Orvos-és Egészségtudományi, Debrecen, Hungary); Prof. Dominique Le Guludec (CHU Bichat-Claude Bernard, Paris, France); Dr. John M. H. de Klerk (Meander Medical Center, Amersfoort, The Netherlands); Dr. Otakar Kraft (UH Ostrava, Ostrava, Czech Republic); Dr. Otto Lang (Charles University, 3rd Medical Faculty, UH Kralovske Vinohrady, Prague, Czech Republic); Dr. Endre Lenart (Bács-Kiskun Megyei Önkormányzat Kórháza, Kecskemet, Hungary); Dr. Isabelle Morelec (CH Civils Lyon Sud, Pierre-Benite, France); Dr. Miroslav Myslivecek (UH Olomouc, Olomouc, Czech Republic); Prof. Christoph H. J. Reiners (Universitätsklinikum Würzburg, Würzburg, Germany); Prof. Sven N. Reske (Universitätsklinikum Ulm, Ulm, Germany); Dr. Frederik Smit (Rijnland Ziekenhuis, Galeiderdorp, The Netherlands); Prof. István Szilvazi (Országos Gyógyintézeti Központ, Budapest, Hungary); Dr. Sarolta Takacs (Budai Irgalmasrendi Hospital, Budapest, Hungary); Dr. Adrienn Tombacz (Heves County, Markhot Ferenc Hospital, Eger, Hungary); Prof. Dr. J. Fred Verzijlbergen (St. Antonius Ziekenhuis, Nieuwegein, The Netherlands); Dr. Jaroslav Vizda (UH Hradec Kralove, Hradec Kralove, Czech Republic); Dr. Petr Vlcek (UH Motol, Prague 5, Czech Republic); Dr. Anthonie Zwijnenburg (Spaarne Ziekenhuis Hoofddorp, The Netherlands).

² http://www.ema.europa.eu/docs/en_GB/document_library/EPAR_-_Product_Information/human/001045/WC500075575.pdf

References

- Concia E, Prandini N, Massari L, Ghisellini F, Consoli V, Menichetti F, et al. Osteomyelitis: clinical update for practical guidelines. *Nucl Med Commun* 2006;27:645–60.
- Love C, Marwin SE, Palestro CJ. Nuclear medicine and the infected joint replacement. *Semin Nucl Med* 2009;39:66–78.
- Chatha DS, Cunningham PM, Schweitzer ME. MR imaging of the diabetic foot: diagnostic challenges. *Radiol Clin North Am* 2005;43:747–59. ix.
- Gnanasegaran G, Chicklore S, Vijayanathan S, O'Doherty MJ, Fogelman I. Diabetes and bone: advantages and limitations of radiological, radionuclide and hybrid techniques in the assessment of diabetic foot. *Minerva Endocrinol* 2009;34:237–54.
- Rozzanigo U, Tagliani A, Vittorini E, Pacchioni R, Brivio LR, Caudana R. Role of magnetic resonance imaging in the evaluation of diabetic foot with suspected osteomyelitis. *Radiol Med* 2009;114:121–32.
- Rojas-Burke J. Health officials reacting to infection mishaps. *J Nucl Med* 1992;33:13N–4N. 27N.
- de Vries EF, Roca M, Jamar F, Israel O, Signore A. Guidelines for the labelling of leucocytes with (99m)Tc-HMPAO. Inflammation/infection Taskgroup of the European Association of Nuclear Medicine. *Eur J Nucl Med Mol Imaging* 2010;37:842–8.
- Schwenke C, Busse R. Analysis of differences in proportions from clustered data with multiple measurements in diagnostic studies. *Methods Inf Med* 2007;46:548–52.
- Termaat MF, Rajmakers PG, Scholten HJ, Bakker FC, Patka P, Haarman HJ. The accuracy of diagnostic imaging for the assessment of chronic osteomyelitis: a systematic review and meta-analysis. *J Bone Joint Surg Am* 2005;87:2464–71.
- Steinsträsser A, Berberich R, Kuhlmann L, Zabori S, Schwarz A. Binding of the monoclonal antibody BW 250/183 to human granulocytes. *Nuklearmedizin* 1992;31:57–63.
- Bosslet K, Steinsträsser A, Schwarz A, Harthus HP, Lüben G, Kuhlmann L, et al. Quantitative considerations supporting the irrelevance of circulating serum CEA for the immunoscintigraphic visualization of CEA expressing carcinomas. *Eur J Nucl Med* 1988;14:523–8.
- Morguet AJ, Munz DL, Ivancević V, Werner GS, Sandrock D, Bökemeier M, et al. Immunoscintigraphy using technetium-99m-labeled anti-NCA-95 antigranulocyte antibodies as an adjunct to echocardiography in subacute infective endocarditis. *J Am Coll Cardiol* 1994;23:1171–8.
- Morguet AJ, Munz DL, Ivancević V, Werner GS, Kreuzer H. The clinical importance of scintigraphy with the murine monoclonal antigranulocyte antibody BW 250/183 for the diagnosis of prosthesis-related endocarditis. *Dtsch Med Wochenschr* 1995;120:861–6.
- Segarra I, Roca M, Baliellas C, Vilar L, Ricart Y, Mora J, et al. Granulocyte-specific monoclonal antibody technetium-99m-BW 250/183 and indium-111 oxine-labelled leucocyte scintigraphy in inflammatory bowel disease. *Eur J Nucl Med* 1991;18:715–9.
- Papos M, Nagy F, Narai G, Rajtar M, Szantai G, Lang J, et al. Anti-granulocyte immunoscintigraphy and [99mTc]hexamethylpropyleneamine-oxime-labeled leukocyte scintigraphy in inflammatory bowel disease. *Dig Dis Sci* 1996;41:412–20.
- Almers S, Granerus G, Franzén L, Ström M. Technetium-99m scintigraphy: more accurate assessment of ulcerative colitis with exametazime-labelled leucocytes than with antigranulocyte antibodies. *Eur J Nucl Med* 1996;23:247–55.
- Tarján Z, Tóth G, Györke T, Mester A, Karlinger K, Makó EK. Ultrasound in Crohn's disease of the small bowel. *Eur J Radiol* 2000;35:176–82.
- Peltier P, Potel G, Lovat E, Baron D, Chatal JF. Detection of lung and bone infection with anti-granulocyte monoclonal antibody BW 250/183 radiolabelled with 99Tcm. *Nucl Med Commun* 1993;14:766–74.
- Kroiss A, Sporn P, Auinger C, Redl E, Böck F, Dinstl K, et al. Immunoscintigraphy for detection of inflammatory perioperative foci. *Acta Med Austriaca* 1993;20:45–9.
- Becker W, Dölkemeyer U, Gramatzki M, Schneider MU, Scheele J, Wolf F. Use of immunoscintigraphy in the diagnosis of fever of unknown origin. *Eur J Nucl Med* 1993;20:1078–83.
- Meller J, Ivancevic V, Conrad M, Gratz S, Munz DL, Becker W. Clinical value of immunoscintigraphy in patients with fever of unknown origin. *J Nucl Med* 1998;39:1248–53.
- Gratz S, Behr TM, Herrmann A, Meller J, Conrad M, Zappel H, et al. Immunoscintigraphy (BW 250/183) in neonates and infants with fever of unknown origin. *Nucl Med Commun* 1998;19:1037–45.
- Graute V, Feist M, Lehner S, Haug A, Müller PE, Bartenstein P, et al. Detection of low-grade prosthetic joint infections using (99m) Tc-antigranulocyte SPECT/CT: initial clinical results. *Eur J Nucl Med Mol Imaging* 2010;37:1751–9.
- Guhlmann A, Brecht-Krauss D, Suger G, Glatting G, Kotzerke J, Kinzl L, et al. Fluorine-18-FDG PET and technetium-99m antigranulocyte antibody scintigraphy in chronic osteomyelitis. *J Nucl Med* 1998;39:2145–52.
- Kaim A, Maurer T, Ochsner P, Jundt G, Kirsch E, Mueller-Brand J. Chronic complicated osteomyelitis of the appendicular skeleton: diagnosis with technetium-99m labelled monoclonal antigranulocyte antibody-immunoscintigraphy. *Eur J Nucl Med* 1997;24:732–8.
- Kroiss A, Böck F, Perneczky G, Auinger C, Weidlich G, Kleinpeter G, et al. Immunoscintigraphy for the detection of inflammation foci in bone and joint diseases. *Wien Klin Wochenschr* 1990;102:713–7.
- Hotze AL, Briele B, Overbeck B, Kropp J, Gruenwald F, Mekki MA, et al. Technetium-99m-labeled anti-granulocyte antibodies in suspected bone infections. *J Nucl Med* 1992;33:526–31.
- Reuland P, Winker KH, Heuchert T, Ruck P, Müller-Schauenburg W, Weller S, et al. Detection of infection in postoperative orthopedic patients with technetium-99m-labeled monoclonal antibodies against granulocytes. *J Nucl Med* 1991;32:2209–14.
- Steinsträsser A, Oberhausen E. Granulocyte labelling kit BW 250/183—results of the European multicenter trial. *Nuklearmedizin* 1996;35:1–11.
- Boubaker A, Delaloye AB, Blanc CH, Dutoit M, Leyvraz PF, Delaloye B. Immunoscintigraphy with antigranulocyte monoclonal antibodies for the diagnosis of septic loosening of hip prostheses. *Eur J Nucl Med* 1995;22:139–47.
- Becker W, Bair J, Behr T, Repp R, Streckenbach H, Beck H, et al. Detection of soft-tissue infections and osteomyelitis using a technetium-99m-labeled anti-granulocyte monoclonal antibody fragment. *J Nucl Med* 1994;35:1436–43.