


Reproductive fitness of honey bee queens exposed to thiamethoxam during development

Veterinary Pathology
2021, Vol. 58(6) 1107-1118
© The Author(s) 2021



Article reuse guidelines:
sagepub.com/journals-permissions
DOI: 10.1177/03009858211031845
journals.sagepub.com/home/vet



Ivanna V. Kozii¹ , Sarah Barnsley¹, Marina Carla Bezerra da Silva¹, Sarah C. Wood¹, Colby D. Klein¹, Igor M. de Mattos¹, Michael W. Zabrodski¹, Roney de C. M. Silva¹, Claudia I. O. Fabela¹, Leland Guillemin¹, Ihor Dvylyuk¹, Maud C. O. Ferrari¹, and Elemir Simko¹

Abstract

The productivity and survival of honey bee (*Apis mellifera*) colonies depend on queen bee health. Colony-level neonicotinoid exposure has negative effects on reproductive fitness of honey bee queens. However, it is unclear if the observed effects are a direct outcome of neonicotinoid toxicity or result from suboptimal care of developing queens by exposed workers. The aim of this study was to evaluate larval survival, reproductive fitness, and histopathology of honey bee queens exposed to incremental doses (0, 5, 50 ng) of the neonicotinoid thiamethoxam (THI) applied directly to individual late larvae (7 days post-oviposition) of queens. The 5 ng dose represents a calculated high environmental level of exposure for honey bee queen larvae. Morphometric evaluation revealed that the total area of mandibular gland epithelium in queens exposed to 5 and 50 ng THI was reduced by 14% ($P = .12$) and 25% ($P = .001$), respectively. Decreased mandibular gland size may alter pheromone production, which could in part explain previously observed negative effects of THI on the reproductive fitness of queens. We also found that late larval exposure to THI reduced larval and pupal survival and decreased sperm viability in mated queens. These changes may interfere with queen development and reproductive longevity.

Keywords

Apis mellifera, bees, queens, development, mandibular gland, neonicotinoids, insecticides, thiamethoxam, ovary

Honey bees (*Apis mellifera*) provide essential ecosystem services through pollination, in addition to producing and collecting a number of valuable hive products, including honey, pollen, wax, propolis, and royal jelly. Recent declines in honey bee populations raise great concerns over their survival and the sustainability of services they provide.²⁹ The causes of honey bee declines are thought to be multifactorial and include, *inter alia*, intensification of modern agricultural practices, spread of infectious and parasitic diseases, decreased genetic diversity, and poor queen quality.^{22,25}

The increase in honey bee mortality has coincided with the introduction and widespread use of neuroactive neonicotinoid insecticides. Neonicotinoids are systemic insecticides that are effective against a wide range of insect pests, yet are much safer for mammals compared to previously used plant-protection products.²⁷ Thiamethoxam (THI) was the first of the second-generation neonicotinoids introduced to the world market as a more potent alternative to imidacloprid, the first neonicotinoid brought to the market.¹⁶ THI remains widely used around the world,²⁷ including the Canadian prairies¹⁷ where the current study was conducted. Of note, the average THI

concentration in honey from central Saskatchewan, Canada,³ is 59 times greater than the global average of 0.29 ng/g.¹⁹ Previous research has shown that exposure to environmental doses of THI has negative effects on worker honey bees, including reduced adult survival, foraging efficiency, and homing success¹¹; altered motor function³⁵; decreased disease resistance³³; and increased larval and pupal mortality.³² Additionally, a growing body of literature suggests neonicotinoids have adverse effects on the honey bee queen and drone reproductive fitness, resulting in decreased genetic diversity within the colony.^{7,8,30}

¹University of Saskatchewan, Saskatoon, Saskatchewan, Canada

Supplemental material for this article is available online.

Corresponding Author:

Ivanna V. Kozii, Department of Veterinary Pathology, Western College of Veterinary Medicine, University of Saskatchewan, 52 Campus Drive, Saskatoon, Saskatchewan, Canada S7N 5B4.

Email: ivanna.kozii@usask.ca

The honey bee queen is the only reproductively active female in the colony. The queen's development from an egg to an adult lasts 16 days and is the shortest among all 3 castes (21 days for workers and 24 days for drones; Suppl. Table S1). Both workers and queens develop from fertilized eggs, with larvae hatching 3 days post-oviposition. Queens develop from larvae that are exclusively fed royal jelly throughout their development by attending workers. Queen larvae are individually sealed off with a wax cap (capped) between days 8 and 9 post-oviposition; the larvae pupate (the transition from larval state to pupal state) within the capped (sealed) queen cells. Adult queens emerge on day 16 post-oviposition. A short glossary table describing common beekeeping terms is provided in Supplemental Table S2.

The effect of neonicotinoids on developing queens has predominantly been evaluated on individuals raised in colonies exposed to neonicotinoids through syrup and/or pollen patty. For example, Forfert et al⁷ and Williams et al³⁹ exposed honey bee colonies to 4 ppb (4 ng/g) THI and 1 ppb (1 ng/g) clothianidin (CLO) through pollen patties over 36 days; the queens raised in these colonies had reduced sperm count and sperm viability, reduced number of ovarioles, and mated with fewer drones on average. Similarly, colonies exposed to pollen patties spiked with 5 ppb (5 ng/g) THI and 2 ppb (2 ng/g) CLO over 46 days had decreased adult and brood population sizes and were at higher risk of post-overwintering queen failures.²⁶ These studies demonstrate the association between neonicotinoid exposure at the colony level and reduced queen quality; however, it is unclear if the observed changes are due to the primary effects of neonicotinoids on individual queens or secondary effects resulting from exposed workers providing suboptimal care to developing and adult queens.

There are very few studies in which individual honey bee queen larvae were directly exposed to THI. In one such study, exposed queens had reduced emergence rate, body weight, and mating success.⁹ Furthermore, Walsh et al³⁷ reported that honey bee queens raised in wax comb contaminated with pesticides had altered composition of their mandibular gland pheromones and decreased attractiveness to workers. The mandibular glands of honey bees are bilaterally symmetrical glands located in the head. These glands are largest in the honey bee queen compared to workers and drones.²⁸ In queens, mandibular glands produce queen pheromones—the main queen signaling chemicals in the hive; these pheromones are vital for homeostasis of the entire colony.

Previous colony-level and individual queen exposure studies suggest that neonicotinoids reduce reproductive fitness of honey bee queens; however, the underlying cause or mechanism of these effects has not been investigated. Therefore, the objectives of the current study were to (1) determine the effects of direct exposure of queens to THI during pupation (which is the period of main organogenesis) and (2) determine the mechanism of these effects by histopathological evaluation focused predominantly on mandibular glands and ovaries.

Materials and Methods

The experiments were conducted from June to August 2018 at the University of Saskatchewan research apiary (52°07'38.4"N 106°36'35.4"W). The experiment was performed twice (experiment A started on June 6, 2018; experiment B started on August 3, 2018) using 2 genetic lines for queen production. Queens were produced through artificial transfer of worker larvae, a process referred to as "grafting" in beekeeping practice (Suppl. Table S2).⁴ All colonies involved in the experiment were maintained in accordance with the Saskatchewan Apiaries Act.³⁴

Rearing of Queens

Experimental queens were reared by standard beekeeping procedures⁴ to generate 7-day-old queen larvae of synchronized age that were exposed to experimental treatment (described below) to determine their survival (capping and emergence rate) and effects on mating success and reproductive fitness. The queens were placed into 3-frame nucleus (small) colonies 2 days before emergence for 3 weeks to allow natural mating. Detailed description of the queen rearing procedure and mating nucleus set up is provided in Supplemental Tables S2 and S3.

Treatment Doses and Exposure

Three treatment groups were used in this study. Queen larvae were exposed to 4 μ l of distilled water containing 0 ng, 5 ng, or 50 ng THI comprising the control, low-dose (theoretical high level of environmental contamination), and high-dose (positive control—unrealistically high dose) groups, respectively. The treatments were administered by pipetting 4 μ l of the test solution directly into the royal jelly bed of each queen cell at day 7 post-oviposition. The environmentally relevant 5 ng dose was calculated based on the total amount of royal jelly consumed by a queen larva during development estimated at 1.5 g,¹⁰ the published maximum THI contamination level in Saskatchewan pollen of 250 ng/g³, and the reported 1% transfer rate of the neonicotinoid imidacloprid from pollen patties to royal jelly.⁶ The estimated 3.75 ng per larva exposure (1.5 g \times 2.5 ng/g) was then rounded up to 5 ng to account for potential underestimation of queen food consumption and contamination, and to better correlate our study with previously published work.⁹ The queen cells on each grafting frame were randomized into treatment groups.

The grafting procedure and queen rearing were performed twice with different genetic lines (experiment A and experiment B). Overall, 158 queen larvae were used in the 2 studies. In experiment A, a total of 91 queen larvae were tested, of which 29 were in the control group, 26 in the 5 ng group, and 36 in the 50 ng group. In experiment B, a total of 67 queens were tested, of which 18 were in control group, 25 in the 5 ng group, and 24 in the 50 ng group.

Evaluation of Capping and Survival Rate During Development

After treatment (day 7 post-oviposition), the experimental queen cells were monitored daily for capping success and pupal survival until day 14 post-oviposition when they were transferred to mating nuclei. The capping rate was defined as the percentage of the treated queen cells that were capped at day 9 post-oviposition (2 days posttreatment). Any uncapped cells at day 9 were removed by the worker bees in the colony as part of their normal “cleaning” behavior; therefore, empty cells at day 9 (representing uncapped cells) were considered “dead” in the survival analysis. Capped queen cells which were subsequently removed by worker bees during pupation (until day 14 post-oviposition) were also considered “dead” in the survival analysis.

Honey Bee Queen Weight and Sperm Evaluation

Between 22 and 26 days post-emergence, mated honey bee queens were collected and examined in cohorts of 9 to 12 queens per day representing an equal proportion of treatments. The queens were caught into queen cages (Mann Lake Ltd) with 4 attendant worker bees from their mating nucleus. All mated queens from experiment B were weighed using a Sartorius Scale (BP121S, Data Weight Systems, Inc). The spermatheca was removed from each queen,² and the contents mixed in 1 ml of semen extender diluent.¹² Sperm viability was evaluated in 100 μ l of each sample using SYBR 14 dye and propidium iodide (Live/Dead Viability Kit, Life Technologies). A minimum of 10 fields at 200 \times magnification (10 \times ocular magnification and 20 \times objective), or at least a total of 200 sperm heads, were counted in each sample. For total sperm count, the spermatheca content from each queen, already diluted in 1 ml of semen extender diluent, was further diluted 1:16 in modified Kiev buffer (sodium citrate 24.3, sodium bicarbonate 2.1, potassium chloride 0.4, sulfanilamide 0.3, glucose 3.0 g/l for all). The sperm was counted using Neubauer hemocytometer following standard procedure.² The queen tissues that remained after extraction of the spermatheca were fixed in 10% neutral buffered formalin for histopathological evaluation.

Histopathology and Morphometric Evaluation

Initial comparative histopathological evaluation of multiple organs of mated queens exposed to different doses of neonicotinoids during development did not reveal any unequivocal differences between groups. Nevertheless, there was a subjective impression that the queens exposed to high doses had hypoplastic mandibular glands surrounded by a reduced number of fat cells and potentially had increased apoptotic rate in the germarium portion of the ovaries.

Accordingly, we performed morphometric histopathological evaluation of serial sections of these 2 organs stained with Harris' hematoxylin and eosin (H&E), and compared the

Table 1. Mean (\pm SEM) number of histologic sections examined for mandibular gland epithelium and lumen, peri-mandibular fat body, and optic lobe.

	0 ng	5 ng	50 ng
Mandibular gland epithelium	29.5 \pm 2.2	29.3 \pm 2.0	27.0 \pm 1.5
Mandibular gland lumen	26.8 \pm 2.4	26.3 \pm 2.3	25.3 \pm 1.5
Peri-mandibular fat body	29.5 \pm 2.2	29.0 \pm 2.2	26.9 \pm 1.4
Optic lobe	11.3 \pm 1.2	11.1 \pm 1.2	11.1 \pm 0.6

results between treatment groups. The total area of mandibular gland epithelium, mandibular gland lumen, and peri-mandibular fat body were identified in serial tissue sections stained with H&E and compared between treatment groups. The total area of the bilateral optic lobes of the brain was also used as an internal control.

The queen heads, fixed in 10% buffered formalin, were removed from the body. The exoskeleton from vertex (immediately behind the ocelli) to the most caudodorsal aspect of the lower jaw was removed via sharp dissection prior to processing, to allow better paraffin penetration during processing and to prevent sectioning artifact caused by the chitinous exoskeleton. The heads were processed according to standard histologic tissue processing procedures and embedded in paraffin blocks for sectioning. The orientation of the heads in the block was such that the mandible laid flat at the surface of the block and the ocelli and antennae were embedded deepest in the block; accordingly, the first sections included the musculature of the lower jaw and caudal portion of the head, whereas the last sections included the most cranial head sections. Five-micrometer-thick serial sections were collected every 25 μ m for histologic evaluation. Prepared slides were first dried at 65 $^{\circ}$ C for 1 hour, then manually stained using H&E.³¹

All slides containing sections of mandibular glands or optic lobes were photographed using a microscope digital camera (Infinity 5, Lumenera Scientifica) and analyzed with image analysis software (Image-Pro Premier 9.1, Media Cybernetics, Inc). The total area of mandibular gland epithelium, mandibular gland lumen, peri-mandibular fat body, and optic lobe were determined in serial H&E-stained sections (Fig. 11) of 4 queen heads per treatment, per experiment (A and B) (4 queens \times 3 treatment groups \times 2 replicate studies = 24 queens total or 8 queens per treatment).

To calculate total mandibular gland area, the glandular epithelium of both glands (right and left) on each section was outlined manually, and subsequently, the area was detected and measured by the image analysis software. The same procedure was repeated for mandibular gland lumen, peri-mandibular fat body, and the optic lobe. The mean (\pm SEM) number of sections examined is provided in Table 1. There was no statistically significant difference in the number of sections examined between treatment groups for any of the parameters (glandular epithelium $F_{2,21} = 0.5$, glandular lumen $F_{2,21} = 0.1$, optic lobes $F_{2,21} = 0.005$, fat body $F_{2,21} = 0.5$; $P > .05$ for all).

Morphometric Histopathologic Evaluation of Ovary

Number of Apoptotic Cells in Germarium. The ovaries from 4 queens from each treatment group from both experiments (4 queens \times 3 treatment groups \times 2 replicate experiments = 24 queens total or 8 queens per treatment) were removed from the abdomen of formalin-fixed queens with previously removed spermatheca. The fixed ovaries were subjected to standard histological tissue processing and subsequently embedded in paraffin blocks in a vertical position so that the proximal portion of the ovary, including the terminal filament and germarium, could be sectioned first in cross sections.

The proximal 1.5 mm of the embedded ovary (encompassing the entire terminal filament, germarium, and cranial vitellarium¹⁴) was serially sectioned. Specifically, for each step, 30 consecutive 5- μ m-thick sections were cut, of which the first 10 sections were collected on a glass slide, stained with H&E, and examined, whereas the following 20 sections were discarded. In this way, we obtained for each queen 10 glass slides containing 10 serial consecutive cross sections of cranial ovary which were 100 μ m apart (Suppl. Fig. S1).

All 10 cross sections on a single slide were examined by a blinded pathologist (MS) to identify one cross section with the least sectioning artifact and, subjectively, the greatest surface area of the germarium. Up to 4 images of germarium were captured from each of the identified best sections using a microscope digital camera (Olympus DP71, Olympus). Accordingly, 15 to 37 (average 26.5) images of the cross section of the ovary containing germarium of each queen were captured. The 12 best sections/images that contained the largest area of germanium for each queen were used for quantification of apoptotic rate by a blinded pathologist (MS) (Fig. 18). The area of the germarium was outlined and measured using image analysis software (Image-Pro Premier 9.1, Media Cybernetics, Inc) and the apoptotic cells were enumerated. Apoptotic cells were defined as cells with hypereosinophilic cytoplasm and condensed, hyperbasophilic, fragmented nuclei. The apoptotic rate was expressed as number of apoptotic cells per 1 mm² of germarium.

Total Ovariole Count. The last section (most caudal) of the ovary acquired from the serial sections described above was used for counting the total number of ovarioles in each ovary. The evaluated sections were approximately 1.5 mm deep from the proximal end of the ovary and were mainly composed of cross sections of the vitellarium and some germarium (Fig. 16). Each oocyte or trophocyte cluster in cross section was counted as a separate ovariole. The data were analyzed as the total ovariole count per both ovaries.

Statistical Analysis

Mating and capping success were analyzed with a χ^2 test and queen survival was compared using Kaplan-Meier survival analysis. The mating data from experiments A and B were analyzed together ($n = 15/\text{treatment}$). Queen weight was

analyzed with one-way ANOVA. Total sperm count was compared between treatment groups using a Kruskal-Wallis test as the data were not normally distributed (Shapiro-Wilk test, $W_{65} = 0.96$, $P = .03$).⁴²

Sperm viability data were assessed for mathematical and biological outliers. A total of 3 outliers were removed from the analysis: one from the control group with a sperm viability of 9%, and 2 from the 50 ng THI group with a sperm viability of 6% and 11%, respectively. These sperm viability scores are outliers from the sperm evaluation data of our lab and the currently published literature. We believe these low scores were likely due to a manual error during sample preparation for fluorescent evaluation.⁴²

A 3 \times 2 ANOVA was used to evaluate the effect of neonicotinoid treatment and time of the experiment (June vs August) on sperm viability and ovarian apoptotic rate. Similarly, a 2-way MANOVA was used to compare the size of mandibular gland epithelium, mandibular gland lumen, peri-mandibular gland fat body, and optic lobes. The time of the experiment had no significant effect on the evaluated outcomes and therefore was removed from the analysis (sperm viability: $F_{2,59} = 0.7$, $P = .5$; gland, fat body and optic lobe area: Wilk's L, $F_{8,30} = 0.3$, $P = .97$). Tukey tests were used for post hoc comparisons. Residual plots were evaluated to ensure the assumptions for the ANOVA were met.⁴² The data analyzed in this study are available as Supplemental Table S4.

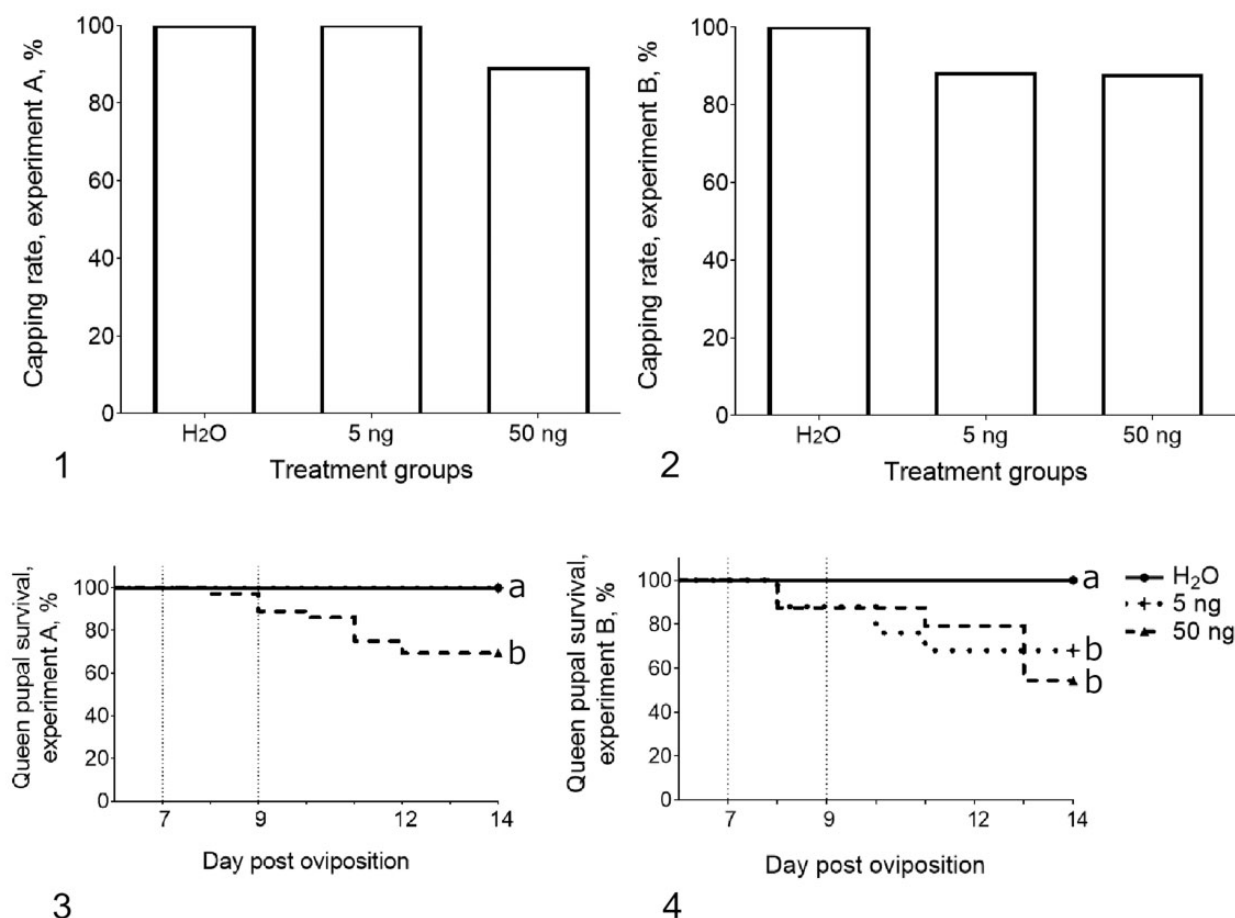
Results

Capping Rate

The overall queen capping rate was negatively affected by high-dose THI treatment in experiment A (likelihood ratio $\chi^2 = 7.7$, $df = 2$, $P = .02$, $n = 91$; Fig. 1), with a capping success of 100% in control (29/29) and low THI (26/26) groups, dropping to 89% (32/36) in the high THI group. In experiment B, we saw a similar drop in capping rate from 100% in the control group (18/18) to 88% (22/25) and 87% (21/24) in the low and high THI groups, respectively; however, this effect of THI treatment on capping rate in experiment B was not statistically significant ($\chi^2 = 4.0$, $df = 2$, $P = .14$, $n = 67$; Fig. 2).

Survival

The overall survival of queens from exposure (day 7 post-oviposition) until day 14 of development was negatively affected by treatment in both experiments A and B (A: $\chi^2 = 19.5$, $df = 2$, $P < .001$; B: $\chi^2 = 9.5$, $df = 2$, $P = .009$; Figs. 3, 4). While the survival of the queens in the control group in both experiment A (29/29) and B (18/18) was 100%, the queens exposed to 50 ng THI had a 31% (25/36) and 46% (13/24) reduction in overall survival in experiments A and B, respectively, compared to controls (multiple pair-wise comparison, A: Control vs 50 ng, $\chi^2 = 10.4$, $P = .001$; B: Control vs 50 ng, $\chi^2 = 10.6$, $P = .001$). Survival of queens in the 5 ng group was only significantly



Figures 1–4. Capping and survival rate of honey bee queen larvae and pupae exposed to 0, 5, or 50 ng of thiamethoxam (THI). **Figure 1.** Capping rate of treated larvae at day 9 of development was overall negatively affected in experiment A (June) ($\chi^2 = 7.7$, $df = 2$, $P = .02$, $n = 91$); however, multiple comparisons were not significant (control vs 50 ng, $P = .06$; 5 ng vs 50 ng, $P = .08$). **Figure 2.** Capping rate was not affected by treatment in experiment B (August) ($\chi^2 = 4.0$, $df = 2$, $P = .14$, $n = 67$), which is likely the result of a smaller sample size in experiment B ($n = 67$) compared to experiment A ($n = 91$). **Figure 3.** Queen pupal survival decreased by 31% (25/36 queens) in experiment A in the 50 ng THI group ($P = .001$). **Figure 4.** In experiment B, queen pupal survival was reduced by 32% (17/25) in the 5 ng group ($P = .009$) and by 46% (13/24) in the 50 ng ($P = .001$) group. Different letters indicate statistically significant differences between treatment groups ($P \leq .05$).

decreased in experiment B (5 ng vs Control, $\chi^2 = 6.8$, $P = .009$), whereas all queens exposed to 5 ng THI in experiment A survived. Similar statistically significant differences in survival between treatment groups in the 2 experiments remained when analysis was limited to post-capping (pupal) survival (day 9 through day 14 of development) (A: Control vs 50 ng, $\chi^2 = 7.0$, $P = .008$; B: Control vs 50 ng, $\chi^2 = 8.3$, $P = .004$; Control vs 5 ng, $\chi^2 = 4.5$, $P = .03$).

Mating Success

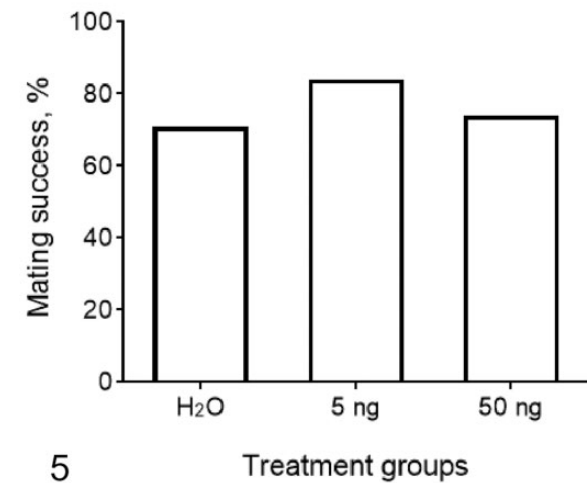
The overall mating success of the queens in experiments A and B ($n = 15/\text{treatment}$) was 70% (21/30), 83% (25/30), and 73% (22/30) in the control, 5 ng THI, and 50 ng THI treatment groups, respectively (68 total; Fig. 5). No statistically

significant differences between groups were noted (total $\chi^2 = 1.6$, $df = 2$, $P = .46$).

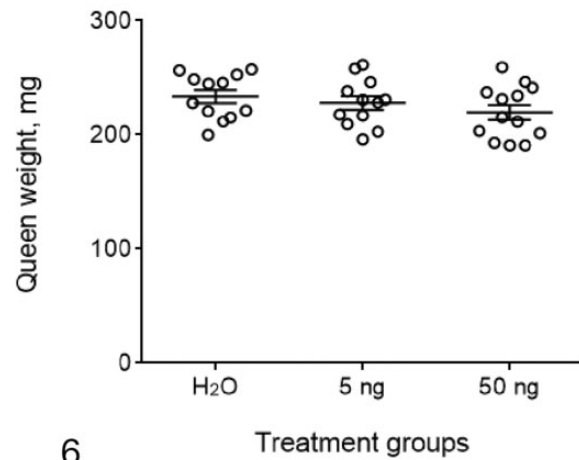
Queen Weights and Sperm Evaluation

The mean weight of queens in the control, 5 ng, and 50 ng groups was 233.6, 228.1, and 219.7 mg, respectively, in experiment B. Treatment had no effect on mean queen weight ($F_{2,34} = 1.343$, $P = .274$; Fig. 6). Queen weight data were not collected in experiment A.

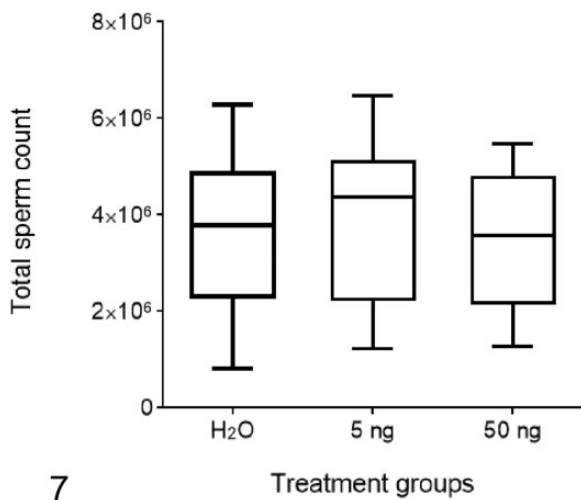
Total sperm counts in the spermatheca of the queens were not affected by treatment in either experiment (A: Kruskal-Wallis $H = 1.2$, $df = 2$, $P = .54$; B: Kruskal-Wallis $H = 5.4$, $df = 2$, $P = .07$; Fig. 7). However, the total sperm count was significantly lower in all 3 treatment groups in experiment



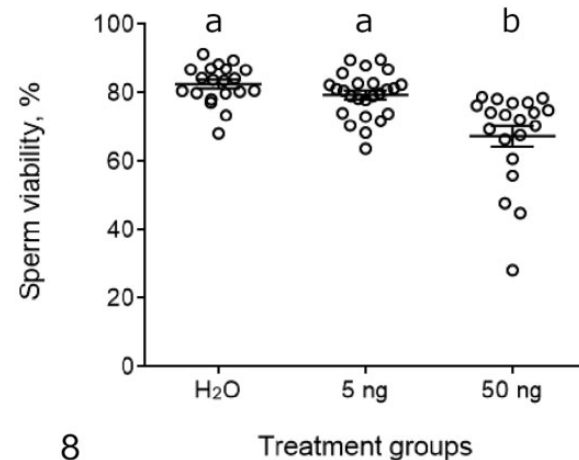
5



6



7



8

Figures 5–8. Mating success, body weight, and sperm quality in honey bee queens exposed to thiamethoxam (THI) during development. The graphs for mating success and sperm quality show data combined from experiments A (June) and B (August); the graph for queen weight shows data only from experiment B. Queen mating success (%) (**Figure 5**), mated queen weights (mean \pm SEM) (**Figure 6**), and total sperm count in the spermatheca of the queens (**Figure 7**) were not affected by THI treatment. The total sperm count is shown in box-plot graphs where the horizontal bar is the median, the box represents interquartile range, and the whiskers show minimum and maximum. **Figure 8.** Mean (\pm SEM) sperm viability was reduced by 18% in queens exposed to 50 ng THI. Different letters indicate statistically significant differences between treatment groups ($P \leq .05$).

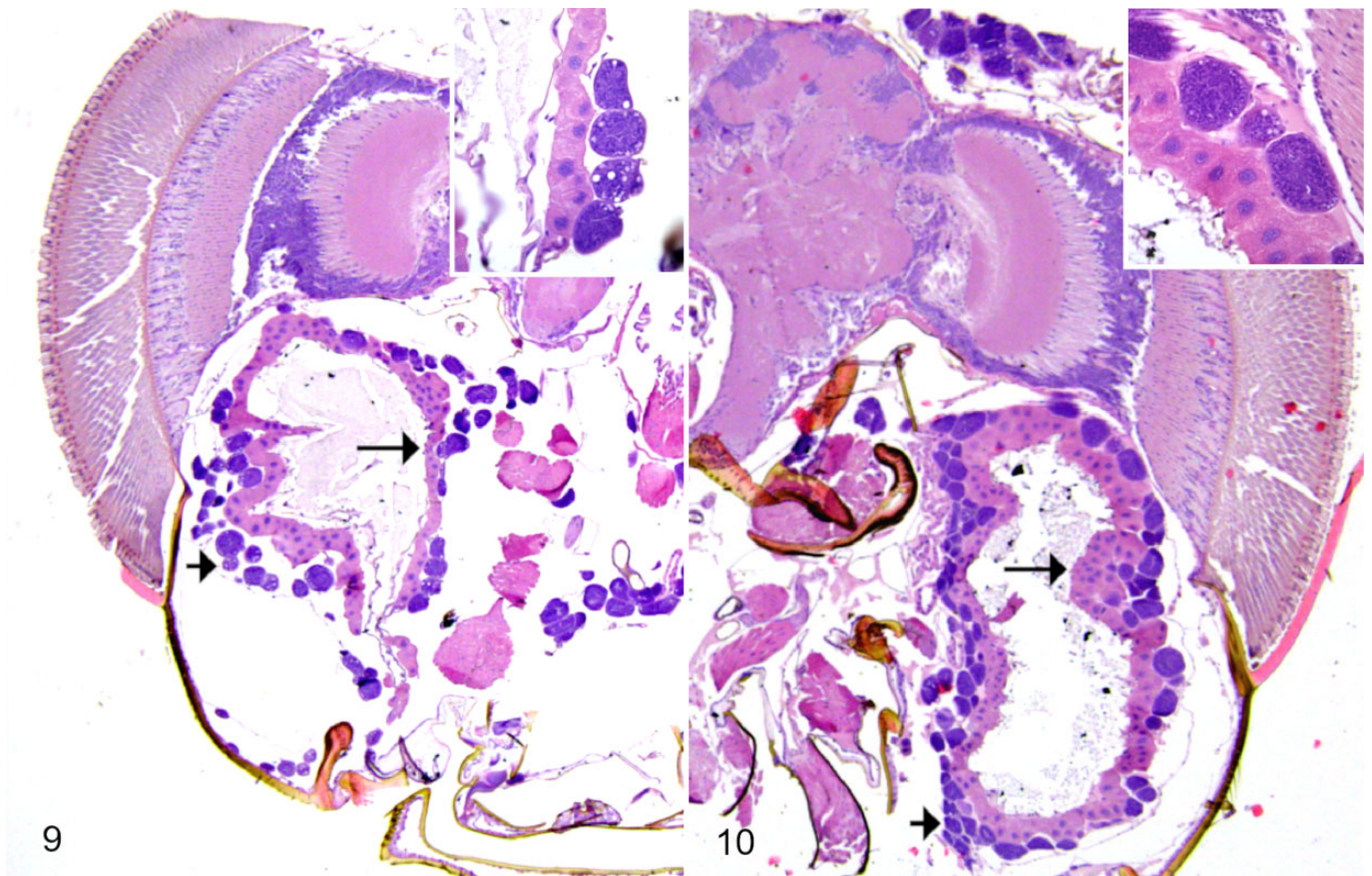
A, compared to experiment B (control: Mann-Whitney $U = 16.0$, $P = .007$; 5 ng THI: Mann-Whitney $U = 6.0$, $P < .001$; 50 ng THI Mann-Whitney $U = 15.0$, $P = .003$). The mean \pm SEM total sperm counts for the control, 5 ng and 50 ng groups were $2\,622\,125 \pm 273\,589$, $2\,739\,000 \pm 314\,432$, and $2\,404\,111 \pm 424\,768$ in experiment A, respectively; and $4\,207\,667 \pm 426\,601$, $5\,249\,000 \pm 223\,196$, and $4\,396\,727 \pm 244\,215$ in experiment B, respectively.

Overall, THI treatment had a negative effect on sperm viability ($F_{2,62} = 15.8$, $P < .001$; Fig. 8); specifically, queens in the 50 ng group had an 18% reduction of sperm viability compared

to queens in the control group, and a 15% reduction compared to the 5 ng group (Tukey post hoc tests, $P < .001$ for both).

Morphometric Histopathologic Evaluation of Mandibular Glands and Optic Lobes

During the initial tissue evaluation, queen mandibular glands and ovaries were identified as organs potentially affected by THI toxicity. Mandibular glands (Figs. 9–11) are exocrine, sack-like symmetrical glands found in the head of the honey bee. The glands extend from mandibles caudally to the vertex



Figures 9–10. Thiamethoxam exposure, head (coronal section), mated honey bee queen. Mandibular glands of the queen in the group receiving 50 ng thiamethoxam (**Figure 9**) are lined by attenuated epithelium (long arrow); the surrounding fat cells (short arrow) are multifocally shrunken and appear less numerous compared to control (**Figure 10**). Insets: mandibular gland lining and peri-mandibular gland fat body. Hematoxylin and eosin (H&E).

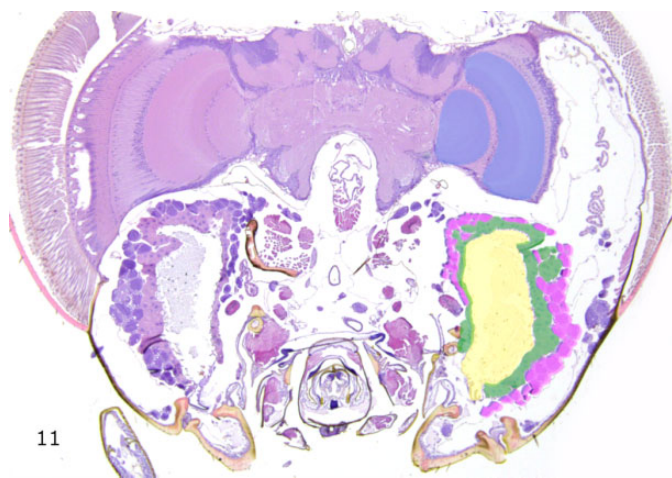
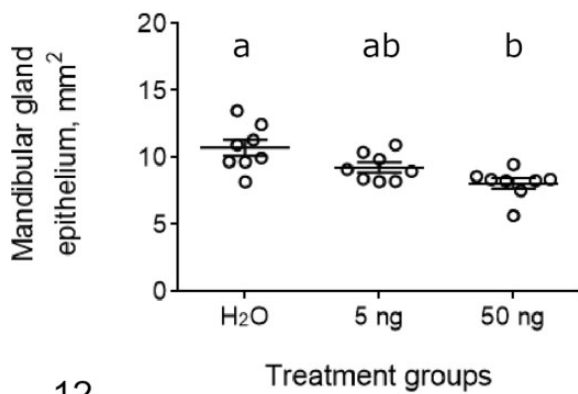


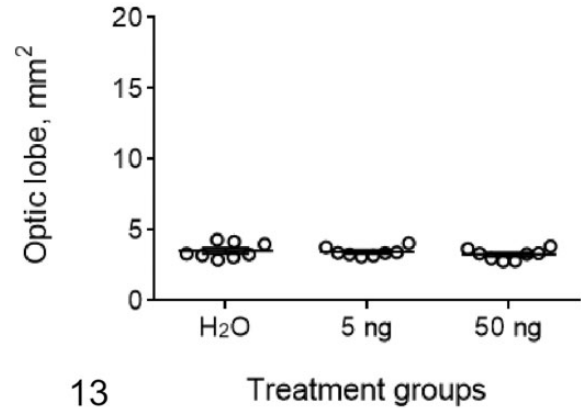
Figure 11. Thiamethoxam exposure, head (coronal section), mated honey bee queen. Image analysis. The highlighted areas on the right indicate the areas of mandibular gland lumen (yellow), mandibular gland epithelium (green), peri-mandibular gland fat body (pink), and optic lobe of the brain (blue). Both right and left sides were included in the analysis. Serial sections were examined to calculate the total area of the highlighted regions. Hematoxylin and eosin (H&E).

and are located ventro-caudally to the brain. Mandibular glands of the honey bee queen are lined by variably corrugated simple cuboidal epithelium surrounding a single large central lumen. The glandular epithelium is characterized by abundant light eosinophilic cytoplasm with a variable degree of microvesicular vacuolation and a prominent round large nucleus with lightly basophilic coarsely stippled chromatin. The mandibular glands are surrounded by clusters of variably sized round to oval basophilic cells with coarsely vacuolated cytoplasm and large smooth nuclei comprising the peri-mandibular fat body.

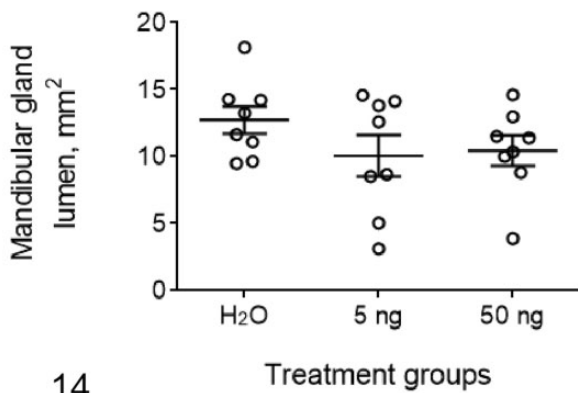
The epithelial lining of the mandibular glands subjectively appeared variably attenuated and/or hypoplastic (less prominent corrugation) in queens exposed to 50 ng THI by light microscopic evaluation (Figs. 9, 10). Therefore, morphometric evaluation was employed and subsequently demonstrated a dose-dependent decrease in total area of mandibular epithelium ($F_{2,21} = 8.1, P = .002$; Fig. 12), while the mean \pm SEM total area of the optic lobe (used as an internal control) was not statistically different between experimental groups ($F_{2,21} = 0.8, P = .46$; Fig. 13). Specifically, queens in the 50 ng THI group had a 25% reduction in the total area of mandibular gland epithelium compared to control ($P = .001$). The 14% epithelial



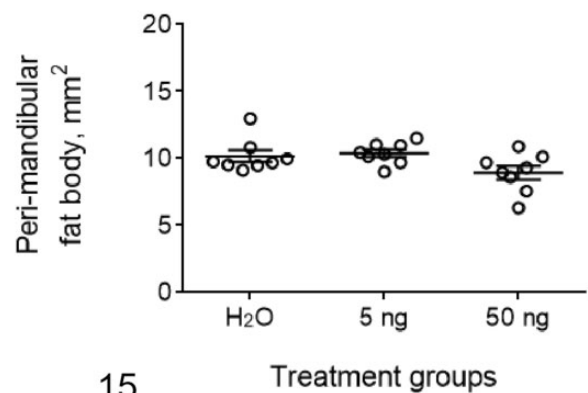
12



13



14



15

Figures 12–15. Morphometric analysis of serial sections of the heads of mated honey bee queens exposed to thiamethoxam (THI) during development. **Figure 12.** The total area of the mandibular epithelium decreased by 2.8 mm^2 (25%) in queens exposed to 50 ng THI ($P = .001$). In queens exposed to 5 ng THI, the 1.3 mm^2 (14%) reduction in epithelial area was not statistically significant ($P = .12$). Treatment did not significantly affect the size (area) of the optic lobe (**Figure 13**), mandibular gland lumen (**Figure 14**), or the peri-mandibular fat body (**Figure 15**). Mean \pm SEM. Different letters indicate significant differences between treatment groups ($P \leq .05$).

area reduction in the 5 ng group was not statistically different from control ($P = .12$). On the other hand, the mandibular gland luminal area was not significantly different ($F_{2,21} = 1.3$, $P = .29$) between treatment groups (Fig. 14). The peri-mandibular fat body cells subjectively varied in size, number, and staining intensity between treatment groups. The morphological evaluation showed that there was 12% and 14% reduction in total area of peri-mandibular fat body in the 50 ng treatment group compared to the control and 5 ng groups, respectively. This result was not statistically significant, but it approached the set confidence level of 0.05 ($F_{2,21} = 3.4$, $P = .051$; Fig. 15).

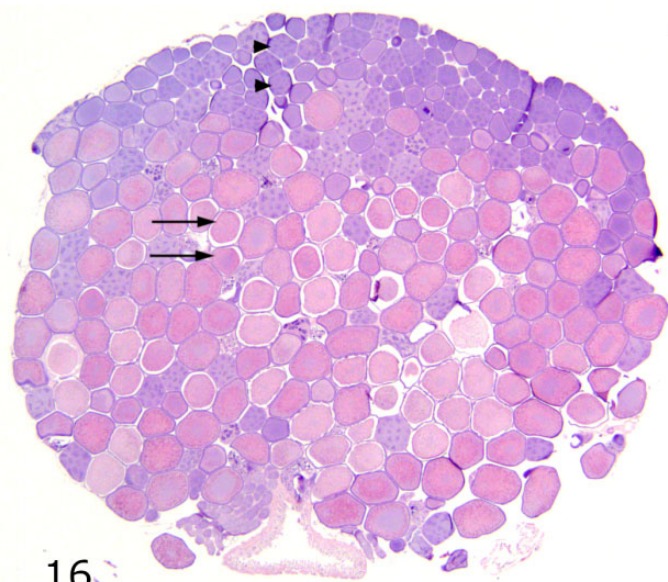
Morphometric Histopathologic Evaluation of Ovary

Sections of proximal ovaries, containing areas of ovarian germarium, had highly variable numbers of apoptotic cells (ie, condensed, hyperbasophilic, fragmented nuclei) within germ-line cell clusters as evaluated in H&E-stained sections under

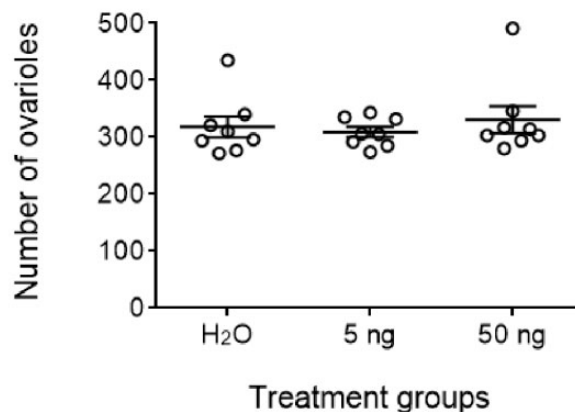
light microscopy. Some apoptosis is expected in this location, but the apoptotic incidence rate appeared to be highly variable between queens. Accordingly, quantitative evaluation of the H&E-stained sections of the ovaries was performed. Neither the total ovariole counts (Figs. 16, 17) nor the ovarian apoptotic rate (Figs. 18, 19) were affected by the neonicotinoid treatment ($F_{2,21} = 0.37$, $P = .70$; $F_{2,21} = 0.28$, $P = .76$, respectively).

Discussion

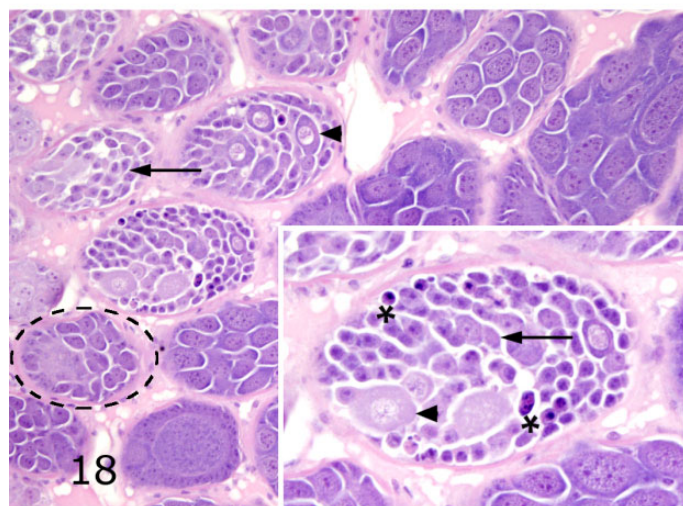
Our study indicates that late larval exposure of honey bee queens to incremental doses of THI can reduce queen pupal survival, decrease sperm viability, and result in hypoplasia of mandibular glands in mated queens. Our study confirmed that queens exposed to THI during development had increased larval and pupal mortality as reported by Gajger et al⁹ and decreased reproductive fitness (eg, sperm viability) as reported by other studies.^{7,26,38} Unique to our study, histopathological



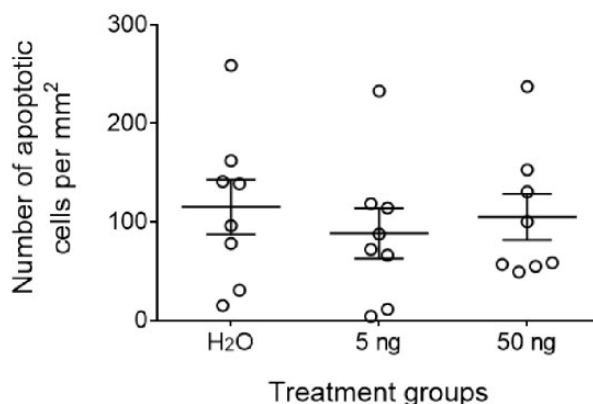
16



17



18



19

Figures 16–19. Number of ovariolar units and apoptotic rate in ovaries of mated honey bee queens exposed to thiamethoxam (THI) during development. **Figure 16.** Normal ovary, mated honey bee queen. The ovariole is represented by distinct round eosinophilic structures (oocytes; arrows) and by light basophilic structures (immature oocytes and/or trophocyte clusters; arrowheads). Hematoxylin and eosin (H&E). **Figure 17.** Total ovariolar counts are not affected by THI treatment. Mean ± SEM. **Figure 18.** Normal proximal ovarioles, mated honey bee queen. The ovarioles contain germarium (arrow, arrowhead) and vitellarium (dashed ellipse). In the germarium, germline cells (arrow) are arranged in rosettes, and there is early differentiation of oocytes (arrowhead). In the vitellarium (dashed ellipse), each oocyte is associated with a cluster of trophocytes within a single ovariole. Inset: a germarium containing apoptotic cells (asterisk) that have condensed, hyperbasophilic, fragmented nuclei. Arrow: germline cells; arrowhead: early oocytes. H&E. **Figure 19.** The apoptotic rate within germarium was not affected by treatment. Mean ± SEM.

evaluation revealed that incremental doses of THI had a negative effect on development of queen mandibular glands.

The queen mandibular glands secrete pheromones regulating all aspects of colony homeostasis including growth, health, production, reproduction, and queen supersedure.^{1,18} Failure of any of these parameters is usually attributed to the poor quality of the queen.

The reduction in the total area of mandibular glandular epithelium in our study was dose-dependent; however, this

reduction was only statistically significant in the positive control treatment group exposed to 50 ng THI. Yet, organ malfunction often precedes the development of morphological changes, which can only be detected in more severe or chronic disease processes.^{13,21} The functional significance of the morphological changes observed in the mandibular glands in this study was not determined. Therefore, we cannot conclude if the non-statistically significant 14% reduction in the total area of the mandibular gland size in queens exposed to 5 ng THI

(theoretical highest environmental dose in Saskatchewan, Canada) is biologically significant. Nevertheless, it is reasonable to hypothesize that reduction in mandibular gland epithelium may result in reduced pheromone production/secretion, which together with other abiotic and biotic stressors could compromise queen performance resulting in suboptimal colony functionality and health. Interestingly, Walsh et al³⁷ recently reported that raising queens in miticide-contaminated wax decreases attractiveness of the queen mandibular gland product to worker bees and alters relative chemical composition of the queen mandibular gland. Taken together, our study and the study of Walsh et al emphasize the importance of mandibular gland morphology and function as indicators of queen health.

THI treatment in our study affected the queen's mandibular glands, but not overall queen size or weight. The optic lobe area, measured as an internal control, remained similar across all treatments as well. This suggests that the morphological changes in mandibular gland are treatment specific rather than reflective of a generalized treatment response (eg, reduction in body mass).

Previously, in a pilot study, we examined the area of mandibular gland epithelium following the same procedures in newly emerged virgin queens (Suppl. Table S4, line 14) (unpublished). Similar to the findings presented in Figure 12, the newly emerged virgin queens exposed to 50 ng THI during development had a 27% reduction in mandibular gland epithelium area compared to water-treated control. Considering the similar trends observed in newly emerged virgins and mated queens, we conclude that the observed changes are due to mandibular gland hypoplasia (underdevelopment) during pupal development rather than mandibular gland atrophy occurring post-emergence.

Reduction in size of mandibular and hypopharyngeal glands have been previously reported in worker bees in association with malnutrition,⁵ infectious diseases,^{15,38} and pesticide exposure.⁴¹ The current study demonstrated that THI exposure during development is associated with reduced mandibular gland size in newly emerged virgin queens and young mated queens. In workers, pesticide exposure has been associated with reduction of gland size and decreased brood food production.⁴¹ In queens, a similar association between mandibular gland size and its biologic activity has not yet been established. Interestingly, in workers, the mandibular gland luminal space (reservoir) and the epithelial cell height was reduced in response to pesticide exposure,⁴¹ whereas in our study the area of mandibular gland epithelium, but not the lumen, was reduced in response to THI treatment. The reduction of epithelial area, but not lumen, in queens exposed to THI suggests that secretory function of the mandibular gland is more likely to be affected than its storage ability. At the same time, we found that perimandibular gland fat body in the 50 ng group was reduced by 12% compared to control (this difference was not statistically significant [$P = .051$], but close to the confidence level value of 0.05). The function of the insect fat body is often compared to that of liver and kidney in mammals, carrying out metabolic and nutritional functions. Accordingly, the observed 12%

reduction of fat body size around the smaller mandibular glands may suggest 2 pathways of mandibular gland hypoplasia in response to THI treatment. One pathway is that the reduced size of the mandibular glands may be directly associated with THI toxicity. Alternatively, the reduced gland size may be a nonspecific change that reflects decreased nutritional supply and metabolic activity of the peri-mandibular gland fat body. It is possible that both pathways may contribute to the observed changes. This finding warrants further investigation into the effects of neonicotinoids on secretion, concentration and/or diversity of queen mandibular pheromone using gas chromatography-mass spectrometry or other techniques.^{18,23} This may help elucidate effects of neonicotinoids on queen quality, which is considered to be 1 of the 3 most commonly reported causes of morbidity and mortality of honey bee colonies.³⁶

Queen pupal survival was dependent on both the dose of THI and the time the experiment was conducted. Queen larvae exposed to 50 ng (positive control) in both experiments A (June) and B (August) had a 31% (11/36) and 46% (11/24) mortality, respectively, compared to 0% mortality in control (Figs. 3, 4). However, the queens exposed to 5 ng THI (theoretical highest environmental dose in Saskatchewan, Canada) experienced a significant negative treatment effect in August, but not in June, with 32% (8/25) and 0% (0/26) mortality, respectively. We hypothesize that the main factors contributing to this variability include the different genetic lines used in the 2 experiments²⁴ and/or the environmental reduction in forage in August in our area. The high pupal mortality rate in individuals exposed to 5 ng THI in experiment B is concerning as it suggests that high environmental doses of THI may have a detrimental effect on queen production when enhanced by unfavorable environmental or genetic conditions. This finding is in agreement with Gajger et al⁹ who reported a statistically significant 13% and 10% decrease in survival of individual queen cells exposed to 4.28 ng and 8.5 ng THI, respectively, compared to control.

The decreased sperm viability and amount of sperm stored in the spermatheca of queens exposed to neonicotinoids is well documented.^{9,26,39} In our study, sperm viability decreased by incremental doses of THI, but only queens exposed to 50 ng THI (positive control) had statistically significant, lower sperm viability compared to controls, and total sperm count was not statistically different between treatment groups. The lack of treatment effect on total sperm count in our study may have been influenced by a low number of drones near our mating colonies, especially in early summer. We deliberately did not augment the drone population during queen mating to enhance mating competition. In addition, the lack of an abundant drone population at mating may have prevented detection of a treatment effect on total sperm count, which was previously reported to be negatively affected by neonicotinoid exposure.⁷ Differences in method of neonicotinoid exposure may also account for differences between our results and those of other studies. In our study, the treatment was pipetted into the royal jelly of individual queen larvae, whereas most other studies^{26,39}

exposed entire colonies through sugar syrup or pollen patty. Therefore, the negative effects of neonicotinoids on sperm viability and/or total count reported by other studies may be, in part, secondary to the effects of neonicotinoids on queen-worker interaction at the colony level, as opposed to a true toxic effect of the neonicotinoid on a developing honey bee queen.

Differences in method of neonicotinoid exposure may also account for the disparity in effects of neonicotinoids on queen weight and ovarian development. Gajger et al⁹ reported that queens exposed to THI during development had decreased body weight. We observed a trend toward decreased body weights of queens exposed to incremental doses of THI, but the changes were not statistically significant. Similarly, there are disparities in reported effects of THI on ovaries: Williams et al³⁹ reported that THI, in combination with clothianidin, increased the number of ovarioles in exposed queens, whereas Gajger et al⁹ reported decreased ovarian weights in queens exposed to THI. In our study, there was no difference in ovariole numbers among treatment groups and histopathological evaluation of ovaries did not reveal unequivocal differences between treatment groups. In addition, we did not detect any difference in apoptotic rate in the ovarian germarium by morphometric analysis.

To evaluate THI toxicity in individual developing honey bee queens in this study, we chose to work with 2 calculated doses based on previous studies^{3,6,10}: (1) worst theoretical exposure possible in Saskatchewan, Canada (5 ng THI), and a (2) positive control (10 times the worst calculated dose, 50 ng THI per larva). In this calculation, we considered only potential transfer of neonicotinoids from contaminated pollen to royal jelly (the only feed provided to queen larvae) and did not take into consideration the additional potential exposure of honey bee queen larvae and pupae to THI through contaminated comb wax which has been shown to contain a wide mixture of pesticides.²⁰ Raising bees in pesticide-contaminated comb was previously shown to delay development and reduce longevity of workers,⁴⁰ reduce reproductive potential of queens,³⁷ and decrease sperm viability in drones. The average THI contamination of beeswax reported previously was 38 ng/g.⁴⁰ Nevertheless, the 5 ng THI treatment dose (the worst calculated exposure dose), although theoretically possible in areas with high THI contamination (Saskatchewan, Canada), is likely an overestimation compared to the world average.¹⁹

In summary, this study demonstrated progressive hypoplasia of mandibular glands in queens exposed to incremental doses of THI during development, even though only the high-dose 50 ng group was significantly different from the control. The functional significance of the morphological changes observed in mandibular glands in this study was not determined, but if confirmed by subsequent studies, could explain, at least in part, some aspects of compromised reproductive fitness and quality of queens exposed to neonicotinoids. Queen survival in response to the calculated high environmental dose of 5 ng per larva was negatively affected in 1 of the 2 replicate experiments. This difference in treatment response emphasizes the

need to consider genetic and environmental variability in honey bee toxicity studies.

Acknowledgements

The authors thank Roman Kozii, Jocelyne Chalifour, Alexandra Wentzell, Crystani Folkes, Esther Derksen, and Benjamin Elwood (all from Western College of Veterinary Medicine, University of Saskatchewan) for their technical assistance.


Declaration of Conflicting Interests

The author(s) declared no potential conflicts of interest with respect to the research, authorship, and/or publication of this article.

Funding

The author(s) disclosed receipt of the following financial support for the research, authorship, and/or publication of this article: This research was funded by the Western Grains Research Foundation, Grant Number ADF 20150125; the Saskatchewan Canola Development Commission, Grant Number ADF 20150125; the Saskatchewan Agricultural Development Fund, Grant Number 20160157; Project Apis m. Costco-Canada Scholarship; Mitacs; North American Pollinator Protection Campaign; Canadian Bee Research Fund; Saskatchewan Beekeepers Development Commission; and Western College of Veterinary Medicine Wildlife Health Research Fund. The personal support of IK was provided by the University of Saskatchewan Graduate Scholarship, WCVM Graduate Enhancement Fund, Saskatchewan Innovation & Opportunity Scholarship, Mitacs Accelerate, and the PEO International Peace Scholarship.

ORCID iD

Ivanna V. Kozii  <https://orcid.org/0000-0002-6802-2762>

References

- Bortolotti L, Costa C. Chemical communication in the honey bee society. In: Mucignat-Caretta C, ed. *Neurobiology of Chemical Communication*. CRC Press/Taylor & Francis; 2014:147–210.
- Cobey SW, Tarpy DR, Woyke J. Standard methods for instrumental insemination of *Apis mellifera* queens. *J Apic Res*. 2013;**52**(4):1–18.
- Codling G, Al Naggar Y, Giesy JP, et al. Concentrations of neonicotinoid insecticides in honey, pollen and honey bees (*Apis mellifera* L) in central Saskatchewan, Canada. *Chemosphere*. 2016;**144**:2321–2328.
- Conner LJ. *Queen Rearing Essentials*. Wicwas Press; 2009.
- Corby-Harris V, Meador CAD, Snyder LA, et al. Transcriptional, translational, and physiological signatures of undernourished honey bees (*Apis mellifera*) suggest a role for hormonal factors in hypopharyngeal gland degradation. *J Insect Physiol*. 2016;**85**:65–75.
- Dively GP, Embrey MS, Kamel A, et al. Assessment of chronic sublethal effects of imidacloprid on honey bee colony health. *PLoS One*. 2015;**10**(3):e0118748.
- Forfert N, Troxler A, Retschnig G, et al. Neonicotinoid pesticides can reduce honeybee colony genetic diversity. *PLoS One*. 2017;**12**(10):e0186109.
- Friedli A, Williams GR, Bruckner S, et al. The weakest link: haploid honey bees are more susceptible to neonicotinoid insecticides. *Chemosphere*. 2020;**242**:125145.
- Gajger IT, Sakač M, Gregorc A. Impact of thiamethoxam on honey bee queen (*Apis mellifera carnica*) reproductive morphology and physiology. *Bull Environ Contam Toxicol*. 2017;**99**(3):297–302.
- Haydak MH. Honey bee nutrition. *Annu Rev Entomol*. 1970;**15**(1):143–156.
- Henry M, Béguin M, Requier F, et al. A common pesticide decreases foraging success and survival in honey bees. *Science*. 2012;**336**(6079):348–350.

12. Hopkins BK, Herr C, Sheppard WS. Sequential generations of honey bee (*Apis mellifera*) queens produced using cryopreserved semen. *Reprod Fertil Dev.* 2012;**24**(8):1079–1083.
13. Kemp WL, Burns DK, Brown TG. Chapter 1: Cellular pathology. In: *Pathology: The Big Picture*. McGraw-Hill; 2013:1–12.
14. Kozii IV, Wood SC, Kozii RV, et al. Histomorphological description of the reproductive system in mated honey bee queens. *J Apic Res.* Published online April 29, 2021. doi:10.1080/00218839.2021.1900636
15. Kozii RV, Wood SC, Kozii IV, et al. Deformed wing virus infection in honey bees (*Apis mellifera* L). *Vet Pathol.* 2019;**56**(4):636–641.
16. Maienfisch P, Huerlimann H, Rindlisbacher A, et al. The discovery of thiamethoxam: a second-generation neonicotinoid. *Pest Manag Sci.* 2001;**57**(2):165–176.
17. Main AR, Headley JV, Peru KM, et al. Widespread use and frequent detection of neonicotinoid insecticides in wetlands of Canada's prairie pothole region. *PLoS One.* 2014;**9**(3):e92821.
18. Maisonnasse A, Alaux C, Beslay D, et al. New insights into honey bee (*Apis mellifera*) pheromone communication. Is the queen mandibular pheromone alone in colony regulation? *Front Zool.* 2010;**7**:18.
19. Mitchell EAD, Mulhauser B, Mulot M, et al. A worldwide survey of neonicotinoids in honey. *Science.* 2017;**358**(6359):109–111.
20. Mullin CA, Frazier M, Frazier JL, et al. High levels of miticides and agrochemicals in North American apiaries: implications for honey bee health. *PLoS One.* 2010;**5**(3):e9754.
21. Oakes S. Cell injury, cell death, and adaptations. In: Kumar V, Abbas AK, Aster JC, eds. *Robbins and Cotran Pathologic Basis of Disease*. Elsevier Health Sciences; 2015:33–69.
22. Potts SG, Biesmeijer JC, Kremen C, et al. Global pollinator declines: trends, impacts and drivers. *Trends Ecol Evol.* 2010;**25**(2):345–353.
23. Princen SA, Oliveira RC, Ernst UR, et al. Honeybees possess a structurally diverse and functionally redundant set of queen pheromones. *Proc Biol Sci.* 2019;**286**(1905):20190517.
24. Rinkevich FD, Margotta JW, Pittman JM, et al. Genetics, synergists, and age affect insecticide sensitivity of the honey bee, *Apis mellifera*. *PLoS One.* 2015;**10**(10):e0139841.
25. Sánchez-Bayo F, Goulson D, Pennacchio F, et al. Are bee diseases linked to pesticides? A brief review. *Environ Int.* 2016;**89–90**:7–11.
26. Sandrock C, Tanadini M, Tanadini LG, et al. Impact of chronic neonicotinoid exposure on honeybee colony performance and queen supersedure. *PLoS One.* 2014;**9**(8):e103592.
27. Simon-Delso N, Amaral-Rogers V, Belzunces LP, et al. Systemic insecticides (neonicotinoids and fipronil): trends, uses, mode of action and metabolites. *Environ Sci Pollut Res.* 2015;**22**(1):5–34.
28. Snodgrass RE. *Anatomy of the Honey Bee*. Read Books; 2017.
29. Steinhauer N, Kulhanek K, Antúnez K, et al. Drivers of colony losses. *Curr Opin Insect Sci.* 2018;**26**:142–148.
30. Straub L, Villamar-Bouza L, Bruckner S, et al. Neonicotinoid insecticides can serve as inadvertent insect contraceptives. *Proc Biol Sci.* 2016;**283**(1835):20160506.
31. Suvarna KS, Layton C, Bancroft JD. *Bancroft's Theory and Practice of Histological Techniques*. 7th ed. Elsevier Churchill Livingstone; 2013.
32. Tavares DA, Dussaubat C, Kretzschmar A, et al. Exposure of larvae to thiamethoxam affects the survival and physiology of the honey bee at post-embryonic stages. *Environ Pollut.* 2017;**229**:386–393.
33. Tesovnik T, Cizelj I, Zorc M, et al. Immune related gene expression in worker honey bee (*Apis mellifera carnica*) pupae exposed to neonicotinoid thiamethoxam and Varroa mites (*Varroa destructor*). *PLoS One.* 2017;**12**(10):e0187079.
34. The Apiaries Act. In: *The Statutes of Saskatchewan*. Regina, Saskatchewan; 2005:1–10.
35. Tosi S, Nieh JC. A common neonicotinoid pesticide, thiamethoxam, alters honey bee activity, motor functions, and movement to light. *Sci Rep.* 2017;**7**(1):15132.
36. van Engelsdorp D, Meixner MD. A historical review of managed honey bee populations in Europe and the United States and the factors that may affect them. *J Invertebr Pathol.* 2010;**103**(suppl 1):S80–S95.
37. Walsh EM, Sweet S, Knap A, et al. Queen honey bee (*Apis mellifera*) pheromone and reproductive behavior are affected by pesticide exposure during development. *Behav Ecol Soci.* 2020;**74**(3):33.
38. Wang DI, Moeller FE. Ultrastructural changes in the hypopharyngeal glands of worker honey bees infected by *Nosema apis*. *J Invertebr Pathol.* 1971;**17**(3):308–320.
39. Williams GR, Troxler A, Retschnig G, et al. Neonicotinoid pesticides severely affect honey bee queens. *Sci Rep.* 2015;**5**(1):14621.
40. Wu JY, Anelli CM, Sheppard WS. Sub-lethal effects of pesticide residues in brood comb on worker honey bee (*Apis mellifera*) development and longevity. *PLoS One.* 2011;**6**(2):e14720.
41. Zaluski R, Justulin LA Jr, de Oliveira Orsi R. Field-relevant doses of the systemic insecticide fipronil and fungicide pyraclostrobin impair mandibular and hypopharyngeal glands in nurse honeybees (*Apis mellifera*). *Sci Rep.* 2017;**7**(1):15217.
42. Zar JH. *Biostatistical Analysis (Books a la Carte)*. Pearson College Division; 2010.