

# Vesicoureteral Reflux Detected on Post-void Image of $^{99m}\text{Tc}$ MAG3 Renal Scintigraphy

Naureen Nizar<sup>1</sup>, Akhtar Ahmed<sup>1,2</sup>

Department of Nuclear Medicine, <sup>1</sup>Sindh Institution of Urology and Transplantation, <sup>2</sup>Karachi Institute of Radiotherapy and Nuclear Medicine, Karachi, Pakistan

## Abstract

$^{99m}\text{Tc}$  MAG3 scintigraphic scan is sensitive at depicting focal parenchymal abnormalities and can be used for the measurement of overall renal function. We experienced a 5-year-old boy presenting with bilateral flank pain, intermittent urinary stream and dysuria. On the post-void delayed image of  $^{99m}\text{Tc}$  MAG3 scintigraphic scan vesicoureteral reflux was detected in left non-functioning kidney, which was missed on voiding cystourethrography.

**Keywords:**  $^{99m}\text{Tc}$  MAG3, vesicoureteral reflux, voiding cystourethrography

## Introduction

Vesicoureteral reflux (VUR) may be diagnosed by both voiding cystourethrography (VCUG) and radionuclide cystourethrography.<sup>[1,2]</sup> Although the results of both methods did not show a significant difference, radionuclide cystourethrography offers a high sensitivity in the younger age group.<sup>[3,4]</sup> Continuous monitoring during and absence of body background allows radionuclide cystourethrography to demonstrate reflux which could well be intermittent and of small volume.<sup>[5]</sup> These facts could have led VCUG to miss VUR.<sup>[4]</sup>

Conventional renal scan is not usually used for diagnosis of VUR. We present a case of unilateral VUR demonstrated on renal scintigraphy, missed on VCUG.

## Case Report

The present case report is about a 5-year-old boy presented with bilateral flank pain with intermittent

urinary stream, dysuria for 2 days and an episode of hematuria. Ultrasonogram abdomen showed bilateral moderate hydronephrosis with ureteric dilatation and distended urinary bladder [Figure 1]. VCUG revealed normal urethral caliber with no evidence of VUR [Figure 2]. Diuretic-augmented renal scintigraphy using  $^{99m}\text{Tc}$  MAG3 was performed with a standard protocol to evaluate renal function which showed functional asymmetry. Right kidney appeared to be fair functioning with incomplete outflow clearance whereas left kidney could not be visualized on initial dynamic images. Post-void delayed image of  $^{99m}\text{Tc}$  MAG3 scintigraphic scan acquired at 20 min after dynamic study, showed appearance of left kidney and ureter which indicate VUR [Figure 3].

## Discussion

Dynamic renography using  $^{99m}\text{Tc}$  MAG3 in combination with furosemide challenge has been widely used to determine the differential function of the kidneys, occurrence of reflux as well as the patency of the outflow tract in this context.<sup>[6]</sup> Renal scans can also be important in monitoring individual renal function during conservative management of many renal disorders. Although VUR shown by radionuclide cystography has been reported, its demonstration during dynamic renography is unusual.<sup>[7,8]</sup> Conventional  $^{99m}\text{Tc}$  MAG3 scintigraphy can work as indirect cystography to detect

### Access this article online

#### Quick Response Code:

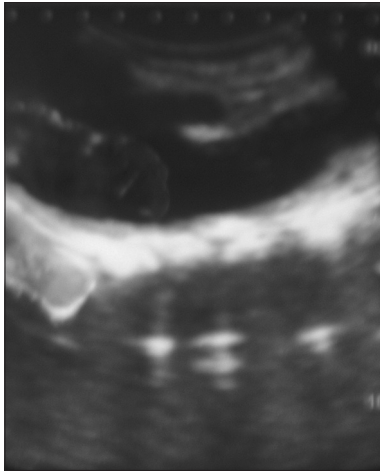


Website:  
[www.wjnm.org](http://www.wjnm.org)

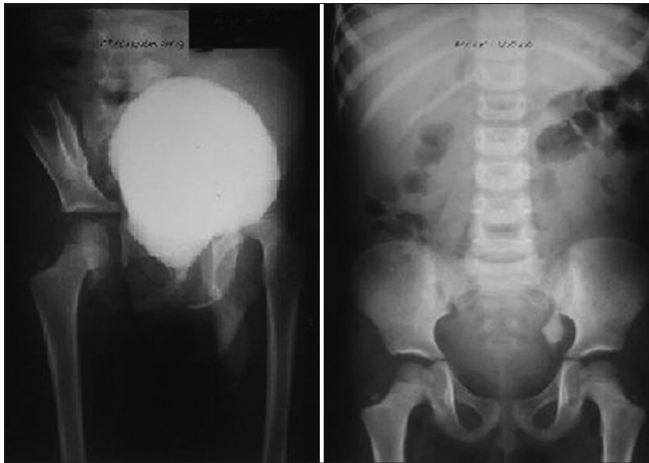
DOI:  
10.4103/1450-1147.136697

#### Address for correspondence:

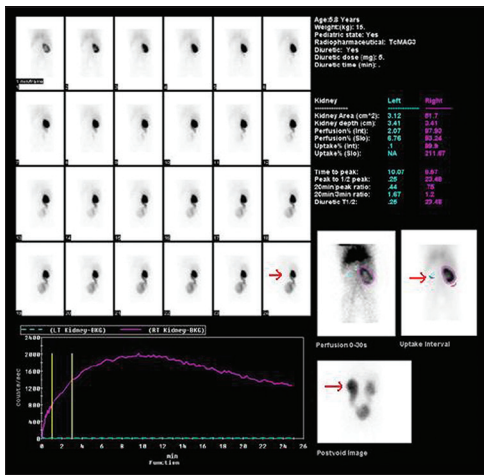
Dr. Naureen Nizar, Department of Nuclear Medicine, Sindh Institute of Urology and Transplantation, Karachi 74600, Pakistan.  
E-mail: [naureennizar@hotmail.com](mailto:naureennizar@hotmail.com)



**Figure 1:** Ultrasound abdomen shows left kidney 7.5 cm with moderate to gross hydronephrosis



**Figure 2:** Voiding cystourethrography showing no evidence of urethral stricture and vesicoureteral reflux



**Figure 3:** <sup>99m</sup>Tc MAG3 renal scintigraphy showing fair functioning hydronephrotic right kidney with partial outflow clearance whereas left kidney is not visualized in dynamic images. Post-void image showing appearance of left kidney and ureter indicative of vesicoureteral reflux

reflux.<sup>[9,10]</sup> We could demonstrate the reflux by this without conventional VCUG by acquiring additional data after micturition and hence that analysis of the kidneys can be undertaken when the bladder is empty.<sup>[11]</sup> Post-void image is essential at the end of the diuretic renogram if outflow clearance is incomplete, to calculate residual urine volume and to better evaluate drainage from the collecting system, as it allows comparison with sequential studies.<sup>[12]</sup> Bladder catheterization has been advocated in children undergoing diuretic renography to maintain an empty bladder throughout the procedure. Using the post-void Images, bladder catheterization is not recommended.

This case illustrates the presence of VUR in the of non-functioning renal tissue on post-void image which was not detected on VCUG as VUR is known to be a somewhat variable phenomenon with different conditions of hydration, bladder volume and pressure. It might be expected that different techniques attempting to diagnose VUR from two separate episodes of voiding would reveal some discrepancy in diagnostic results.<sup>[13]</sup>

The case described, demonstrates the value of acquiring post-void image in diuretic renography which would help the physician in making appropriate management decisions. A careful review of the post-void image established the correct diagnosis, obviating the need for further investigation.

## References

- Gibson HM. Ureteral reflux in the normal child. *J Urol* 1949;60:40-9.
- Treves ST, Gelfand M, Willi UV. Vesicoureteric reflux and radionuclide cystography. In: Treves ST, editor. *Pediatric Nuclear Medicine*. New York: Springer Verlag; 1994. p. 411-27.
- Gil Salom M, Nuñez F, Hernández R, Fons J, Lara A, Brines J, *et al*. Value of isotopic cystography in the diagnosis of vesicoureteral reflux in childhood. *Actas Urol Esp* 1989;13:339-42.
- Poli-Merol ML, Francois S, Pfliger F, Lefebvre F, Roussel B, Liehn JC, *et al*. Interest of direct radionuclide cystography in repeated urinary tract infection exploration in childhood. *Eur J Pediatr Surg* 1998;8:339-42.
- Treves ST. The ongoing challenge of diagnosis and treatment of urinary tract infection, vesicoureteral reflux and renal damage in children. *J Nucl Med* 1994;35:1608-11.
- Alwis L, Hampson F, Pawaroo D, Balan K. Urinary reflux from ileal neobladder into a non-functioning kidney: Detection during diuretic renography. *Clin Nucl Med* 2009;34:725-6.
- Kibar M, Doğruca Z, Büyükdereli G, Noyan A, Onsel C. The detection of vesicoureteral reflux in a nonfunctioning kidney on a Tc-99m DTPA renal function study. *Clin Nucl Med* 1998;23:108-10.
- De Palma D, Manzoni GA. The detection of vesicoureteral reflux in the nonfunctioning lower half of an occult duplex kidney by Tc-99m MAG3 indirect radionuclide cystography. *Clin Nucl Med* 2000;25:628-9.
- Tsachimochi S, Nakajo M, Tanabe H, Jinguji M, Nakabeppu Y,

- Tani A. Unilateral vesicoureteral reflux detected by diuretic renography without voiding. *Clin Nucl Med* 2003;28:228-9.
10. Fonseca RB, Duarte PS, Susuki L. Vesicoureteral reflux in a patient with complete ureteral duplication detected on Tc-99m DTPA renography. *Clin Nucl Med* 2003;28:498-500.
  11. Kim HG, Yu J, Ham JY, Pai KS, Yun SN. Reflux nephropathy detected by post-voiding Image on scintigraphic Tc-99m MAG3 scan. *J Korean Soc Pediatr Nephrol* 2003;7:239-44.
  12. Gordon I, Mialdea-Fernandez RM, Peters AM. Pelviureteric junction obstruction. The value of a post-micturition view in <sup>99m</sup>Tc DTPA diuretic renography. *Br J Urol* 1988;61:409-12.
  13. Bower G, Lovegrove FT, Geijsel H, Van der Schaff A, Guelfi G. Comparison of "direct" and "indirect" radionuclide cystography. *J Nucl Med* 1985;26:465-8.

**How to cite this article:** Nizar N, Ahmed A. Vesicoureteral Reflux Detected on Post-void Image of <sup>99m</sup> Tc MAG3 Renal Scintigraphy. *World J Nucl Med* 2013;12:70-2.

**Source of Support:** Nil, **Conflict of Interest:** None declared.

#### Dispatch and return notification by E-mail

The journal now sends email notification to its members on dispatch of a print issue. The notification is sent to those members who have provided their email address to the association/journal office. The email alerts you about an outdated address and return of issue due to incomplete/incorrect address.

If you wish to receive such email notification, please send your email along with the membership number and full mailing address to the editorial office by email.