


CASE REPORT

Is the left bundle branch pacing a choice to conquer the right bundle branch block?—A case report

Song-Yun Chu MD  | Qin-Hui Sheng MD | Er-Dong Chen MD | Han Jin MD |
Jie Jiang MD | Yu-Ling Wang BSN | Peng-Kang He MD | Jing Zhou MD |
Yan-Sheng Ding MBS

Department of Cardiology, Peking University First Hospital, Beijing, China

Correspondence

Song-Yun Chu, MD, Department of Cardiology, Peking University First Hospital, Address: No. 8 Xishiku Street, Xicheng District, Beijing 100034, China. Email: cstellar@sina.com

Funding information

Peking University First Hospital, Grant/Award Number: 2017CR20

Abstract

In patients with preserved ejection fraction or right bundle branch block (RBBB) pattern requiring a high percentage of ventricular pacing, His-bundle pacing (HBP) might be an alternative to biventricular pacing, although the high threshold occasionally occurs. We provided a case of the intrinsic RBBB correction by capturing intra-Hisian left bundle branch (LBB) or distal His-bundle with different output settings. LBB pacing had the advantage of a much lower threshold while remained most synchrony as HBP. LBB pacing might be a promisingly safe and effective procedure for patients with high-grade atrioventricular (AV) block and RBBB pattern.

KEYWORDS

electrocardiography, Non-invasive techniques, pacemaker-bradyarrhythmias, physiologic pacing

1 | INTRODUCTION

Since long-term right ventricular pacing is in disfavor of cardiac function, biventricular (BiV) pacing is recommended in current guidelines for patients with reduced ejection fraction (EF) who require high percentages of pacing. However, BiV pacing might not provide as much benefit in patients with right bundle branch block (RBBB) pattern. Permanent His-bundle pacing (HBP) has recently been reported to overcome BBB (Sharma et al., 2018). We report a case of conquering the intrinsic RBBB pattern in which the intra-Hisian left bundle branch was captured as a preferred therapy.

2 | CASE PRESENTATION

A 74-year-old man was admitted for recurrent syncope. Sinus bradycardia, RBBB pattern, and 2-degree atrioventricular (AV) block with

2:1 conduction were detected, and pacemaker implantation was suggested. Considering the expected high percentage of ventricular pacing, a physiological modality by using His-bundle pacing (HBP) was recommended. The protocol was approved by the institutional review committee. The patient provided written informed consent.

His-bundle pacing was performed using the Select Secure pacing lead (model 3830, 69 cm; Medtronic Inc.) delivered through a preshaped sheath (C315HIS, Medtronic Inc.). A unipolar electrogram was recorded from the lead tip and displayed on an EP recording system at a sweep speed of 100 mm/s. At mapping the AV septum, the distal multiphasic split His potential suggested an intra-Hisian block (Figure 1a,b). We paced at the assumed location of distal His-bundle in the hope of activating beyond the block. The specific diverse QRS configurations varying with the output settings were noted. Lower output (<5 V/1.0 ms) pacing resulted in an LBBB pattern, QS with a notch at the downslope in V1 and the QRS width of 128 ms, whereas high-output (≥ 5 V/1.0 ms) pacing resulted in a

This is an open access article under the terms of the Creative Commons Attribution-NonCommercial License, which permits use, distribution and reproduction in any medium, provided the original work is properly cited and is not used for commercial purposes.

© 2020 The Authors. *Annals of Noninvasive Electrocardiology* published by Wiley Periodicals LLC

much narrower QRS complex of 106 ms suggesting the His-bundle capture (Figure 1c,d). After the lead's fixation, unipolar pacing with the output of 0.75 V/0.4 ms induced selective intra-Hisian LBB capture, showing as qR in V1, QRS width of 109 ms, and the isoelectric interval between the pacing spike and the QRS (Figure 2b). Higher output (<8.0 V/0.4 ms) unipolar pacing or bipolar pacing induced nonselective LBB capture (increasingly fainter isoelectric interval) without significant change of configuration of QRS and duration. Nonselective His-bundle capture was attained with very high-output (8.0 V/0.4–1.2 ms) bipolar pacing, showing no R wave in V1 and a QRS width of 106 ms (Figure 2c).

3 | DISCUSSION

We have presented a case of intra-Hisian conduction delay with RBBB pattern in whom permanent pacing narrowed the QRS complex by either activating the intra-Hisian left bundle branch (LBBP) or recruitment of the RBB (HBP). This case highlights that LBBP

might serve as an alternative to HBP owing the advantage of a much lower threshold.

In patients with RBBB, RV contracts asynchronously with mostly normal LV activation (Varma, 2009). Routine RV pacing led to local RV myocardium pre-excitation but more pronounced LV activation delay, thus taking the risks of pacing-induced cardiomyopathy for patients expected to receive a high percentage of ventricular pacing. BiV pacing, when delivered to patients with preserved activation via the left bundle, results in iatrogenic prolongation of LV activation time relative to the intrinsic rhythm. Additionally, the LV lead placement might increase the difficulty and time of the procedure. Finally, fewer benefits for patients with RBBB pattern have been reported (Belkin & Upadhyay, 2017).

His-bundle pacing provides a new therapeutic option for patients with an intrinsic RBBB pattern (Sharma et al., 2018). In the prior study, HBP achieved cardiac synchrony in 2 ways: (a) recruitment of RBB with HBP and (b) fusion between HBP (with RBBB pattern) and RV pacing (by using CRT) (Sharma et al., 2018). However, the high threshold for recruitment of RBB or the need for CRT instead

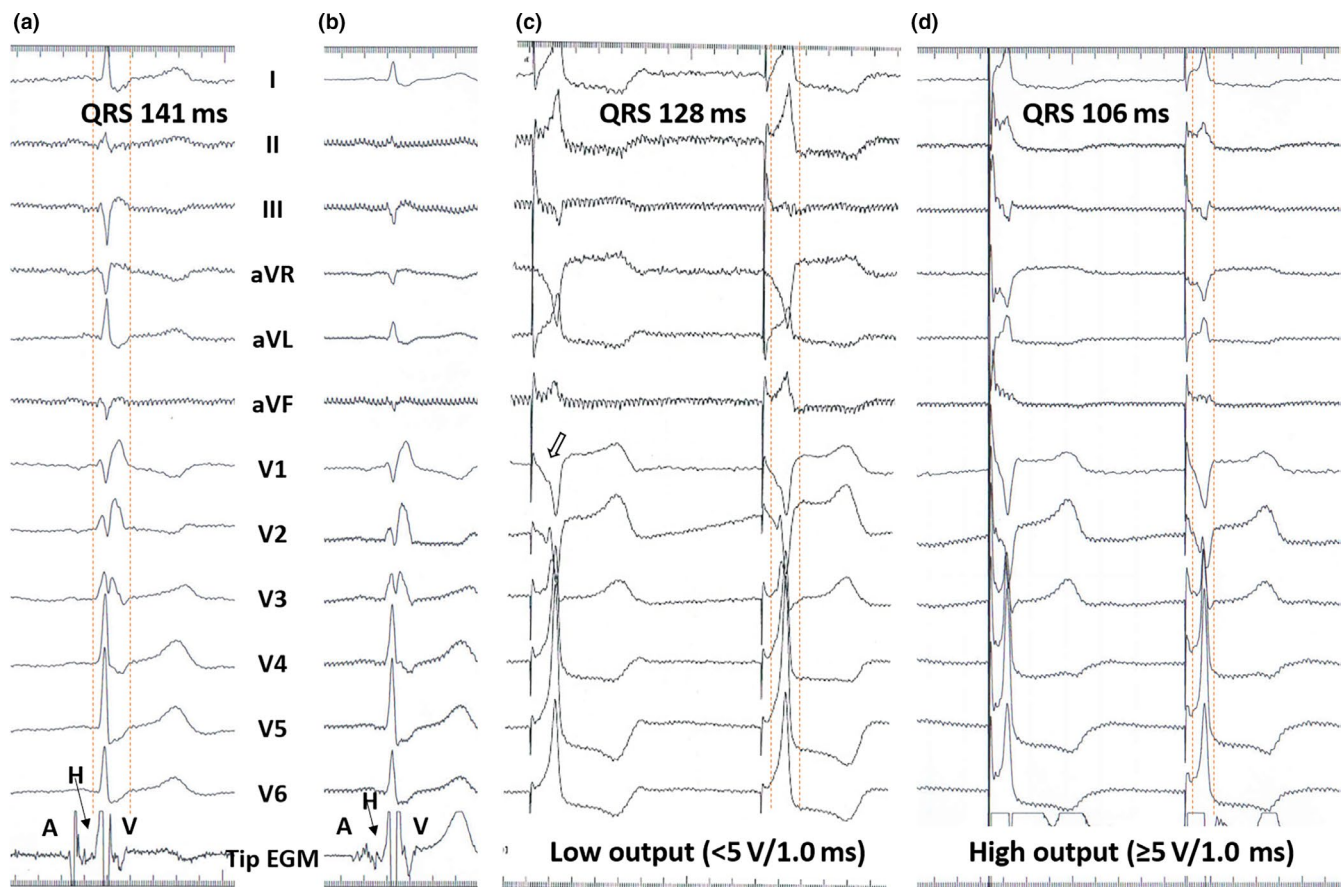


FIGURE 1 (a) Intrinsic RBBB pattern with a QRS width of 141 ms showed in 12-lead ECG. Intracardiac electrogram recorded by the lead tip at the atrial side of the AV septum showed the sharp His-bundle potential (arrow) and atrial and ventricular potentials with the almost equal amplitudes. (b) Intracardiac electrogram recorded by the lead tip at the ventricular side of the AV septum showed the small atrial signals and multiphasic fragmented His-bundle potential (arrow). (c and d) Pacing map of the ventricular side of AV septum before screwing-in the lead. (c) During pacing at the lower output (<5.0 V/1.0 ms), there was a notch at the downslope of the QS pattern in V1 (paced QRS width = 128 ms), indicating high RV septal pacing and predicting future LBB capture after typical evolvement of the notch with fixation of the lead. When pacing at the high output (≥5.0 V/1.0 ms), the abrupt narrower QRS (paced QRS width = 106 ms) indicated the capture of His-bundle and correction of RBBB pattern. Recording speed was 100 mm/s

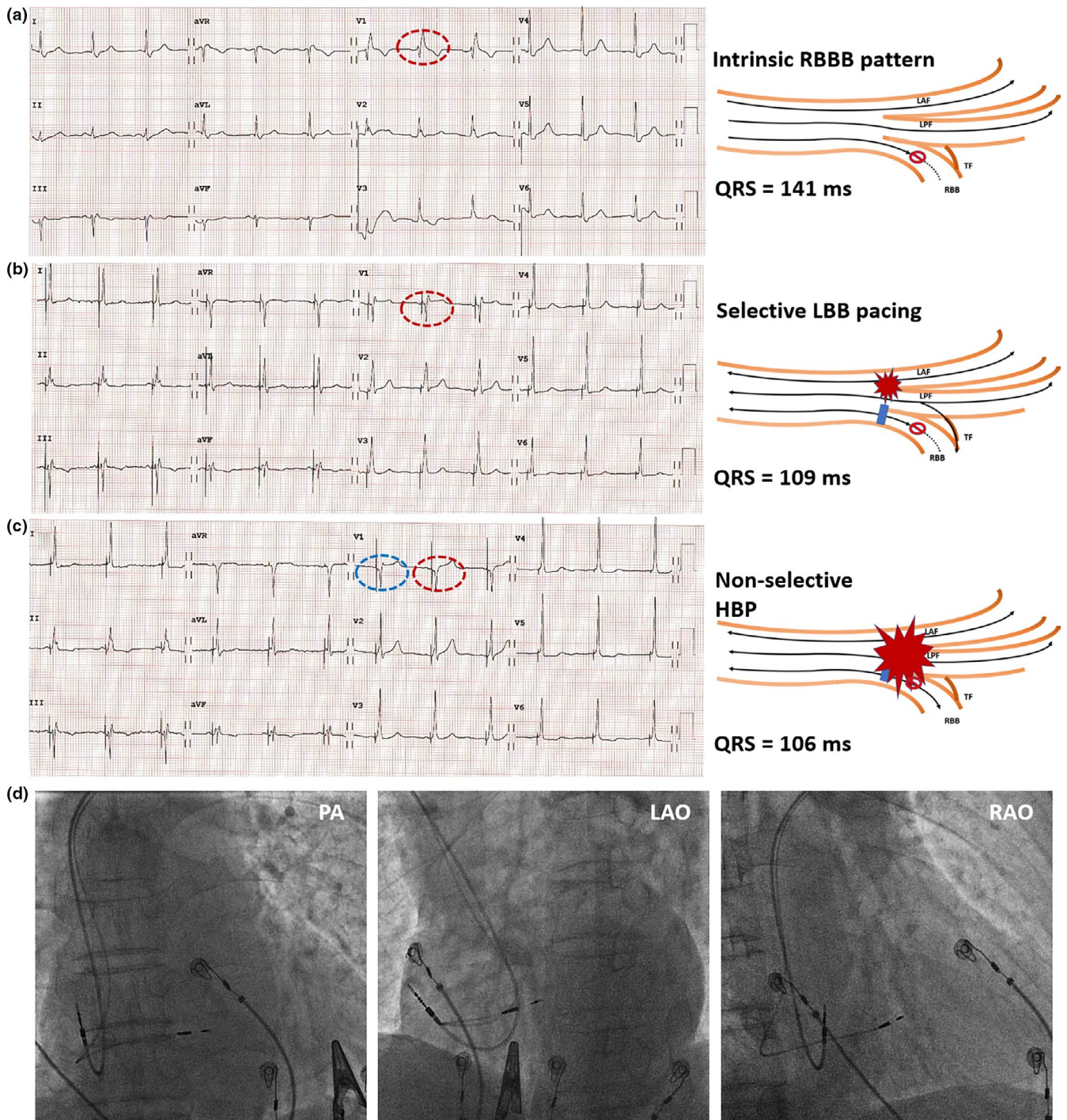


FIGURE 2 Comparisons of 12-lead ECG showed the RBBB pattern at baseline and after the fixation of the lead with different outputs. (a) baseline intrinsic rhythm showed a typical RBBB pattern with the QRS width of 141 ms; (b) unipolar pacing at 0.75 V/0.4 ms captured the intra-Hisian LBB with the resultant qR pattern in V1 (red oval dashed circle) but significantly narrower QRS of 109 ms. The iso-electrical interval between the pacing spike and the onset of the QRS indicated selective capture of the LBB. (c) With bipolar pacing or increasing output unipolar pacing, the qR pattern remained in V1 (blue oval dashed circle), but iso-electrical intervals faded (suggesting nonselective LBB capture), and finally, R wave disappeared in V1 (red oval dashed circle) and narrow QRS of 106 ms indicated His-bundle captured with RBB recruitment. The recording speed was 25 mm/s. Schematic representation of the site of RBBB and capture of intra-Hisian LBB and His-bundle are shown at the sides of the ECG. The intra-Hisian LBB capture might activate the RBB by transverse interconnections and result in a similar later activation manner as in HBP. (d) Final lead locations showed in fluoroscopic images. Abbreviations: LAF, left anterior fascicle; LAO, left anterior oblique projection; LPF, left posterior fascicle; PA, posterior-anterior projection; RAO, right anterior oblique projection; RBB, right bundle branch; TF, transverse interconnective fibers

of a conventional pacemaker compromised the cost-benefit ratio of the therapy. Recently, LBBP has been reported to correct LBBB and maintain LV electrical synchrony with a low and stable threshold (Chen, Wu, Su, Su, & Huang, 2019; Huang et al., 2017). The RBBB pattern created by LBBP, though, potentially forecasts its futility in the correction of intrinsic RBBB. Despite this, we have presented a possible usage of LBBP in this scenario.

Initially planning as HBP, we have noticed the QRS figuration changes with pacing output increased when we mapped at the peri-Hisian area. The notch at the downslope of the QS pattern in V1 before the fixation of the lead suggested further evolvement of the QRS with screw-in the lead and capture of LBB (Chen et al., 2019). After the fixation of the lead, intra-Hisian selective LBB capture was accomplished by very low output of unipolar pacing and resulted in a qR pattern in V1 yet significantly narrower QRS than intrinsic RBBB pattern. The intra-Hisian LBB capture was supported by the atrial signal recorded at the pacing location and His-bundle potential instead of LBB potential found. The longitudinal dissociation in the His-bundle makes a perfect explanation for this phenomenon. The pacing site was probably proximal to the conduction delay/block, so that low-output pacing only activated healthy LBB, whereas very high-output pacing can recruit distal RBB and resulted in unanimous activation of the His-Purkinje system. Furthermore, the intra-Hisian LBB capture might activate the RBB by transverse interconnections (Lazzara, Yeh, & Samet, 1973) and result in a similar later activation manner of QRS as in HBP of the narrowed QRS. Besides, the LBB pacing might lead to the virtual electro-depolarization (VEP) effect (Sepulveda, Roth, & Wikswo, 1989; Sharma, Huizar, Ellenbogen, & Tan, 2016), by which a stimulus creates regions of depolarization and hyperpolarization in the vicinity of the pacing electrode, resulting in the propagation through previously refractory tissue, as in diseased RBB.

One might argue that the typical LBB area pacing, in contrast to intra-Hisian LBB capture, would create RBBB morphology and might not be narrower than the intrinsic ones. However, the RBBB pattern created in LBBP is a reflection of the relative delay of the activation among the rest conduction system in comparison with LBB. The general LV electrical synchrony is preserved because the impulse propagates rapidly through intact LBB. Additionally, the VEP effect and the transverse interconnections might well contribute to more synchronized global activation. All these provide benefits beyond the sole narrowness of QRS.

We admit that HBP, representing the most physiological pacing modality, has the advantage to potentially correct otherwise delayed RV contraction in patients with intrinsic RBBB, which creates the ideal homogeneous activation of the whole His-Purkinje system and results in synchronization to the maximum. However, challenges lie in the high threshold for recruitment of RBB, developing conduction disease, future loss of capture and early drainage of the battery. LBBP, in contrast, maintains the synchrony of the LV as the predominant contributor to cardiac function with a low and stable threshold as we have shown. Technically, hypertrophic and fibrotic interventricular septum might be a limitation for LBBP. When the

advancement of the fibrosis precludes the successful capture of the LBBP, attempts by switching back to HBP or exploration LBBP in another location could be considered.

4 | CONCLUSIONS

The present case suggests a new therapeutic option by pacing LBB for patients with RBBB pattern in whom ventricular pacing is expected to predominate. This pacing manner provides more physiological activation than traditional RV pacing or BiV pacing. Most importantly, LBBP has the advantage of a much lower and stable threshold compared to HBP. The feasibility and efficacy of this treatment strategy need further evaluation in large cohorts and long-term follow-up.

ACKNOWLEDGMENTS

This study was supported by the youth clinical research project of Peking University First Hospital (No. 2017CR20). We thank Xue-Mei Zhang, Zi-Ming Wang, and Wen-Ye Wang for their assistance with image recording, acquisition, and processing.

CONFLICTS OF INTEREST

None declared.

AUTHOR CONTRIBUTIONS

Song-Yun Chu: Conceptualization, Project administration, Writing - original draft, Writing - review & editing. Qin-Hui Sheng, Er-Dong Chen, Han, Jin: Investigation, Writing - review & editing. Jie Jiang, Yu-Ling Wang, Peng-Kang He: Investigation, Methodology, Follow-up, Data curation; Jing Zhou, Yan-Sheng Ding: Supervision, Writing - review & editing.

ETHICAL APPROVAL

The study was performed in accordance with the Declaration of Helsinki and was approved by the institutional review board of our center.

ORCID

Song-Yun Chu  <https://orcid.org/0000-0003-4042-4054>

REFERENCES

- Belkin, M. N., & Upadhyay, G. A. (2017). Does cardiac resynchronization therapy benefit patients with non-left bundle branch block prolonged QRS patterns? *Current Cardiology Reports*, *19*, 125. <https://doi.org/10.1007/s11886-017-0929-8>
- Chen, X., Wu, S., Su, L., Su, Y., & Huang, W. (2019). The characteristics of the electrocardiogram and the intracardiac electrogram in left bundle branch pacing. *Journal of Cardiovascular Electrophysiology*, *30*, 1096-1101. <https://doi.org/10.1111/jce.13956>
- Huang, W., Su, L., Wu, S., Xu, L., Xiao, F., Zhou, X., & Ellenbogen, K. A. (2017). A novel pacing strategy with low and stable output: pacing the left bundle branch immediately beyond the conduction block. *Canadian Journal of Cardiology*, *33*(1736), 1736.e1-1736.e3. <https://doi.org/10.1016/j.cjca.2017.09.013>

- Lazzara, R., Yeh, B. K., & Samet, P. (1973). Functional transverse interconnections within the His bundle and the bundle branches. *Circulation Research*, 32, 509–515. <https://doi.org/10.1161/01.RES.32.4.509>
- Sepulveda, N. G., Roth, B. J., & Wikswo, J. P. Jr (1989). Current injection into a two-dimensional anisotropic bidomain. *Biophysical Journal*, 55, 987–999. [https://doi.org/10.1016/S0006-3495\(89\)82897-8](https://doi.org/10.1016/S0006-3495(89)82897-8)
- Sharma, P. S., Huizar, J., Ellenbogen, K. A., & Tan, A. Y. (2016). Recruitment of bundle branches with permanent His bundle pacing in a patient with advanced conduction system disease: What is the mechanism? *Heart Rhythm: The Official Journal of the Heart Rhythm Society*, 13, 623–625. <https://doi.org/10.1016/j.hrthm.2015.11.012>
- Sharma, P. S., Naperkowski, A., Bauch, T. D., Chan, J. Y. S., Arnold, A. D., Whinnett, Z. I., ... Vijayaraman, P. (2018). Permanent his bundle pacing for cardiac resynchronization therapy in patients with heart failure and right bundle branch block. *Circulation: Arrhythmia and Electrophysiology*, 11, e006613. <https://doi.org/10.1161/CIRCEP.118.006613>
- Varma, N. (2009). Left ventricular conduction delays and relation to QRS configuration in patients with left ventricular dysfunction. *American Journal of Cardiology*, 103, 1578–1585. <https://doi.org/10.1016/j.amjcard.2009.01.379>

How to cite this article: Chu S-Y, Sheng Q-H, Chen E-D, et al. Is the left bundle branch pacing a choice to conquer the right bundle branch block?—A case report. *Ann Noninvasive Electrocardiol*. 2021;26:e12797. <https://doi.org/10.1111/anec.12797>