

# A 3-year prospective cohort study on mandibular anterior cantilever restorations associated with screw-retained implant-supported prosthesis: An *in vivo* study

Vizaikumar Vasudha Nelluri, Kandathilparambil Maria Roseme<sup>1</sup>, Rajani Kumar Gedela<sup>2</sup>

Department of Prosthodontics, Government Dental College and Hospital, Hyderabad, Telangana, <sup>1</sup>Department of Prosthodontics, S B Patil Dental College and Hospital, Bidar, Karnataka, <sup>2</sup>Department of Periodontics, Army College of Dental Sciences, Secunderabad, Telangana, India

**Abstract:** **Aim:** The aim of this study is to evaluate the survival of single implant supported cantilever prosthesis (ISCP) replacing missing two adjacent natural teeth in the anterior mandible.

**Settings and Design:** *In vivo* - Prospective cohort study.

**Materials and Methods:** Thirty patients with missing both mandibular central incisors were selected. A single implant was used to replace the missing teeth and restored with cantilever screw-retained prosthesis. Twenty-two patients were followed for 3 years for the implant and prosthetic success.

**Statistical Analysis Used:** Weibull test for survival probability.

**Results:** Survival probability of the ISCP for the first 100 days was found to be 97.55%, for 200 days, it was 71.4%, for 250 days, it was 46%, and for 365 days, it was 3.9%, i.e., 20 prosthesis had screw loosening after prosthetic loading. However, it increased to 95.2% at the end of 3 years.

**Conclusion:** Screw-retained ISCP developed early technical complications. After prosthetic loading, the survival probability of the screw-retained ISCP was very low (3.9%) at one year, which increased to 95.2% after retightening and retorquing of the abutment screw, porcelain repair and conformation of the tongue to the prosthesis. The most common prosthetic failure was screw loosening (81%), followed by porcelain fracture (14.3%), and implant survival of 95% at the end of three years.

**Keywords:** Anterior guidance, anterior region, implant-supported cantilever prosthesis, internal hex, porcelain fracture, prospective study, prosthetic failure, screw loosening, survival probability

**Address for correspondence:** Dr. Kandathilparambil Maria Roseme, H. No; 18-8-278/10, New Rakshapuram, Uppuguda, Charminar, Hyderabad, Telangana, India.

E-mail: roseme.maria@gmail.com

**Submitted:** 02-Sep-2020, **Revised:** 24-Mar-2021, **Accepted:** 05-Apr-2021, **Published:** 28-Apr-2021

## INTRODUCTION

Loss of teeth leads to difficulty in mastication, poor esthetics, and altered speech and also affects the quality

of life of an individual. Various causes of tooth loss may be congenital,<sup>[1-4]</sup> pathologic, and traumatic.<sup>[5]</sup> Loss of maxillary and mandibular anterior teeth has shown serious

Access this article online	
Quick Response Code:	Website: www.j-ips.org
	DOI: 10.4103/jips.jips_446_20

This is an open access journal, and articles are distributed under the terms of the Creative Commons Attribution-NonCommercial-ShareAlike 4.0 License, which allows others to remix, tweak, and build upon the work non-commercially, as long as appropriate credit is given and the new creations are licensed under the identical terms.

**For reprints contact:** WKHLRPMedknow\_reprints@wolterskluwer.com

**How to cite this article:** Nelluri VV, Roseme KM, Gedela RK. A 3-year prospective cohort study on mandibular anterior cantilever restorations associated with screw-retained implant-supported prosthesis: An *in vivo* study. J Indian Prosthodont Soc 2021;21:150-60.

esthetic<sup>[6]</sup> and phonetic<sup>[7]</sup> considerations, respectively, to most of the individuals. The various treatment options available include removable partial dentures (RPDs),<sup>[8]</sup> resin bonded/glass fiber-reinforced prosthesis,<sup>[9]</sup> fixed partial dentures (FPDs),<sup>[10]</sup> and implant-supported fixed prosthesis (ISP).<sup>[11]</sup> RPDs are bulky and need removal from the oral cavity for hygiene maintenance, minimally invasive resin-bonded bridges have shown poor longevity and FPD require preparation of supporting tooth structures. Among all the modalities, ISP is naturally appearing and less damaging to the adjacent tooth structures.

These ISP may be single or multiple implant-supported restorations and also cantilever prosthesis. The appreciably high clinical success rate of single and multiple ISP restored with implant protected occlusion in situations of adequate bone support has been well known.<sup>[12]</sup> ISP with cantilever molar extensions is usually unilateral/full mouth restorations in the clinical conditions of resorbed maxillary or mandibular posterior ridges.<sup>[13-15]</sup> Anterior cantilever extensions are usually given in missing two adjacent maxillary/mandibular teeth such as both incisors or incisors and canine.<sup>[16-18]</sup>

However, complications have also been reported with ISP which may be at implant or surgical and/or prosthetic level.<sup>[19]</sup> Prosthetic complications reported are porcelain veneer fracture,<sup>[20]</sup> abutment screw fracture,<sup>[21]</sup> in screw and cement-retained prosthesis,<sup>[22]</sup> and screw loosening.<sup>[23-25]</sup> Zurdo *et al.* in a systematic review on the survival and complication rates of implant-supported FPD with cantilevers concluded that cantilever extension has minor technical complications and stated that limited data were available. However, the study does not specify anterior or posterior cantilevers.<sup>[26]</sup> Aglietta *et al.* assessed the survival rates of short-span implant-supported cantilever fixed dental prostheses and concluded that cantilevers showing not much detrimental effects and is a valid treatment modality.<sup>[27]</sup> Aglietta *et al.* in a retrospectively study concluded that one cantilever extent mesial/distal in the posterior maxilla or mandible showed minimal bone changes comparable to implants supporting single-unit crowns.<sup>[28]</sup> Wu *et al.* evaluated the clinical results of the mandibular anterior implant-supported fixed bridges with a cantilever and reported good implant survival without technical complications and also suggested further studies to evaluate their long-term therapeutic efficiency.<sup>[17]</sup>

There is a lacuna with regard to prosthetic/technical complications with implant-supported cantilever prosthesis (ISCP) in the anterior region which usually act as guiding restorations both in group function and mutually

protected occlusion. Freedom in the retrusion/protrusion range on cantilever, anterior guided lateral movements, and the absence of nonworking side contacts on the cantilever FPD were advocated by Laurell *et al.* considering the biomechanical factors.<sup>[29]</sup> To reduce the occlusal overload and implant prosthetic failure, centric contacts, anterior guidance, and shallow anterior angle was suggested by Jamcoski *et al.*<sup>[30]</sup> Sheridan *et al.* recommended a mutually protected occlusion with anterior guidance and evenly distributed contacts with wide freedom in centric relation.<sup>[31]</sup> In order to fulfil the esthetic and phonetic requirements in the anterior regions, it is impossible to totally avoid anterior guidance as suggested with ISP. Anterior guidance generates oblique forces, which may lead to technical complications. Hence, there is a need to understand the prosthetic/technical complications with anterior ISCP. Moreover, there are no adequate *in-vivo* studies on single implant-supported screw-retained cantilever prosthesis in mandibular anterior region, which has been a treatment option for edentulous sites with inadequate mesio-distal space.<sup>[16-18]</sup>

The present prospective cohort study aimed to evaluate the survival of a single implant-supported cantilever prosthesis (ISCP) replacing two missing adjacent natural teeth in the anterior mandible over a period of 3 years. The null hypothesis of the study was that prosthetic complications are not associated with screw-retained ISCP in the mandibular anterior region.

## MATERIALS AND METHODS

The present prospective cohort study which was carried out as per STROBE (2007) guidelines included 30 patients, both male (18) and female (12) within the age group of 25–50 years for a period of 3 years from the Outpatients, Department of Prosthodontics, Crown and Bridge of the Institute from June 2015 to May 2018. Growth completion was confirmed with hand-wrist radiographs for patients around 25 years of age. Written consent was obtained from the patients before the surgical procedure. Ethical committee approval was obtained from the Institutional Ethical Board (Lt. No. IEC/IDS/2015-16:13) and the study was conducted in accordance with the ethical principles mentioned in the Declaration of Helsinki (2013).

The patients with missing both mandibular central incisors due to congenital anodontia/hypodontia and/or trauma; the edentulous regions with adequate bone width and height, adequate inter-occlusal clearance, insufficient mesio-distal width (available space <12 mm which cannot accommodate two narrow diameter two-piece implants)

and the occlusal schemes, canine guided or group function were the inclusion criteria.

Patients with tooth loss due to traumatic occlusion and periodontal disorders, parafunctional habits such as tongue thrust and bruxism, severe occlusal wear, immune-compromised conditions, and on medication/physiological conditions known to affect wound and bone healing were the exclusion criteria.

Armamentarium used for implant placement included Physiodispenser (WH Si-923 Implant Motor Physiodispenser, Querencia Meditech Pvt. Ltd., Pune, Maharashtra, India) and the surgical kit (Adin Dental Implant Systems Ltd., Israel). Radiographic evaluation was made using the intra-oral periapical radiographs (E-Speed, Care Stream Health Inc., New York, USA, 14608), which were scanned with the digital scanner (Epson V700, Dual Lens System) and the images were inverted in vista dent database server (Digital Cephalometric Analyzing Tool, Version-4.2.1[29]). Clinical evaluation was performed using the regular examination instruments such as mouth mirror and straight explorer (Ruby Dental Pvt. Ltd., Delhi, India).

After intra-oral and the diagnostic cast's examination, presurgical evaluation was initiated. It included laboratory investigations, radiological examinations using orthopantomographs and cone-beam computed tomography. A single titanium alloy, two-piece endosseous internal hex dental implant (Toureg S, Adin Dental Implant Systems Ltd., Israel) of 3.5 mm diameter and 13 mm length was planned for surgical placement by the Periodontists and Oral surgeons of the Institute.

Oral health and hygiene of the participants were improved by prescribing the usage of Chlorhexidine mouth wash 2–3 times daily, 3 days prior surgery. The participants were premedicated with suitable antibiotics, anti-anxiety drugs 1 day before the surgery.<sup>[32]</sup>

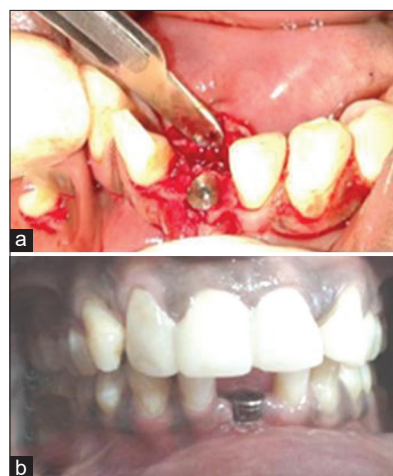Strict sterilization protocol was followed as per the Occupational Safety and Health Administration guidelines. The lower anterior edentulous surgical site was anesthetized by infiltration of 2% lignocaine with 1:100,000 epinephrine (Indoco Remedies Ltd., Gujarat, India), a mid-crestal incision, slightly lingual was made using B. P. knife (Ruby Dental Pvt. Ltd., Delhi, India) and muco-periosteal flap was raised. Drilling/osteotomy was performed using the Physiodispenser (WH Si-923 Implant Motor Physiodispenser, Querencia Meditech Pvt. Ltd., Pune, Maharashtra, India) using drills from the surgical kit (Adin

Dental Implant Systems Ltd., Industrial zone Alon Tavor, POB 1128, Afula 1811101, Israel).

The lower anterior mandible is of D1/D2 bone quality. The osteotomy was performed intermittently under copious irrigation throughout the procedure with cool sterile saline solution at appropriate torque and speed as it is more susceptible to heat generation. After implant placement, the periosteal flap sutured carefully with 3-0 black nonabsorbable silk suture (Silk braided – Jackson sutures, USA). Sutures were removed after 7–10 days. Radiographs were recorded to assess the marginal bone.

Delayed loading protocol (i.e., after 3–4 months) of all the implants was planned. Second stage surgery was performed incising the mucosa to expose the implants and the cover screw was replaced with a healing screw [Figure 1a and b] of the same system, and the mucosa was repositioned and sutured.

One week later, closed tray implant impressions were made with an addition silicone impression material (Aquasil, Soft Putty and Light body, Dentsply, Germany) by the single-stage impression technique using a stock tray. The dental stone cast (Kala stone, Kalabhai Dental Products Pvt. Ltd., Mumbai, Maharashtra, India) was prepared placing the implant analog and closed tray transfer unit assembly. On the obtained cast, an engaging castable abutment with internal hex (Adin Dental Implant Systems Ltd., Israel) was positioned on to the implant analog. A wax pattern of two central incisors was built on the castable abutment using blue inlay wax (Bego crown wax, Bremer Gold schlagerei Wilh. Herbst GmbH andamp; Co. KG Bremen, Germany) leaving screw access channel lingually for placing the abutment screw. The patterns were cast in a base metal



**Figure 1:** (a) Implantation in the mandibular anterior region (b) Gingival former placed on the mandibular single anterior implant

alloy (Wiron 99, BEGO, Goldschlagerei Wilh. Herbst GmbH andamp; Co. KG Bremer, Germany) using lost wax technique. Its metal trial was done, and the fit was evaluated radiographically [Figure 2a-d]. Later, porcelain (VITA VMK Master, Vita ZahnfabrikH. Rauter GmbH and Co. KG, Germany) was layered according to the manufacturer's instructions. The two central incisors were contoured with a fine-grained bur monitoring the anatomy. Pink porcelain was added to produce natural gingival contours.

Bisque trial and occlusal adjustment were made to minimize occlusal stresses on the ISCP, with no incisal contact in the centric position, shallow anterior angle providing wide freedom in centric relation, anterior guidance with evenly distributed contacts.<sup>[30,31]</sup> After glazing, the finished prosthesis was screw retained using an abutment screw, tightening it to a torque of 30 Ncm (recommended torque by the manufacturer sufficient to elongate and produce tension/preload within the screw joint) using a torque wrench (Adin Dental Implant Systems Ltd., Israel) on the lower anterior implant through a lingually placed access hole. The gingival one-third of the access channel was packed with gutta-percha (Dentsply India Pvt. Ltd., Noida, India) for easy retrievability and occlusal two-thirds was filled with Glass Ionomer cement (GC FUJI 9, GC Corporation, Tokyo, Japan) and smoothly polished. In all the patients, both central incisor teeth were restored with ISCP with the cantilever extent of 1–1.5 mm [Figure 3a-c]. All the participants were given oral hygiene instructions and advised a regular recall visit every 3 months/or to report if any troubleshooting.

All the patients were evaluated for their oral hygiene maintenance using plaque and gingival indices, marginal

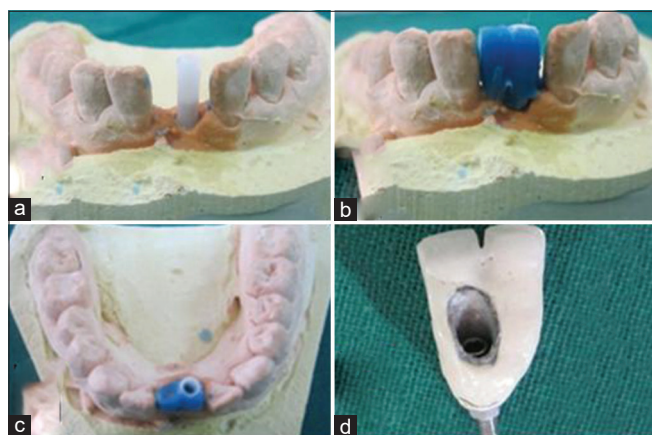
bone loss around the implant, and integrity of the prosthesis such as screw loosening and porcelain fracture.

Marginal bone loss around each implant was assessed by intra-oral periapical radiographs recorded using the paralleling cone technique (RinnXcp Apparatus, Paralleling Cone Technique Device, Manufactured by Sensibles, Universal X-Ray Holder, Flow Dental, and 100West Industry, New York). To calculate the marginal bone loss the intra-oral periapical radiographs (E-Speed, Care Stream Health. Inc., New York, USA, 14608) were scanned with the digital scanner (Epson V700, Dual Lens System) and the images were inverted in vista dent database server (Digital Cephalometric Analyzing Tool, version-4.2.1 [29]). The inverted images are uploaded in the Image] Analysis Software [National Institute of Health (NIH), Bethesda, MD & Laboratory for Optical and Computational Instrumentation (LOCI), University of Wisconsin, Madison, United States] to measure the crestal bone loss.

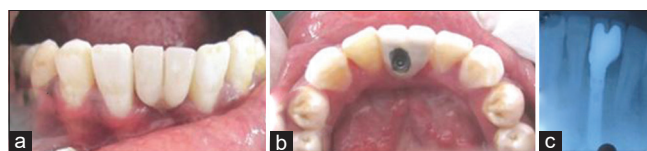
Screw loosening of the prosthesis was evaluated on recall visits by the application of horizontal force using the blunt end of the explorer on the prosthesis. It was confirmed radiographically by the visible gap between the implant and prosthetic margin and unseating of the prosthetic hex from the implant.

Porcelain fractures were clinically inspected under adequate light, and all observations were tabulated with time. Debonding of ceramic from the metal surface (adhesive fracture) was excluded and ceramic chipping (co-adhesive fractures) was only considered.<sup>[33]</sup> Periodontal diseases, high frenal attachment causing gingival recession, and traumatic occlusion were found to be the confounding factors.

The sample size of 30 patients was included in the study based on the availability of treated patients in the department, but only 22 participants were available for regular follow-up of 3 years. All the observations were made by a single operator and potential sources of bias were eliminated by double blinding. The patient's records and the study outcome at every recall visit were concealed to the assessor by providing a checklist so that the relevant values of plaque and gingival indices, marginal bone loss, screw loosening by tactile perception and radiological examination, and porcelain



**Figure 2:** Laboratory steps in the fabrication of cantilever prosthesis (a) Castable abutment placed upon the implant analogue over the patients working model (b) Built up of the wax pattern on the working model (c) Labial view (d) Screw retained cantilever definitive fixed partial denture



**Figure 3:** Definitive prosthesis insertion (a) Labial view (b) Lingual view (c) Postoperative periapical radiograph

fracture (present or absent) are noted and handed over to the personnel for documentation. The collected data were tabulated and subjected to the statistical analysis.

**Statistical methods**

The data collected after a follow-up period of 3 years (1095 days) of all the restored implants were entered in MS office excel and were transferred into Statistical Software Minitab® version 19.2020.1 (Minitab, LLC, State College, Pennsylvania, United States) (64-bit) and the probability of failure as a function of time (in days) was evaluated using Weibull test. In the distribution overview plot of screw loosening, day 1 indicates the day of prosthetic loading, i.e., 3–4 months after implantation each participant [Figure 4].

**RESULTS**

Out of all 30 patients, 22 patients with implant restorations were followed for a period of 3 years (1095 days). The health of soft tissues around implants was assessed as per the grades suggested by Loe and Silness plaque index; oral hygiene was assessed as suggested by Quingley and Hein Gingival Index every 3 months. It was observed that the oral hygiene of all the restored participants had been satisfactory.

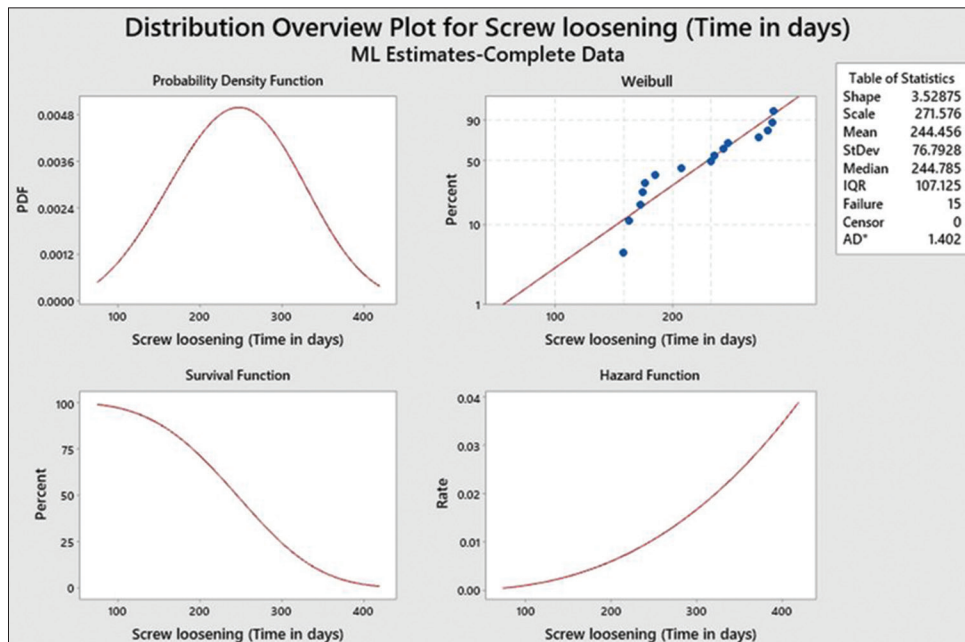
On the radiographic evaluation of 22 implants, the crestal bone loss was comparative to the individual implant-supported prosthesis (i.e.) <0.2 mm at the end of each year, no clinical mobility and peri-implant radiolucency was seen, except one implant which showed mobility and peri-implant radiolucency at the end of 3 months after

implantation leading to a cumulative implant survival rate of 95% at the end of 3 years [Table 1].

Abutment screw loosening was noticed in 07 out of 21 implants at 06 months, 04 implants at 09 months, 04 implants at 1 year after restoration, and 05 implants had *in situ* abutment screws showing 71% screw loosening at the end of 1 year. Clinical follow-up after employing maximum preload, i.e., retightening and retorquing after 10 min with a new abutment screw of the same manufacturer showed no further screw loosening of the prosthesis except in two cases at 2.5 years leading to a cumulative screw loosening of 81% at the end of 3 years [Figure 5a and b].

Porcelain veneer fracture was reported in 03 patients at 06 months recall showing 14.3% ceramic fracture at the end of 1 year. Porcelain repair was done with repair ceramics. No further fractures were reported resulting in no rise in the cumulative ceramic fracture value of 14.3% at the end of 3 years [Table 2].

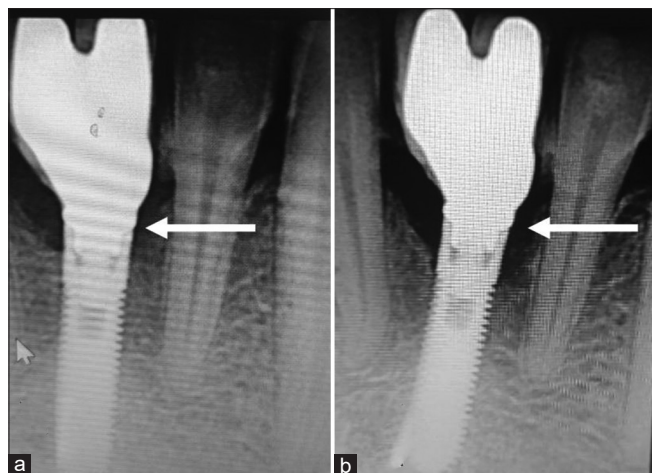On statistical analysis using the Weibull test, the survival probability of the prosthesis for the first 100 days was found to be 97.55%, for 200 days, it was 71.4%, for 250 days, it was 46%, and for 365 days or 1 year, it was 3.9%, i.e., 20 cantilever prosthesis had screw loosening after prosthetic loading. Retightening and retorquing after 10 min and porcelain repair of the prosthesis during the recall visits, the survival probability increased to 95.2% at the end of 3 years [Figure 4].



**Figure 4:** The probability of failure as a function of time (in days) evaluated using the Weibull test

**Table 1: Sequence of implantation, treatment time, observations and maintenance of implant-supported cantilever prosthesis for three years (in days showing the timing of implant & prosthetic failures)**

Patient number	Implant insertion day	Implant failure on day	Prosthesis delivery (3-4 months) on day	Screw loosening on day	Porcelain fracture on day	Screw loosening after retightening and retorquing on day	Porcelain fracture after repair on day
1	1	-	93	250	-	-	-
2	1	-	95	150	-	910	-
3	1	-	95	-	155	-	-
4	1	95	-	-	-	-	-
5	1	-	112	155	-	-	-
6	1	-	124	-	180	-	-
7	1	-	120	255	-	-	-
8	1	-	90	165	-	-	-
9	1	-	111	270	-	-	-
10	1	-	96	278	-	-	-
11	1	-	95	170	-	-	-
12	1	-	94	168	-	-	-
13	1	-	100	180	-	940	-
14	1	-	130	-	157	-	-
15	1	-	112	332	-	-	-
16	1	-	102	350	-	-	-
17	1	-	111	210	-	-	-
18	1	-	99	-	-	-	-
19	1	-	95	360	-	-	-
20	1	-	98	-	-	-	-
21	1	-	120	362	-	-	-
22	1	-	112	-	-	-	-



**Figure 5:** Intra-oral periapical radiographs (a) Definitive prosthesis at insertion with total seating of abutment hex (b) Screw loosening with visible gap between implant and prosthetic margin

## DISCUSSION

### Rationale behind the treatment plan:

Clinical situation addressed in the present observational study is the absence of two adjacent teeth in the esthetic zone, the mandibular right and left central incisors. Therapeutically, due to insufficient space for two implants, the placement of only one implant is suggested between the mandibular laterals speculating a better clinical performance<sup>[34]</sup> by the formation of biologic space around titanium implants.<sup>[35]</sup> Lack of biologic space leads to rapid resorption of bone crest around the implant platform followed by the exposure of titanium to the

oral environment. Placement of a single implant would preserve the papilla between the tooth and implant and maintains the gingival contour as there would be no bone crest resorption.<sup>[17]</sup>

According to Dr. Woelfel's original research data, an average width of the root at the cervix is 3.5 mm (ranging from 2.7 to 4.6 mm), the mesio-distal crown width is 5.3 mm (ranging from 4.4 mm to 6.7 mm) of an adult mandibular central incisor.<sup>[36]</sup> In the present cases, mesio-distal length of the available bone is 11 mm and two mandibular central incisor crowns can be comfortably accommodated but not two implants as the inter-implant distance (3 mm),<sup>[37]</sup> implant body to natural tooth distance on both sides (1.5 mm × 2 mm = 3 mm) and two implant diameter (3.5 mm × 2 mm = 7 mm) totally needs a mesio-distal length of 13 mm. Thus, placing two narrow-diameter implants in the edentulous site (3.5 mm) would make it difficult to accommodate for the surgical, periodontal, and prosthetic requirements.<sup>[38]</sup> These dimensions quote the crest module dimensions which are wider than implant body dimensions. Hence, a single two-piece implant was planned in the edentulous sites included in the present study. However, meticulous daily oral hygiene was suggested to avoid food entrapment under the cantilever prosthesis of the prosthesis. The two crowns were splinted together and designed to use oral hygiene aids to allow healthy inter-proximal regions.

**Table 2: Clinical outcome of implant-supported cantilever prosthesis every 3 months with respect to the observed variables**

Time in months	Number of implants with screw loosening	Number of implants with porcelain fracture	Cumulative incidence of screw loosening (%)	Number of implants failed out of 22	Cumulative incidence of porcelain fracture (%)
0	-	-	-	-	-
3	-	-	-	1	-
6	7	3	33.3	-	14.3
9	4	-	53.4	-	-
12	4	-	71	-	-
15	-	-	-	-	-
18	-	-	-	-	-
21	-	-	-	-	-
24	-	-	-	-	-
27	-	-	-	-	-
30	2	-	81	-	-
33	-	-	-	-	-
36	-	-	-	-	-

However, placement of two single-piece implants were not opted to restore lost both mandibular central incisors as the available bone in the anterior region is lingual to the arch form and the final restoration would be lingually positioned. Single-piece implants offer a very little scope for the correction of prosthetic position, whereas two-piece implants can support straight, angulated as well as castable abutments.

**Loading protocol**

Late or delayed loading, i.e., leaving for 3–4 months for osseointegration<sup>[39]</sup> of all the implants was done followed by restoration with screw-retained ISCP. However, various loading techniques showed no difference in implant failure rate.<sup>[40]</sup>

**Biomechanics**

The success of implants depends on the number of implants, their diameter and length, occlusal pattern and prosthesis design.<sup>[41]</sup> These factors also influence the biomechanical integrity of implant prosthesis. The biomechanical longevity of ISCP in the mandibular anterior region was anticipated because occlusal forces in this region were reported to be less than half the value observed in the posterior region.<sup>[42]</sup> Furthermore, dense cortical bone (D1 bone) in the mandibular anterior region found in 6% of anterior mandibles<sup>[43]</sup> gives rigid fixation after implant placement and promotes better osseointegration. This homogenous dense cortical lamellar bone heals with little interim woven bone formation ensuring excellent bone strength next to the implant.<sup>[44,45]</sup> Hence, there was a 95% cumulative implant survival rate at the end of 3 years in the present study.

**Force factors**

Prosthetic/technical failures are of concern in the mandibular anterior regions where in the tongue accommodates to the available space with increase in size leading to an aberrant

tongue position. Placement of implant and prosthetic teeth in these sites results in lateral force, which may be continuous on to the implants and prosthesis.<sup>[46]</sup>

Although all the participants had no para-functional habits, which was one of the exclusion criteria in the present study, horizontal forces by tongue and extra-oral musculature are anticipated due to the nonacclimatization of the restorations which affects the biomechanical longevity of implants.<sup>[47]</sup>

**Screw loosening**

The most common prosthetic complication was screw loosening (81%) observed in the present study over a period of 3 years. Some of the reasons for prosthetic complications such as screw loosening are implant and abutment connection design, an improper fit of the framework, insufficient torque for abutment screw tightening, loss of preload of the abutment screw, and overload on the prosthesis.<sup>[48-50]</sup> Kreissl *et al.* in their study stated that at the end of 5 years, a cumulative incidence of screw loosening was 6.7%, screw fracture was 3.9%, and porcelain fractures was 5.7% with single implant crowns. However, the complications with cantilever prosthesis were high, 68.6%; these results seemed closer to our study.<sup>[51]</sup> A meta-analytic study by Pjetursson *et al.* showed a cumulative incidence of 5.8% of screw loosening or fracture.<sup>[52]</sup> Most studies mention the distal cantilever extension of more than 4 mm, but the present study differs being specific to the mandibular anterior restorations with a minimal cantilever prosthesis arm of 1–1.5 mm, which was not reported earlier.

In addition, rotation of the prosthesis and screw loosening was reported with casted abutment with defective hexagon.<sup>[53]</sup> To prevent screw-loosening, abutment screw tightening with mechanical torque device is mandated as handheld drivers produce varied torques.<sup>[54]</sup>

In the present study, all the abutments were casted, evaluated for casting defects and later abutment screw was tightened using the torque wrench. Initial torque of 30 N was given to produce preload as recommended by the manufacturer sufficient to create clamping force. For the screw to remain tight, the clamping forces should be greater than the separating forces, which are external forces acting on the screw joint. When external joint separating forces are greater than the clamping force, the screw becomes loose. These external forces may be para-function, excessive crown height, masticatory dynamics, prosthesis position in the dental arch, and opposing dentition. Conditions that magnify or increase external forces include cantilevers, angled loads, and poor cuspal designs.<sup>[55]</sup> Increase in the forces is in direct relationship to the length of the cantilever, thereby increasing the risk of screw loosening.<sup>[56]</sup>

In the present study, initial torque as recommended by the manufacturer could not generate required maximum preload to resist the separating external forces by the aberrant tongue position, cantilever design, and oblique occlusal guiding forces in the mandibular anterior prosthesis.

*In vitro* studies retaining implant-supported dentures by Spazzin *et al.*<sup>[57]</sup> and Farina *et al.*<sup>[58]</sup> stated the necessity of maximum preload by retorquing of supporting abutment screws. Krishnan *et al.*<sup>[23]</sup> also suggested retorquing after 10 min to counter the embedment relaxation between the mating threads to prevent loss of preload.

In the present study, observation of early screw loosening on recall visits suggestive of insufficient preload/loss of preload and application of maximum preload by retorquing was found to be essential for screw-retained mandibular anterior cantilever prosthesis. Hence, retorquing of supporting abutment screws after 10 min of initial torque was advocated to maintain the preload; the data after further follow-up were analyzed.

Dincer Kose *et al.* also stated that early screw loosening/fracture was found due to insufficient preload.<sup>[59]</sup> Nithyapriya *et al.* in their systematic analysis of factors that cause loss of preload in dental implants concluded that retorquing of the abutment screw after 10 min was found to produce the maximum preload of the initial torque.<sup>[25]</sup>

Jivraj stated that oral forces, fit and strength of the components make the screw joints prone to technical complications.<sup>[60]</sup> The higher percentage of the population shows the positioning of the dorsum of the tongue to the palate with tip forward and slightly below the incisal edges

of the mandibular central incisors according to Wright.<sup>[61]</sup> There is a possibility of aberrant tongue position due to loss of teeth results in continuous lateral force, on to the implants and prosthesis restored in these sites.<sup>[46]</sup> Lower anterior restoration might have caused constant lateral forces leading to early screw loosening/prosthetic failure. In addition, cantilever prosthesis design might have aggravated lateral forces and resulted in loss of preload after initial torque as early as 06 months in few cases. Hence, on statistical analysis using the Weibull test, the survival probability was low, i.e., about 3.9% at the end of 1 year.

During the follow-up visits, in cases of screw loosening, screw was replaced with a new abutment screw of the same manufacturer; maximum preload was given by retightening and retorquing after 10 min with adequate torque. The ISCP with showed no further screw loosening except in two cases at 2.5 years increasing the survival probability to 95.2% at the end of 3 years. The increased survival might be due to the application of maximum preload and early learning curve leading to conformation of the tongue to the new prosthesis within few weeks, which has resulted in reduction of lateral forces.<sup>[62]</sup> The screw loosening found in two cases might be due to either defective casting or continued lateral forces on the cantilever prosthesis.

#### Porcelain veneer fracture

All the participants included in the study possessed canine guided or group function occlusal scheme. The definitive restorations, i.e., screw-retained ISCP replacing both the mandibular central incisor were made with no incisal contact in the centric position. Wide freedom of centric was provided with shallow anterior angle and anterior guidance with evenly distributed contacts.<sup>[30,31]</sup> However, the second most common prosthetic complication observed in the present study was porcelain veneer fracture (14.3%), which is quite high and was noted very early at 06 months recall.

The screw-retained ISCP replacing both mandibular central incisors served as anterior guidance during mandibular movements, thus producing nonaxial forces on to the veneering ceramics. These nonaxial or oblique forces cause fatigue fractures in the ceramics. Rangert *et al.* stated that these nonaxial or oblique forces generated have to be avoided on the ISP which may lead to bone loss.<sup>[63]</sup>

In a study on the impact of occlusal guidance by Linkevicius *et al.* revealed that 66 prostheses had contact in protrusive and/or lateral mandibular movements, up to 17.4% of all restorations; while 13 restorations had ceramic fractures, which are 19.7% of all guiding prostheses. These findings are closer to the present study, which showed 14.3% of ceramic



fractures of all the anterior guiding prosthesis indicating that nonaxial loads resulted in co-adhesive failures.<sup>[64]</sup>

Fractures of ceramic veneers are classified to adhesive failures, where metal framework is denuded of ceramic or co-adhesive failures, where fracture occurs within the ceramic material itself.<sup>[33]</sup> Adhesive failures indicate un-oxidized metal surface which fails to bond with ceramic. Moreover, when thickness of veneering ceramic exceeds 2 mm fractures results within the ceramic.<sup>[65]</sup> It is suggestive that, during ceramic veneering, prescribed laboratory protocol (metal surface treatment for ceramic bonding and the thickness of veneering ceramic less than 2 mm) should be followed meticulously to minimize adhesive and co-adhesive failures, especially at the occlusal or incisal guiding surfaces.

Early co-adhesive fracture was reported in 03 participants at 06 months recall resulting in 14.3% ceramic fracture at the end of 1 year. However, after repair further ceramic complication was prevented resulting in no rise in cumulative ceramic fracture values, which remained constant, 14.3% at the end of 3 years.

The present prospective cohort study resulted in a survival probability of 95.2% at the end of 3 years thus rejecting the null hypothesis. In addition, the present treatment modality needs greater chair-side time, meticulous laboratory work, and regular follow-up visits for maintenance.

## CONCLUSIONS

1. Anterior guiding screw-retained implant-supported cantilever prosthesis (ISCP) developed early technical complications, namely screw loosening and porcelain fracture in the mandibular anterior regions
2. After prosthetic loading, the survival probability of the screw-retained ISCP was very low (3.9%) at the end of 1 year, which increased to 95.2% after retightening and retorquing of the abutment screw, porcelain repair and conformation of the tongue to the prosthesis at the end of 3 years
3. Most common prosthetic failure was screw loosening (81%), followed by porcelain fracture (14.3%) and implant survival of 95% at the end of 3 years
4. The present treatment modality, screw-retained ISCP needs greater chair-side time, meticulous laboratory work and regular follow-up visits for maintenance.

## Limitations of the study

A further study with increased sample size and different implant-abutment connections using similar prosthetic design is required.

## Clinical significance

Maximum preload application through retightening and retorquing after 10 min of initial torque is mandatory to limit technical complications with regard to screw-retained implant supported cantilever prosthesis, when anterior guidance cannot be totally avoided.

## Financial support and sponsorship

Nil.

## Conflicts of interest

There are no conflicts of interest.

## REFERENCES

1. Behr M, Driemel O, Mertins V, Gerlach T, Kolbeck C, Rohr N, *et al.* Concepts for the treatment of adolescent patients with missing permanent teeth. *Oral Maxillofac Surg* 2008;12:49-60.
2. Berendt HC. Report of 7 cases of anodontia partialis. *Oral Surg Oral Med Oral Pathol* 1950;3:1435-46.
3. Cronin RJ Jr, Oesterle LJ, Ranly DM. Mandibular implants and the growing patient. *Int J Oral Maxillofac Implants* 1994;9:55-62.
4. Guckes AD, Scurria MS, King TS, McCarthy GR, Brahim JS. Prospective clinical trial of dental implants in persons with ectodermal dysplasia. *J Prosthet Dent* 2002;88:21-5.
5. Emerich K, Czerwinska M, Ordyniec-Kwasnica I. Immediate self-replantation of an avulsed permanent mandibular incisor-a case report. *Dent Traumatol* 2010;26:443-6.
6. Elian N, Ehrlich B, Jalbout ZN, Classi AJ, Cho SC, Kamer AR, *et al.* Advanced concepts in implant dentistry: Creating the "aesthetic site foundation". *Dent Clin North Am* 2007;51:547-63, xi-xii.
7. Leblebicioglu B, Rawal S, Mariotti A. A review of the functional and esthetic requirements for dental implants. *J Am Dent Assoc* 2007;138:321-9.
8. Jones JD, Turkyilmaz I, Garcia LT. Removable partial dentures – treatment now and for the future. *Tex Dent J* 2010;127:365-72.
9. Vallittu PK. Survival rates of resin-bonded, glass fiber-reinforced composite fixed partial dentures with a mean follow-up of 42 months: A pilot study. *J Prosthet Dent* 2004;91:241-6.
10. Wassermann A, Kaiser M, Strub JR. Clinical long-term results of VITA In-Ceram Classic crowns and fixed partial dentures: A systematic literature review. *Int J Prosthodont* 2006;19:355-63.
11. Ledermann PD, Hassell TM, Hefti AF. Osseointegrated dental implants as alternative therapy to bridge construction or orthodontics in young patients: Seven years of clinical experience. *Pediatr Dent* 1993;15:327-33.
12. Pjetursson BE, Brägger U, Lang NP, Zwahlen M. Comparison of survival and complication rates of tooth-supported fixed dental prostheses (FDPs) and implant-supported FDPs and single crowns (SCs). *Clin Oral Implants Res* 2007;18 Suppl 3:97-113.
13. Greenstein G, Cavallaro J Jr. Cantilevers extending from unilateral implant-supported fixed prostheses: A review of the literature and presentation of practical guidelines. *J Am Dent Assoc* 2010;141:1221-30.
14. Romeo E, Tomasi C, Finini I, Casentini P, Lops D. Implant-supported fixed cantilever prosthesis in partially edentulous jaws: A cohort prospective study. *Clin Oral Implants Res* 2009;20:1278-85.
15. Brosky ME, Koriath TW, Hodges J. The anterior cantilever in the implant-supported screw-retained mandibular prosthesis. *J Prosthet Dent* 2003;89:244-9.
16. Wu MJ, Wang XJ, Zou LD, Xu WH, Zhang XH. Evaluation of the therapeutic efficiency of mandibular anterior implant-supported fixed bridges with cantilevers. *Chin Med J (Engl)* 2013;126:4665-9.
17. Barreto M, Francischone CE, Filho HN. Two prosthetic crowns

- supported by a single implant: An esthetic alternative for restoring the anterior maxilla. *Quintessence Int* 2008;39:717-25.
18. Bhandari S. Designing both mandibular central incisors on one 3.0-mm single-piece implant: Five years' outcome. *J Oral Implantol* 2018;44:439-45.
  19. Goodacre CJ, Bernal G, Rungcharassaeng K, Kan JY. Clinical complications with implants and implant prostheses. *J Prosthet Dent* 2003;90:121-32.
  20. Shadid RM, Sadaqah NR, Abu-Naba'a L, Al-Omari WM. Porcelain fracture of metal-ceramic tooth-supported and implant-supported restorations: A review. *Open J Stomatol* 2013;3:411-8.
  21. Katsavochristou A, Koumoulis D. Incidence of abutment screw failure of single or splinted implant prostheses: A review and update on current clinical status. *J Oral Rehabil* 2019;46:776-86.
  22. Jain JK, Sethuraman R, Chauhan S, Javiya P, Srivastava S, Patel R, *et al.* Retention failures in cement- and screw-retained fixed restorations on dental implants in partially edentulous arches: A systematic review with meta-analysis. *J Indian Prosthodont Soc* 2018;18:201-11.
  23. Krishnan V, Tony Thomas C, Sabu I. Management of abutment screw loosening: Review of literature and report of a case. *J Indian Prosthodont Soc* 2014;14:208-14.
  24. Kourtis S, Damanaki M, Kaitatzidou S, Kaitatzidou A, Roussou V. Loosening of the fixing screw in single implant crowns: Predisposing factors, prevention and treatment options. *J Esthet Restor Dent* 2017;29:233-46.
  25. Nithyapriya S, Ramesh AS, Kirubakaran A, Mani J, Raghunathan J. Systematic analysis of factors that cause loss of preload in dental implants. *J Indian Prosthodont Soc* 2018;18:189-95.
  26. Zurdo J, Romão C, Wennström JL. Survival and complication rates of implant-supported fixed partial dentures with cantilevers: A systematic review. *Clin Oral Implants Res* 2009;20 Suppl 4:59-66.
  27. Aglietta M, Siciliano VI, Zwahlen M, Brägger U, Pjetursson BE, Lang NP, *et al.* A systematic review of the survival and complication rates of implant supported fixed dental prostheses with cantilever extensions after an observation period of at least 5 years. *Clin Oral Implants Res* 2009;20:441-51.
  28. Aglietta M, Iorio Siciliano V, Blasi A, Sculean A, Brägger U, Lang NP, *et al.* Clinical and radiographic changes at implants supporting single-unit crowns (SCs) and fixed dental prostheses (FDPs) with one cantilever extension. A retrospective study. *Clin Oral Implants Res* 2012;23:550-5.
  29. Laurell L, Lundgren D, Falk H, Hugoson A. Long-term prognosis of extensive polyunit cantilevered fixed partial dentures. *J Prosthet Dent* 1991;66:545-52.
  30. Jancoski VH, Faot F, de Mattias Sartori IA, Vieira RA, Tioffi R. Occlusal concepts application in resolving implant prosthetic failure: Case report. *J Oral Implantol* 2014;40:203-10.
  31. Sheridan RA, Decker AM, Plonka AB, Wang HL. The role of occlusion in implant therapy: A comprehensive updated review. *Implant Dent* 2016;25:829-38.
  32. Resnik RR, Misch CE. Pharmacology in implant dentistry. In: Misch CE, Abbas HA, editors. *Contemporary Implant Dentistry*. 3<sup>rd</sup> ed. St. Louis: Mosby; 2008. p. 472-4.
  33. dos Santos JG, Fonseca RG, Adabo GL, dos Santos Cruz CA. Shear bond strength of metal-ceramic repair systems. *J Prosthet Dent* 2006;96:165-73.
  34. Tarnow D, Elian N, Fletcher P, Froum S, Magner A, Cho SC, *et al.* Vertical distance from the crest of bone to the height of the interproximal papilla between adjacent implants. *J Periodontol* 2003;74:1785-8.
  35. Hermann JS, Buser D, Schenk RK, Higginbottom FL, Cochran DL. Biologic width around titanium implants. A physiologically formed and stable dimension over time. *Clin Oral Implants Res* 2000;11:1-11.
  36. Scheid RC, Weiss G. *Woelfel's Dental Anatomy*. 8<sup>th</sup> ed. Philadelphia: Lippincott Williams & Wilkins; 2012. p. 16.
  37. Tarnow DP, Cho SC, Wallace SS. The effect of inter-implant distance on the height of inter-implant bone crest. *J Periodontol* 2000;71:546-9.
  38. Misch CE. *Contemporary Implant Dentistry*. 2<sup>nd</sup> ed. Missouri: Mosby; 1999. p. 423.
  39. Grütter L, Belser UC. Implant loading protocols for the partially edentulous esthetic zone. *Int J Oral Maxillofac Implants* 2009;24 Suppl: 169-79.
  40. Ioannidou E, Doufexi A. Does loading time affect implant survival? A meta-analysis of 1,266 implants. *J Periodontol* 2005;76:1252-8.
  41. Adell R, Lekholm U, Rockler B, Brånemark PI. A 15-year study of osseointegrated implants in the treatment of the edentulous jaw. *Int J Oral Surg* 1981;10:387-416.
  42. Gibbs CH, Mahan PE, Mauderli A, Lundeen HC, Walsh EK. Limits of human bite strength. *J Prosthet Dent* 1986;56:226-9.
  43. Misch CE. *Contemporary Implant Dentistry*. 2<sup>nd</sup> ed. Missouri: Mosby; 1999. p. 372.
  44. Roberts EW, Turley PK, Brezniak N, Fielder PJ. Implants: Bone physiology and metabolism. *J Calif Dent Assoc* 1987;15:54-61.
  45. Roberts EW. Fundamental principles of bone physiology, metabolism and loading. In: Naert I, van Steenberghe D, Worthington P, editors. *Osseointegration Oral Rehabilitation*. Carol Stream: Quintessence; 1993. p. 157-70.
  46. Misch CE. Treatment planning: Force factors related to patient conditions. In Misch CE, Abbas HA, editors. *Contemporary Implant Dentistry*. 3<sup>rd</sup> ed. St. Louis: Mosby; 2008. p. 116-7.
  47. Kim Y, Oh TJ, Misch CE, Wang HL. Occlusal considerations in implant therapy: Clinical guidelines with biomechanical rationale. *Clin Oral Implants Res* 2005;16:26-35.
  48. Adell R, Lekholm U, Rockler B, Brånemark PI, Lindhe J, Eriksson B, *et al.* Marginal tissue reactions at osseointegrated titanium fixtures (i). A 3-year longitudinal prospective study. *Int J Oral Maxillofac Surg* 1986;15:39-52.
  49. Zarb GA, Schmitt A. The longitudinal clinical effectiveness of osseointegrated dental implants: The Toronto Study. Part II: The prosthetic results. *J Prosthet Dent* 1990;64:53-61.
  50. Naert I, Quirynen M, van Steenberghe D, Darius P. A study of 589 consecutive implants supporting complete fixed prostheses. Part II: Prosthetic aspects. *J Prosthet Dent* 1992;68:949-56.
  51. Kreissl ME, Gerds T, Muehe R, Heydecke G, Strub JR. Technical complications of implant-supported fixed partial dentures in partially edentulous cases after an average observation period of 5 years. *Clin Oral Implants Res* 2007;18:720-6.
  52. Pjetursson BE, Tan K, Lang NP, Brägger U, Egger M, Zwahlen M. A systematic review of the survival and complication rates of fixed partial dentures (FPDs) after an observation period of at least 5 years. *Clin Oral Implants Res* 2004;15:625-42.
  53. Binon PP. The effect of implant/abutment hexagonal misfit on screw joint stability. *Int J Prosthodont* 1996;9:149-60.
  54. Sameera Y, Rai R. Tightening torque of implant abutment using hand drivers against torque wrench and its effect on the internal surface of implant. *J Indian Prosthodont Soc* 2020;20:180-5.
  55. Misch CE, Resnik RR. Stress treatment theorem for implant dentistry. In: Resnik RR, editor. *Misch's Contemporary Implant Dentistry*. 3<sup>rd</sup> ed. St. Louis: Mosby; 2021. p. 153-77.
  56. Kallus T, Bessing C. Loose gold screws frequently occur in full arch fixed prosthesis supported by osseointegrated implants after 5 years. *Int J Oralmaxillofac Implants* 1991;9:169-78.
  57. Spazzin AO, Henrique GE, Nóbilo MA, Consani RL, Correr-Sobrinho L, Mesquita MF. Effect of retorque on loosening torque of prosthetic screws under two levels of fit of implant-supported dentures. *Braz Dent J* 2010;21:12-7.
  58. Farina AP, Spazzin AO, Consani RL, Mesquita MF. Screw joint stability after the application of retorque in implant-supported dentures under simulated masticatory conditions. *J Prosthet Dent* 2014;111:499-504.
  59. Dincer Kose O, Karataslı B, Demircan S, Kose TE, Cene E,

- Aya SA, *et al.* *In vitro* evaluation of manual torque values applied to implant-abutment complex by different clinicians and abutment screw loosening. *Biomed Res Int* 2017;2017:1-9.
60. Jivraj S. Screw versus cemented implant restorations: The decision-making process. *J Dent Implant* 2018;8:9-19.
61. Wright CR. Evaluation of the factors necessary to develop stability in mandibular dentures. *J Prosthet Dent* 1966;16:414-30.
62. "Stability in Mandibular Denture-StatPearls-NCBI Bookshelf." Available from: <https://www.ncbi.nlm.nih.gov/books/NBK549861/>. [Last accessed on 2020 Dec 15].
63. Rangert B, Jemt T, Jörneus L. Forces and moments on Branemark implants. *Int J Oral Maxillofac Implants* 1989;4:241-7.
64. Linkevicius T, Vladimirovas E, Grybauskas S, Puisys A, Rutkunas V. Veneer fracture in implant-supported metal-ceramic restorations. Part I: Overall success rate and impact of occlusal guidance. *Stomatologija* 2008;10:133-9.
65. Rosenstiel SF, Land MF, Fujimoto J. *Contemporary Fixed Prosthodontics*. 2<sup>nd</sup> ed. St. Louis: Mosby; 1995.

### Author Help: Online submission of the manuscripts

Articles can be submitted online from <http://www.journalonweb.com>. For online submission, the articles should be prepared in two files (first page file and article file). Images should be submitted separately.

1) **First Page File:**

Prepare the title page, covering letter, acknowledgement etc. using a word processor program. All information related to your identity should be included here. Use text/rtf/doc/pdf files. Do not zip the files.

2) **Article File:**

The main text of the article, beginning with the Abstract to References (including tables) should be in this file. Do not include any information (such as acknowledgement, your names in page headers etc.) in this file. Use text/rtf/doc/pdf files. Do not zip the files. Limit the file size to 1 MB. Do not incorporate images in the file. If file size is large, graphs can be submitted separately as images, without their being incorporated in the article file. This will reduce the size of the file.

3) **Images:**

Submit good quality color images. Each image should be less than 4096 kb (4 MB) in size. The size of the image can be reduced by decreasing the actual height and width of the images (keep up to about 6 inches and up to about 1800 x 1200 pixels). JPEG is the most suitable file format. The image quality should be good enough to judge the scientific value of the image. For the purpose of printing, always retain a good quality, high resolution image. This high resolution image should be sent to the editorial office at the time of sending a revised article.

4) **Legends:**

Legends for the figures/images should be included at the end of the article file.