

Effect of intravitreal aflibercept injection for age-related macular degeneration with a retinal pigment epithelial tear refractory to intravitreal ranibizumab injection

Ayaka Fujii¹
Hisanori Imai^{1,2}
Michiko Kanai¹
Atsushi Azumi^{1,2}

¹Department of Ophthalmology, Kobe Kaisei Hospital, ²Department of Organ Therapeutics, Division of Ophthalmology, Kobe University Graduate School of Medicine, Kobe, Japan

Background: The purpose of this study was to evaluate the effects of intravitreal aflibercept injection for age-related macular degeneration (AMD) with a retinal pigment epithelial (RPE) tear after intravitreal ranibizumab injection (IVR) which finally became resistant to additional IVR.

Methods: We reviewed the medical records of AMD patients with RPE tears after intravitreal ranibizumab injection who were treated with intravitreal aflibercept injection after acquisition of resistance to additional IVR.

Results: One eye from three patients, aged 66, 77, and 78 years, was evaluated. All cases started treatment with IVR for AMD. RPE tear developed 1, 4, and 3 months after the first IVR, respectively. Additional IVR was performed seven, seven, and nine times over 10, 19, and 21 months, respectively, but all cases finally became resistant to IVR. Intravitreal aflibercept injection was performed four times, six times, and once over 8, 9, and 6 months, respectively. At the last visit, all patients had complete resolution of subretinal and intraretinal fluid.

Conclusion: Continued intravitreal aflibercept injection may be beneficial to manage AMD with RPE tear which has become resistant to additional IVR.

Keywords: aflibercept, ranibizumab, retinal pigment epithelial tear, age-related macular degeneration

Introduction

Retinal pigment epithelial (RPE) tears are known to develop in eyes affected by exudative age-related macular degeneration (AMD) and commonly occur in patients with retinal pigment epithelial detachment. RPE tears occur spontaneously in 10% of patients with AMD,¹ and also occur in association with various treatments for exudative AMD, such as photodynamic therapy^{2,3} and anti-vascular endothelial growth factor (VEGF) therapy.⁴ Sometimes, additional treatments are required for the persistent exudative change after development of RPE tear. However, there is no clinically proven guideline for how to manage this condition. Here, we report three cases of AMD with RPE tears, which developed after intravitreal ranibizumab injection (IVR, 0.5 mg/0.05 mL) and finally became resistant to additional IVR, that were treated with intravitreal aflibercept injection (IVA, 2.0 mg/0.05 mL). For this study, we reviewed the medical records of AMD patients with RPE tears after IVR that were treated with IVA after acquisition of resistance to additional IVR.

Correspondence: Hisanori Imai
Department of Ophthalmology,
Kobe Kaisei Hospital, 3-11-15
Shinoharakitamachi, Nada-ku,
Kobe 657-0068, Japan
Tel +817 8871 5201
Fax +817 8871 5206
Email imai@kobe-kaisei.or

Case reports

Patient 1

A 66-year-old woman presented with a large fibrovascular pigment epithelial detachment in her left eye. At the initial visit, her best-corrected Landolt ring chart visual acuity (BCVA) was 0.7 in the left eye. Fluorescein angiography showed an occult choroidal neovascularization. Indocyanine green angiography showed no polypoidal lesion. IVR was performed to treat the choroidal neovascularization, but a

RPE tear developed one month after the first injection. Three monthly additional IVR improved the exudative change for 3 months but recurrence developed. Four additional IVR were performed over 7 months, but did not improve the recurrent exudative change any further. We switched the anti-VEGF agent from ranibizumab to aflibercept. A total of four IVA injections over 8 months resulted in complete resolution of the persistent exudative change. BCVA improved to 0.9 at the last visit (Figure 1).

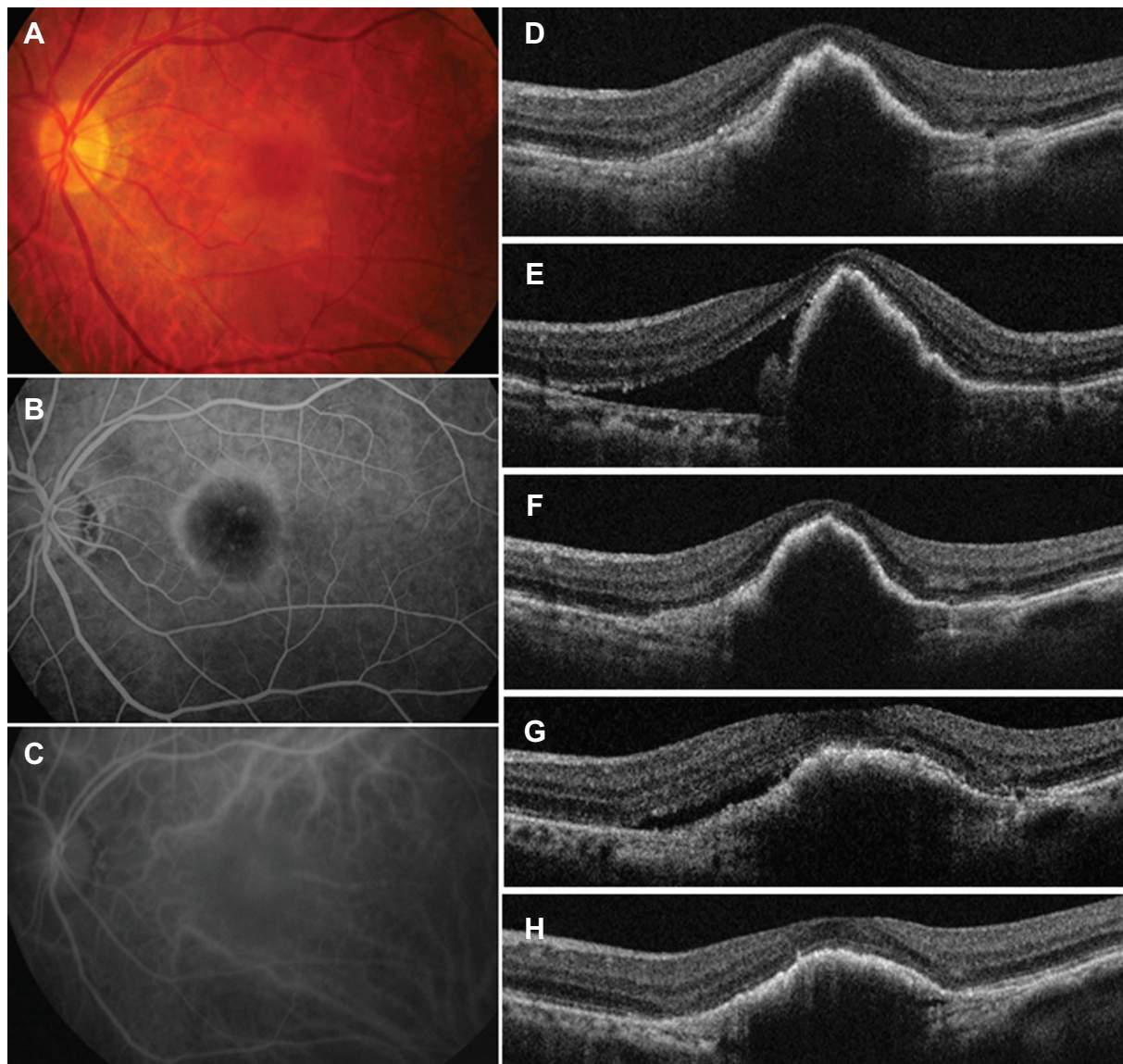


Figure 1 Findings from case 1, a 66-year-old woman with a large pigment epithelial detachment in the left eye.

Notes: (A) Fundus photograph of the left eye at initial examination showing a large pigment epithelial detachment. (B) Fluorescein angiography images of the left eye at the initial visit showing late leakage suggesting occult with no classic choroidal neovascularization. (C) Indocyanine green angiography images at the initial visit showing no polypoidal lesion. (D) OCT image of the left eye at the first examination showing a large pigment epithelial detachment. (E) OCT image one month after one injection of ranibizumab. A retinal pigment epithelial tear was detected and the SRF worsened. (F) OCT image one month after 3 monthly IVR showing complete resolution of SRF. However, 2 months later, recurrent SRF was observed. (G) One month after the last IVR (total of seven injections), SRF was persistent. (H) SRF was completely resolved after one injection of aflibercept and maintained well by three additional IVA injections over 8 months.

Abbreviations: OCT, optical coherence tomography; SRF, subretinal fluid; IVR, intravitreal ranibizumab injection; IVA, intravitreal aflibercept injection.

Patient 2

A 77-year-old man presented with a large pigment epithelial detachment and subretinal fluid associated with polypoidal choroidal vasculopathy in his right eye. BCVA was 1.2. He had received three monthly IVR injections, but a RPE tear were observed 4 months after the first injection. An additional IVR resolved the subretinal fluid once, but six additional IVR injections over 18 months could not improve the recurrent exudative change. BCVA was decreased to 0.3. We switched to IVA, and the exudative change completely disappeared after six IVA injections over 9 months. BCVA remained at 0.3 at the last visit.

Patient 3

A 78-year-old man presented with subretinal fluid associated with AMD in the right eye. BCVA was 1.2. Fluorescein angiography displayed occult with no classic choroidal neovascularization, and indocyanine green angiography showed no polypoidal lesion. After three monthly IVR injections, an RPE tear developed. Nine monthly additional IVR injections over 21 months failed to improve the persistent exudative change and BCVA was reduced to 0.2. We switched the anti-VEGF agent from ranibizumab to aflibercept. The persistent exudative change resolved completely after one injection and there was no recurrence over 6 months. BCVA was 0.2 at the last visit.

Discussion

Several papers have already reported the effect of additional anti-VEGF therapy for persistent exudative change in AMD after development of an RPE tear.⁵⁻⁸ A previous report suggested that visual acuity continued to improve in 67% of eyes treated with additional intravitreal injection of ranibizumab or bevacizumab.⁵ Another report showed that the mean visual acuity at 24 months was better in patients receiving ranibizumab than in those who received sham injection plus photodynamic therapy or sham injection alone.⁶ We also observed improvement of the persistent exudative change for 3 months after three additional IVR in patient 1, and for 2 months after an additional IVR in patient 2 after additional IVR. These results suggest that continued anti-VEGF therapy could be the guideline for management of persistent exudative change in AMD after development of RPE tear.

On the other hand, we had a case of AMD with RPE tear that had no response to additional IVR (case 3) and two cases that developed resistance to additional IVR (cases 1 and 2). Asao et al reported that subretinal fluid was persistent in three of ten patients with RPE tear at 12 months in spite of additional anti-VEGF therapy.⁸ The low responsiveness to

drug therapy, development of tachyphylaxis, and formation of neutralizing antibodies to ranibizumab may be related to the reduced efficacy in such recalcitrant cases of AMD.^{9,10} In our study, all cases were treated successfully by conversion of the anti-VEGF agent from ranibizumab to aflibercept. Several papers have already reported on the effectiveness of aflibercept for AMD resistant to ranibizumab.^{11,12} These results suggest that the binding properties of aflibercept, the increased binding affinity to VEGF-A,^{13,14} and the ability of aflibercept to bind to VEGF-B and placental growth factor¹³⁻¹⁶ could account for the positive effects of IVA, even for AMD with RPE tears resistant to previous IVR.

Recently, Patel et al reported the usefulness of IVA in the treatment of large pigment epithelial detachments associated with occult choroidal neovascularization.¹⁷ Our results suggest an advantage of aflibercept for the treatment of choroidal neovascularization existing beneath the RPE, even after the development of RPE tear.

In summary, we examined the effect of IVA for AMD with RPE tear that finally became refractory to IVR. Switching of the anti-VEGF agent may be one of the useful treatment options for AMD with RPE tear resistant to prior anti-VEGF therapies.

Disclosure

The authors report no conflicts of interest in this work.

References

1. Pece A, Vitale L, Milani P, Pierro L. Spontaneous reattachment of the margins of a macular retinal pigment epithelium tear: Optical coherence tomography documentation of a case. *Ophthalmologica*. 2010;224(3):159-161.
2. Intorini U, Torres Gimeno A, Scotti F, Setaccioli M, Giatsidis S, Bandello F. Vascularized retinal pigment epithelial detachment in age-related macular degeneration: treatment and RPE tear incidence. *Graefes Arch Clin Exp Ophthalmol*. 2012;250(9):1283-1292.
3. Shima C, Gomi F, Sawa M, Sakaguchi H, Tsujikawa M, Tano Y. One-year results of combined photodynamic therapy and intravitreal bevacizumab injection for retinal pigment epithelial detachment secondary to age-related macular degeneration. *Graefes Arch Clin Exp Ophthalmol*. 2009;247(7):899-906.
4. McLaughlin S, Lockington D, Mansfield D. The importance of informed consent in patients with wet age-related macular degeneration considering intravitreal anti-vascular endothelial growth factor treatments. *Scott Med J*. 2012;57(1):48-49.
5. Chan CK, Meyer CH, Gross JG, et al. Retinal pigment epithelial tears after intravitreal bevacizumab injection for neovascular age-related macular degeneration. *Retina*. 2007;27(5):541-551.
6. Cunningham ET Jr, Feiner L, Chung C, Tuomi L, Ehrlich JS. Incidence of retinal pigment epithelial tears after intravitreal ranibizumab injection for neovascular age-related macular degeneration. *Ophthalmology*. 2011;118(12):2447-2452.
7. Gamulescu MA, Framme C, Sachs H. RPE-rip after intravitreal bevacizumab (Avastin) treatment for vascularised pigment epithelial detachment secondary to AMD. *Graefes Arch Clin Exp Ophthalmol*. 2007;245(7):1037-1040.

8. Asao K, Gomi F, Sawa M, Nishida K. Additional anti-vascular endothelial growth factor therapy for eyes with a retinal pigment epithelial tear after the initial therapy. *Retina*. 2014;34(3):512–518.
9. Forooghian F, Cukras C, Meyerle CB, Chew EY, Wong WT. Tachyphylaxis after intravitreal bevacizumab for exudative age-related macular degeneration. *Retina*. 2009;29(6):723–731.
10. Schaal S, Kaplan HJ, Tezel TH. Is there tachyphylaxis to intravitreal anti-vascular endothelial growth factor pharmacotherapy in age-related macular degeneration? *Ophthalmology*. 2008;115(12):2199–2205.
11. Kumar N, Marsiglia M, Mrejen S, Fung AT. Visual and anatomical outcomes of intravitreal aflibercept in eyes with persistent subfoveal fluid despite previous treatments with ranibizumab in patients with neovascular age-related macular degeneration. *Retina*. 2013;33(8):1605–1612.
12. Ho VY, Yeh S, Olsen TW, et al. Short-term outcomes of aflibercept for neovascular age-related macular degeneration in eyes previously treated with other vascular endothelial growth factor inhibitors. *Am J Ophthalmol*. 2013;156(1):23–28.
13. Browning DJ, Kaiser PK, Rosenfeld PJ, Stewart MW. Aflibercept for age-related macular degeneration: a game-changer or quiet addition? *Am J Ophthalmol*. 2012;154(2):222–226.
14. Papadopoulos N, Martin J, Ruan Q, et al. Binding and neutralization of vascular endothelial growth factor (VEGF) and related ligands by VEGF Trap, ranibizumab and bevacizumab. *Angiogenesis*. 2012;15(2):171–185.
15. Holash J, Davis S, Papadopoulos N, et al. VEGF-Trap: a VEGF blocker with potent antitumor effects. *Proc Natl Acad Sci U S A*. 2002;99(17):11393–11398.
16. Stewart MW, Rosenfeld PJ. Predicted biological activity of intravitreal VEGF Trap. *Br J Ophthalmol*. 2008;92(5):667–668.
17. Patel KH, Chow CC, Rathod R, et al. Rapid response of retinal pigment epithelial detachments to intravitreal aflibercept in neovascular age-related macular degeneration refractory to bevacizumab and ranibizumab. *Eye (Lond)*. 2013;27(5):663–667.

Clinical Ophthalmology

Publish your work in this journal

Clinical Ophthalmology is an international, peer-reviewed journal covering all subspecialties within ophthalmology. Key topics include: Optometry; Visual science; Pharmacology and drug therapy in eye diseases; Basic Sciences; Primary and Secondary eye care; Patient Safety and Quality of Care Improvements. This journal is indexed on

Submit your manuscript here: <http://www.dovepress.com/clinical-ophthalmology-journal>

Dovepress

PubMed Central and CAS, and is the official journal of The Society of Clinical Ophthalmology (SCO). The manuscript management system is completely online and includes a very quick and fair peer-review system, which is all easy to use. Visit <http://www.dovepress.com/testimonials.php> to read real quotes from published authors.