

# Step-wise Technical Description of Performing Ureteric Tunnel Dissection in Laparoscopic Radical Hysterectomy

Dipak Limbachiya\*, Rashmi Kumari

Department of Gynecology, Eva Women's Hospital and Endoscopy Centre, Ahmedabad, Gujarat, India

## Abstract

**Objectives:** Technical description of performing ureteric tunnel dissection in laparoscopic radical hysterectomy (LRH) surgery.

**Materials and Methods:** This is a retrospective analysis. A total of 91 patients of the International Federation of Gynaecology and Obstetrics Stage IA2, IB1, and IB2 of cervical cancer were operated by the same surgeon between January 2015 and December 2019 were analyzed.

**Results:** The median time for one side ureteric tunnel dissection was 3 min 15 s (range 2 min 35 s– 6 min 18 s). None of the cases were converted to laparotomy. The patients' median hospital stay was 2 days (range 1–4 days). There were no short-term or long-term complications related to ureteric tunnel dissection.

**Conclusion:** This analysis explains the descriptive methodology of operative technique, especially for ureteric tunnel dissection in LRH. This technique is easily reproducible and replicable, with chances of marginal or negligible complication rates.

**Keywords:** Laparoscopic radical hysterectomy, operative technique, ureteric tunnel dissection

## INTRODUCTION

Laparoscopic radical hysterectomy (LRH) has emerged as a possible substitute in gynecological oncology that offers the advantages of minimally invasive surgery without compromising the surgical and oncologic outcomes.<sup>[1]</sup> The combined surgical technique of LRH and pelvic lymphadenectomy for the treatment of patients with cervical cancer was described in the early 1990s by Canis *et al.*<sup>[2]</sup> and Nezhat *et al.*<sup>[3]</sup> The perspective of laparoscopy in radical hysterectomy has evolved to a great extent in its technicality and approach for comprehensiveness in the treatment of malignancies. It is now being considered the standard of approach in the hands of experts,<sup>[4,5]</sup> having survival outcomes and complications rate similar to open approach and many studies supporting its feasibility.<sup>[6]</sup>

Recently, LACC study<sup>[7]</sup> concluded that minimally invasive radical hysterectomy was associated with lower rates of disease-free survival and overall survival than open abdominal radical hysterectomy among women with early-stage cervical cancer. Few probable reasons for the inferior outcomes of the laparoscopy arm in the LACC trial might be lack of adequate experience in laparoscopy among operative surgeons and a multicentric approach with the absence of uniformity in surgical procedures. In our study, the same surgeon who is sufficiently qualified with adequate surgical skills performed all the surgeries, so consistency in the surgical procedures was maintained. The degree of radicality in radical hysterectomy influences the outcome of the procedure. Thus, we have tried to homogenize one of the most important steps of radical hysterectomy (ureteric tunnel dissection).

### Article History:

**Submitted:** 25 June 2020

**Revised:** 19 October 2020

**Accepted:** 27 January 2021

**Published:** 5 November 2021

**Address for correspondence:** Dr. Dipak Limbachiya,

Eva Women's Hospital and Endoscopy Centre, Block-C, Neelkanth Park-2, Ghoda Camp Road, Shahibaug, Ahmedabad, Gujarat, India.

E-mail: limbachiyaipak63@gmail.com

### Access this article online

Quick Response Code:



**Website:**  
www.e-gmit.com

**DOI:**  
10.4103/GMIT.GMIT\_85\_20

This is an open access journal, and articles are distributed under the terms of the Creative Commons Attribution-NonCommercial-ShareAlike 4.0 License, which allows others to remix, tweak, and build upon the work non-commercially, as long as appropriate credit is given and the new creations are licensed under the identical terms.

**For reprints contact:** WKHLRPMedknow\_reprints@wolterskluwer.com

**How to cite this article:** Limbachiya D, Kumari R. Step-wise technical description of performing ureteric tunnel dissection in laparoscopic radical hysterectomy. *Gynecol Minim Invasive Ther* 2021;10:215-20.

One of the most pivotal and arduous steps in completing radical hysterectomy is ureteric tunnel dissection and separating the ureter from the vesicouterine ligament. This step decides the entireness of the specimen and further determines the prognosis of the patients. We have evaluated our own experience of 91 patients with cervical cancer, stages IA2-IB2, who underwent LRH at our center in the last 5 years. Considering it, we have tried to frame a feasible and easily replicable operative technique with the minuscule description of every step for completeness of surgery.

## MATERIALS, METHODS AND SURGICAL TECHNIQUE

This is a kind of retrospective analysis. Video records of all our laparoscopic radical hysterectomies performed for early cervical cancer of International Federation of Gynaecology and Obstetrics Stage IA2, IB1, and IB2 at our center between January 2015 and December 2019 were analyzed. A total of 91 patients were operated by the same surgeon during the above-mentioned duration. The ureteric tunnel dissection was done according to the technique described below. The technique was evaluated for its feasibility, replicability, operating time, or any complication intra-operatively and postoperatively related to ureteric dissection. The length of hospital stay of all the patients was also assessed. This study had institutional review board approval from Sangini Hospital Ethics Committee. (approval no. ECR/147/Inst/GJ/2013/RR-19). We have obtained the written permission of patients for publication of this article.

### Surgical technique

Under general anesthesia, the patient is placed in modified Lloyd Davis position at 30° angle with the horizontal. Foleys catheter is inserted into the urinary bladder. The operating surgeon stood on the left side of the patient. The first assistant holding the camera was positioned toward the head end of the table and the second assistant on the right side helps with uterine manipulation, grasping, and retracting tissues. Port positions: five trocars were used in the authors' technique. The primary trocar (10 mm) was inserted at 1 cm above the umbilicus. Four accessory trocars (5 mm) were inserted under direct vision, two on the left and two on the right side. The first port on the left side was inserted at 2 cm above and medial to the iliac crest and the second port was inserted midway between the supra-umbilical and the left lower quadrant port. Similarly, two trocars were placed on the right side as a mirror image to the left side. The abdomen is insufflated with CO<sub>2</sub> gas and maintained at a pressure of 12 mm Hg during the surgery. In our study, the operating surgeon is a right-handed person, so having the Ultrasonic Shear in the dominant right hand and holding the atraumatic forceps in the nondominant left hand.

## Steps

### *Bladder dissection*

The loose utero-vesical fold of the peritoneum is held in mid-position with atraumatic forceps with the left hand of the surgeon and pulled vertically upwards. An incision is given at the base of it with Ultrasonic shear. This allows CO<sub>2</sub> gas to enter within the loose fold of the peritoneum and helps in the identification of the fascial plane between the bladder and the cervix. This loose fold of the peritoneum is cut from the lateral most point of one round ligament to the most lateral point of another round ligament. Further, the bladder is held centrally and traction is given in upward direction and dissection continues in the vesicovaginal plane until the bladder is mobilized away from the vagina to provide an adequate length of vaginal margins for excision.

### *Development of paravesical and pararectal spaces*

The development of avascular spaces in the pelvis is preliminary and an important step of radical hysterectomy. We will discuss here only the dissection of paravesical and pararectal space, as these are the only spaces relevant to the topic. Retro-peritoneal space dissection begins by putting the round ligament under traction. The round ligament is divided laterally using ultrasonic shear. The lateral edge of the cut peritoneum is then retracted laterally while the entire infundibulopelvic ligament is gently pulled in opposite direction. Peritoneum over the lateral border of the infundibulopelvic ligament is incised and the cut is extended in a cranial direction up to the pelvic brim. This allows CO<sub>2</sub> gas to enter within the areolar tissue of the retroperitoneal space and helps in creating a proper plane. Keeping the ureter under vision, the loose areolar tissue within this region is cut using ultrasonic shear to expose the pararectal space, medial to internal iliac artery. The uterine artery originates from the internal iliac artery which forms the common boundary between pararectal space and paravesical space. Infero-medial to the terminal part of internal iliac artery (also known as obliterated umbilical artery), operator grasps the fibro-fatty tissue with atraumatic forceps and dissects it with Ultrasonic shear to expose the paravesical space. At this point, it is important to consider removing as much as fibrofatty tissue as possible, till the base of paravesical space (formed by the levator ani muscle) is visible. This will further facilitate the ureteric tunnel dissection.

### *Releasing ureter from its peritoneal attachment*

Before starting ureteric tunnel dissection, the ureter is mobilized laterally from its broad ligament peritoneal attachment. Meso-ureter is held with atraumatic forceps and pulled laterally. Brushing strokes are applied with ultrasonic shear on the medial surface of the ureter, separating it from its peritoneal attachment.

### *Uterine artery skeletonization*

The uterine artery is properly skeletonized denuding it of all its fibrofatty tissue surrounding it.

### *Creating a window underneath the uterine artery*

The uterine artery is held with atraumatic forceps and gently pulled in upward direction and a window is created underneath it using ultrasonic shear. At this step, the uterine artery is dissected away from the ureter near its proximal attachment to specimen, using the divergent force of ultrasonic shear on the medial surface of the ureter. Fibrofatty tissue overlying the superolateral surface of the ureter is cut using ultrasonic shear to display the ureter.

### *Development of gateway of the ureteric tunnel*

#### *Left side*

The uterine artery is now kept in place by the closed tip of Ultrasonic shear. Thrust stroke is applied on the medial surface of the ureter with the opening of atraumatic forceps which highlights the entry of the ureter into the tunnel.

#### *Right side*

The uterine artery is now held in place by atraumatic forceps. Thrust stroke is applied on the medial surface of the ureter with the opening of the tip of ultrasonic shear which highlights the entry of the ureter into the tunnel [Figure 1].

### *Rotation of uterine artery*

The uterine artery is now held with atraumatic forceps with the left hand and is rotated from caudal to cranial direction [Figure 1]. At this position, the ureter is visualized through the window created underneath the uterine artery and a divergent force of ultrasonic shear is applied on the medial surface of ureter to lateralize it from the vesicouterine ligament. This is the benefit of preserving the uterine artery intact, as it facilitates the ureteric tunnel dissection.

### *Vesico-uterine ligament dissection*

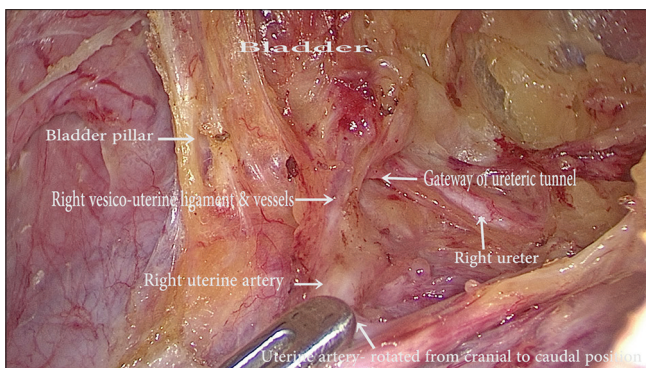
The intact uterine artery is held with atraumatic forceps with the left hand of the surgeon near to its attachment to the uterus

and traction is given laterally. The assistant is asked to hold the bladder pillar with the vesico-uterine ligament and pull in upward direction. The surgeon works with the divergent force of the tip of ultrasonic shear on the lateral side of the bladder pillar. This skeletonises the vesico-uterine ligament along with its containing vessels, separating it from the bladder and ureter caudally. The vesico-uterine ligament along with its containing vessels are gradually coagulated and cut with the tip of Ultrasonic shear in small sections while applying slight downward traction with the blades of Ultrasonic shear simultaneously [Figures 1 and 2]. This prevents the ureter away from the energy applied area.

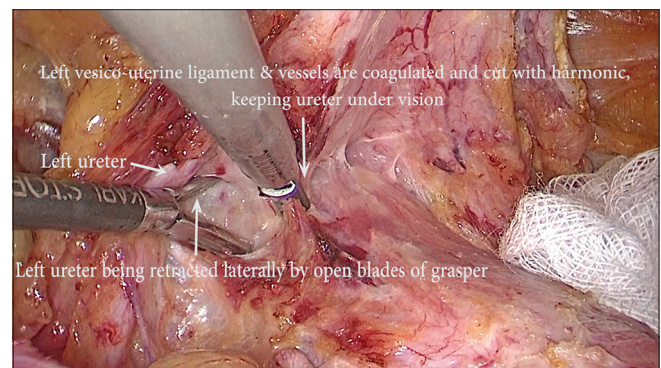
Further ureter is also safeguarded by retracting it laterally by applying the open blades of atraumatic forceps on the medial surface of the ureter by the left hand of the surgeon while delivering the energy near to the ureter. This step is especially beneficial while operating for the left ureteric tunnel dissection [Figure 2]. This is a very crucial step, as improper handling of the tissues at this point can lead to the tearing of blood vessels and the soiling of the operative field. This obscures the operative field and anatomical details are lost. The resultant inadvertent use of energy application in a haste to control the bleeding in this obscured operative field can lead to complications. Hence, a detailed and descriptive knowledge about the relevant anatomy of this area is of utmost importance. Even if the bleeding occurs, rather than undue energy application, mops can be pressurized over the bleeding area and the exact bleeding site can be localized. Consequently, bleeder can be dealt with judiciously without any complications. Thus, aforementioned steps with detailed anatomical knowledge minimize the risk. At this step, bladder is further dissected down in the bladder pillar area.

### *Recognizing the bend of the ureter*

Proceeding further, the assistant is made to hold the bladder with peritoneum near to the operating field and give upward and forward traction. The surgeon holds the meso-ureter

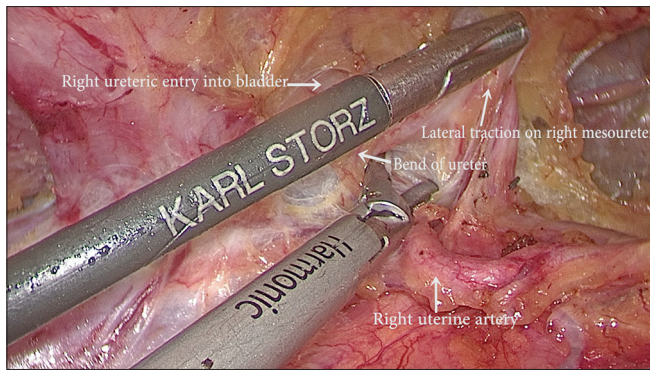


**Figure 1:** Endo-view showing right uterine artery being rotated from cranial to caudal direction. This figure also highlights vesico-uterine ligament and vessels along with bladder pillar



**Figure 2:** Endo-view showing left vesico-uterine ligament and vessels being cut and simultaneously retracting the left ureter with the open blades of grasper, keeping the ureter under vision





**Figure 3:** Endo-view highlighting the bend of ureter (knee of ureter) after providing a lateral traction on meso-ureter

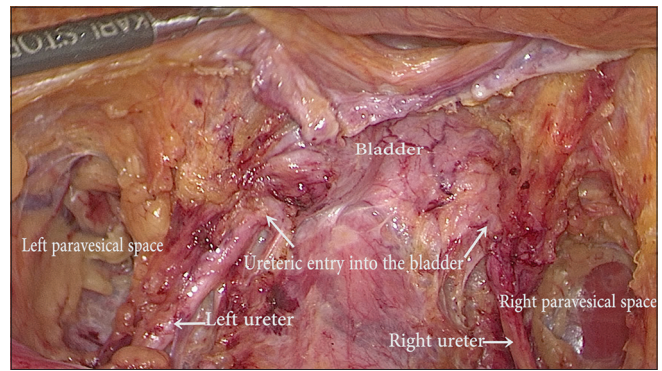
with atraumatic forceps with the left hand and gives lateral traction [Figure 3]. This step accentuates the bend of the ureter (knee of the ureter),<sup>[8]</sup> which is due to sudden deviation in its course from vertically downwards to anteromedial turn in a transverse plane to enter into the bladder. It is crucial to recognize this course of the ureter to avoid undue injuries to the terminal part of the ureter.

#### *Dissection of the terminal part of ureter till its entry into the bladder*

A proper plane is developed underneath the inferior surface of the terminal part of the ureter with the divergent force of ultrasonic shear and the ureter is freed of all fibrofatty tissue holding it. For this, the open end of atraumatic forceps safeguard and lateralize the terminal part of the ureter with the left hand of surgeon, and ultrasonic shear coagulates and cut the tissue. This also allows the surgeon to keep a constant eye over the ureter through the open blades of forceps while applying energy near to ureter. Simultaneously sweeping strokes are applied over the inferior surface of the ureter with the tip of the ultrasonic shear in upward direction. This completely lateralizes the ureter till its entry into the bladder. Now the surgeon holds the bladder near to the terminal end of the dissected ureter with atraumatic forceps with the left hand and traction is applied in upward direction. The bladder is further dissected down medially, maintaining constant traction in upward direction [Figure 4].

Further bilateral lateral parametrium, paracervical and paracolpos tissue can be easily taken with proper coagulation, without any injury to adjacent important structures. Subsequently, LRH is completed with proper margins.

The aforementioned steps of ureteric tunnel dissection with ultrasonic device can be comfortably and safely performed with other electrosurgical devices like with advanced bipolar and scissor with the same dexterity and outcomes with minimal modifications and some more surgical assistance.



**Figure 4:** Final endo-view after bilateral ureteric tunnel dissection till their respective entry into the bladder

**Table 1: Parameters evaluated in our study**

Parameters	Values
Study duration	5 years (January 2015-December 2019)
Sample size	91 cases (with bilateral ureteric tunnel dissection)
Age	Median 46 years (range 28-72 years)
BMI	Median 25.4 kg/m <sup>2</sup> (range 19.4-35.8 kg/m <sup>2</sup> )
Operating time for ureteric tunnel dissection	Median 3 min 15 s (range 2 min 35 s-6 min 18 s)
Complication (intra-operative and postoperative)	0
Conversion to laparotomy	0
Hospital stay	Median 2 days (range 1-4 days)

BMI: Body mass index

## RESULTS

A total of 91 patients were operated for LRH in the last 5 years with bilateral ureteric tunnel dissection. The median age of the patients was 46 years (range, 28–72 years) and the median body mass index (BMI) was 25.4 kg/m<sup>2</sup> (range, 16–32 kg/m<sup>2</sup>).

The median time for one side ureteric tunnel dissection was 3 min 15 s (range 2 min 35 s–6 min 18 s). None of the cases were converted to laparotomy. The patients' median hospital stay was 2 days (range 1–4 days). There were no short-term or any long-term complications related to ureteric dissection [Table 1].

## DISCUSSION

LRH has gained quiet an acceptance among gynec-oncologists in recent times owing to its benefits of the minimal invasive approach. Ureteric tunnel dissection is one of the most imperative trends of LRH. Ureteric tunnel dissection, if performed aptly, will determine the adequacy of parametrium, paracolpos, and paravaginal tissue, thus helping in the retrieval of a complete specimen with proper margins. This will further guide the prognosis of the patients.

**Table 2: Comparative Table**

Evaluated factors	Our study	Volpi <i>et al.</i> study
Study duration	5 years (January 2015-December 2019)	January 2002-April 2004
Sample size	91 cases (with bilateral ureteric tunnel dissection)	17 patients (31 ureters were unroofed; in three patients, monolateral dissection was performed)
Indication of procedure	Early cervical cancer FIGO Stage IA2, IB1 and IB2	Cervical cancer, endometrial cancer, endometriosis, myoma
Operating time for ureteric tunnel dissection	Median 3 min 15 s (range 2 min 35 s-6 min 18 s)	Median 14 min 35 s (range 10 min 15 s-63 min)
Conversion to laparotomy	0	0
Complication (intra-operative and postoperative)	0	0
Hospital stay	Median 2 days (range 1-4 days)	Median 3 days (range 2-10 days)

FIGO: International federation of gynaecology and obstetrics

Different authors have used and described different techniques of LRH in the literature. However, there are very few articles specific for this most crucial step of LRH, that is ureteric tunnel dissection. Volpi *et al.*<sup>[9]</sup> had described laparoscopic dissection of the ureter for radical laparoscopic hysterectomy in 2005. However, the sample size was small and LRH with varied indications (like cervical carcinoma, endometrial carcinoma, endometriosis, myoma) were enrolled in the study. The appropriacy of the specimen was not a requisite in all the cases, which is the principal impetus to elucidate the steps of ureteric tunnel dissection. While our study recruited only cervical carcinoma cases which further validate the study because the sample population is identical [Table 2].

The average median time to emancipate the ureter with complete ureteric tunnel dissection on one side was 3 min 15 s. The perplexing ureteric tunnel dissection was observed with substandard health of the tissue which were usually seen with old age cases, postmenopausal females and with diabetes mellitus as a comorbid condition. These cases required a comparatively prolonged duration to complete the procedure. However, still, it was considerably lesser as compared to Volpi *et al.*<sup>[9]</sup> the study, where the median time to free the ureter on one side was 14 min 35 s. None of the patients required conversion to laparotomy [Table 2]. Even with patients with extremes of BMI (BMI = 19.4 or BMI >25) were operated on with relative ease following the aforementioned surgical steps for ureteric tunnel dissection.

Given a normal unirradiated ureter, we believe that the incidence of ureteral fistulas and permanent stenosis can be kept below 1% with meticulous intraoperative management of the ureter by a technically skilful operator who can prevent vascular trauma to the periurethral sheath and injury to the muscularis of the ureter.<sup>[10]</sup> Nevertheless, we did not have any intra- or postoperative ureteric complications. However, correct surgical technique, advanced laparoscopic surgical skills, and detailed anatomical knowledge are prerequisite for it.

The rationale behind the development of the authors' technique was to have a standardized approach for complete dissection

that exposes the anatomical references necessary for an appropriate ureteric tunnel dissection that make LRH a safer procedure, with minimal complications. The author has a substantial sample size (91 patients were operated with a total of 182 ureteric tunnel dissection was done on bilateral sides). This sizeable sample size ensures the rationality of the operative technique illustrated above. The uterine artery was kept intact till the end of the procedure, as an intact uterine artery was utilized to impart appropriate traction for ureteric tunnel dissection. A comprehensive understanding of the relevant anatomy along with exhaustive and intricate knowledge of manipulating the tissue and energy source are the pivotal ingredient of ureteric tunnel dissection. The authors have attempted to assimilate these steps sequentially to make ureteric tunnel dissection simple and safe.

## CONCLUSION

Ureteric tunnel dissection is one of the most pivotal step of LRH. Explicit and elaborative knowledge of pertinent anatomy with apt surgical technique is crucial for the completeness of the procedure. This is by far the largest study with a substantial sample size exclusively for ureteric tunnel dissection in LRH. This analysis explains the descriptive methodology of operative technique, especially for ureteric tunnel dissection in LRH. There was neither extended hospital stay nor any further intervention or procedure required in any of the patients relating to ureteric tunnel dissection. This technique is easily reproducible and replicable, with chances of marginal or negligible complication rates.

## Financial support and sponsorship

Nil.

## Conflicts of interest

There are no conflicts of interest.

## REFERENCES

1. Limbachiya D, Gandhi P, Kenkre M, Shah S, Chawla H, Agrawal G, *et al.* Laparoscopic radical hysterectomy with lymphadenectomy in cervical cancer: Our technique and experience. *Eur J Gynecol Oncol* 2019;40:394-401.

2. Canis M, Mage G, Wattiez A, Pouly JL, Manhes H, Bruhat MA. Does endoscopic surgery have a role in radical surgery of cancer of the cervix uteri? *J Gynecol Obstet Biol Reprod (Paris)* 1990;19:921.
3. Nezhat CR, Burrell MO, Nezhat FR, Benigno BB, Welander CE. Laparoscopic radical hysterectomy with paraaortic and pelvic node dissection. *Am J Obstet Gynecol* 1992;166:864-5.
4. Salicrú SR, de la Torre JF, Gil-Moreno A. The surgical management of early-stage cervical cancer. *Curr Opin Obstet Gynecol* 2013;25:312-9.
5. Hong JH, Choi JS, Lee JH, Eom JM, Ko JH, Bae JW, *et al.* Can laparoscopic radical hysterectomy be a standard surgical modality in stage IA2-IIA cervical cancer? *Gynecol Oncol* 2012;127:102-6.
6. Yan X, Li G, Shang H, Wang G, Chen L, Han Y. Complications of laparoscopic radical hysterectomy and pelvic lymphadenectomy – Experience of 117 patients. *Int J Gynecol Cancer* 2009;19:963-7.
7. Ramirez PT, Frumovitz M, Pareja R, Lopez A, Vieira M, Ribeiro R, *et al.* Minimally invasive versus abdominal radical hysterectomy for cervical cancer. *N Engl J Med* 2018;379:1895-904.
8. Thompson JD. Operative injuries to the ureter: Prevention, recognition, and management. In: Rock JA, Thompson JD, editors. *Te Linde's Operative Gynecology*. 8<sup>th</sup> ed. Philadelphia, PA: Lippincott Raven; 1997. p. 1137.
9. Volpi E, Ferrero A, Carus AP, Jacomuzzi E, Sismondi P. Laparoscopic dissection of the ureter for radical laparoscopic hysterectomy. *Gynecol Surg* 2005;2:179-82.
10. Dennis SC, Abu-Rustam NR, Plante M, Roy M. Cancer of the cervix. In: Rock JA, Jones 3<sup>rd</sup> HW, editors. *Te Linde's Operative Gynecology*. 10<sup>th</sup> ed. Philadelphia, PA: Lippincott Raven; 2008. p. 1278.