

New developments in magnetic resonance imaging techniques for shoulder instability in athletes

Timothy R McAdams¹
Michael Fredericson¹
Melissa Vogelsong²
Garry Gold²

¹Department of Orthopedic Surgery, Stanford University School of Medicine, ²Department of Radiology, Stanford University School of Medicine, CA, USA

Abstract: Magnetic resonance (MR) imaging can be a very useful tool in the evaluation of instability in the athlete's shoulder. Technical options of MR imaging, such as arthrography, higher power magnets, and shoulder positioning, have enhanced MR evaluation of the shoulder. This update discusses the application of new MR techniques to a variety of shoulder instability patterns, including anterior instability, posterior instability, and atraumatic multidirectional instability. Specific applications of MR imaging in the postoperative patient is discussed. Finally, we describe the future directions of MR imaging in the setting of shoulder instability.

Keywords: athletes, magnetic resonance imaging, shoulder instability

Introduction

Shoulder instability is a common problem in which the degree of structural tissue injury and the direction of the instability vary greatly. Magnetic resonance (MR) imaging is a valuable tool for the diagnosis and management of shoulder instability. In recent years, new techniques have been developed in an effort to enhance the visualization of the structural entities (the labrum, capsule, and glenohumeral bone and articular cartilage) involved in shoulder instability. In this update of the use of MR imaging in the evaluation of shoulder instability, general principles and technical options are reviewed and three clinical scenarios of shoulder instability (traumatic anterior, traumatic posterior, and atraumatic multidirectional) as well as postoperative imaging are discussed.

General principles for MR imaging evaluation of the shoulder

Most facilities have standard protocols for MR imaging evaluation of the shoulder which include oblique coronal, oblique sagittal, and axial views: T1- and T2-weighted fat-saturated images for pathologic evaluation and often a proton density-gradient echo for the labrum. As technology continues to evolve, physicians have an increasing number of options (eg, use of dye, special positioning views, and/or higher power magnets) for using MRI to evaluate the unstable shoulder.

Enhancement of the glenohumeral joint with dye, usually gadolinium, can be either direct (as in the MR arthrogram) or indirect (as in intravenous contrast). Direct arthrographic protocols vary, but the resultant images have been shown to be superior to nonenhanced images in the evaluation of the glenohumeral labrum.¹ In the evaluation of the labrum, conventional MR has a lower sensitivity and specificity (68%–93%) than does an MR arthrogram (91%–93%).^{2,3} Direct arthrograms also facilitate the

Correspondence: Timothy McAdams
Department of Orthopedic Surgery,
Stanford University, 450 Broadway Street,
Redwood City, CA 94063, USA
Tel +1 650 721 7800
Fax +1 650 721 3470
Email tmcadams@stanford.edu

injection of a local anesthetic and/or corticosteroid solutions into the glenohumeral joint, which can be helpful both diagnostically and therapeutically in patients with shoulder instability. However, the injection of the dye is not without risk, the scan times may be longer, and logistical and scheduling difficulties can occur in some centers that are not equipped for the routine use of arthrogram enhancement.

Indirect arthrography involves the use of an intravenous contrast agent. In that technique, gadolinium is injected intravenously, and delayed imaging is performed after the patient has engaged in passive exercise for about 15 minutes. The advantages of that technique include differential enhancement of local vascularity, no need for a fluoroscopic unit or a radiologist to inject the dye, and improved visualization of small cartilaginous defects. Disadvantages include difficulty in interpreting differential enhancement, lack of joint distension, the risks of intravenous contrast, and relatively longer scan times.

Investigations continue to explore the value of specific positioning and views in identifying shoulder pathologies. For example, the abduction-external rotation view can be helpful in the evaluation of some labral injuries by applying tension to the anterior capsulolabral complex.⁴ When that technique is performed, the patient places the palm of one hand behind his or her head. (Figure 1). More recently, an adduction-internal rotation view that is used to evaluate anterior labroligamentous periosteal sleeve avulsion (ALPSA) lesions has been described.⁵

Higher power MR imaging is now available in many regions in the form of a 3 Tesla (3T) MR image rather than the traditional 1.5 Tesla (1.5T) (Figure 2a–d). Some

investigations have shown that the 3T MR imaging has a very high sensitivity and specificity in labral tear evaluation.⁶ Furthermore, when combined with an MR arthrogram, a 3T MR image may be even more specific for labral tears.⁷ The potential disadvantages of 3T MR imaging include cost, longer scan times, and susceptibility artifact.

Traumatic anterior dislocation

The most common traumatic dislocation involves injury to the anterior labrum, which results in the classic Bankart anteroinferior labroligamentous disruption. Other injury patterns caused by that mechanism include the anterior glenoid bony (“bony Bankart”) lesion, avulsion of the anteroinferior labrum with an intact scapula periosteum (Perthes) lesion, the anterior glenolabral articular defect (GLAD) lesion, the anterior labroligamentous periosteal sleeve avulsion (ALPSA) lesion, and humeral avulsion of the glenohumeral ligament (HAGL) lesion. MRI has proven useful in the evaluation of all those injuries. (Figure 3). The 3T MR arthrogram appears to have the highest specificity for those types of labral injuries.⁷ HAGL lesions deserve special mention because they are being increasingly recognized and treated. However, a recent study described four patients in whom HAGL lesions were seen on MRI but not during arthroscopy.⁸ Further study is needed to understand those false-positive results, which have also occurred in our practice.

Varying degrees of anteroinferior bone loss can occur as a result of recurrent anterior instability, and Hill-Sachs bone defects of the posterolateral humeral head are common. (Figure 4). Computed tomographic (CT) imaging has been the imaging modality of choice to evaluate those defects,

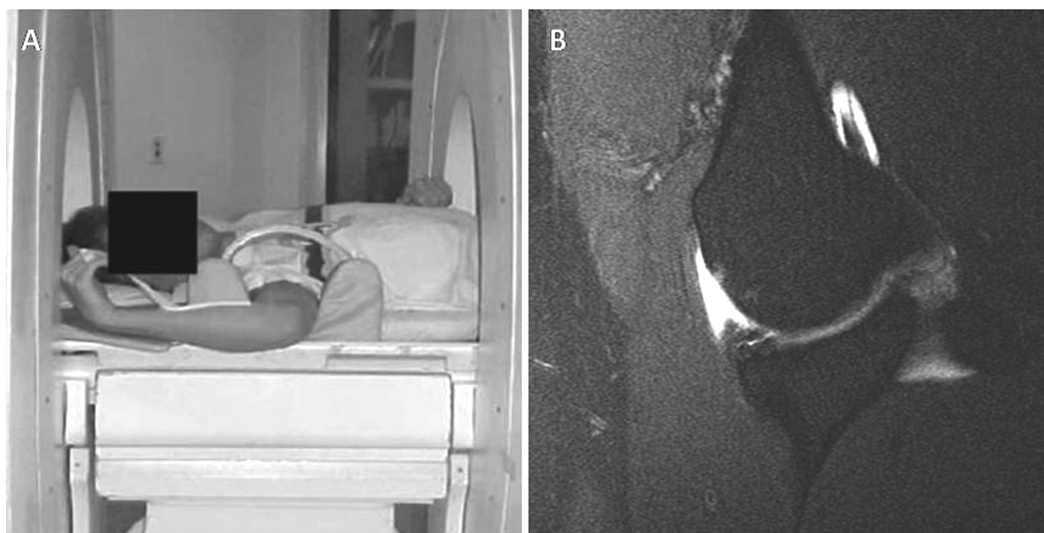


Figure 1 A) ABER (abduction/external rotation) position. B) ABER view of anteroinferior labral tear.

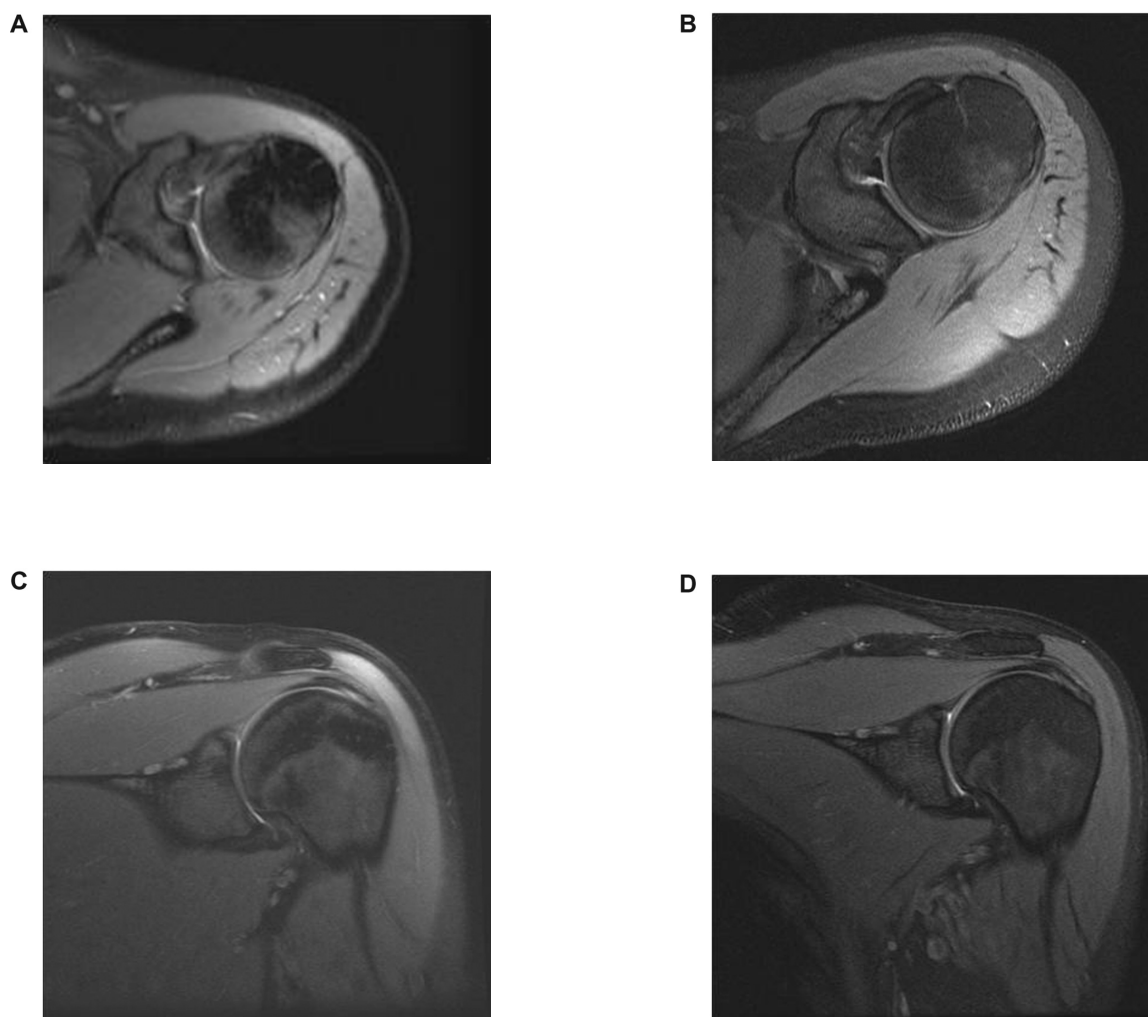


Figure 2 Comparison of 1.5 T and 3 T images of the shoulder. **A)** 1.5 T axial PD image. **B)** 3 T axial PD image. **C)** 1.5 T coronal-oblique PD image. **D)** 3 T coronal-oblique PD image.

but it subjects the patient to significant doses of radiation. MRI can be helpful in the evaluation of bone defects as well. A recent cadaveric study showed no statistical difference between the results from MR and CT imaging in the evaluation of glenoid bone defects.⁹

Traumatic posterior dislocation

Acute posterior dislocations account for only 2%–4% of all glenohumeral dislocations.¹⁰ As in cases of anterior instability, posterior instability can involve a posterior labrum tear or any number of variants. Reverse glenohumeral ligament avulsion (GLAD) lesions, posterior labrocapsular periosteal sleeve avulsion (POLPSA) lesions, and humeral avulsion of the posterior glenohumeral ligament can all be visualized with MR imaging.¹¹ In addition, MR imaging is useful in the identification of superficial tears between the postero-inferior labrum and the glenoid articular cartilage without

complete detachment of the labrum (marginal cracking, or “Kim Lesion”)¹¹ (Figure 5). Paraglenoid cysts, which are common in patients with a posterior labral tear, can be addressed with image-guided aspiration after their detection with MR imaging. Paraglenoid cysts arising from posterior or posterosuperior labral tears can extend into the spinoglenoid or suprascapular notch and cause nerve compression, and MR imaging is useful in determining the extent of those cysts.¹²

Posterior dislocations and instability can result in posterior glenoid bone injury (a reverse bony Bankart lesion) or defects in the anteromedial humeral head (a reverse Hill-Sachs defect). (Figure 6). A Bennett lesion, which is an extra-articular calcification along the posteroinferior glenoid, is often seen in throwing athletes. MR imaging can evaluate the association of that calcification with any posterior labrum tears in the region of the posterior band of the inferior glenohumeral ligament.

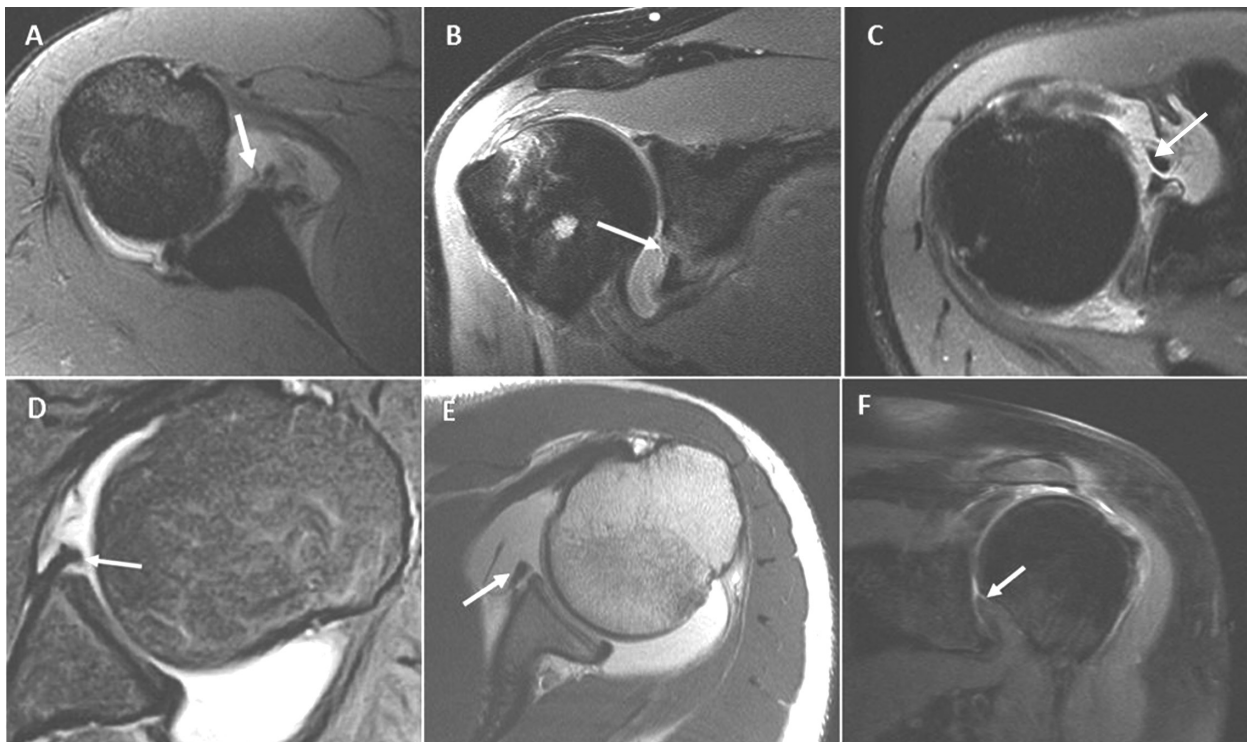


Figure 3 MRI of traumatic anterior injuries of the shoulder. **A)** Bankart lesion. **B)** Bony Bankart lesion. **C)** Perthes lesion. **D)** GLAD lesion. **E)** ALPSA lesion. **F)** HAGL lesion.

Atraumatic multidirectional instability

Atraumatic multidirectional instability is a broad term that encompasses a number of distinct pathological and physiologic laxity problems in patients with shoulder instability. The various presentations of that condition are beyond the scope of this review, but it is worthwhile to describe the utility of MR imaging in individuals with multidirectional laxity or multidirectional instability (MDI). One study found the cross-sectional area of the

capsule was increased in the setting of MDI with MR arthrography compared to controls.¹³ Laxity is often very difficult to assess with MR imaging or even MR arthrography. Capsular stretching and laxity can be difficult to quantify.¹⁴ There appears to be great variation in the degree of patulous capsules identified with MR imaging, and it is challenging to base treatment recommendations on the imaging studies.

The dimensions of the rotator interval, considered an important structure in patients with MDI, can be visualized

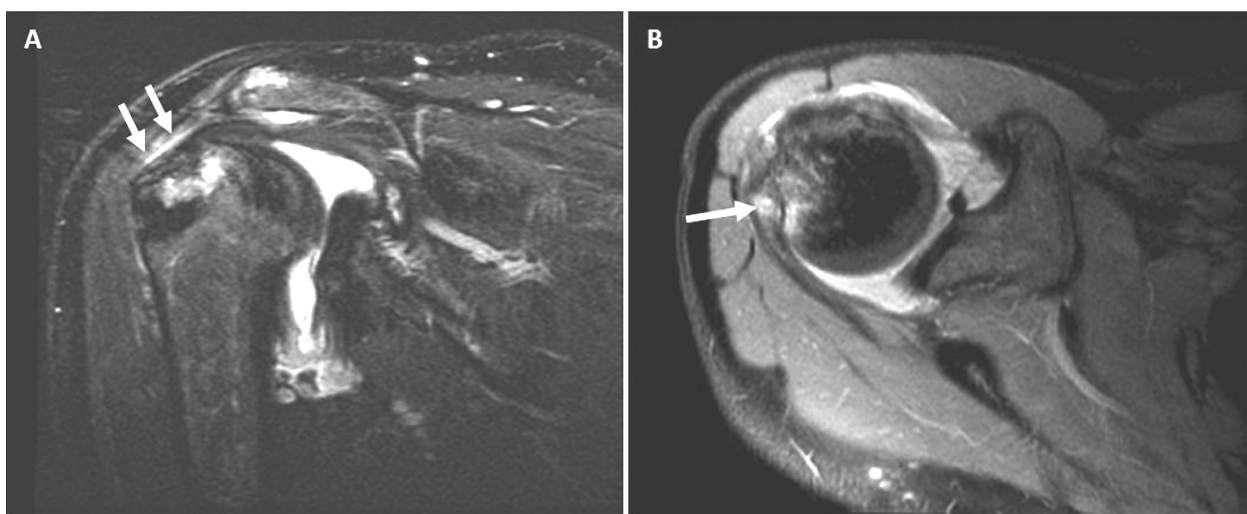


Figure 4 MRI of a humeral head Hill-Sachs lesion. **A)** Coronal-oblique view. **B)** Axial view.

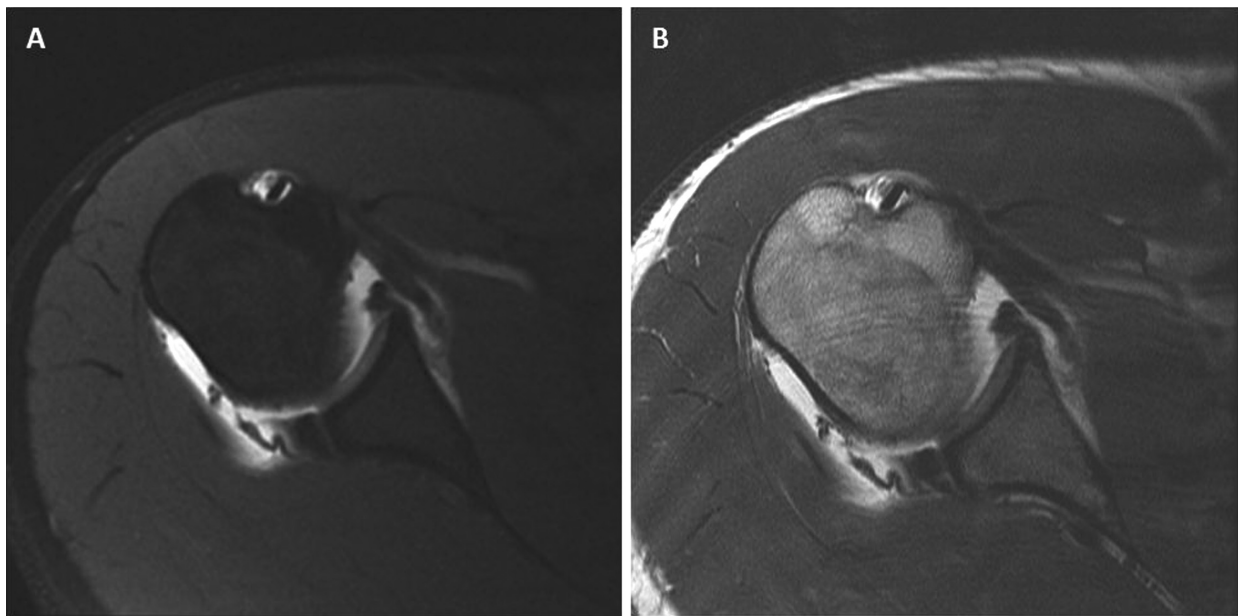


Figure 5 MRI of Kim lesion of the posterior-inferior glenoid labrum. **A)** Fat saturated T1 arthrogram. **B)** T1 arthrogram without fat suppression.

with MR arthrography. Kim et al reported significantly greater dimensions of the rotator interval in patients with instability than in those with no instability.¹⁵ Open MR imaging has also been recently used to study alterations in static stabilizers in patients with MDI.¹⁶ These developments may increase the utility of MR imaging in the management of patients with atraumatic multidirectional instability but at present routine MR imaging of these patients can be questioned.

Postoperative imaging

Evaluation of the labrum after surgical repair can be challenging, but MR imaging can be useful in that assessment. Some investigators have found that when compared with surgical findings MR arthrography has good accuracy (91.9%), sensitivity (100%), and specificity (85%) in the

evaluation of anteroinferior labral tears.¹⁷ In addition, patients with recurrent shoulder instability after arthroscopic Bankart repair have been found to have less prominent capsulolabral buttress dimensions when evaluated by 1.5T MR imaging.¹⁸ MR imaging is also useful in the identification of cystic changes that can occur around bioabsorbable implants in postoperative patients.

Future directions in magnetic resonance imaging of shoulder instability

Many labral injuries are stable in static images but become symptomatic only when stress is applied in a dynamic situation. Dynamic imaging is being explored in many centers, including our institution. Open MR imaging enables dynamic

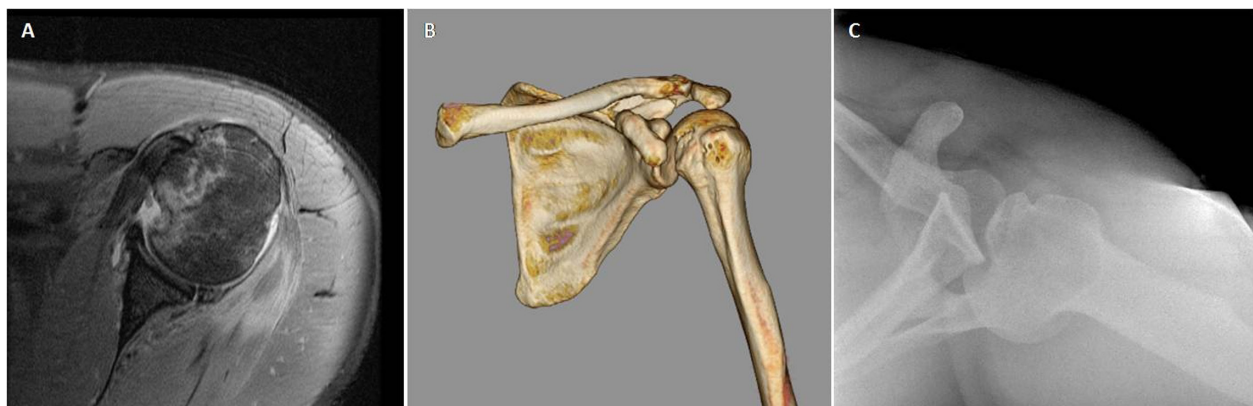

Figure 6 Engaging reverse Hill-Sachs lesion showing marrow edema on the anterior humeral head along with the bony trough. **A)** MRI. **B)** 3D CT reconstruction. **C)** Injury plain film radiograph in posteriorly dislocated position.

abduction-external rotations and even throwing motions can be replicated. As technology improves, more dynamic MR imaging assessments of shoulder instability should become feasible. This could greatly improve our understanding of labral injuries, especially in patients with a subtle labral pathologic condition.

Disclosure

The authors report no conflicts of interest in this work

References

- Gusmer PB, Potter HG, Schatz JA, et al. Labral injuries: accuracy of detection with unenhanced MR imaging of the shoulder. *Radiology*. 1996;200:519–524.
- Iannotti JP, Zlatkin MD, Esterhai JL, et al. Magnetic resonance imaging of the shoulder. Sensitivity, specificity, and predictive value. *J Bone Joint Surg (Am)*. 1991;73:17–29.
- Palmer WE, Brown JH, Rosenthal DI. Labral-ligamentous complex of the shoulder: evaluation with MR arthrography. *Radiology*. 1994;190:645–651.
- Saleem AM, Lee JK, Novak LM. Usefulness of the abduction and external rotation views in shoulder MR arthrography. *Am J Roentgenol*. 2008;191:1024–1030.
- Song HT, Huh YM, Kim S, et al. Anteroinferior labral lesions of recurrent shoulder dislocation evaluated by MR arthrography in an adduction internal rotation (ADIR) position. *J Magn Reson Imag*. 2006;23:29–35.
- Magee T, Williams D. Sensitivity and specificity in detection of labral tears with 3.0 T MRI of the shoulder. *Am J Roentgenol*. 2006;187:1448–1452.
- Magee T. 3-T MRI of the shoulder: Is MR arthrography necessary? *Am J Roentgenol*. 2009;192:86–92.
- Melvin JS, MacKenzie JD, Nacke E, et al. MRI of HAGL lesions: Four arthroscopically confirmed cases of false-positive diagnosis. *Am J Roentgenol*. 2008;191:730–734.
- Huijsmans PE, Haen PS, Kidd M, et al. Quantification of a glenoid defect with three-dimensional computed tomography and magnetic resonance imaging: A cadaveric study. *J Shoulder Elbow*. 2007;16:803–809.
- Murray PJ, Shaffer BS. Clinical update: MR imaging of the shoulder. *Sports Med Arthrosc Rev*. 2009;17:40–48.
- Shah N, Tung GA. Imaging signs of posterior glenohumeral instability. *Am J Roentgenol*. 2009;192:730–735.
- Steinbach LS. MRI of shoulder instability. *Eur J Radiol*. 2008;68:57–71.
- Dewing CB, McCormick F, Bell SJ, et al. An analysis of capsular area in patients with anterior, posterior, and multidirectional shoulder instability. *Am J Sports Med*. 2009;36:515–522.
- Parker BJ, Zlatkin MB, Newman JS, Rathur SK. Imaging of shoulder injuries in sports medicine: Current protocols and concepts. *Clin Sports Med*. 2008;27:579–606.
- Kim KC, Rhee KJ, Shin HD, Kim YM. Estimating the dimensions of the rotator interval with use of magnetic resonance arthrography. *J Bone Joint Surg (Am)*. 2007;89:2450–2455.
- von Eisenhart-Rothe R, Mayr HO, Hinterwimmer S, Graichen H. Simultaneous 3D assessment of glenohumeral shape, humeral head centering, and scapular positioning in atraumatic shoulder instability: A magnetic resonance-based in vivo analysis. *Am J Sports Med*. 2009; epub PreView.
- Probyn LJ, White LM, Salonen DC, et al. Recurrent symptoms after shoulder instability repair: Direct MR arthrographic assessment-correlation with second-look surgical evaluation. *Radiology*. 2007; 245:814–823.
- Yoo JC, Lee YS, Tae SK, et al. Magnetic resonance imaging appearance of a repaired capsulolabral complex after arthroscopic Bankart repair. *Am J Sports Med*. 2008;36:2310–2316.

Open Access Journal of Sports Medicine

Publish your work in this journal

Open Access Journal of Sports Medicine is an international, peer-reviewed, open access journal publishing original research, reports, reviews and commentaries on all areas of sports medicine. The manuscript management system is completely online and includes a very quick and fair peer-review system.

Submit your manuscript here: <http://www.dovepress.com/open-access-journal-of-sports-medicine-journal>

Dovepress

Visit <http://www.dovepress.com/testimonials.php> to read real quotes from published authors.